



RAPID COMMUNICATION

Endoscopic findings can predict the efficacy of leukocytapheresis for steroid-naïve patients with moderately active ulcerative colitis

Yasushi Umehara, Masatoshi Kudo, Masanori Kawasaki

Yasushi Umehara, Masatoshi Kudo, Masanori Kawasaki, Division of Gastroenterology and Hepatology, Department of Internal Medicine Kinki University School of Medicine, 377-2 Ohno-Higashi, Osaka-Sayama 589-8511, Japan

Author contributions: Umehara Y, Kudo M and Kawasaki M contributed equally to this work; Umehara Y and Kudo M designed research; Umehara Y and Kawasaki M performed research; Umehara Y and Kudo M contributed new reagents/analytic tools; Umehara Y and Kudo M analyzed data and Umehara Y wrote the paper.

Correspondence to: Masatoshi Kudo, MD, PhD, Division of Gastroenterology and Hepatology, Department of Internal Medicine Kinki University School of Medicine, 377-2 Ohno-Higashi, Osaka-Sayama 589-8511, Japan. m-kudo@med.kindai.ac.jp

Telephone: +81-723-660221-3525 Fax: +81-723-672880

Received: June 21, 2008 Revised: August 11, 2008

Accepted: August 18, 2008

Published online: September 14, 2008

for steroid-naïve UC patients with moderate disease activity. Moreover, the efficacy of the treatment can be predicted on the basis of endoscopic findings.

© 2008 The WJG Press. All rights reserved.

Key words: Ulcerative colitis; Steroid-naïve; Leukocytapheresis; Efficacy; Endoscopic findings

Peer reviewer: Alastair JM Watson, Professor, Department of Gastroenterology, University of Liverpool, the Henry Wellcome Laboratory, Nuffield Bldg, Crown St, Liverpool L69 3GE, United Kingdom

Umehara Y, Kudo M, Kawasaki M. Endoscopic findings can predict the efficacy of leukocytapheresis for steroid-naïve patients with moderately active ulcerative colitis. *World J Gastroenterol* 2008; 14(34): 5316-5321 Available from: URL: <http://www.wjgnet.com/1007-9327/14/5316.asp> DOI: <http://dx.doi.org/10.3748/wjg.14.5316>

Abstract

AIM: To investigate the therapeutic usefulness of leukocytapheresis (LCAP; Cellsoba) in steroid-naïve patients with moderately active ulcerative colitis (UC).

METHODS: Eighteen steroid-naïve patients with moderately active UC received one LCAP session every week for five consecutive weeks.

RESULTS: The remission rate 8 weeks after the last LCAP session was 61.1% (11/18). All three patients with deep ulcers showed worsening after LCAP. For the remaining 15 patients, who had erosions or geographic ulcers, the average clinical activity index (CAI) score dropped significantly from 9.4 to 3.8 eight weeks after the last LCAP session ($t = 4.89$, $P = 0.001$). The average C-reactive protein (CRP) levels before and after LCAP were 1.2 mg/dL and 1.0 mg/dL, respectively. Of the patients with erosions, geographic ulcers, and deep ulcers, 100% (9/9), 33.3% (2/6), and 0% (0/3) were in remission 8 weeks after the last LCAP session, respectively ($\chi^2 = 7.65$, $P < 0.005$). Forty-eight weeks after the last LCAP session, the remission rates for patients with erosions and geographic ulcers were 44.4% (4/9) and 16.7% (1/6), respectively. Only one patient suffered a mild adverse event after LCAP (nausea).

CONCLUSION: LCAP is a useful and safe therapy

INTRODUCTION

Although the etiology of ulcerative colitis (UC) is still unknown, it is believed that an immune abnormality may be involved in its development^[1,2]. It is characterized by chronic over-activation of the colonic mucosal immune system. Consequently, if remission cannot be achieved by salazosulfapyridine or mesalazine treatment, the second line of treatment has conventionally been to administer steroids^[2-6]. However, steroid administration can increase susceptibility to infections, diabetes mellitus and osteoporosis. Recently, it was reported that steroid-refractory or steroid-dependent patients with UC can be effectively treated by cytapheresis^[7-10]. To determine whether leukocytapheresis (LCAP) may also be useful with other UC patients, we administered LCAP to 18 steroid-naïve UC patients. We also assessed whether the efficacy of LCAP can be predicted on the basis of endoscopic findings.

MATERIALS AND METHODS

From January 2005 to April 2007, 33 UC patients were treated with LCAP at our hospital. All patients were

Table 1 Steroid-naïve UC patient characteristics (mean \pm SD)

Characteristics	Data
Male/Female	11/7
Age (yr)	46.1 \pm 18.4
Duration of disease (yr)	6.0 \pm 8.5
Clinical course	
First attack	4
Relapse-remitting	6
Chronic continuous	8
Extent of disease	
Entire	15
Left sided	2
Rectum	1
Endoscopic findings	
Erosions	9
Geographic ulcers	6
Deep ulcers	3

examined by colonoscopy before treatment and UC was diagnosed on the basis of established endoscopic and histological criteria^[11]. At the time of diagnosis, infectious colitis (*Salmonella*, *Campylobacter*, *Vibrio*, *Yersinia* and *Shigella spp.*) was ruled out by stool culture and *Clostridium difficile* toxin testing. Moreover, we excluded Crohn's disease, ischemic colitis, radiation colitis and intestinal Behçet disease. None of patients were receiving drugs, including non-steroidal anti-inflammatory drugs or antibiotics. Patients with severe cardiovascular disease, severe cerebral disease, severe anemia (hemoglobin; less than 8 g/dL) and hypotension (less than 80 mmHg) were excluded. Of the 33 patients, 15 had severe activity and were treated with steroids along with LCAP. These patients were excluded from the study. The remaining 18 steroid-naïve patients had moderate activity, as defined by a Lichtiger's clinical activity index (CAI) score^[12] of < 12. These patients were enrolled in the study. Their characteristics are summarized in Table 1.

For all patients, LCAP sessions were performed once a week for five consecutive weeks by using Cellsorba (Asahi Medical Co., Ltd, Tokyo, Japan). Leukocyte removal in LCAP is effective because of its adherence to fibers in the filter. The throughput was 2-3 L of whole blood and the flow rate was 30-50 mL/min for approximately 60 min. The access and return lines were connected to cubital veins. Heparin was used as an anticoagulant for the extracorporeal circulation.

Patients were 46.1 \pm 18.4 years old; there were 11 males and 7 females. Their duration of disease was 6.0 \pm 8.5 years. With regard to their clinical course, four patients presented the "first attack" type, six the "relapse-remitting" type, and eight the "chronic continuous" type. We defined patients presenting with an activity phase lasting for 6 mo or longer from the first attack as belonging to the "chronic continuous" type. Fifteen patients had total colitis, two had left-sided colitis and one had proctitis. We performed endoscopy before and after LCAP. For the present study, we classified the patients into three groups on the basis of the endoscopic findings before LCAP treatment, namely, those with erosions, geographic ulcers, or deep

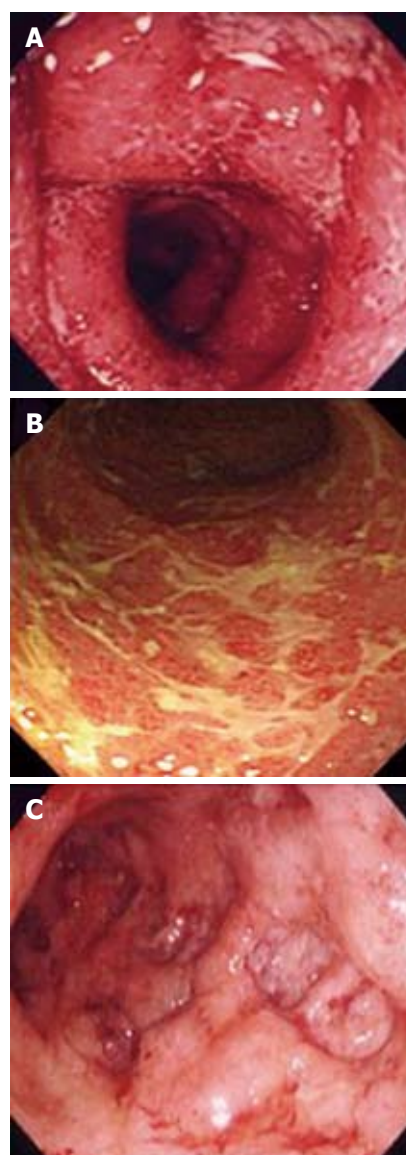


Figure 1 The patients were divided before LCAP into three groups according to whether their endoscopic findings revealed erosions (A), geographic ulcers (B), or deep ulcers (C). Representative findings are shown.

ulcers (Figure 1). Nine patients had erosions in the large intestine, six had geographic ulcers, and three had deep ulcers. All patients were concomitantly treated with mesalazine (2250 mg/d) for at least 4 weeks prior to the initiation of LCAP therapy. There was no change in the dosage of mesalazine. Immunomodulators such as azathioprine, 6-mercaptopurine and cyclosporine were never administered.

Disease activity was evaluated before and after LCAP by measuring the CAI. A CAI less than 4 indicates remission. Relapses were also identified when the patient needed another therapy, such as steroid or cyclosporine treatment and/or LCAP.

The endpoint of this study was to determine the factor related to remission by LCAP.

Statistical analysis

The Wilcoxon test was used to compare CAI scores

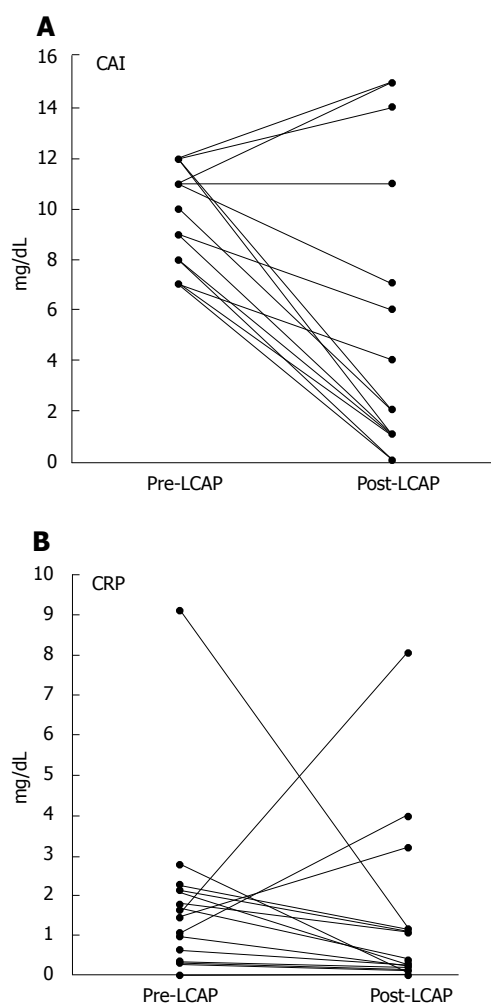


Figure 2 Change in average CAI score (A) and CRP levels (B) 8 wk after the last LCAP session. The data of the three patients with deep ulcers whose conditions worsened during LCAP are not included. The average CAI dropped from 9.4 ± 1.9 to 3.8 ± 4.8 ($P = 0.001$) while the average CRP levels before and after LCAP were 1.2 ± 0.8 mg/dL and 1.0 ± 2.0 mg/dL, respectively, and did not differ significantly.

and C-reactive protein (CRP) levels before and after treatment. The Mann-Whitney U -test was used to compare the age, duration of disease, pre-CAI, post-CAI, pre-CRP and post-CRP levels of two groups, while the χ^2 test was used to test the effect of sex. χ^2 test was used to compare the clinical course, extent of disease and endoscopic findings of two groups. $P < 0.05$ was considered to indicate statistical significance. Results were presented as mean \pm SD.

RESULTS

Efficacy of LCAP

For all 18 patients, the remission rates 8 and 48 wk after the last LCAP session were 61.1% (11/18) and 27.7% (5/18), respectively. At 48 wk after remission, the relapse rate was 54.5% (6/11), and the duration to relapse was 8.7 ± 4.2 mo. Three patients with deep ulcers worsened during LCAP and required additional treatments such as steroids. However, the remaining 15 patients showed a significant drop in the CAI score from 9.4 ± 1.9 to $3.8 \pm$

Table 2 Comparison of responders and non-responders 8 wk after the last LCAP session (mean \pm SD)

	Responders (<i>n</i> = 11)	Non-responders (<i>n</i> = 7)	<i>P</i>
Patient characteristic			
Male/Female	7/4	4/3	NS
Age (yr)	39.7 ± 15.9	56.1 ± 17.5	NS
Duration of disease (yr)	5.7 ± 7.7	6.3 ± 9.7	NS
Pre-CAI	9.0 ± 2.0	11.1 ± 0.9	NS
Pre-CRP	1.0 ± 0.8	2.4 ± 2.7	NS
Clinical course			
First attack	4	0	< 0.001
Relapse-remitting	6	0	
Chronic continuous	1	7	
Extent of disease			
Entire	8	7	NS
Left sided	2	0	
Proctitis	1	0	
Endoscopic findings			
Erosions	9	0	< 0.005
Geographic ulcers	2	4	
Deep ulcers	0	3	

LCAP: Leukocytopheresis; CAI: Clinical activity index; CRP: C-reactive protein levels (mg/dL).

4.8 eight weeks after the last LCAP session ($P = 0.001$) (Figure 2). The CRP levels before (1.2 ± 0.8 mg/dL) and after (1.0 ± 2.0 mg/dL) LCAP did not differ significantly (Figure 2). When the endoscopic findings obtained before LCAP were considered, we found that all nine patients with erosions had entered remission (100%) 8 wk after the last LCAP session. However, only two of six (33%) and none of three of the patients with geographic ulcers and deep ulcers, respectively, had entered remission at this time point ($P < 0.005$) (Table 2). The remission rates dropped over time as of the patients with erosions and geographic ulcers who were in remission at the 8-wk timepoint, 44.4% (4/9) and 16.7% (1/6) remained in remission 48 wk after LCAP.

Clinical characteristics of the patients who entered remission

Table 2 shows how the responders compare to the non-responders 8 wk after LCAP. These two groups did not differ significantly in patient characteristics (i.e., sex, age, duration of disease, pre-CAI levels and pre-CRP levels). However, all first attack and relapse-remitting type patients entered remission while seven of the eight chronic continuous type patients did not ($P < 0.001$). Whether there was total colitis, left-sided colitis, or proctitis was not significantly associated with the ability of the patient to enter remission after LCAP. As indicated above, with regard to the endoscopic findings, all patients with erosions entered remission after LCAP but it was more difficult to induce remission in patients with geographic ulcers or deep ulcers ($P < 0.005$).

Clinical characteristic of the patients who entered remission and then relapsed

Of the 11 patients who entered remission 8 wk after LCAP, six relapsed. Table 3 summarizes the

Table 3 Comparison of the remission and relapse groups 48 wk after the last LCAP session (mean \pm SD)

	Remission (<i>n</i> = 5)	Relapse (<i>n</i> = 6)	<i>P</i>
Patient characteristic			
Male/Female	2/3	5/1	NS
Age (yr)	45.4 ± 13.5	35.0 ± 16.1	NS
Duration of disease (yr)	3.5 ± 3.2	7.6 ± 9.6	NS
Pre-CAI	8.8 ± 1.7	9.1 ± 2.2	NS
Post-CAI	0.6 ± 0.4	1.8 ± 1.0	< 0.05
Pre-CRP	1.0 ± 0.9	1.0 ± 0.8	NS
Post-CRP	0.18 ± 0.14	0.32 ± 0.39	NS
Clinical course			
First attack	3	1	NS
Relapse-remitting	2	4	
Chronic continuous	0	1	
Extent of disease			
Entire	3	5	NS
Left sided	1	1	
Proctitis	1	0	
Endoscopic findings			
Erosions	4	5	NS
Geographic ulcers	1	1	
Deep ulcers	0	0	

CAI: Clinical activity index; CRP: C-reactive protein levels (mg/dL).

characteristics of the five patients who remained in remission 48 wk after LCAP and the six relapsed patients. The two groups only differed significantly in terms of the post-CAI scores ($P < 0.05$). None of the other parameters, namely, the clinical course, extent of disease, or endoscopic findings, correlated with relapse.

Course of the cases who worsened during LCAP

Table 4 summarizes the courses of the three cases with deep ulcers that worsened during LCAP. As a result, two cases were given steroids and one case received cyclosporine. Two patients became infected with cytomegalovirus and received ganciclovir. After a transient improvement, two patients relapsed and underwent surgery. The remaining patient, who developed interstitial pneumonitis, died of aspiration pneumonitis. Aspiration pneumonitis developed 3 mo after LCAP, and therefore the two events were probably unrelated to each other. We think that interstitial pneumonitis was a cause of the development of aspiration pneumonitis.

Adverse effects

None of the patients experienced any severe adverse effects from LCAP. Only one patient reported a mild adverse event (nausea). However, this patient did not suffer from the same problem after subsequent LCAP sessions.

DISCUSSION

When UC patients fail to enter remission after salazosulfapyridine or mesalazine treatment, the conventional second-line therapy involves administration of steroids^[13,14]. However, steroids can cause severe side effects in some patients^[15,16]. When patients with severe

Table 4 Course of cases whose condition worsened during LCAP

	Case 1	Case 2	Case 3
Additional therapy	PSL	PSL	CsA
Complication	-	GCV CMV	GCV CMV
Result	Operation	Operation	Aspiration pneumonitis Dead

PSL: Prednisolone; CsA: Cyclosporine; GCV: Ganciclovir; CMV: Cytomegalovirus.

activity fail to respond to steroids, they must undergo a colectomy, although cyclosporine can sometimes induce remission in these cases^[17-20]. In 1995, Sawada *et al.*^[21] introduced LCAP therapy for patients with UC. This therapy is now a widely used treatment option for UC^[22,23]. LCAP is a method where the blood is passed though a leukocyte removal filter before being returned to the body. On average, 1.6×10^{10} leukocytes are removed during one session. These leukocytes include granulocytes, lymphocytes and monocytes. Almost 100% of granulocytes and monocytes and 60% of lymphocytes are removed by removal filter^[24,25]. It has been reported that 73.3% of steroid-refractory patients with UC enter remission after LCAP^[26]. It is likely that this treatment is effective because it reduces the number of leukocytes available for transmigration and infiltration into the colonic mucosa.

In this study, we found that 61.1% of steroid-naïve UC patients (11/18) had entered remission 8 wk after the last LCAP session. At this time point, the average CAI score had dropped significantly from 9.4 ± 1.9 to 3.8 ± 4.8 ($P = 0.001$) (the three cases who worsened during LCAP were excluded from this calculation). Since steroids can induce remission in 45% to 90% of salazosulfapyridine or mesalazine non-responders^[15,27-29], it appears that LCAP is as efficacious as steroids as a second-line treatment. Given the low rate of adverse events suffered by patients treated with LCAP, we propose that patients with moderately active UC should be treated with LCAP before steroids are considered. It should be noted, however, that 54.5% of the patients in remission (6/11) relapsed 48 wk after the last LCAP session, and that the average duration to relapse was 8.7 mo. Thus, while LCAP is useful for inducing remission in steroid-naïve UC patients, it does not maintain remission.

Analysis of the endoscopic findings of the patients revealed that while all nine patients with erosions had entered remission 8 wk after the last LCAP session, only two of six (33%) and none of three patients with geographic ulcers and deep ulcers, respectively, entered remission. Indeed, the three cases with deep ulcers worsened during LCAP and had to be given steroids (2 cases) or cyclosporine (1 case). Two of these cases became infected with cytomegalovirus and were administered ganciclovir. These observations suggest that patients with geographic ulcers and deep ulcers tend to be refractory to LCAP, particularly the latter. Indeed,

LCAP may not improve the situation for patients with deep ulcers given their higher risk of developing cytomegalovirus infections^[30]. Such patients should perhaps be treated with an intensive therapy such as cyclosporine at a more early stage^[31]. However, since all patients with erosion entered remission 8 wk after LCAP and many (44.4%) remained in remission at the 48-wk time point, LCAP is strongly recommended for patients with erosion.

The post-CAI was the only factor that predicted a relapse. In other words, if the post-CAI could be maintained at < 1 by LCAP, it may be possible to maintain long duration remission.

In conclusion, LCAP is a useful and safe therapy for steroid-naïve UC patients with moderate activity. Moreover, endoscopic findings help to predict the efficacy of this treatment.

COMMENTS

Background

An immune dysfunction is believed to be involved in the development of ulcerative colitis (UC). For a long time, steroids have represented the second line therapy for the induction to remission in UC, if remission cannot be achieved by salazosulfapyridine or mesalazine treatment. However, steroid administration can cause several side effects. Leukocytapheresis (LCAP) have been reported to be effective for steroid-refractory or steroid-dependent patients with UC; however, the data of LCAP for steroid-naïve patient with UC is limited.

Research frontiers

To determine whether LCAP may also be useful in steroid-naïve UC patients, these authors administered LCAP to steroid-naïve UC patients. They also assessed whether the efficacy of LCAP can be predicted on the basis of endoscopic findings.

Innovations and breakthroughs

The authors found that 61.1% of steroid-naïve UC patients (11/18) had entered remission 8 wk after the last LCAP session. Since steroids can induce remission in 45% to 90% of salazosulfapyridine or mesalazine non-responders, it appears that LCAP is as efficacious as steroids as a second-line treatment. Analysis of the endoscopic findings of the patients revealed that the remission rate of the patients with erosion was extremely high after LCAP, compared to the extremely low rate observed in patients with geographic ulcers and deep ulcers. None of the patients experienced any severe adverse effects from LCAP.

Applications

Given the low rate of adverse events suffered by patients treated with LCAP, authors propose that patients with moderately active UC should be treated with LCAP before steroids are considered.

Terminology

LCAP is a treatment procedure where leukocytes are removed through their adherence to fibers in the filter.

Peer review

LCAP is a useful and safe therapy for steroid-naïve UC patients with moderate activity. Moreover, endoscopic findings help to predict the efficacy of this treatment. This is an interesting study.

REFERENCES

- 1 Arai F, Takahashi T, Furukawa K, Matsushima K, Asakura H. Mucosal expression of interleukin-6 and interleukin-8 messenger RNA in ulcerative colitis and in Crohn's disease. *Dig Dis Sci* 1998; **43**: 2071-2079
- 2 Podolsky DK. Inflammatory bowel disease (1). *N Engl J Med* 1991; **325**: 928-937
- 3 Truelove SC, Jewell DP. Intensive intravenous regimen for severe attacks of ulcerative colitis. *Lancet* 1974; **1**: 1067-1070
- 4 Meyers S, Sachar DB, Goldberg JD, Janowitz HD. Corticotropin versus hydrocortisone in the intravenous treatment of ulcerative colitis. A prospective, randomized, double-blind clinical trial. *Gastroenterology* 1983; **85**: 351-357
- 5 Hanauer SB. Inflammatory bowel disease. *N Engl J Med* 1996; **334**: 841-848
- 6 Jarnerot G, Rolny P, Sandberg-Gertzen H. Intensive intravenous treatment of ulcerative colitis. *Gastroenterology* 1985; **89**: 1005-1013
- 7 Naganuma M, Funakoshi S, Sakuraba A, Takagi H, Inoue N, Ogata H, Iwao Y, Ishi H, Hibi T. Granulocytapheresis is useful as an alternative therapy in patients with steroid-refractory or -dependent ulcerative colitis. *Inflamm Bowel Dis* 2004; **10**: 251-257
- 8 Giampaolo B, Giuseppe P, Michele B, Alessandro M, Fabrizio S, Alfonso C. Treatment of active steroid-refractory inflammatory bowel diseases with granulocytapheresis: Our experience with a prospective study. *World J Gastroenterol* 2006; **12**: 2201-2204
- 9 Emmrich J, Petermann S, Nowak D, Beutner I, Brock P, Klingel R, Mausfeld-Lafdihiya P, Liebe S, Ramlow W. Leukocytapheresis (LCAP) in the management of chronic active ulcerative colitis—results of a randomized pilot trial. *Dig Dis Sci* 2007; **52**: 2044-2053
- 10 Domenech E, Hinojosa J, Esteve-Comas M, Gomollon F, Herrera JM, Bastida G, Obrador A, Ruiz R, Saro C, Gassull MA. Granulocytapheresis in steroid-dependent inflammatory bowel disease: a prospective, open, pilot study. *Aliment Pharmacol Ther* 2004; **20**: 1347-1352
- 11 Garland CF, Lilienfeld AM, Mendeloff AI, Markowitz JA, Terrell KB, Garland FC. Incidence rates of ulcerative colitis and Crohn's disease in fifteen areas of the United States. *Gastroenterology* 1981; **81**: 1115-1124
- 12 Lichtiger S, Present DH, Kornbluth A, Gelernt I, Bauer J, Galler G, Michelassi F, Hanauer S. Cyclosporine in severe ulcerative colitis refractory to steroid therapy. *N Engl J Med* 1994; **330**: 1841-1845
- 13 Podolsky DK. Inflammatory bowel disease. *N Engl J Med* 2002; **347**: 417-429
- 14 Kornbluth A, Sachar DB. Ulcerative colitis practice guidelines in adults (update): American College of Gastroenterology, Practice Parameters Committee. *Am J Gastroenterol* 2004; **99**: 1371-1385
- 15 Lennard-Jones JE. Toward optimal use of corticosteroids in ulcerative colitis and Crohn's disease. *Gut* 1983; **24**: 177-181
- 16 Baron JH, Connell AM, Kanaghinis TG, Lennard-Jones JE, Jones AF. Out-patient treatment of ulcerative colitis. Comparison between three doses of oral prednisone. *Br Med J* 1962; **2**: 441-443
- 17 Rowe FA, Walker JH, Karp LC, Vasiliaskas EA, Plevy SE, Targan SR. Factors predictive of response to cyclosporin treatment for severe, steroid-resistant ulcerative colitis. *Am J Gastroenterol* 2000; **95**: 2000-2008
- 18 Stack WA, Long RG, Hawkey CJ. Short- and long-term outcome of patients treated with cyclosporin for severe acute ulcerative colitis. *Aliment Pharmacol Ther* 1998; **12**: 973-978
- 19 Sandborn WJ. A critical review of cyclosporin therapy in inflammatory bowel disease. *Inflamm Bowel Dis* 1995; **1**: 48-63
- 20 Santos J, Baudet S, Casellas F, Guarner L, Vilaseca J, Malagelada JR. Efficacy of intravenous cyclosporine for steroid refractory attacks of ulcerative colitis. *J Clin Gastroenterol* 1995; **20**: 285-289
- 21 Sawada K, Ohnishi K, Fukui S, Yamada K, Yamamura M, Amano K, Amano K, Wada M, Tanida N, Satomi M. Leukocytapheresis therapy, performed with leukocyte removal filter, for inflammatory bowel disease. *J Gastroenterol* 1995; **30**: 322-329
- 22 Sawada K, Shimoyama T. Therapeutic cytappheresis for inflammatory bowel disease. *Ther Apher* 1998; **2**: 90-92
- 23 Sawada K, Muto T, Shimoyama T, Satomi M, Sawada T, Nagawa H, Hiwatashi N, Asakura H, Hibi T. Multicenter

- randomized controlled trial for the treatment of ulcerative colitis with a leukocytapheresis column. *Curr Pharm Des* 2003; **9**: 307-321
- 24 **Shirokaze J**. Leukocytapheresis using a leukocyte removal filter. *Ther Apher* 2002; **6**: 261-266
- 25 **Yamaji K**, Tsuda H, Hashimoto H. Current topics on cytappheresis technologies. *Ther Apher* 2001; **5**: 287-292
- 26 **Kohgo Y**, Hibi H, Chiba T, Shimoyama T, Muto T, Yamamura K, Popovsky MA. Leukocyte apheresis using a centrifugal cell separator in refractory ulcerative colitis: a multicenter open label trial. *Ther Apher* 2002; **6**: 255-260
- 27 **Lennard-Jones JE**, Longmore AJ, Newell AC, Wilson CW, Jones FA. An assessment of prednisone, salazopyrin, and topical hydrocortisone hemisuccinate used as out-patient treatment for ulcerative colitis. *Gut* 1960; **1**: 217-222
- 28 **Powell-Tuck J**, Bown RL, Lennard-Jones JE. A comparison of oral prednisolone given as single or multiple daily doses for active proctocolitis. *Scand J Gastroenterol* 1978; **13**: 833-837
- 29 **Faubion WA Jr**, Loftus EV Jr, Harmsen WS, Zinsmeister AR, Sandborn WJ. The natural history of corticosteroid therapy for inflammatory bowel disease: a population-based study. *Gastroenterology* 2001; **121**: 255-260
- 30 **Nishimoto Y**, Matsumoto T, Suekane H, Shimizu M, Mikami Y, Iida M. Cytomegalovirus infection in a patient with ulcerative colitis: colonoscopic findings. *Gastrointest Endosc* 2001; **53**: 816-818
- 31 **D'Haens G**, Lemmens L, Geboes K, Vandeputte L, Van Acker F, Mortelmans L, Peeters M, Vermeire S, Penninckx F, Nevens F, Hiele M, Rutgeerts P. Intravenous cyclosporine versus intravenous corticosteroids as single therapy for severe attacks of ulcerative colitis. *Gastroenterology* 2001; **120**: 1323-1329

S- Editor Li DL L- Editor Negro F E- Editor Zhang WB