



## CASE REPORT

# A case of Noonan syndrome and Whipple's disease in the same patient

Sundip S Karsan, Hetal A Karsan, Anand S Karsan, James Ian McMillen

Sundip S Karsan, Cedars-Sinai Medical Center, 8700 Beverly Blvd, Room 5512, Los Angeles, California, CA 90048, United States

Hetal A Karsan, Emory University School of Medicine and Atlanta Gastroenterology Associates, Atlanta, GA 30322, United States

Anand S Karsan, University of California, San Diego, CA 92093, United States

James Ian McMillen, Atlanta Clinical Care and Atlanta Specialty Research, Atlanta, GA 30322, United States

**Author contributions:** Karsan SS, Karsan HA, Karsan AS contributed equally to this work and were responsible for the review of the literature and initial preparation of the paper; Karsan SS and Karsan HA wrote the paper and had final approval of the version to be published; McMillen JI contributed to revising it critically for important intellectual content.

**Correspondence to:** Sundip S Karsan, MD, MPH, Cedars-Sinai Medical Center, 8700 Beverly Blvd, Room 5512, Los Angeles, California, CA 90048, United States. [sundip.karsan@csnhs.org](mailto:sundip.karsan@csnhs.org)

Telephone: +1-650-9068387 Fax: +1-650-4946112

Received: December 1, 2008 Revised: February 16, 2009

Accepted: February 23, 2009

Published online: March 28, 2009

of Gastroenterology, Medical School of Lisbon, Av Prof Egas Moniz, 1649-028 Lisbon, Portugal

Karsan SS, Karsan HA, Karsan AS, McMillen JI. A case of Noonan syndrome and Whipple's disease in the same patient. *World J Gastroenterol* 2009; 15(12): 1524-1527 Available from: URL: <http://www.wjgnet.com/1007-9327/15/1524.asp> DOI: <http://dx.doi.org/10.3748/wjg.15.1524>

## INTRODUCTION

We report the first known case of both Noonan syndrome and Whipple's disease (WD) occurring in the same patient. Noonan syndrome is an autosomal dominant genetic disorder that causes abnormal development, originally labeled as the "male Turner syndrome." It affects at least 1 in 2500 male and female children and is thought to be due to a genetic mutation of *PTPN11* gene, first discovered in 2001. Signs and symptoms include webbing of the neck, changes in the sternum (pectus excavatum), facial abnormalities (low-set or abnormally shaped ears, ptosis, hypertelorism, epicanthal folds, antimongoloid palpebral slant, micrognathia), cubitus vulgaris, congenital heart disease (especially pulmonary stenosis, and/or atrial septal defect), and variable hearing loss. Mild mental retardation is present in approximately 25% of cases. WD is a rare systemic infection caused by a non-acid fast gram positive bacillus, *Tropheryma whippelii* (*T. whippelii*). Thus far fewer than 1000 reported cases have been described with an annual incidence of approximately 30 cases per year since 1980. In 1907, Whipple first reported this syndrome in an original case report. Invasion or uptake of the bacillus is widespread throughout the body, including the intestinal epithelium, macrophages, capillary and lymphatic endothelium, colon, liver, brain, heart, lung, synovium, kidney, bone marrow, and skin. Advancement in diagnosis has only recently occurred with the first successful culture of *T. whippelii* in the year 2000; nearly a full century after the disease entity was first described.

## Abstract

We report the first known case of both Noonan syndrome and Whipple's disease occurring in the same patient. A 36-year-old female with history of Noonan syndrome developed fatigue, anorexia, arthritis of the knees and hands with a diffuse hyperpigmented rash, night sweats, and an unintentional fifteen pound weight loss over 4 mo. Small bowel enteroscopy demonstrated mild edematous yellowish mucosa without friability. Random small bowel biopsies revealed extensive periodic acid-Schiff positive material within the foamy macrophages. She was treated with a 12 mo course of trimethoprim-sulfamethoxazole DS with clinical improvement to baseline status.

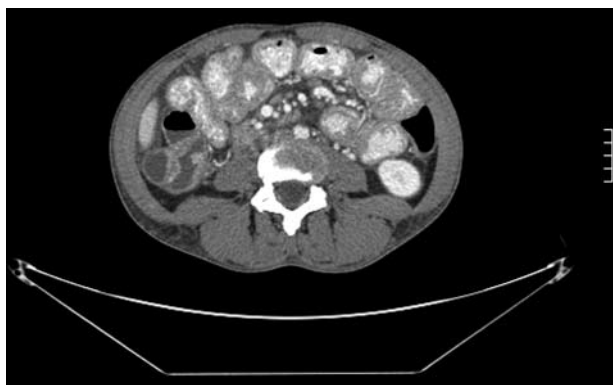© 2009 The WJG Press and Baishideng. All rights reserved.

**Key words:** Whipple's disease; Noonan syndrome; *Tropheryma whippelii*; Periodic acid-schiff stain; *PTPN11* gene

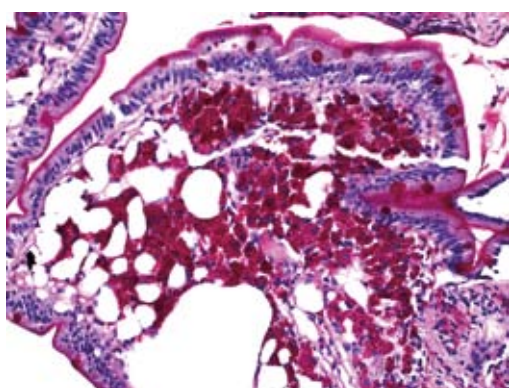
**Peer reviewer:** Miguel C De Moura, Professor, Department

## CASE REPORT

A 36-year-old female with history of Noonan syndrome developed fatigue, anorexia, arthritis of the knees and hands with a diffuse rash, night sweats, and an



**Figure 1** Computerized tomography scan image displaying diffuse lymphadenopathy and small bowel wall thickening.



**Figure 2** A periodic acid-Schiff (PAS) stain showing extensive PAS positive material within the foamy macrophages (small intestinal biopsy).

unintentional fifteen pound weight loss over the past 4 mo. One year prior, she had an endoscopic workup performed for iron deficiency, which was significant for erosive esophagitis. Of note, ileal and duodenal biopsies were histologically normal. Prior to this consultation, she had recently seen a rheumatologist and was placed on prednisone and Plaquenil for arthritis thought to be of rheumatoid origin. She then developed an episode of acute right lower quadrant abdominal pain and an abdominal computerized tomography (CT) scan was ordered. This revealed lymphadenopathy and diffuse thickening of the small bowel (Figure 1). The patient was then referred for gastroenterological consultation at which time her chief complaints were fatigue, arthralgias, and anorexia. She denied abdominal pain, diarrhea, hematochezia, fevers, chills, nausea, or vomiting.

She was 5'2" feet tall and weighed 117 pounds. Physical examination was significant for arthritis of the knees and hands with mild diffuse hyperpigmented skin. Laboratory tests were significant for sedimentation rate of 33, hemoglobin 9.6, and a white blood cell count of 10.4 without a shift. At this time, concern for lymphoma warranted further investigation. Thus, enteroscopy was performed in May 2006. The only significant endoscopic findings were a mild edematous yellowish mucosa without friability in the

distal duodenum and jejunum. Random small bowel biopsies revealed intestinal mucosa in which the lamina propria was markedly expanded due to an infiltrate of histiocytic-appearing cells with foamy cytoplasm and a periodic acid-Schiff (PAS) stain showing extensive PAS positive material within the foamy macrophages; AFB stain was negative (Figure 2). These findings were consistent with a diagnosis of WD. Due to the patient's inability to psychologically tolerate intravenous therapy and an allergy to penicillin, she was placed on an oral regimen of trimethoprim-sulfamethoxazole double-strength twice daily for a 12 mo course.

At follow up in December 2006, she had a remarkable clinical improvement and returned to her baseline clinical status. That is, she had a marked improvement in weight and complete resolution of anemia, arthritis, rash, and bowel wall thickening and lymphadenopathy on CT scan.

## DISCUSSION

We report the first known case of both Noonan syndrome and WD occurring in the same patient. Noonan syndrome is an autosomal dominant genetic disorder that causes abnormal development, originally labeled as the "male Turner syndrome." It affects at least 1 in 2500 male and female children and is thought to be due to a genetic mutation of *PTPN11* gene, first discovered in 2001.

WD is a rare systemic infection caused by a non-acid fast gram positive bacillus, *T. whipplei*. Thus far, fewer than 1000 reported cases have been described<sup>[1]</sup>, with an annual incidence of approximately 30 cases per year since 1980. In postmortem studies, the frequency of the disease is less than 0.1%<sup>[2]</sup>. In 1907 Whipple first reported this syndrome in an original case report<sup>[3]</sup>. The ability to diagnose WD was advanced in 1949 with PAS staining which identified granules within macrophages that likely represented degenerating bacterial forms<sup>[4]</sup>. Invasion or uptake of the bacillus is widespread throughout the body, including the intestinal epithelium, macrophages, capillary and lymphatic endothelium, colon, liver, brain, heart, lung, synovium, kidney, bone marrow, and skin. The chronic, insidious nature of WD may at least be in part due to the long doubling time of 17 d. Advancement in diagnosis has only recently occurred with the first successful culture of *T. whipplei* in the year 2000; nearly a full century after the disease entity was first described. One year later, in 2001, the first phenotypic characterization of the Whipple bacillus occurred, resulting in the renaming of the bacterium to *T. whipplei*<sup>[5]</sup>.

Clinical manifestations include four cardinal findings: arthralgias, weight loss, diarrhea, and abdominal pain. Neurological involvement (dementia, supranuclear ophthalmoplegia, nystagmus, and myoclonus) has been recognized in up to 40% of patients, either as initial manifestations or during the course of the disease. Less common symptoms include fever and skin

hyperpigmentation. There may also be symptoms or signs related to cardiac disease (dyspnea, pericarditis, culture-negative endocarditis), pleuropulmonary disease (pleural effusions) or mucocutaneous disease.

Traditionally, the disease has been described in two stages: a prodromal stage and a much later steady-state stage. The time between these stages varies; however, it typically averages 6 years<sup>[6]</sup>. The prodromal stage is predominantly characterized by nonspecific symptoms including arthralgias and fatigue. More specific findings such as weight loss, diarrhea, and multi organ involvement occur in the steady state stage. Approximately 15% of patients with WD do not present with classic signs and symptoms of the disease; therefore, the diagnosis should be considered in a broad range of clinical scenarios<sup>[7,8]</sup>. Furthermore, immunosuppressed patients can display a more rapid progression of the disease<sup>[9,10]</sup>.

The clinical manifestations of the disease are believed to be caused by infiltration of *T. whipplei* into various tissues. The patient's immune system reacts by incorporating the bacteria into tissue macrophages. Serum studies typically have presented nonspecific findings, therefore biopsy of the appropriate tissue is essential for diagnosis. Tissue samples from the small bowel show expanded villi containing PAS staining macrophages. After the discovery of PAS staining in 1949, the detection of bacteria in macrophages in 1961 further contributed to our understanding of WD<sup>[4,11,12]</sup>. However, the only specific diagnostic tests for WD include determining the presence of *T. whipplei* DNA through molecular amplification of the 16S rRNA of *T. whipplei* by polymerase-chain-reaction (PCR) and cell culture of the organism<sup>[13-15]</sup>. Subsequently, this finding led to electron microscopy, which in turn led to DNA testing for *T. whipplei*. Most recently, in 2003 the full sequencing of two genomes from two different strains of *T. whipplei* has been reported<sup>[6,16,17]</sup>.

In conjunction with clinical signs and symptoms, endoscopy is an important diagnostic modality in WD. Endoscopic examination of the postbulbar region of the duodenum and jejunum includes findings consisting of pale yellow and shaggy mucosa alternating with eroded, erythematous, or mildly friable mucosa<sup>[18]</sup>. Several biopsy samples should be studied because the lesions can be sparse and focal<sup>[6]</sup>.

In the era before routine access to antibiotics, WD was a universally fatal disease. The discovery of antibiotics has resulted in antibiotics as the mainstay of therapy for WD. Treatment regimens are tailored for severity of disease, however, lack of well-controlled trials limits recommendations to reports of experience. The first reported efficacy of antibiotic treatment with chloramphenicol occurred in 1952<sup>[19]</sup>. With the progressive discovery of safer antibiotics, tetracycline at one time was the mainstay of therapy for many years. However, a comprehensive review by Keinath *et al*<sup>[20]</sup> subsequently revealed an overall relapse rate of 35% with

a high CNS relapse rate among patients treated primarily with tetracycline<sup>[21,22]</sup>. As a result, the current standard of therapy includes an initial phase of intravenous antibiotics known to penetrate the blood brain barrier followed by 12 mo of oral maintenance treatment. A typical course often includes ceftriaxone or penicillin for two weeks followed by trimethoprim-sulfamethoxazole double strength twice per day for one year. Depending on allergies to medications, antibiotics can be substituted as needed.

## REFERENCES

- 1 Roberts IM. Whipple disease. Available from: URL: <http://www.emedicine.com/med/topic2409.htm>
- 2 Enzinger FM, Helwig EB. Whipple's disease: a review of the literature and report fifteen patients. *Virchows Arch Pathol Anat Physiol Klin Med* 1963; **336**: 238-269
- 3 Swartz MN. Whipple's disease--past, present, and future. *N Engl J Med* 2000; **342**: 648-650
- 4 Black-Schaffer B. The tinctoral demonstration of a glycoprotein in Whipple's disease. *Proc Soc Exp Biol Med* 1949; **72**: 225-227
- 5 La Scola B, Fenollar F, Fournier PE, Altwegg M, Mallet MN, Raoult D. Description of *Tropheryma whipplei* gen. nov., sp. nov., the Whipple's disease bacillus. *Int J Syst Evol Microbiol* 2001; **51**: 1471-1479
- 6 Fenollar F, Puéchal X, Raoult D. Whipple's disease. *N Engl J Med* 2007; **356**: 55-66
- 7 Misbah SA, Mapstone NP. Whipple's disease revisited. *J Clin Pathol* 2000; **53**: 750-755
- 8 Durand DV, Lecomte C, Cathébras P, Rousset H, Godeau P. Whipple disease. Clinical review of 52 cases. The SNFMI Research Group on Whipple Disease. Société Nationale Française de Médecine Interne. *Medicine (Baltimore)* 1997; **76**: 170-184
- 9 Gerard A, Sarrot-Reynauld F, Liozon E, Cathébras P, Besson G, Robin C, Vighetto A, Mosnier JF, Durieu I, Vital Durand D, Rousset H. Neurologic presentation of Whipple disease: report of 12 cases and review of the literature. *Medicine (Baltimore)* 2002; **81**: 443-457
- 10 Mahnel R, Kalt A, Ring S, Stallmach A, Strober W, Marth T. Immunosuppressive therapy in Whipple's disease patients is associated with the appearance of gastrointestinal manifestations. *Am J Gastroenterol* 2005; **100**: 1167-1173
- 11 Chears WC Jr, Ashworth CT. Electron microscopic study of the intestinal mucosa in Whipple's disease. Demonstration of encapsulated bacilliform bodies in the lesion. *Gastroenterology* 1961; **41**: 129-138
- 12 Yardley JH, Hendrix TR. Combined electron and light microscopy in Whipple's disease. Demonstration of "bacillary bodies" in the intestine. *Bull Johns Hopkins Hosp* 1961; **109**: 80-98
- 13 Wilson KH, Blitchington R, Frothingham R, Wilson JA. Phylogeny of the Whipple's-disease-associated bacterium. *Lancet* 1991; **338**: 474-475
- 14 Relman DA, Schmidt TM, MacDermott RP, Falkow S. Identification of the uncultured bacillus of Whipple's disease. *N Engl J Med* 1992; **327**: 293-301
- 15 Raoult D, Birg ML, La Scola B, Fournier PE, Enea M, Lepidi H, Roux V, Piette JC, Vandenesch F, Vital-Durand D, Marrie TJ. Cultivation of the bacillus of Whipple's disease. *N Engl J Med* 2000; **342**: 620-625
- 16 Bentley SD, Maiwald M, Murphy LD, Pallen MJ, Yeats CA, Dover LG, Norbertczak HT, Besra GS, Quail MA, Harris DE, von Herbay A, Goble A, Rutter S, Squares R, Squares S, Barrell BG, Parkhill J, Relman DA. Sequencing and analysis of the genome of the Whipple's disease bacterium

- Tropheryma whipplei. *Lancet* 2003; **361**: 637-644
- 17 **Raoult D**, Ogata H, Audic S, Robert C, Suhre K, Drancourt M, Claverie JM. Tropheryma whipplei Twist: a human pathogenic Actinobacteria with a reduced genome. *Genome Res* 2003; **13**: 1800-1809
- 18 **Marth T**, Raoult D. Whipple's disease. *Lancet* 2003; **361**: 239-246
- 19 **Paulley JW**. A case of Whipple's disease (intestinal lipodystrophy). *Gastroenterology* 1952; **22**: 128-133
- 20 **Keinath RD**, Merrell DE, Vlietstra R, Dobbins WO 3rd. Antibiotic treatment and relapse in Whipple's disease. Long-term follow-up of 88 patients. *Gastroenterology* 1985; **88**: 1867-1873
- 21 **Durand DV**, Lecomte C, Cathébras P, Rousset H, Godeau P. Whipple disease. Clinical review of 52 cases. The SNFMI Research Group on Whipple Disease. Société Nationale Française de Médecine Interne. *Medicine* (Baltimore) 1997; **76**: 170-184
- 22 **Fleming JL**, Wiesner RH, Shorter RG. Whipple's disease: clinical, biochemical, and histopathologic features and assessment of treatment in 29 patients. *Mayo Clin Proc* 1988; **63**: 539-551

**S- Editor** Tian L **L- Editor** O'Neill M **E- Editor** Zheng XM