



ORIGINAL ARTICLES

Clinical usefulness of ^{18}F -FDG PET/CT in the restaging of esophageal cancer after surgical resection and radiotherapy

Long Sun, Xin-Hui Su, Yong-Song Guan, Wei-Ming Pan, Zuo-Ming Luo, Ji-Hong Wei, Long Zhao, Hua Wu

Long Sun, Xin-Hui Su, Wei-Ming Pan, Zuo-Ming Luo, Ji-Hong Wei, Long Zhao, Hua Wu, Minnan PET Center and Department of Nuclear Medicine, the First Hospital of Xiamen, Fujian Medical University, Xiamen 316003, Fujian Province, China

Yong-Song Guan, State Key Laboratory of Biotherapy, West China Medical School, Sichuan University, Gaopeng Street, Keyuan Road 4, Chengdu 610041, Sichuan Province, China

Author contributions: Sun L wrote the paper and organized the figures and patient data; Su XH, Pan WM, Luo ZM, Zhao L, and Wei JH completed patient follow-ups and data collection; Guan YS helped to write, organize, and correct the paper; Wu H supervised the writing and organization process.

Correspondence to: Hua Wu, Minnan PET Center and Department of Nuclear Medicine, the First Hospital of Xiamen, Fujian Medical University, Xiamen 316003, Fujian Province, China. wuhua1025@163.com

Telephone: +86-592-2139527 Fax: +86-592-2139527

Received: August 25, 2008 Revised: March 7, 2009

Accepted: March 14, 2009

Published online: April 21, 2009

The three false positive PET/CT findings comprised chronic inflammation of mediastinal lymph nodes ($n = 2$) and anastomosis inflammation ($n = 1$). PET/CT demonstrated distant metastasis in 10 patients. ^{18}F -FDG PET/CT imaging-guided salvage treatment in nine patients was performed. Treatment regimens were changed in 12 (60%) patients after introducing ^{18}F -FDG PET/CT into their conventional post-treatment follow-up program.

CONCLUSION: Whole body ^{18}F -FDG PET/CT is effective in detecting relapse of esophageal cancer after surgical resection and radiotherapy. It could also have important clinical impact on the management of esophageal cancer, influencing both clinical restaging and salvage treatment of patients.

© 2009 The WJG Press and Baishideng. All rights reserved.

Key words: ^{18}F -fluorodeoxyglucose; Positron emission tomography/computed tomography; Esophageal cancer; Surgical resection; Radiotherapy radiation; Restaging

Peer reviewer: Dr. Serdar Karakose, Professor, Department of Radiology, Meram Medical Faculty, Selcuk University, Konya 42080, Turkey

Sun L, Su XH, Guan YS, Pan WM, Luo ZM, Wei JH, Zhao L, Wu H. Clinical usefulness of ^{18}F -FDG PET/CT in the restaging of esophageal cancer after surgical resection and radiotherapy. *World J Gastroenterol* 2009; 15(15): 1836-1842 Available from: URL: <http://www.wjgnet.com/1007-9327/15/1836.asp> DOI: <http://dx.doi.org/10.3748/wjg.15.1836>

Abstract

AIM: To evaluate the clinical usefulness of ^{18}F -fluorodeoxyglucose positron emission and computed tomography (^{18}F -FDG PET/CT) in restaging of esophageal cancer after surgical resection and radiotherapy.

METHODS: Between January 2007 and Aug 2008, twenty histopathologically diagnosed esophageal cancer patients underwent 25 PET/CT scans (three patients had two scans and one patient had three scans) for restaging after surgical resection and radiotherapy. The standard reference for tumor recurrence was histopathologic confirmation or clinical follow-up for at least ten months after ^{18}F -FDG PET/CT examinations.

RESULTS: Tumor recurrence was confirmed histopathologically in seven of the 20 patients (35%) and by clinical and radiological follow-up in 13 (65%). ^{18}F -FDG PET/CT was positive in 14 patients (68.4%) and negative in six (31.6%). ^{18}F -FDG PET/CT was true positive in 11 patients, false positive in three and true negative in six. Overall, the accuracy of ^{18}F -FDG PET/CT was 85%, negative predictive value (NPV) was 100%, and positive predictive value (PPV) was 78.6%.

INTRODUCTION

Esophageal cancer is one of the least studied and deadliest cancers worldwide and one of the 10 most prevalent cancers worldwide and has an unfavorable prognosis among digestive tract malignancies^[1,2]. The management of esophageal cancer has evolved from surgery alone to definitive and preoperative chemotherapy-radiation therapy. The best option for curative treatment for patients with esophageal cancer is radical surgery; however, the long-term survival is only 25%^[3]. Postoperative tumor recurrence is not uncommon

in patients undergoing curative resection for esophageal cancer and can be categorized as either locoregional (locoregional lymph node metastases, anastomotic recurrence) or distant (hematogenous metastases, pleural or peritoneal seeding). Lymph node recurrence and hematogenous metastasis to solid organs (commonly to the lung) are the usual patterns of recurrence^[4,5].

¹⁸F-fluorodeoxyglucose positron emission tomography (¹⁸F-FDG PET) and, particularly, ¹⁸F-FDG positron emission and computed tomography (¹⁸F-FDG PET/CT) are widely accepted imaging methods in the management of a wide variety of cancers^[6]. In the initial staging of esophageal cancer, a preoperative PET scan may be useful in detecting additional cases of metastatic disease before costly and toxic definitive therapy^[7]. Currently, ¹⁸F-FDG PET and PET/CT also seem to be the best available tool for neoadjuvant therapy response assessment in esophageal cancer^[8,9]. However, the utility and limitation of ¹⁸F-FDG PET/CT in patients with esophageal cancer treated by surgical resection and post operation radiation is not clear. In this study, we aimed to analyze the value of ¹⁸F-FDG PET/CT scans in the follow up of patients with esophageal cancer treated with combined surgical treatment and radiotherapy management.

MATERIALS AND METHODS

Patients

A retrospective review of our electronic database of 20 patients with esophageal cancer after surgical resection and following radiotherapy (15 males and 5 female; age range, 39-68 years; mean age, 55.1 years) imaged by ¹⁸F-FDG PET/CT between January 2007 and Aug 2008 was performed to select and analyze ¹⁸F-FDG PET/CT scans findings of patients with or without clinically and/or radiologically suspicious findings for restaging. Twenty patients had undergone 25 PET/CT scans (three patients had two scans and one patient had three scans). The standard reference for tumor recurrence consisted of histopathological confirmation or clinical follow-up for at least ten months after ¹⁸F-FDG PET/CT.

¹⁸F-FDG PET/CT technique

The patients were asked to fast for at least 4 h before undergoing ¹⁸F-FDG PET/CT. Their blood glucose levels were within the normal range (70-120 mg/dL) prior to intravenous injection of ¹⁸F-FDG. The patients received an intravenous injection of 370-666 MBq (10-18 mCi) of ¹⁸F-FDG. Data acquisition by an integrated PET/CT system (Discovery STE; GE Medical Systems, Milwaukee, WI, USA) was performed within 60 min after injection. The procedure for data acquisition was as follows: CT scanning was performed first, from the head to the pelvic floor, with 110 kV, 110 mA, a tube rotation time of 0.5 s, a 3.3-mm section thickness, which was matched to the PET section thickness. Immediately after CT scanning, a PET emission scan that covered the identical transverse field of view was obtained. Acquisition time was three minutes per table position. PET image data sets were reconstructed iteratively by

Table 1 Patient characteristics

Clinical characteristics	Data
Mean age (yr)	55.1 (39-68)
Gender	
Males	15
Females	5
Mean time after treatment to PET/CT exam	1 mo-5 yr; mean 20 mo
Mean follow-up time after PET/CT exam	1 mo-18 mo; mean 11 mo

applying the CT data for attenuation correction, and coregistered images were displayed on a workstation.

Definitive diagnoses of positive and negative findings

Reviewer 1 and reviewer 2, who were aware of other clinical or imaging information, read the ¹⁸F-FDG PET/CT images on a high-resolution computer screen. The reviewers reached a consensus in cases of discrepancy. Reviewer 1 had 20 years of experience in both nuclear medicine and radiology, and reviewer 2 had 5 years of experience in both nuclear medicine and radiology. On the basis of knowledge of the normal biodistribution of FDG, lesions were identified as foci with increased tracer accumulation relative to that in comparable normal contralateral structures and surrounding soft tissues. The lesions were qualitatively graded as definitely or probably abnormal (i.e. representing tumors) if the accumulation of FDG was markedly to moderately increased. Diffuse mildly increased activity or no increased activity (in the case of an abnormality identified on CT for which no corresponding abnormality was present on PET) was considered normal or as benign disease. Quantification of the tumor metabolic activity was obtained using the Standardized Uptake Value (SUV) normalized to body weight. mean \pm SD of maximum-pixel SUV (SUVmax) of the lesions were calculated.

RESULTS

The characteristics of the patients are summarized in Table 1. For suspected recurrent esophageal cancer, the mean patient age was 55.1 years with a tendency of male gender distribution (75%). ¹⁸F-FDG PET/CT was positive in 14 patients (68.4%) and negative in six (31.6%). When correlated with final diagnosis, which was confirmed by histopathological evidence of tumor recurrence in seven of the 20 patients (35%) and by clinical and radiological follow-up in 13 (65%), ¹⁸F-FDG PET/CT was true positive in 11 patients (Table 2, Figures 1 and 2), false positive in three and true negative in six. The three false positive PET/CT findings were chronic inflammation of mediastinal lymph nodes ($n = 2$) and anastomosis inflammation ($n = 1$) (Figure 3), which were confirmed by at least 11 mo of clinical and radiological follow-up. There were no false negatives in our group. Overall, the accuracy of ¹⁸F-FDG PET/CT was 85%, negative predictive value (NPV) was 100%, and positive predictive value (PPV) was 78.6%.

Notably, ¹⁸F-FDG PET/CT demonstrated true positive distant metastasis in 90.9% (10/11) patients.

Table 2 PET/CT findings in 11 patients with true positive PET/CT scans

No.	PET/CT findings	SUV max	Further treatment plan	Interval time
1	Retroperitoneal lymph nodes	4.5	Surgical resection of metastases	5 yr
2	Retroperitoneal lymph nodes	6.5	Local radiotherapy	1yr
	Lung metastasis	1.6	Chemotherapy	
3	Mediastinal lymph nodes	5.2	Chemotherapy	13 mo
4	Supraclavicular lymph nodes	3.3	Local radiotherapy	11 mo
5	Retroperitoneal lymph nodes	6.0	Local radiotherapy	2 mo
6	Supraclavicular lymph nodes	8.4	Chemotherapy	11 mo
	Retroperitoneal lymph nodes	3.6		
	Liver metastasis	10.6	RF-ablation	
7	Retroperitoneal lymph nodes	12.1	Chemotherapy	14 mo
	Liver metastasis	14.0	RF-ablation	
8	Liver metastasis	8.4	RF-ablation	16 mo
	Supraclavicular lymph nodes	3.6	Chemotherapy	
	Retroperitoneal lymph nodes	10.6		
9	Supraclavicular lymph nodes	3.2	Local radiotherapy	1 mo
10	Supraclavicular lymph nodes	6.7		1 mo
	Osseous metastasis	5.3		
	Peritoneal carcinomatosis	7.9		
11	Anastomosis recurrence	7.1	Stent implant	5 mo
	Retroperitoneal lymph nodes	8.5	Chemotherapy	

RF-ablation: Radiofrequency-ablation.

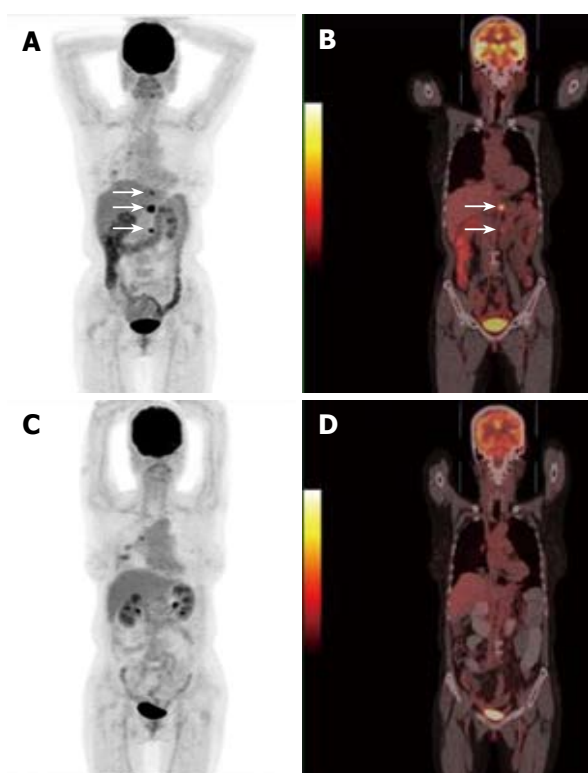


Figure 1 A 56-year-old woman who had esophageal cancer resection 5 years ago. PET/CT displayed multi-retroperitoneal lymph node recurrence (arrows in A and B). The patient accepted retroperitoneal lymph node resection, which was later verified as esophageal cancer metastasis by histopathology. PET/CT Follow-up 10 mo after her second operation demonstrated no new recurrent lesions (C, D).

Except for 45.5% (5/11) patients who suffered from supraclavicular lymph nodes metastasis, the remaining 54.5% (6/11) patients were asymptomatic, with no evidence of relapse disease. These remaining patients underwent further PET/CT scans as part of routine post-operative surveillance. ^{18}F -FDG PET/CT imaging-guided salvage treatment (surgical resections of

metastasis lesions, additional radiotherapy, chemotherapy, and radiofrequency ablation of hepatic metastatic tumors) in 10 patients was performed within two weeks after the ^{18}F -FDG PET/CT scan. Clinical decisions of treatment were changed in 12 (60%) patients after introducing ^{18}F -FDG PET/CT into their conventional post-treatment follow-up program.

In our study, 90.9% (10/11) cases of recurrence after curative resection occurred within 16 mo and 9.1% (1/11) occurred within 5 years, respectively, after the initial resection. A high percentage of first failures presented as supraclavicular lymph nodes and retroperitoneal lymph nodes metastases.

DISCUSSION

Surgery is still the main treatment option for esophageal cancer; however, long-term survival has remained poor, even when a curative operation is performed^[10]. Despite increasingly extended radical esophagectomy for esophageal cancer, many patients continue to experience relapse of the disease^[11]. About one half of the patients develop recurrent disease within three years after the operation, and most of them develop mediastinal lymph node, liver, bone, or lung metastasis^[12]. Anastomotic recurrence is a major reason of late mortality following esophago-gastrectomy for carcinoma of the esophagus and esophago-gastric junction, using either the Ivor Lewis approach with intra-thoracic anastomosis^[13]. However, neoplastic recurrence was most common at the supraclavicular lymph nodes and retroperitoneal lymph nodes (81.8%; 9/11); only one patient suffered from mediastinal lymph nodes recurrence and one patient suffered from anastomotic recurrence in our study results. Cooper *et al*^[14] reported that concurrent postoperative chemotherapy and radiotherapy significantly improved the rates of local and regional

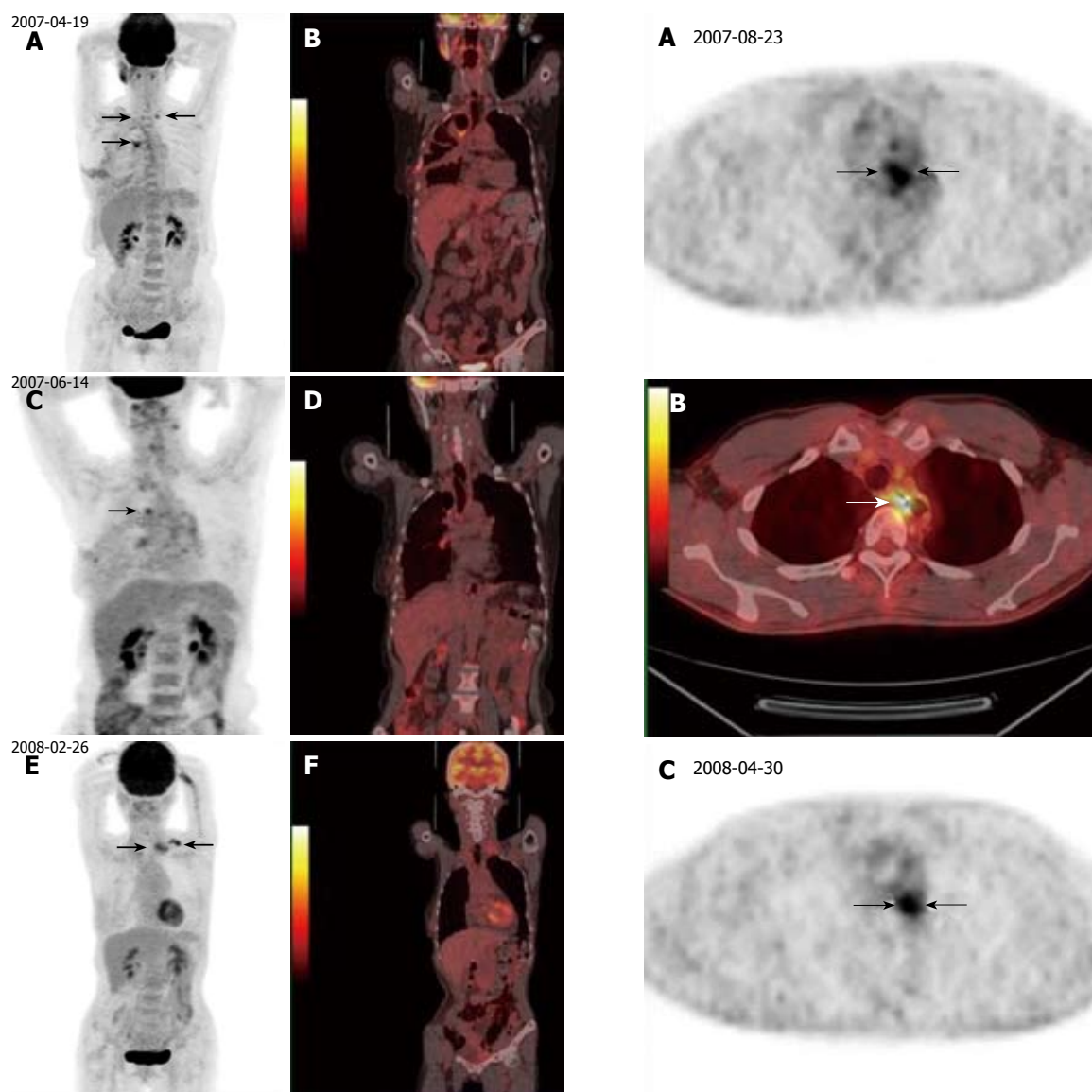


Figure 2 A 62-year-old woman had esophageal cancer resection. She underwent three PET/CT scans (1.5, 4.5 and 11 mo after treatment, respectively) as part of routine post-operative surveillance. The first PET/CT imaging (1.5 mo) revealed hypermetabolic activity in the anastomosis and supraclavicular lymph nodes (arrows, A, B). The second PET/CT imaging (4.5 mo) showed decreasing of hypermetabolic activity at anastomosis and supraclavicular lymph nodes (arrows, C, D). The third PET/CT imaging (11 mo) showed no abnormal FDG uptake at anastomosis, but revealed new focal hypermetabolic activity at left supraclavicular lymph nodes (arrows, E, F). Inflammation of lymph nodes and anastomosis at the first and second PET/CT scan were confirmed by the third PET/CT examination. New relapse at the left supraclavicular lymph nodes was later verified by biopsy.

control and disease-free survival among high-risk patients with resected head and neck cancer. All of our patients accepted postoperative radiotherapy, which may be beneficial in the control of mediastinum recurrence.

It was reported that PET/CT using the radiolabeled glucose analog, ^{18}F -FDG, was valuable in detecting recurrence of esophageal cancer, particularly when anatomic imaging modalities have presented equivocal interpretations^[15]. ^{18}F -FDG PET/CT is a metabolic imaging technique where the scope covers the whole body (from the skull to the lower limbs). Major advantages

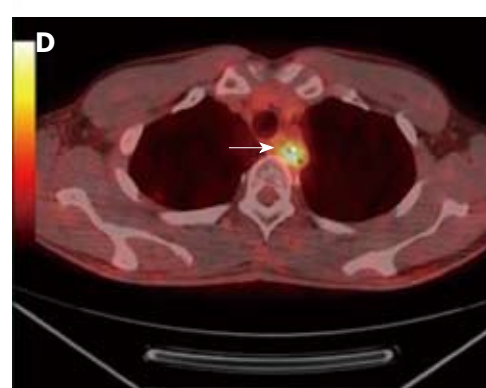


Figure 3 A 40-year-old asymptomatic man who had esophageal cancer resection 30 mo ago underwent PET/CT as part of routine post-operative surveillance. The first PET/CT revealed hypermetabolic activity at the anastomosis (arrows, A, B) 5 mo after treatment. The second PET/CT showed hypermetabolic activity at the anastomosis (arrows, C, D) 30 mo after treatment. The final diagnosis by endoscopic biopsy was anastomotic inflammation.

of ^{18}F -FDG PET/CT are the ability to perform full body examinations, the potential to detect locoregionally recurrence and distant metastatic lesions in one single examination, and the possibility of distinguishing new

active disease from scar or necrotic tissue^[16,17]. However, conventional CT and magnetic resonance imaging (MRI) examinations only cover local regions of the body. The current study is the first that specifically focused on the utility of ¹⁸F-FDG PET/CT imaging for whole body diagnosis and staging of recurrent esophageal cancer after curative resection and postoperative radiotherapy. Our preliminary results suggest that ¹⁸F-FDG PET/CT provides a highly sensitive diagnosis of recurrent disease, both for locoregionally recurrence and distant metastasis.

Whether earlier diagnosis of recurrent esophageal cancer would improve patient survival has not yet been reported^[18,19]. The possibility of a survival benefit, however, can be deduced indirectly from results obtained in our previous study with early detection of recurrence in asymptomatic post-operation patients with gastric cancer, indicating a survival benefit of nine months^[20]. The available therapeutic modalities in recurrent esophageal cancer are radical re-resection, palliative resection and bypass, laser thermocoagulation, stenting, chemotherapy, brachytherapy, and radiotherapy, alone or in combination^[21,22]. The choice of a specific therapeutic modality depends on the extent of the recurrence. Patients with metastatic esophageal cancer have a median survival time of six months^[23,24]. However, one patient who suffered from retroperitoneal lymph node recurrence around the pancreas accepted retroperitoneal lymph node resection and partial excision of the pancreas. The patient remained in a good condition over a 10-mo follow-up period.

The prognosis of patients with post-operative loco-regional recurrence of esophageal cancer is poor. However, long-term survival might be expected by definitive radiotherapy for the patients with small-size tumors and with a good performance status^[25]. Raoul *et al*^[26] reported the survival rates of patients with postoperative recurrence treated with chemoradiotherapy to be 47.1% at one year, 17.1% at two years and 4.3% at three years. Although the average follow-up time of this group of patients is only 11 mo, our study results of nine patients also indicated that ¹⁸F-FDG PET/CT-guided salvage therapy and earlier diagnosis of recurrent esophageal cancer might improve patient survival. PET/CT also has advantages in individualized treatment for patients. Morphological imaging with CT or MRI after radiofrequency ablation of malignant liver tumors is hampered by rim-like enhancement in the ablation margin, making the identification of residual or local recurrent tumors in the ablation zone difficult^[27,28]. In our study, three patients with hepatic metastatic tumors from esophageal cancer accepted radiofrequency-ablation of metastatic lesions. ¹⁸F-FDG PET/CT proved to be more accurate in morphological imaging with CT or MRI when making radiofrequency-ablation plans and assessing the liver for residual tumors after radiofrequency-ablation.

A noteworthy finding in the current study is the high incidence [21.4%; (3/14)] of false-positive ¹⁸F-FDG PET/CT findings at the mediastinal lymph nodes ($n = 2$) and anastomotic inflammation ($n = 1$). False-

positive FDG uptake at inflammatory lesions is widely known and remains a major problem in the diagnosis of oncologic patients^[29,30]. Three other patients had high-moderate uptake at the mediastinal lymph nodes. The FDG uptake in the three patients probably reflected a normal inflammatory healing process after operation and radiation. In our experience, the presence of the stomach in the thoracic cavity after the operation induces focal atelectasis and lung inflammation in many of patients after treatment, which might be also contribute to the increasing FDG uptake in mediastinal lymph nodes.

PET scans for response assessment should also be timed correctly^[31,32]. Treatment with surgical resection and radiation often results in temporary inflammatory changes that may show up positive on a PET/CT scan when there is no real disease. These changes take some time to subside^[33,34]. In our experience, it is recommended that PET/CT scans be performed only after at least two weeks of chemotherapy and five-six weeks of radiation for the true picture to emerge. Thus, the sophisticated surgical procedures used in esophagectomy and radiation treatment after operation can result in anatomical and functional changes. Clinicians at PET/CT centers must understand how these procedures can affect imaging data and be familiar with the appearances of postoperative anatomical changes, complications, and tumor recurrence, to ensure accurate evaluation of affected patients.

In conclusion, ¹⁸F-FDG PET/CT has the potential to be a highly sensitive diagnostic tool for accurate whole-body staging of asymptomatic and symptomatic recurrent esophageal cancer. ¹⁸F-FDG PET/CT-guided salvage treatment to the early recurrent lesion might improve patient survival in a considerable proportion of patients. Due to the false-positive findings based on ¹⁸F-FDG accumulation in areas of inflammation, interpretation of ¹⁸F-FDG PET/CT results is optimized by understanding the diagnostic limitations and pitfalls that may be encountered, together with knowledge of the natural history of esophageal cancer and the staging and treatment options available.

COMMENTS

Background

The incidence of esophageal cancer has steadily increased over the past three decades. The best option for curative treatment for patients with esophageal cancer is radical surgery, with a long-term survival of only 25%. Postoperative tumor recurrence is not uncommon in patients undergoing curative resection for esophageal cancer. The outcome of esophagectomy could be improved by optimal diagnostic strategies leading to adequate guided salvage treatment. In this study, we aimed to analyze the value of ¹⁸F-fluorodeoxyglucose positron emission and computed tomography (¹⁸F-FDG PET/CT) scans in the follow up of patients with esophageal cancer treated with combined surgical treatment and radiotherapy management.

Research frontiers

¹⁸F-FDG PET and, particularly, ¹⁸F-FDG PET/CT are widely accepted imaging methods in the management of a wide variety of cancers. However, the utility and limitation of ¹⁸F-FDG PET/CT in patients with esophageal cancer treated by surgical resection and post operation radiation is not clear.

Innovations and breakthroughs

Whole body ¹⁸F-FDG PET/CT was effective in detecting relapse in esophageal

cancer after surgical resection and radiotherapy and also had important clinical impacts on the management of esophageal cancer; influencing both clinical restaging and salvage treatment of patients.

Applications

This has the potential to be a powerful technology for restaging of esophageal cancer after surgical resection and radiotherapy.

Peer review

This manuscript can be presented as an initial report and is an interesting article about the application of PET-CT to restaging of esophageal cancer after surgical resection and radiotherapy.

REFERENCES

- Jemal A, Siegel R, Ward E, Murray T, Xu J, Thun MJ. Cancer statistics, 2007. *CA Cancer J Clin* 2007; **57**: 43-66
- Enzinger PC, Mayer RJ. Esophageal cancer. *N Engl J Med* 2003; **349**: 2241-2252
- Westerterp M, van Westreenen HL, Reitsma JB, Hoekstra OS, Stoker J, Fockens P, Jager PL, Van Eck-Smit BL, Plukker JT, van Lanschot JJ, Sloof GW. Esophageal cancer: CT, endoscopic US, and FDG PET for assessment of response to neoadjuvant therapy--systematic review. *Radiology* 2005; **236**: 841-851
- Kim TJ, Lee KH, Kim YH, Sung SW, Jheon S, Cho SK, Lee KW. Postoperative imaging of esophageal cancer: what chest radiologists need to know. *Radiographics* 2007; **27**: 409-429
- Lee SJ, Lee KS, Yim YJ, Kim TS, Shim YM, Kim K. Recurrence of squamous cell carcinoma of the oesophagus after curative surgery: rates and patterns on imaging studies correlated with tumour location and pathological stage. *Clin Radiol* 2005; **60**: 547-554
- Antoch G, Kanja J, Bauer S, Kuehl H, Renzing-Koehler K, Schuette J, Bockisch A, Debatin JF, Freudenberg LS. Comparison of PET, CT, and dual-modality PET/CT imaging for monitoring of imatinib (STI571) therapy in patients with gastrointestinal stromal tumors. *J Nucl Med* 2004; **45**: 357-365
- Flamen P, Lerut A, Van Cutsem E, De Wever W, Peeters M, Stroobants S, Dupont P, Bormans G, Hiele M, De Leyn P, Van Raemdonck D, Coosemans W, Ectors N, Haustermans K, Mortelmans L. Utility of positron emission tomography for the staging of patients with potentially operable esophageal carcinoma. *J Clin Oncol* 2000; **18**: 3202-3210
- Levine EA, Farmer MR, Clark P, Mishra G, Ho C, Geisinger KR, Melin SA, Lovato J, Oaks T, Blackstock AW. Predictive value of 18-fluoro-deoxy-glucose-positron emission tomography (18F-FDG-PET) in the identification of responders to chemoradiation therapy for the treatment of locally advanced esophageal cancer. *Ann Surg* 2006; **243**: 472-478
- Swisher SG, Maish M, Erasmus JJ, Correa AM, Ajani JA, Bresalier R, Komaki R, Macapinlac H, Munden RF, Putnam JB, Rice D, Smythe WR, Vaporciyan AA, Walsh GL, Wu TT, Roth JA. Utility of PET, CT, and EUS to identify pathologic responders in esophageal cancer. *Ann Thorac Surg* 2004; **78**: 1152-1160; discussion 1152-1160
- Dresner SM, Griffin SM. Pattern of recurrence following radical oesophagectomy with two-field lymphadenectomy. *Br J Surg* 2000; **87**: 1426-1433
- Osugi H, Takemura M, Higashino M, Takada N, Lee S, Ueno M, Tanaka Y, Fukuhara K, Hashimoto Y, Fujiwara Y, Kinoshita H. Causes of death and pattern of recurrence after esophagectomy and extended lymphadenectomy for squamous cell carcinoma of the thoracic esophagus. *Oncol Rep* 2003; **10**: 81-87
- Nakagawa S, Kanda T, Kosugi S, Ohashi M, Suzuki T, Hatakeyama K. Recurrence pattern of squamous cell carcinoma of the thoracic esophagus after extended radical esophagectomy with three-field lymphadenectomy. *J Am Coll Surg* 2004; **198**: 205-211
- Chen G, Wang Z, Liu XY, Liu FY. Recurrence pattern of squamous cell carcinoma in the middle thoracic esophagus after modified Ivor-Lewis esophagectomy. *World J Surg* 2007; **31**: 1107-1114
- Cooper JS, Pajak TF, Forastiere AA, Jacobs J, Campbell BH, Saxman SB, Kish JA, Kim HE, Cmelak AJ, Rotman M, Machtay M, Ensley JF, Chao KS, Schultz CJ, Lee N, Fu KK. Postoperative concurrent radiotherapy and chemotherapy for high-risk squamous-cell carcinoma of the head and neck. *N Engl J Med* 2004; **350**: 1937-1944
- Guo H, Zhu H, Xi Y, Zhang B, Li L, Huang Y, Zhang J, Fu Z, Yang G, Yuan S, Yu J. Diagnostic and prognostic value of 18F-FDG PET/CT for patients with suspected recurrence from squamous cell carcinoma of the esophagus. *J Nucl Med* 2007; **48**: 1251-1258
- Fletcher JW, Djulbegovic B, Soares HP, Siegel BA, Lowe VJ, Lyman GH, Coleman RE, Wahl R, Paschold JC, Avril N, Einhorn LH, Suh WW, Samson D, Delbeke D, Gorman M, Shields AF. Recommendations on the use of 18F-FDG PET in oncology. *J Nucl Med* 2008; **49**: 480-508
- Facey K, Bradbury I, Laking G, Payne E. Overview of the clinical effectiveness of positron emission tomography imaging in selected cancers. *Health Technol Assess* 2007; **11**: iii-iv, xi-267
- Flamen P, Lerut A, Van Cutsem E, Cambier JP, Maes A, De Wever W, Peeters M, De Leyn P, Van Raemdonck D, Mortelmans L. The utility of positron emission tomography for the diagnosis and staging of recurrent esophageal cancer. *J Thorac Cardiovasc Surg* 2000; **120**: 1085-1092
- Tahara M, Ohtsu A, Hironaka S, Boku N, Ishikura S, Miyata Y, Ogino T, Yoshida S. Clinical impact of criteria for complete response (CR) of primary site to treatment of esophageal cancer. *Jpn J Clin Oncol* 2005; **35**: 316-323
- Sun L, Su XH, Guan YS, Pan WM, Luo ZM, Wei JH, Wu H. Clinical role of 18F-fluorodeoxyglucose positron emission tomography/computed tomography in post-operative follow up of gastric cancer: initial results. *World J Gastroenterol* 2008; **14**: 4627-4632
- Motoyama S, Saito R, Okuyama M, Maruyama K, Nanjo H, Ogawa J. Long-term survival after salvage resection of recurrent esophageal cancer with anterior mediastinal lymph node involvement: report of a case. *Surg Today* 2006; **36**: 827-830
- Shigemitsu K, Naomoto Y, Shirakawa Y, Haisa M, Gunduz M, Tanaka N. A case of advanced esophageal cancer with extensive lymph node metastases successfully treated with multimodal therapy. *Jpn J Clin Oncol* 2002; **32**: 310-314
- Chen G, Wang Z, Liu XY, Zhang MY, Liu FY. Clinical study of modified Ivor-Lewis esophagectomy plus adjuvant radiotherapy for local control of stage IIA squamous cell carcinoma in the mid-thoracic esophagus. *Eur J Cardiothorac Surg* 2009; **35**: 1-7
- Albertsson M. Chemoradiotherapy of esophageal cancer. *Acta Oncol* 2002; **41**: 118-123
- Shioyama Y, Nakamura K, Ohga S, Nomoto S, Sasaki T, Yamaguchi T, Toba T, Yoshitake T, Terashima H, Honda H. Radiation therapy for recurrent esophageal cancer after surgery: clinical results and prognostic factors. *Jpn J Clin Oncol* 2007; **37**: 918-923
- Raoul JL, Le Pris   E, Meunier B, Julienne V, Etienne PL, Gosselin M, Launois B. Combined radiochemotherapy for postoperative recurrence of oesophageal cancer. *Gut* 1995; **37**: 174-176
- Tachibana M, Yoshimura H, Kinugasa S, Shibakita M, Dhar DK, Ueda S, Fujii T, Nagasue N. Postoperative chemotherapy vs chemoradiotherapy for thoracic esophageal cancer: a prospective randomized clinical trial. *Eur J Surg Oncol* 2003; **29**: 580-587
- Kuehl H, Antoch G, Stergar H, Veit-Haibach P, Rosenbaum-Krumme S, Vogt F, Frilling A, Barkhausen J, Bockisch A. Comparison of FDG-PET, PET/CT and MRI for follow-up of colorectal liver metastases treated with radiofrequency

- ablation: initial results. *Eur J Radiol* 2008; **67**: 362-371
- 29 **Travaini LL**, Trifirò G, Ravasi L, Monfardini L, Della Vigna P, Bonomo G, Chiappa A, Mallia A, Ferrari M, Orsi F, Paganelli G. Role of [18F]FDG-PET/CT after radiofrequency ablation of liver metastases: preliminary results. *Eur J Nucl Med Mol Imaging* 2008; **35**: 1316-1322
- 30 **Kato H**, Miyazaki T, Nakajima M, Fukuchi M, Manda R, Kuwano H. Value of positron emission tomography in the diagnosis of recurrent oesophageal carcinoma. *Br J Surg* 2004; **91**: 1004-1009
- 31 **Lerut T**, Flamen P, Ectors N, Van Cutsem E, Peeters M, Hiele M, De Wever W, Coosemans W, Decker G, De Leyn P, Deneffe G, Van Raemdonck D, Mortelmans L. Histopathologic validation of lymph node staging with FDG-PET scan in cancer of the esophagus and gastroesophageal junction: A prospective study based on primary surgery with extensive lymphadenectomy. *Ann Surg* 2000; **232**: 743-752
- 32 **Brücher BL**, Weber W, Bauer M, Fink U, Avril N, Stein HJ, Werner M, Zimmerman F, Siewert JR, Schwaiger M. Neoadjuvant therapy of esophageal squamous cell carcinoma: response evaluation by positron emission tomography. *Ann Surg* 2001; **233**: 300-309
- 33 **Swisher SG**, Erasmus J, Maish M, Correa AM, Macapinlac H, Ajani JA, Cox JD, Komaki RR, Hong D, Lee HK, Putnam JB Jr, Rice DC, Smythe WR, Thai L, Vaporciyan AA, Walsh GL, Wu TT, Roth JA. 2-Fluoro-2-deoxy-D-glucose positron emission tomography imaging is predictive of pathologic response and survival after preoperative chemoradiation in patients with esophageal carcinoma. *Cancer* 2004; **101**: 1776-1785
- 34 **Roedl JB**, Halpern EF, Colen RR, Sahani DV, Fischman AJ, Blake MA. Metabolic tumor width parameters as determined on PET/CT predict disease-free survival and treatment response in squamous cell carcinoma of the esophagus. *Mol Imaging Biol* 2009; **11**: 54-60

S- Editor Tian L **L- Editor** Stewart GJ **E- Editor** Yin DH