



CASE REPORT

Post-gastrectomy acute pancreatitis in a patient with gastric carcinoma and pancreas divisum

I-Ming Kuo, Frank Wang, Keng-Hao Liu, Yi-Yin Jan

I-Ming Kuo, Frank Wang, Keng-Hao Liu, Yi-Yin Jan, Department of Surgery, Chang Gung Memorial Hospital, Chang Gung University, Linkou, Taiwan, China

Author contributions: Kuo IM contributed to manuscript preparation, manuscript editing and was the primary writer of the manuscript; Wang F revised the manuscript; Liu KH contributed to data collection and manuscript review; Jan YY reviewed the manuscript.

Correspondence to: Dr. Keng-Hao Liu, Department of Surgery, Chang Gung Memorial Hospital, 5, Fu-Shin Street, Kweishan, Taoyuan, Taiwan, China. kenghao@adm.cgmh.org.tw

Telephone: +886-3-3281200 Fax: +886-3-3285818

Received: July 11, 2009 Revised: August 6, 2009

Accepted: August 13, 2009

Published online: September 28, 2009

Abstract

Gastrectomy is commonly performed for both benign and malignant lesions. Although the incidence of post-gastrectomy acute pancreatitis (PGAP) is low compared to other well-recognized post-operative complications, it has been reported to be associated with a high mortality rate. In this article, we describe a 70-year-old man with asymptomatic pancreatic divisum who underwent palliative subtotal gastrectomy for an advanced gastric cancer with liver metastasis. His post-operative course was complicated by acute pancreatitis and intra-abdominal sepsis. The patient eventually succumbed to multiple organ failure despite surgical debridement and drainage, together with aggressive antibiotic therapy and nutritional support. For patients with pancreas divisum or dominant duct of Santorini who fail to follow the normal post-operative course after gastrectomy, clinicians should be alert to the possibility of PGAP as one of the potential diagnoses. Early detection and aggressive treatment of PGAP might improve the prognosis.

© 2009 The WJG Press and Baishideng. All rights reserved.

Key words: Acute Pancreatitis; Gastrectomy; Pancreas divisum; Duct of Santorini; Laparoscopy

Peer reviewers: Jose Sahel, Professor, Hepato-gastroenterology, Hospital sainti Marevenite, 1270 Boolevard AE Sainti Margrenise, Marseille 13009, France; Chikashi Shibata, Department of Surgery, Tohoku University, 1-1 Seiryomachi, Aoba-ku, Japan

Kuo IM, Wang F, Liu KH, Jan YY. Post-gastrectomy acute pancreatitis in a patient with gastric carcinoma and pancreas divisum. *World J Gastroenterol* 2009; 15(36): 4596-4600 Available from: URL: <http://www.wjgnet.com/1007-9327/15/4596.asp> DOI: <http://dx.doi.org/10.3748/wjg.15.4596>

INTRODUCTION

Although gastrectomies for lesions of the stomach and duodenum have been performed safely for more than one hundred years, major complications such as anastomosis leakage, duodenal stump leakage and post-operative bleeding cannot be completely avoided even by experienced surgeons. In the past, most gastrectomies were performed for benign gastric or duodenal ulcer. One of the complications associated with these procedures was post-gastrectomy acute pancreatitis (PGAP). The pathogenesis of this condition is hypothesized to be related to pancreatic parenchymal injury secondary to severe adhesion of peripancreatic tissue, compromised pancreatic micro-circulation, hyperpressure of the duodenum, and edema or spasm of the major papilla^[1,2]. The incidence of PGAP has decreased in recent years, coinciding with the dramatic reduction in the need for surgical intervention of complicated peptic ulcer disease in the advent of improved medical and endoscopic management. Gastrectomies nowadays are performed mainly for patients with gastric malignancy. The "pancreatitis-like" presentation is mostly seen in patients with afferent loop obstruction after gastrectomies, mostly following Billroth II reconstruction. The true PGAP might be related to the extended lymph node dissection and resection of adjacent organs (such as splenectomy and distal pancreatectomy) in radical gastrectomies for gastric cancer^[3-5]. However, the correlation between pancreatic anomalies and PGAP has not been well documented in the literature. This article, therefore, reports a patient with concurrent advanced gastric cancer and pancreas divisum (PD) who had PGAP and died from multiple organ failure post-operatively.

CASE REPORT

A 70-year-old gentleman with a medical background of hypertension and asthma, presented with a 3 mo history

of poor appetite, 10 kg weight loss, postprandial fullness and nausea. There was, however, no history of tarry stool, hematemesis, fever or abdominal pain. The physical examination did not reveal any palpable abdominal mass, lymphadenopathy, anemia, or jaundice. All laboratory data, including biochemistry examination and hemogram, were within normal ranges except for a low hemoglobin level (10.3 g/dL). Esophagogastroduodenoscopy (EGD) was performed and one ulcerative mass over the posterior wall of antrum was identified (Figure 1). The histopathological examination of the biopsy of the gastric lesion confirmed that it was an adenocarcinoma. Dynamic CT was arranged for pre-operative staging. It revealed several cystic lesions of the liver and possible deformity of the duodenal bulb without definite evidence of metastatic disease (Figure 2). In addition, the gallbladder was contracted with suspicious wall thickening and heterogeneous content. At laparotomy, one unsuspected nodule was seen in segment 3 of the liver. The lesion was confirmed to be a metastatic liver nodule by frozen section. At the time of the operation, severe adhesion between the head of the pancreas and the peripyloric tissue was noted. As a result, a palliative subtotal gastrectomy with Billroth II gastrojejunostomy was performed due to partial outlet obstruction.

Post operatively, the patient had low-grade fever and persistent epigastric pain without jaundice, tarry stools, or active upper gastrointestinal hemorrhage. The laboratory tests on the 3rd postoperative day demonstrated a raised white cell count with left shift (11 500/ μ L), a platelet count of 176 000/ μ L and a hemoglobin of 9.5 g/dL. Serum biochemistry revealed a normal liver function and renal function but a raised C-reactive protein (CRP) of 193.27 mg/L. Slightly elevated amylase (185 U/L) and normal lipase (39 U/L) level were also noted. Chest X ray and urinary analysis were obtained and disclosed no pneumonia or urinary tract infection. Although the drainage fluid was clear, there was some yellowish and cloudy discharge from the abdominal wound. We collected the fluid for microbial analysis only and culture, which grew a yeast-like organism. Fever persisted despite the administration of intravenous antibiotics. Abdominal CT arranged on the 8th postoperative day demonstrated irregular pancreatic contours with diffuse enlargement and fluid accumulation in the lesser sac with retroperitoneal extension (Figure 3), suggestive of either an acute pancreatitis or duodenal stump leakage. The laboratory tests on the 10th postoperative day demonstrated a white cell count with marked left shift (8400/ μ L, 86% in segment form and 10% in band form), a decreased platelet count of 58 000/ μ L, a raised CRP of 247.95 mg/L, and normal serum level of pancreatic enzymes (amylase level was 79 U/L and lipase level was 26 U/L). In view of continuing clinical deterioration associated with peritonitis and intra-abdominal sepsis from a possible anastomosis leak rather than acute pancreatitis (according to the normal amylase and lipase levels), the patient underwent an exploratory laparotomy instead of percutaneous drainage of the fluid 10 d after the first operation. At laparotomy, colorless turbid fluid accumulation was found at the same regions as reported on the abdominal CT scan. There was no

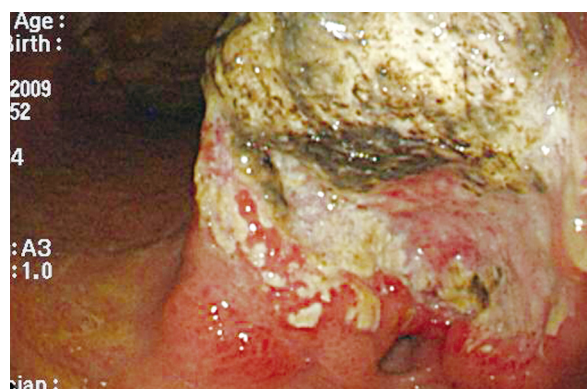


Figure 1 The esophagogastroduodenoscopy (EGD) showed an ulcerated, annular lesion over the gastric antrum.

evidence of bile leak, and the duodenal stump and anastomosis were intact. The necrotic tissues around the cavity of the loculated fluid collection had a similar appearance to fat necrosis in acute pancreatitis. Limited debridement was performed and a sump drain tube was placed for post-operative irrigation and drainage.

Bile-stained fluid was noted in the sump drain 2 d after the second operation, and the biochemistry study of the drainage fluid disclosed lower amylase and lipase levels (14 U/L and 9 U/L). Blood culture grew *Bacteroides fragilis* and hemogram showed progressive pancytopenia. A repeat CT scan suggested possible duodenal stump leakage with abscess formation (Figure 4). Despite total parenteral nutrition, hemodialysis for acute renal failure, and sump drain irrigation-drainage with intravenous antibiotics for septicemia and intra-abdominal infection, the patient eventually died of profound septic shock and multiple organ failure on day 30 after the first operation. A retrospective review of the patient's abdominal CT demonstrated a previously undiagnosed, asymptomatic PD (Figure 5).

DISCUSSION

Gastrectomy is a commonly practiced procedure for both benign and malignant lesions of the stomach. Major complications such as postoperative bleeding, anastomotic leak and delayed gastric emptying are well documented^[6]. In the past, most gastrectomies were performed for benign gastric or duodenal ulcer. The incidence of PGAP might be as high as 40.8% and the mortality rates in this group of patients ranged from 12.6% to 62.5%^[1,2]. Recently, gastrectomies have mostly been performed for gastric malignancies, and the complication and mortality rates are much less because of improved surgical technique and postoperative care. The incidence of PGAP nowadays, although difficult to accurately estimate, has been reported to be less than 5%^[7]. The mortality rate, however, can be up to 33.3%-50%^[8,9] and is higher than acute pancreatitis of other etiologies^[10]. Chen *et al*^[3] reported a higher incidence of PGAP in patients having total gastrectomy compared with other types of gastrectomies (7.4% *vs* 0.8%), with a 33.3% mortality rate. Another study reported higher

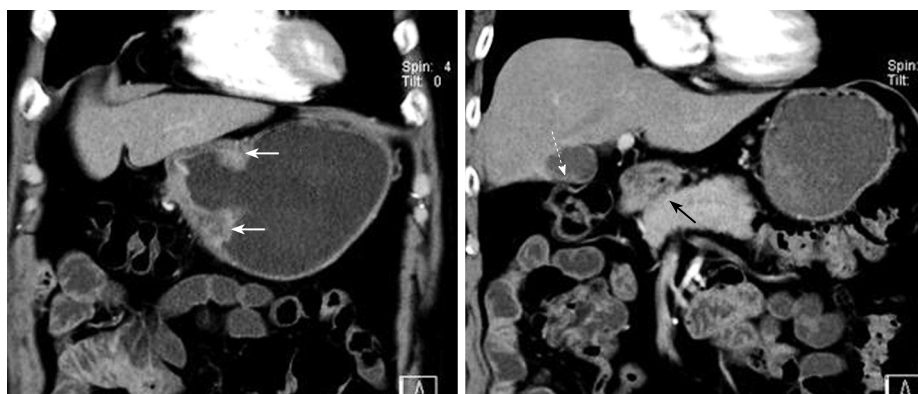


Figure 2 Preoperative abdominal CT images in coronary and transverse sections. The white solid arrows indicate diffuse wall thickening at the gastric antrum. The white dotted arrow indicates a contracted gallbladder with eccentric wall thickening. The black solid arrows point to the apparent deformity of the duodenal bulb with adhesion to the head of the pancreas. There is no evidence of intra-abdominal metastasis in this study.

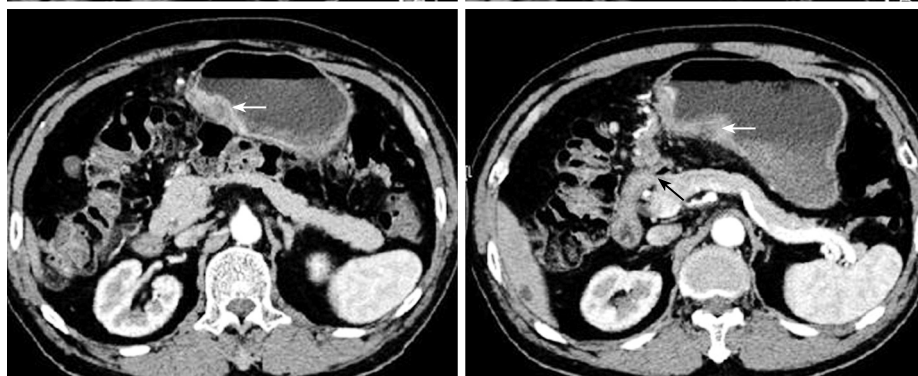


Figure 3 Abdominal CT 8 d after the first operation demonstrates massive fluid accumulation in the peripancreatic area and the lesser sac. The homogenous fluid extends to the retroperitoneal space. The status of the duodenal stump (black arrow) cannot be clearly assessed. The pancreas is well enhanced and enlarged, and the head shows an uneven and infiltrative margin (white arrow).

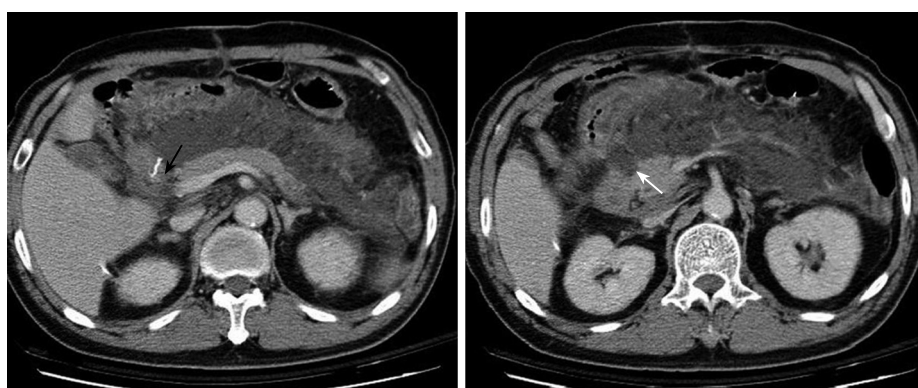


Figure 4 Follow-up abdominal CT after the second operation. Severe fat stranding is seen. An edematous duodenal stump is observed without a clear fat plane surrounding it. This is highly suspicious of a stump leak (black arrow). The loculated fluid with heterogeneous changes indicates the possibility of an abscess formation (white arrow).

PGAP rate in patients undergoing extended lymph node dissection^[4]. Despite the various advantages of laparoscopically assisted gastrectomy (LAG), the rates of acute pancreatitis after LAG have also been shown to range from 0.7% to 2.3%^[8,9,11]. The poorer prognosis of PGAP might be related to postoperative immunosuppression, increased pancreatitis-related hemorrhage because of extensive soft tissue/lymph node dissection, or anastomotic leak secondary to necrotizing pancreatitis

and intra-abdominal sepsis.

PGAP may be a result of several factors. The stomach/duodenum might adhere to the underlying pancreas because of severe peptic ulceration or desmoplastic change from malignancy. Sometimes, the pancreas might actually be the base of the ulcer. Injury to the pancreatic parenchyma by electrocauterization or traction, microcirculation compromise, and direct injury to the pancreatic duct might occur during gastrectomy^[7,11]. Other causes

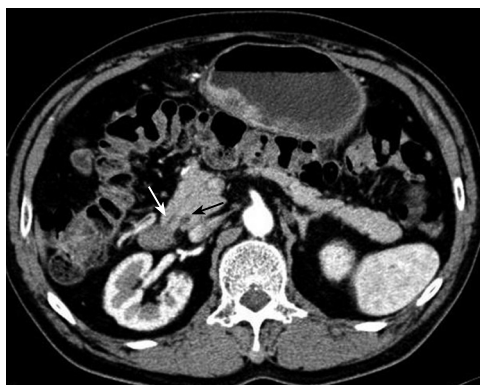

Figure 5 The preoperative CT scan. The dominant dorsal duct (duct of Santorini) drains into the minor papilla (white arrow). The CBD is seen in the section (black arrow) but the ventral duct (duct of Wirsung) can not be traced. These features are consistent with pancreas divisum.

of PGAP such as duodenal hyperpressure^[1] and post-operative spasm of the major papilla^[2] have been hypothesized, but there is a general lack of evidence in the literature to substantiate these theories. Although some studies suggested insertion of a nasogastric tube or a duodenostomy tube after gastrectomy for decompression and releasing duodenal hyperpressure, Hsu *et al*^[12] reported no difference in PGAP in spite of NG tube insertion. On the contrary, the “pancreatitis-like” presentation (such as hyperamylasemia and epigastric pain) caused by afferent loop obstruction can be cured under careful management of operations or decompression procedures^[7,13]. The condition should be taken into consideration because the prognosis, timing of intervention and treatment options are far different from PGAP without A-loop obstruction.

The diagnosis of acute pancreatitis is mainly dependent on suggestive clinical features and laboratory studies. Physical examination may be variable and non-specific in postoperative patients because of pain and symptoms related to the operation. Elevated lipase levels 3-fold or more above the normal range appearing within 48 h is the most reliable test^[14]. However, normal serum pancreatic enzyme levels cannot exclude acute pancreatitis absolutely^[14]. Abdominal CT scan is particularly helpful in making a definitive diagnosis and excluding other differential diagnoses such as anastomotic leak, intra-abdominal abscess and hemorrhage^[15]. However, the anatomical distortion post-operatively often makes the interpretation of CT images difficult^[16]. This is exemplified by the present case report whereby a definitive diagnosis of PGAP was delayed because of equivocal pancreatic enzymes and non-specific CT findings of intra-abdominal fluid collection.

PD is a common congenital anomaly of the pancreas, with an incidence rate of 4% to 10%^[17-19]. Anatomically, the dorsal duct (duct of Santorini) becomes the dominant duct draining the majority of the pancreatic juice through the minor papilla. The ventral duct (duct of Wirsung) does not fuse with the dorsal duct and only drains a small portion of the pancreatic head through the major papilla. The diagnosis of PD is made with

endoscopic retrograde pancreatography (ERP) or magnetic resonance pancreatography (MRP). However, with the advent of multi-detector CT scans, high sensitivity and specificity for diagnosis of PD can be achieved by CT images in some particular conditions^[20-22]. The CT features consistent with PD include the presence of the dominant dorsal duct sign (the dorsal duct being larger than the ventral duct, or a missing ventral duct) and the miss-communication between the two pancreatic ducts^[20]. Both of these features were observed on the patient's CT images retrospectively (Figure 5). About 5% to 45.5% of patients with PD present with pancreatitis or chronic abdominal pain^[23,24]. The pathogenesis of this is attributable to the “relative stenosis” of the minor papilla as it drains the majority of the pancreatic juice through a small opening^[24], resulting in an increase in the intra-ductal pressure of the dorsal duct system (20-28 mmHg *vs* 8-14 mmHg in normal pressure of major papilla)^[25]. In addition, the unusual anatomical arrangement of the sphincter of the minor papilla could also contribute to the development of intra-ductal hypertension leading to pancreatitis^[26]. Kamisawa *et al*^[27] reported the high incidence of pancreatitis or pancreatic-type abdominal pain in patients with dominant duct of Santorini but without pancreas divisum.

According to these findings, it is reasonable to suppose that patients with PD might be more sensitive to minor injury of the pancreas and disturbance of its microcirculation. Once developed, it might progress precipitously to a more severe form and patients are slower to gain full recovery. Prophylactic administration of octreotide in the post-operative setting has been suggested in an attempt to prevent the development of PGAP^[7]. The roles of preoperatively prophylactic cannulation of minor papilla, stent placement, and sphincterotomy have not been reported yet. The potential benefits of these invasive procedures in patients with PD or dominant duct of Santorini undergoing gastrectomy warrant further investigation.

In conclusion, PGAP is a less frequent post-gastrectomy complication in the current era. However, diagnosis and intervention should be made as early as possible because of the relatively high mortality rate associated with PGAP. Theoretically, patients with pancreas divisum or dominant duct of Santorini might connect to PGAP but the absolute relationship should be explored. Although serum pancreatic enzymes play an important role in the diagnosis of acute pancreatitis, imaging study such as an abdominal CT scan is particularly helpful in patients at high risk for PGAP. The roles and benefits of prophylactic octreotide, preoperative cannulation/stenting of the minor papilla, and sphincterotomy of minor papilla have not been well documented and would therefore warrant further investigation.

REFERENCES

- 1 **Bacchini I**, Martino G, Falaschi CF, Viti M, Sammartano C, Mantovani R. [Postoperative acute pancreatitis (PAP). Direct personal experience] *Minerva Chir* 1980; **35**: 421-427
- 2 **Lubianskii VG**, Nasonov SV. [Acute pancreatitis after resection of stomach for low duodenal ulcer] *Khirurgiya*

- (Mosk) 2001; 8-11
- 3 **Chen MM**, Zhu ZG, Yan M, Chen J, Xiang M, Li C, Zhang J, Yao XX, Yang QM. Etiology and management of early postoperative severe acute pancreatitis following radical gastrectomy. *Shanghai Jiaotong Daxue Xuebao (Yixueban)* 2007; **27**: 566-568
 - 4 **Li FN**, Chen D, Wang HY. Acute pancreatitis following radical gastrectomy for carcinoma of the stomach: Its features, prevention, and treatment. *Qingdao Daxue Yixueyuan Xuebao* 2003; **39**: 259-267
 - 5 **Doglietto GB**, Pacelli F, Caprino P, Bossola M, Di Stasi C. Pancreas-preserving total gastrectomy for gastric cancer. *Arch Surg* 2000; **135**: 89-94
 - 6 **Siewert JR**, Bumm R. Distal gastrectomy with Billroth I, Billroth II or Roux-Y reconstruction. In: Fischer JE, Bland KI, editors. *Mastery of Surgery*. 5th ed. Philadelphia: Lippincott Williams and Wilkins; 2007: 849-860
 - 7 **Soybel DI**, Zinner MJ. Complications following gastric operations. In: Zinner MJ, Schwartz SI, editors. *Maingot's Abdominal Operations*. 10th ed. Stamford, CT: Appleton and Lange; 1997: 1029-1056
 - 8 **Park JM**, Jin SH, Lee SR, Kim H, Jung IH, Cho YK, Han SU. Complications with laparoscopically assisted gastrectomy: multivariate analysis of 300 consecutive cases. *Surg Endosc* 2008; **22**: 2133-2139
 - 9 **Ibanez Aguirre FJ**, Azagra JS, Erro Azcarate ML, Goergen M, Rico Selas P, Moreno Elola-Olaso A, Clemares de Lama M, de Simone P, Echenique Elizondo MM. Laparoscopic gastrectomy for gastric adenocarcinoma. Long-term results. *Rev Esp Enferm Dig* 2006; **98**: 491-500
 - 10 **Tonsi AF**, Bacchion M, Crippa S, Malleo G, Bassi C. Acute pancreatitis at the beginning of the 21st century: the state of the art. *World J Gastroenterol* 2009; **15**: 2945-2959
 - 11 **Bo T**, Zhihong P, Peiwu Y, Feng Q, Ziqiang W, Yan S, Yongliang Z, Huaxin L. General complications following laparoscopic-assisted gastrectomy and analysis of techniques to manage them. *Surg Endosc* 2009; **23**: 1860-1865
 - 12 **Hsu SD**, Yu JC, Chen TW, Chou SJ, Hsieh HF, Chan DC. Role of Nasogastric Tube Insertion after Gastrectomy. *Chir Gastroenterol* 2007; **23**: 303-306
 - 13 **Kim HJ**, Kim JW, Kim KH, Jo KW, Hong JH, Baik SK, Kim HS. [A case of afferent loop syndrome treated by endoscopic drainage procedure using nasogastric tube] *Korean J Gastroenterol* 2007; **49**: 173-176
 - 14 **Cartier T**, Sogni P, Perruche F, Meyniard O, Claessens YE, Dhainaut JF, Der Sahakian G. Normal lipase serum level in acute pancreatitis: a case report. *Emerg Med J* 2006; **23**: 701-702
 - 15 **Steer ML**. Exocrine pancreas. In: Townsend CM, Beauchamp RD, editors. *Sabiston Textbook of Surgery*. 17th ed. Philadelphia: Elsevier Saunders; 2004: 1643-1678
 - 16 **Kim KW**, Choi BI, Han JK, Kim TK, Kim AY, Lee HJ, Kim YH, Choi JI, Do KH, Kim HC, Lee MW. Postoperative anatomic and pathologic findings at CT following gastrectomy. *Radiographics* 2002; **22**: 323-336
 - 17 **Agha FP**, Williams KD. Pancreas divisum: incidence, detection, and clinical significance. *Am J Gastroenterol* 1987; **82**: 315-320
 - 18 **Delhaye M**, Engelholm L, Cremer M. Pancreas divisum: congenital anatomic variant or anomaly? Contribution of endoscopic retrograde dorsal pancreatography. *Gastroenterology* 1985; **89**: 951-958
 - 19 **Millbourn E**. On the excretory ducts of the pancreas in man, with special reference to their relations to each other, to the common bile duct and to the duodenum. *Acta Anat (Basel)* 1950; **9**: 1-34
 - 20 **Soto JA**, Lucey BC, Stuhlfaut JW. Pancreas divisum: depiction with multi-detector row CT. *Radiology* 2005; **235**: 503-508
 - 21 **Anderson SW**, Soto JA. Pancreatic duct evaluation: accuracy of portal venous phase 64 MDCT. *Abdom Imaging* 2009; **34**: 55-63
 - 22 **Itoh S**, Takada A, Satake H, Ota T, Ishigaki T. Diagnostic value of multislice computed tomography for pancreas divisum: assessment with oblique coronal reconstruction images. *J Comput Assist Tomogr* 2005; **29**: 452-460
 - 23 **Varshney S**, Johnson CD. Pancreas divisum. *Int J Pancreatol* 1999; **25**: 135-141
 - 24 **Gregg JA**. Pancreas divisum: its association with pancreatitis. *Am J Surg* 1977; **134**: 539-543
 - 25 **Staritz M**, Meyer zum Buschenfelde KH. Elevated pressure in the dorsal part of pancreas divisum: the cause of chronic pancreatitis? *Pancreas* 1988; **3**: 108-110
 - 26 **Valverde Barbato de Prates NE**, Smanio T, De Maio Domingos M, Ferraz de Carvalho CA. "Sphincter" of the minor papilla of the human duodenum. *Clin Anat* 1996; **9**: 34-40
 - 27 **Kamisawa T**, Egawa N, Nakajima H, Okamoto A. Clinical and radiological findings in dominance of Santorini's duct. *Digestion* 2004; **70**: 146-151

S- Editor Li LF L- Editor O'Neill M E- Editor Ma WH