



EDITORIAL

Clinical analysis of primary anaplastic carcinoma of the small intestine

Tsutomu Namikawa, Kazuhiro Hanazaki

Tsutomu Namikawa, Kazuhiro Hanazaki, Department of Surgery, Kochi Medical School, Kohasu-Okochi, Nankoku-City, Kochi 783-8505, Japan

Author contributions: Namikawa T and Hanazaki K contributed equally to this work; Namikawa T and Hanazaki K analyzed the data and wrote the paper.

Correspondence to: Kazuhiro Hanazaki, Professor, Department of Surgery, Kochi Medical School, Kohasu-Okochi, Nankoku-City, Kochi 783-8505, Japan. hanazaki@kochi-u.ac.jp

Telephone: +81-88-8802370 Fax: +81-88-8802371

Received: September 1, 2008 Revised: December 10, 2008

Accepted: December 17, 2008

Published online: February 7, 2009

Abstract

Primary anaplastic carcinoma is a rare variant of small intestinal cancer. Most reports of primary anaplastic carcinoma of the small intestine are isolated case reports, therefore the clinicopathological features, therapeutic management, and surgical outcome of this tumor type remain unclear. This review analyzes the available clinical characteristics of primary anaplastic carcinoma of the small intestine and investigates key differences from differentiated adenocarcinoma of the small intestine. A Medline search was performed using the keywords 'small intestine' and 'anaplastic carcinoma' or 'undifferentiated carcinoma'. Additional articles were obtained from references within the papers identified by the Medline search. The literature revealed a poor prognosis for patients who underwent surgical resection for anaplastic carcinoma of the small intestine, which gave a 3-year overall survival rate of 10.8% and a median survival time of 5.0 mo. The literature suggests that anaplastic carcinoma is markedly more aggressive than differentiated adenocarcinoma of the small intestine. Surgical resection with the aim of complete tumor removal provides the only beneficial therapeutic option for patients with anaplastic carcinoma of the small intestine, because chemotherapy and radiation therapy have no significant effect on the rate of survival. However, despite complete tumor resection, most patients with anaplastic carcinoma of the small intestine are at great risk of disease recurrence. Multicenter clinical trials are expected to provide additional therapeutic strategies and establish the efficacy of multimodality adjuvant therapy. This

report also highlights the importance of a systematic diagnostic approach for anaplastic carcinoma of the small intestine.

© 2009 The WJG Press and Baishideng. All rights reserved.

Key words: Anaplastic carcinoma; Small intestinal cancer; Small intestinal tumor; Operation; Prognosis

Peer reviewer: Dario Conte, Professor, GI Unit - IRCCS Osp. Maggiore, Chair of Gastroenterology, Via F. Sforza, 35, Milano 20122, Italy

Namikawa T, Hanazaki K. Clinical analysis of primary anaplastic carcinoma of the small intestine. *World J Gastroenterol* 2009; 15(5): 526-530 Available from: URL: <http://www.wjgnet.com/1007-9327/15/526.asp> DOI: <http://dx.doi.org/10.3748/wjg.15.526>

INTRODUCTION

The small intestine represents more than 75% of the length and 90% of the total mucosal surface area of the alimentary tract; however, it contributes only about 1% of malignant gastrointestinal tumors^[1]. Several hypotheses have been proposed to explain why small intestinal tumors are rare^[2]. While there are many reported reviews of small intestinal tumors^[3-7] including sarcomas^[8,9], only a few describe the occurrence of small intestinal carcinoma^[10-13]. Small intestinal carcinomas are uncommon among the malignant tumors that occur throughout the entire alimentary tract but represent 50% of small intestinal malignant tumors. Anaplastic carcinoma is a rare variant of small intestinal carcinoma. Most reports describing the occurrence of anaplastic carcinoma of the small intestine do not include a detailed description of the pathology of this disease. The aim of the present study was to review the clinical presentation, surgical management, and prognostic factors of primary anaplastic carcinoma of the small intestine.

PATIENTS AND CLINICAL PRESENTATION

We reviewed 18 patients who underwent surgical resection for anaplastic carcinoma of the small

Table 1 Clinicopathological data for reported cases of anaplastic carcinoma of the small intestine

Case	Author	Yr	Age	Gender	Chief complaint	Primary site	Tumor size (cm)	Tumor depth	Lymph node metastasis	Prognosis (mo)
1	Ikeda ^[22]	1974	62	F	Abdominal pain	Ileum	9	SE	Negative	Alive 12
2	Sasaki ^[23]	1988	37	M	Abdominal pain	Jejunum	7	SS	Positive	9
3	Robey-Cafferty ^[24]	1989	62	M	Cervical LN enlarge	Ileum	5	SI	ND	20
4			38	F	Fatigue	Jejunum	16	MP	Positive	8
5			48	F	Periumbilical mass	Jejunum	6	SI	Positive	2
6			65	M	Abdominal pain	Jejunum	5	SE	Positive	5
7			54	F	intestinal obstruction	Ileum	4.5	MP	Negative	Alive 12
8			35	F	Abdominal pain	Jejunum	7.5	ND	Negative	36
9	Ikeguchi ^[25]	1993	63	M	Abdominal pain	Ileum	4	SS	Negative	Alive 36
10	Amano ^[26]	1998	81	M	Abdominal pain	Jejunum	8.5	SE	Positive	1
11	Agrawal ^[27]	1999	53	M	melenia	Ileum	13	SI	Positive	2
12	Nakamura ^[28]	2000	73	F	Vomiting	Ileum	3.5	SS	Negative	6
13	Kadoya ^[29]	2003	57	M	General fatigue	Ileum	21	SE	Positive	2
14	Sato ^[30]	2003	46	M	Back pain	Jejunum	9	SE	ND	4
15	Usuda ^[31]	2007	84	M	Fever of unknown origin	Jejunum	8	SE	Positive	1.5
16	Shiraishi ^[32]	2007	48	M	Abdominal pain	Jejunum	5	SE	Negative	Alive 8
17	Matsuoka ^[33]	2008	56	M	Abdominal pain	Jejunum	10	SS	Positive	1
18	Our case	2008	65	F	Anemia	Ileum	6	SS	Negative	Alive 8

MP: Muscularis propria layer; SS: Subserosal layer, SE: Penetration of serosa; SI: Invasion of adjacent structures; ND: Not described.

intestine between 1974 and 2008. Seventeen cases were identified in the available literature using a Medline search and Japan Centra Revuo Medicina (Table 1). One reported case was a patient treated in our hospital. The clinicopathological features of the 18 reported cases are listed in Table 1. The mean age of patients with anaplastic carcinoma of the small intestine was 58 years (range, 38–81 years). There was a slight male predominance, with a male-to-female ratio of 11:7. The most common presenting signs and symptoms of small intestinal cancer were nausea, vomiting, abdominal pain, melena, weight loss, anemia, and palpable mass, none of which is pathognomonic for small intestinal tumors. The most common presenting complaint of patients with anaplastic carcinoma of the small intestine was abdominal pain, which was present in 47% of patients. For malignant small bowel neoplasms the most common symptom was pain followed by gastrointestinal bleeding, weight loss, nausea, and vomiting. The nonspecific nature of the reported symptoms usually leads to a delay in presentation and work-up. The average diameter of tumors was 8.3 cm (range, 3.5–21 cm).

The most common location for small intestinal carcinoma is the duodenum^[4]. More distal tumors are found more frequently in the jejunum than in the ileum^[4,12]. By comparison, anaplastic carcinoma of the small intestine was not found in the duodenum but in the jejunum in 10 cases and in the ileum in 8 cases. The symptoms associated with primary small intestinal tumors were usually vague and nonspecific. The nonspecificity of the symptoms associated with this disease is considered a contributing factor in the delayed diagnosis associated with small intestinal tumors.

The pathogenesis of small intestinal carcinoma is largely unknown. Small intestinal regional enteritis, or Crohn's disease, is reported to be associated with small intestinal carcinoma. It is estimated that a carcinoma

will develop in 2%–3% of patients with small intestinal regional enteritis^[14]. One investigator reported a linear correlation between the incidence of small intestinal cancer and colon cancer^[15].

Survival analyses of patients with small intestinal carcinoma were performed using the Kaplan Meier method with the log rank test to assess statistical significance. Values were expressed appropriately as the mean \pm SD. The Cox proportional hazards regression model was used to assess the combined effects of covariates on survival. *P* values of less than 0.05 were considered significant.

TREATMENT OF SMALL INTESTINAL CANCER

In most studies, surgery as a curative treatment option for small intestinal cancer was performed in 40%–65% of patients, with reported 5-year survival rates of 40%–60% for resected tumors *versus* 15%–30% for nonresected tumors^[10,11,16]. Many reports indicated that chemotherapy and radiation therapy did not significantly influence survival^[12,17]. According to published reports, jejunal or ileal adenocarcinoma should be treated aggressively with segmental resection and primary anastomosis^[18]. Pancreaticoduodenectomy with complete resection of the tumor and negative margins is associated with favorable long-term survival^[19]. On the basis of this finding, patients with a tumor at the proximal duodenum should be treated by pancreaticoduodenectomy. Analysis of the findings of previous reports suggests that radical curative surgery is the most important prognostic factor for survival of patients with small intestinal cancer. Complete surgical resection has emerged as the most important prognostic variable in the management of this disease. A similar management strategy can be applied for the treatment of patients with anaplastic carcinoma

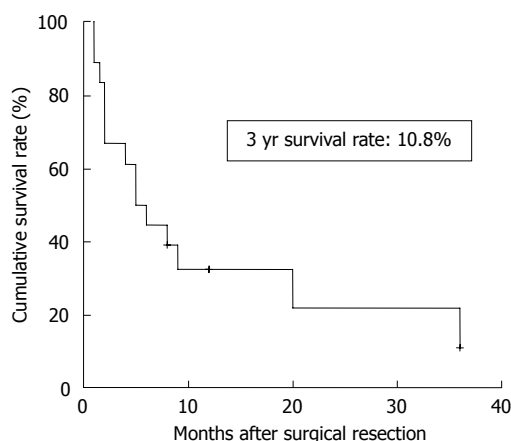


Figure 1 Survival after surgical resection for anaplastic carcinoma of the small intestine ($n = 18$).

of the small intestine. However, the prognosis for patients with small intestinal cancer is dismal.

PROGNOSTIC FACTORS OF RESECTABLE SMALL INTESTINAL CANCER

The 5-year survival rate for primary adenocarcinoma of the small intestine ranges from 17.5% to 37%^[12,13,17]. In this review, the overall 3-year survival rate of anaplastic carcinoma of the small intestine after surgical resection was 10.8% (Figure 1). There were no patients who survived over 4 years. Thus, patients with anaplastic carcinoma of the small intestine have a poorer prognosis than patients with adenocarcinoma of the small intestine. In general, anaplastic carcinoma has a high malignancy grade potential. Consistent with findings reported in previous reviews, the prognostic factors that influence the survival of patients with anaplastic carcinoma include patient age, tumor site, clinical staging, curative resection surgery, tumor size, histological grade, nodal metastases, lymphangiosis carcinomatosa, and vascular invasion^[6,12,17]. Univariate analysis of the different prognostic factors predicted to contribute to patient prognosis revealed that age and lymph node metastases were unfavorable prognostic factors. Overall median survival of patients over 65 years old with lymph node metastases was significantly worse than that for patients under 65 years old without lymph node metastases. Gender, tumor depth, tumor location, and tumor size were not significant prognostic factors (Table 2). By comparison, Veyrières *et al*^[10] (1997) revealed the degree of tumor differentiation to be a significant prognostic factor. However, multivariate analysis demonstrated that lymph node metastases, and not tumor differentiation, was an independent prognostic factor^[11]. For patients with anaplastic carcinoma of the small intestine, the median survival period was significantly shorter for patients with positive lymph nodes than for patients with negative lymph nodes, according to the Cox proportional hazards model (Table 3). When a curative surgical

Table 2 Clinical characteristics after surgical resection of anaplastic carcinoma of the small intestine (mean \pm SD)

Characteristics	No. of patients	3 yr survival rate (%)	Median survival in months	P value
Overall	17	10.8	5.0 \pm 1.4	
Age (yr)				
< 65	13	15	9.0 \pm 4.2	0.03
> 65	5	0	5.0 \pm 1.6	
Gender				
Male	11	12.1	4.0 \pm 1.5	0.38
Female	7	0	8.0 \pm 2.6	
Tumor depth				
T2 (MP)	2	66.7	26.7 \pm 7.6	0.21
T3 (SS)	5	0	6.0 \pm 1.5	
T4 (SE, SI)	10	0	2.0 \pm 1.0	
Tumor location				
Jejunum	10	0	4.0 \pm 2.4	0.17
Ileum	8	25	6.0 \pm 7.0	
Tumor size (cm)				
< 7	8	28.6	20.0 \pm 10.9	0.13
> 7	10	0	2.0 \pm 1.3	
LN metastasis				
Negative	7	41.7	36.0 \pm 21.9	0.0009
Positive	9	0	2.0 \pm 0.3	

MP: Muscularis propria layer; SS: Subserosal layer; SE: Penetration of serosa; SI: Invasion of adjacent structures.

Table 3 Relative risk with regard to survival rate according to the Cox proportional hazards model

Variable	Odds ratio (95% CI)	P value
Lymph node metastasis		
Negative	13.7 (1.6-114.1)	0.016
Positive		
Age (yr)		
< 65	2.9 (0.7-11.8)	0.145
> 65		

resection is performed before lymph node metastases, the chance of long-term survival is greatly increased. A previous study revealed a significant positive correlation between the survival of patients with adenocarcinoma of the small intestine and pathological differentiation (Table 4). In the present review, more patients with anaplastic carcinoma had a poorer prognosis than patients with adenocarcinoma, despite curative resection of the tumor. However, the number of patients is too small to allow an accurate evaluation of prognosis. The establishment of a multicenter registry would provide a basis for multivariate analysis of factors influencing survival.

METHODS AND EFFICACY OF EARLY DIAGNOSIS

The poor prognosis for anaplastic carcinoma of the small intestine may be related to a delay in the diagnosis and treatment of the disease. An early and accurate diagnosis is essential to improve the prognosis for patients with small intestinal cancer. The correct

Table 4 Survival rates of patients with adenocarcinoma of the small intestine according to pathological differentiation

Author	Differentiation	No. of patients	Survival rate (%)		Significance
			5 yr	10 yr	
Miles ^[7]	Well differentiated	13	15	8	0.18
	Undifferentiated	5	60	33	
Veyrieres ^[10]	Well differentiated	51	56	43	0.08
	Undifferentiated	6	40	0	
Dabaja ^[11]	Well differentiated	92	25		0.45
	Undifferentiated	57	24		
Wu ^[13]	Well differentiated	33	88.7 ± 18.88 ¹		0.26
	Undifferentiated	10	13.3 ± 3.96 ¹		
Robey-Cafferty ^[24]	Well differentiated	29	25		0.24
	Undifferentiated	6	0		

¹Mean survival time (months ± SD).

diagnosis of small intestinal tumors remains difficult, because the tumors are rare and the symptoms are ambiguous. Performance of a conventional double-contrast series of the small intestine proved to be an excellent diagnostic modality, but is increasingly being replaced by cross-sectional imaging methods including computed tomography (CT) and magnetic resonance imaging (MRI). CT was the most efficient method for demonstrating the presence of a mass lesion, which suggests a locally advanced tumor with contiguous organ invasion, and for confirming the absence of distant metastases. Recent advances in multidetector CT (MDCT) technology have allowed the production of high-resolution cross-sectional images of the abdomen and the small intestine^[20]. Upper gastrointestinal endoscopy is an accurate method for the diagnosis of duodenal tumors, but deep insertion of an endoscope by the push technique is difficult. A novel double-balloon enteroscopy system, which was developed by Yamamoto *et al.*^[21], has been applied for diagnosis in patients with obscure gastrointestinal bleeding or chronic abdominal pain. The double-balloon enteroscopy system has the advantage of allowing examination of the entire small intestine by direct visualization. It is apparent from these studies that early enteroscopic examination must be performed as soon as carcinoma of the small intestine is suspected, to allow accurate and early diagnosis.

CONCLUSION

Anaplastic carcinoma of the small intestine is an extremely rare disease, is often diagnosed at an advanced stage, and displays an aggressive clinical course. Despite treatment by means of optimized surgical procedures, patients who have undergone complete tumor resection have a poor prognosis. To improve the outcome of surgical treatment, additional therapy, such as multimodality adjuvant therapy or the administration of novel molecular targeted drugs, should be considered for patients with anaplastic carcinoma of the small intestine. Furthermore, randomized, prospective clinical trials need to be conducted to demonstrate an unequivocal survival advantage for patients who have received chemotherapy

or radiation therapy after resection of anaplastic carcinoma of the small intestine.

REFERENCES

- 1 Silberman H, Crichlow RW, Caplan HS. Neoplasms of the small bowel. *Ann Surg* 1974; **180**: 157-161
- 2 Lowenfels AB. Why are small-bowel tumours so rare? *Lancet* 1973; **1**: 24-26
- 3 Cunningham JD, Aleali R, Aleali M, Brower ST, Aufses AH. Malignant small bowel neoplasms: histopathologic determinants of recurrence and survival. *Ann Surg* 1997; **225**: 300-306
- 4 Ciccirelli O, Welch JP, Kent GG. Primary malignant tumors of the small bowel. The Hartford Hospital experience, 1969-1983. *Am J Surg* 1987; **153**: 350-354
- 5 Mittal VK, Bodzin JH. Primary malignant tumors of the small bowel. *Am J Surg* 1980; **140**: 396-399
- 6 Minardi AJ Jr, Zibari GB, Aultman DF, McMillan RW, McDonald JC. Small-bowel tumors. *J Am Coll Surg* 1998; **186**: 664-668
- 7 Miles RM, Crawford D, Duras S. The small bowel tumor problem: an assessment based on a 20 year experience with 116 cases. *Ann Surg* 1979; **189**: 732-740
- 8 McGrath PC, Neifeld JP, Lawrence W Jr, Kay S, Horsley JS 3rd, Parker GA. Gastrointestinal sarcomas. Analysis of prognostic factors. *Ann Surg* 1987; **206**: 706-710
- 9 Yao KA, Talamonti MS, Langella RL, Schindler NM, Rao S, Small W Jr, Joehl RJ. Primary gastrointestinal sarcomas: analysis of prognostic factors and results of surgical management. *Surgery* 2000; **128**: 604-612
- 10 Veyrieres M, Baillet P, Hay JM, Fingerhut A, Bouillot JL, Julien M. Factors influencing long-term survival in 100 cases of small intestine primary adenocarcinoma. *Am J Surg* 1997; **173**: 237-239
- 11 Dabaja BS, Suki D, Pro B, Bonnen M, Ajani J. Adenocarcinoma of the small bowel: presentation, prognostic factors, and outcome of 217 patients. *Cancer* 2004; **101**: 518-526
- 12 Chaiyasate K, Jain AK, Cheung LY, Jacobs MJ, Mittal VK. Prognostic factors in primary adenocarcinoma of the small intestine: 13-year single institution experience. *World J Surg Oncol* 2008; **6**: 12
- 13 Wu TJ, Yeh CN, Chao TC, Jan YY, Chen MF. Prognostic factors of primary small bowel adenocarcinoma: univariate and multivariate analysis. *World J Surg* 2006; **30**: 391-398; discussion 399
- 14 Munkholm P, Langholz E, Davidsen M, Binder V. Intestinal cancer risk and mortality in patients with Crohn's disease. *Gastroenterology* 1993; **105**: 1716-1723
- 15 Neugut AI, Jacobson JS, Suh S, Mukherjee R, Arber N. The epidemiology of cancer of the small bowel. *Cancer Epidemiol Biomarkers Prev* 1998; **7**: 243-251

- 16 **Ouriel K**, Adams JT. Adenocarcinoma of the small intestine. *Am J Surg* 1984; **147**: 66-71
- 17 **Talamonti MS**, Goetz LH, Rao S, Joehl RJ. Primary cancers of the small bowel: analysis of prognostic factors and results of surgical management. *Arch Surg* 2002; **137**: 564-570; discussion 570-571
- 18 **Neugut AI**, Marvin MR, Rella VA, Chabot JA. An overview of adenocarcinoma of the small intestine. *Oncology* (Williston Park) 1997; **11**: 529-536; discussion 545, 549-550
- 19 **Bakaeen FG**, Murr MM, Sarr MG, Thompson GB, Farnell MB, Nagorney DM, Farley DR, van Heerden JA, Wiersema LM, Schleck CD, Donohue JH. What prognostic factors are important in duodenal adenocarcinoma? *Arch Surg* 2000; **135**: 635-641; discussion 641-642
- 20 **Sailer J**, Zacherl J, Schima W. MDCT of small bowel tumours. *Cancer Imaging* 2007; **7**: 224-233
- 21 **Yamamoto H**, Sekine Y, Sato Y, Higashizawa T, Miyata T, Iino S, Ido K, Sugano K. Total enteroscopy with a nonsurgical steerable double-balloon method. *Gastrointest Endosc* 2001; **53**: 216-220
- 22 **Ikeda Y**, Matsumura S, Sunagawa K, Watanabe K, Masaoka T, Uegaki K. Primary carcinoma of the small intestine; A report of two cases. *J Hiroshima Med Assoc* 1979; **27**: 358-362
- 23 **Sasaki M**, Hanatate F, Yamamura K, Munemoto Y, Takabatake I, Murakami S, Hikishima H, Hayashi T, Yamada T, Kitagawa S, Nakagawa M. A case of small intestinal undifferentiated carcinoma with a chief complaint of anemia. *Jpn J Gastroenterol Surg* 1988; **21**: 2435-2438
- 24 **Robey-Cafferty SS**, Silva EG, Cleary KR. Anaplastic and sarcomatoid carcinoma of the small intestine: a clinicopathologic study. *Hum Pathol* 1989; **20**: 858-863
- 25 **Ikeguchi M**, Nishidoi H, Kudou H, Murakami S, Masaki T, Taniguchi H, Maeda K. A case of primary ileal undifferentiated carcinoma: clinicopathological study on 95 cases of primary jejunal and ileal carcinoma in Japan. *Jpn J Surg Assoc* 1993; **54**: 450-454
- 26 **Amano H**, Kuroda Y, Kuranishi F, Urushihara T, Shimokado K, Fujimori M, Kitayama T, Yonehara S. Two cases of primary small intestinal cancer. *J Hiroshima Med Assoc* 1998; **51**: 739-742
- 27 **Agrawal S**, Trivedi MH, Lukens FJ, Moon C, Ingram EA, Barthel JS. Anaplastic and sarcomatoid carcinoma of the small intestine: an unusual tumor. *J Clin Gastroenterol* 1999; **29**: 99-101
- 28 **Nakamura T**, Otani Y, Kokuba Y, Kanazawa H, Aihara S, Kakita A. A case of undifferentiated cancer with neuroendocrine differentiation of the small intestine accompanied by multiple small bowel metastases. *Jpn J Surg Assoc* 2000; **61**: 3271-3275
- 29 **Kadoya M**, Suzuki Y, Hazama K, Nakanishi Y, Kanai M, Takahashi M, Fujita M, Kato H. A case of primary anaplastic carcinoma of the small intestine. *Jpn J Gastroenterol Surg* 2003; **36**: 1615-1620
- 30 **Sato Y**, Nagatsuka Y, Iwabuchi H, Arai H, Wakayama T, Ogawa T, Tanaka M. A case of synchronous double cancer involving the lung and small intestine. *Jpn J Surg Assoc* 2003; **64**: 3230-3234
- 31 **Usuda M**, Nakano T, Hirano T, Suzuki H, Mochizuki I, Ono S. A case of undifferentiated carcinoma of the small intestine presenting as fever of unknown origin. *Jpn J Surg Assoc* 2007; **68**: 2543-2547
- 32 **Shiraishi R**, Kikkawa A, Sumi K, Hidaka K. A case of primary undifferentiated cancer in the small intestine. *Intern Med* 2007; **100**: 790-794
- 33 **Matsuoka T**, Katsuragi K, Matsuzaki T, Takashima S, Wakasa K, Okuno M. A case of small bowel anaplastic carcinoma with multiple intramural metastases. *Jpn J Gastroenterol Surg* 2008; **41**: 123-128

S- Editor Cheng JX L- Editor Stewart GJ E- Editor Zheng XM