

## Anal transition zone in the surgical management of ulcerative colitis

Jennifer Holder-Murray, Alessandro Fichera

Jennifer Holder-Murray, Alessandro Fichera, Department of Surgery, University of Chicago, Chicago, IL 60637, United States  
Author contributions: Holder-Murray J and Fichera A wrote the paper.

Correspondence to: Alessandro Fichera, MD, Department of Surgery, University of Chicago, 5841 S. Maryland Ave MC 5095, Chicago, IL 60637,

United States. [afichera@surgery.bsd.uchicago.edu](mailto:afichera@surgery.bsd.uchicago.edu)

Telephone: +1-773-7026142 Fax: +1-773-8341995

Received: October 21, 2008 Revised: January 20, 2009

Accepted: January 27, 2009

Published online: February 21, 2009

15(7): 769-773 Available from: URL: <http://www.wjgnet.com/1007-9327/15/769.asp> DOI: <http://dx.doi.org/10.3748/wjg.15.769>

### INTRODUCTION

Restorative proctocolectomy and ileal pouch anal anastomosis (RPC IPAA) remain the standard of care in the surgical management of ulcerative colitis; however, controversy persists regarding preservation of the anal transition zone (ATZ). RPC IPAA is performed *via* either a stapled technique or a transanal mucosectomy and endoanal anastomosis, frequently referred to as a handsewn anastomosis. When the stapled technique is utilized, the ATZ is preserved; whereas a mucosectomy is usually performed from the level of the dentate line, therefore eliminating the ATZ and the proximal cuff of rectal epithelium. While the preservation of the ATZ has been shown to improve functional results and reduce operative time and complications, great debate persists regarding outcomes during recurrent or persistent disease and the theoretical risk of malignant transformation. Given the paucity of data in this realm, the long-term fate of the ATZ in the surgical management of ulcerative colitis has yet to be determined.

### DEFINING THE ATZ

Defining the anatomy of the ATZ is difficult. Fenger first described the ATZ as “the zone interposed between uninterrupted crypt bearing colorectal-type mucosa above and uninterrupted squamous epithelium below”<sup>[1]</sup>, which he characterized utilizing an Alcian dye technique. This technique is used for staining the ATZ macroscopically as the columnar epithelium stains dark blue, the squamous epithelium does not stain, and the ATZ stains pale blue. The Alcian dye technique delineates the margins of the ATZ from 6 mm below to 20 mm above the dentate line<sup>[1]</sup> with the median span from 0.73 to 0.89 cm<sup>[1,2]</sup>. Further studies by Thompson-Fawcett demonstrated that the Alcian dye technique overestimates the length of the ATZ when comparing this to computer mapping of the histological results<sup>[2]</sup>. Using computer histological mapping, the median upper and lower borders of the ATZ, measured from the

### Abstract

Preservation of the anal transition zone has long been a significant source of controversy in the surgical management of ulcerative colitis. The two techniques for restorative proctocolectomy and ileal pouch anal anastomosis (RPC IPAA) in common practice are a stapled anastomosis and a handsewn anastomosis; these techniques differ in the amount of remaining rectal mucosa and therefore the presence of the anal transition zone following surgery. Each technique has advantages and disadvantages in long-term functional outcomes, operative and postoperative complications, and risk of neoplasia. Therefore, we propose a selective approach to performing a stapled RPC IPAA based on the presence of dysplasia in the preoperative endoscopic evaluation.

© 2009 The WJG Press and Baishideng. All rights reserved.

**Key words:** Anal transition zone; Ileal pouch anal anastomosis; Restorative proctocolectomy; Ulcerative colitis

**Peer reviewers:** Ali Keshavarzian, MD, Josephine M. Dyrenforth, Professor of Medicine, Professor of Pharmacology and Molecular Biophysics & Physiology Director, Digestive Diseases and Nutrition Vice Chairman of Medicine for Academic and Research Affairs, Rush University Medical Center, 1725 W. Harrison, Suite 206, Chicago, IL 60612, United States; Hitoshi Asakura, Director, Emeritus Professor, International Medical Information Center, Shinanomachi Renga Bldg. 35, Shinanomachi, Shinjuku, Tokyo 160-0016, Japan

Holder-Murray J, Fichera A. Anal transition zone in the surgical management of ulcerative colitis *World J Gastroenterol* 2009;

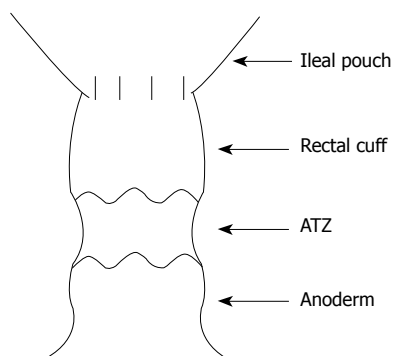


Figure 1 Retained rectal cuff after RPC IPAA.

lower margin of the internal sphincter, were 1.82 and 1.27 cm, respectively, with the dentate line measuring 1.05 cm by histology or 1.16 cm macroscopically above the lower margin of the internal sphincter. The median span was 0.45 cm *versus* 0.73 cm by the Alcian dye technique. This difference in length was accounted for by close examination of the histological specimens. The pale blue zone was due to staining of both superficial nuclei of thin squamous anoderm and the transitional epithelium that characterizes the ATZ. Fenger's technique for analyzing the ATZ did not exactly match the macroscopic Alcian blue specimens to the histological specimens, in comparison to Thompson-Fawcett's computer histological and Alcian dye mapping, and therefore likely overestimated the ATZ.

After careful measurements aided by computer mapping, the ATZ is now recognized to be smaller than previously considered. Significantly, columnar epithelium exists lower in the anorectal canal, and it is left behind when a stapled technique is utilized, which could be of consequence following RPC IPAA (Figure 1).

## PRESERVATION OF THE ATZ: FUNCTIONAL OUTCOMES AND COMPLICATIONS

Duthie and Gairns in 1960 described a vast array of sensory nerve endings in the anal canal<sup>[3]</sup>, which demonstrated sensitivity to temperature, touch, and pain, while the rectal mucosa lacked this innervation and sensation<sup>[3,4]</sup>. The rectum is able to sense distension, however, that results in a brief reflexive relaxation of the internal anal sphincter and contraction of the external anal sphincter, thus allowing the anal mucosa to sample the rectal contents. This sampling is thought to aid the ATZ in discrimination between gas, liquid, and solid stool. Anorectal sensation is abnormal in incontinent patients<sup>[5,6]</sup> and in patients following mucosectomy<sup>[7,8]</sup>. Thus, the extensive innervation of the ATZ is thought to play a very important role in maintaining fecal continence.

Following RPC IPAA *via* stapled or mucosectomy with endoanal anastomosis techniques, patients demonstrate decreased anal resting pressure (ARP)<sup>[9-13]</sup>, thought to occur secondary to the extent of dissection, level of rectal transection, diameter of the stapling

device, and anal retraction. However, ARP is greater following RPC IPAA stapled anastomoses than following mucosectomy with endoanal anastomoses<sup>[8,10,11,14,15]</sup>. Controversy exists regarding improvement of ARP over time when comparing the two surgical techniques. ARP has been demonstrated to return to a normal value by 12 mo after the operation only in RPC IPAA *via* a stapled technique<sup>[9]</sup>, whereas Tuckson *et al* demonstrated no significant improvement in ARP 13 mo after either technique<sup>[10]</sup>. Both these studies analyzed a very small group of patients, with relatively short follow-up.

Functionally, preservation of the ATZ *via* RPC IPAA stapled anastomosis improves clinically relevant outcomes. Three prospective randomized controlled trials were performed in the early 1990s with limited numbers of patients (between 23 and 41 in each study). The results showed only limited benefit for stapled anastomosis with no worse outcomes<sup>[15-17]</sup>. More specifically, Luukkonen *et al* demonstrated no statistically significant differences between the only two functional parameters measured: number of nocturnal bowel movements and frequency of mucous leakage<sup>[17]</sup>. Choen *et al* also argued that many functional parameters showed no differences including frequency of bowel movements, number of nocturnal bowel movements, ability to delay defecation, and full continence<sup>[16]</sup>. However, Reilly *et al* demonstrated trends towards improved functional outcomes in all parameters measured: nocturnal seepage, daytime continence, ability to differentiate stool and flatus, and pad usage<sup>[15]</sup>.

Other studies more clearly outline the functional benefit of stapled anastomoses. Remzi *et al* showed that patients with stapled anastomoses had better outcomes in every functional category measured, including statistically significant differences in incontinence, daytime and nighttime seepage, and pad usage<sup>[18]</sup>. Saigusa *et al* described an improved ability to discriminate between flatus and stool in the stapled *versus* handsewn group, 80% *versus* 33% ( $P < 0.05$ )<sup>[8]</sup>. Michelassi *et al* found that between 57% and 78% of patients were always able to delay a bowel movement until convenient; although this did not differ between the two groups<sup>[19]</sup>. These authors also demonstrated that stapled patients had improved rates of full continence, which persisted over time. Sagar *et al* studied stapled IPAA patients only for 12 mo postoperatively and compared parameters at 3 and 12 mo<sup>[9]</sup>. They showed that not only were functional outcomes better in the stapled IPAA group, but outcomes improved over time. Statistically significant improvements in the number of bowel movements ( $P < 0.001$ ), number of nocturnal bowel movements ( $P < 0.001$ ), frequency of loose stool consistency ( $P < 0.001$ ), use of anti-diarrheal medication ( $P < 0.01$ ), ability to defer defecation for more than 15 min ( $P < 0.001$ ) and ability to discriminate flatus from stool ( $P < 0.001$ ) were demonstrated. A single meta-analysis of 4183 patients (2699 handsewn and 1484 stapled IPAA) demonstrated no significant differences in the number of bowel movements, number of nocturnal bowel movements, daytime seepage, and use of anti-diarrheal

medication<sup>[14]</sup>. However, incontinence was more common in the handsewn group ( $P = 0.009$ ) and the incidence of nocturnal seepage and nocturnal pad usage favored the stapled IPAA group ( $P < 0.001$  and  $P = 0.007$ , respectively). Both groups were rated with a high quality of life with no statistically significant difference between the groups.

Early septic complications can occur following stapled or handsewn IPAA and may include anastomotic dehiscence with diffuse or localized sepsis, abscess, and fistula formation. These septic complications may require prolonged hospitalization, interventional procedures, reoperation, and pouch excision, therefore resulting in increased patient morbidity, prolonged recovery, and loss of bowel continuity. Risk factors for pelvic sepsis include ulcerative colitis, ulcerative colitis associated with toxic megacolon or fulminant colitis, male gender, and a handsewn anastomosis<sup>[20]</sup>. More than a two-fold increase in the rate of septic complications has been reported following handsewn *versus* stapled anastomoses<sup>[14,20,21]</sup>, which results in increased rates of pouch failure requiring permanent diverting ileostomy<sup>[14,20,22]</sup> and more frequent pouch excision<sup>[14,21]</sup>. Pouch failure and pouch excision occur secondary to anastomotic dehiscence, poor functional results, pouchitis, perianal disease, and pouch leakage. Risk factors for pouch failure have been outlined and include handsewn anastomoses, anastomotic tension, use of diverting ileostomy, Crohn's disease, and postoperative anastomotic leak<sup>[22]</sup>. Further supporting the use of a stapled technique, when anastomotic leaks do occur, a better prognosis has been shown following a stapled anastomosis<sup>[20,22]</sup>.

## INFLAMMATION AND DYSPLASIA IN THE ATZ

It is well documented that chronic inflammation may lead to dysplasia and dysplasia may ultimately lead to neoplasia in patients with long-standing ulcerative colitis. The retained ATZ following stapled RPC IPAA is therefore at risk for chronic inflammation from recurrent or persistent disease, dysplasia, and possibly malignancy. The retained ATZ and potentially rectal mucosa is greater in length in the stapled anastomosis patient but can still be present in the handsewn patient due to the variation in location of the ATZ and incomplete transanal mucosectomy<sup>[2,23,24]</sup>.

Inflammation within the ATZ is well documented. In early studies the incidence of endoscopic anal canal inflammation confirmed by biopsy was reported to be as high as 22% as estimated by Lavery *et al*, while the incidence of symptomatic inflammatory changes in the retained mucosa was 14.7%<sup>[25]</sup>. More recent prospective data document the incidence of inflammation following stapled RPC IPAA to be much higher: 4.6% with acute inflammation, 84.9% with chronic inflammation, and only 10.5% with normal mucosa<sup>[26]</sup>. The presence of inflammation, however, does not seem to negatively affect functional outcomes, as our group has reported in a large prospective study of 225 patients, with 96%

of them reporting perfect fecal continence, 5.3% using protective pads, and 93.2% being able to delay a bowel movement for more than 30 min<sup>[26]</sup>. Patients with chronic inflammation of the ATZ still report better functional parameters when compared to handsewn control patients, including statistically significant improved flatus *versus* stool discrimination, decreased protective pad usage, and decreased dietary modification regarding meal timing<sup>[27]</sup>. In addition, patients with chronic inflammation of the retained ATZ more commonly reported an improved quality of life than prior to surgery when compared to handsewn patients ( $P < 0.001$ )<sup>[27]</sup>.

Several studies have published their experience with postoperative serial endoscopic surveillance and the risk of dysplasia following preservation of the ATZ *via* a stapled RPC IPAA. The principal risk factor for developing dysplasia in the ATZ was the presence of dysplasia or cancer in the proctocolectomy specimen, independent of the location; no other factors including age, sex, or duration of disease, appear to increase this risk<sup>[28-31]</sup>. Ziv *et al* reported eight cases of dysplasia in 254 patients with a mean postoperative follow-up of 2.3 years; however, repeat biopsy revealed dysplasia in only two of these patients, who underwent a transanal mucosectomy without evidence of cancer in the final specimen<sup>[28]</sup>. Remzi *et al* analyzed a total of 178 patients with a mean follow-up of more than 10 years and identified dysplasia in only eight patients (4.5%) and no evidence of cancer<sup>[30]</sup>. No dysplasia was identified by our group in 242 patients with a mean follow-up of 56 mo<sup>[27]</sup>. This small disparity in incidence may be explained by variation in patient selection. In our practice, we do not offer a stapled RPC IPAA to patients with documented, and confirmed by two independent pathologists, colorectal dysplasia, irrespective of degree and location. Instead, these patients will undergo a transanal mucosectomy with a handsewn anastomosis<sup>[27]</sup>. We believe that the presence of dysplasia irrespective of degree and location is an indication of "mucosal instability." Since the primary risk factor for developing dysplasia in the ATZ is the presence of dysplasia or cancer in the surgical specimen, we perform a complete mucosectomy in this patient population. Complete absence of dysplasia or cancer in the ATZ in our series after 56 mo of follow-up, supports this approach.

Overall, dysplasia within the ATZ is uncommon and the risk of developing cancer following RPC IPAA is even more unlikely with only 19 reported cases in the literature<sup>[31]</sup> (Table 1). Even following a mucosectomy with endoanal anastomosis, islands of rectal mucosa probably exist at or below the dentate line in at least 20% of patients<sup>[23,24]</sup>. These islands of rectal tissue may not be easily visualized during endoscopic biopsy, and dysplastic or malignant transformation may ultimately be difficult to detect. In fact, of the 19 reported cases of adenocarcinoma, 13 occurred in patients who underwent transanal mucosectomy. Furthermore, six of these patients developed cancer within the pouch itself, raising concern for metaplasia of the pouch as a method for

Table 1 Adenocarcinoma after RPC IPAA for UC<sup>1</sup>

Reference	Yr	RPC IPAA	Preoperative diagnosis	Pathological diagnosis	Yr to CA <sup>2</sup>	Site of carcinoma
Ravitch	1984	HS	NR	NR	NR	NR
Stern	1990	HS	Dysplasia	HGD rectum	3	Pouch
Puthu	1992	NR	NR	NR	6	NR
Rodriguez-Sanjuan	1995	HS	Dysplasia	HGD rectum	3.5	Pouch
Sequens	1997	Stapled	Carcinoma	CA rectum	1	ATZ
Vieth	1998	HS	Carcinoma	CA colon, multifocal dysplasia	2	Pouch
Iwama	2000	HS	UC	LGD	18	Anastomosis
Rotholtz	2001	Stapled	UC	HGD distal margin	7	ATZ
Heuschen	2001	HS	Dysplasia	CA colon	3	Pouch
Laureti	2002	HS	Carcinoma	CA anastomosis	2	Anastomosis
Hyman	2002	Stapled	Dysplasia	HGD distal margin & colon	5	Rectal stump
Baratsis	2002	Stapled	UC	CA cecum, multifocal dysplasia	2	ATZ
Bentrem	2003	HS	UC	CA colon, dysplasia	14	Pouch
Hassan	2003	HS	UC	UC	2	Pouch
Negi	2003	HS	Dysplasia	HGD	5	Rectal stump
Bell	2003	Stapled	Dysplasia	HGD colon	12	Anastomosis
Lee	2005	HS	Dysplasia	HGD rectum	2	Anastomosis
Lee	2005	HS	Dysplasia	CA rectum	6.5	Anastomosis
Lee	2005	HS	UC	UC	16	Rectal stump
Schaffzin	2005	HS	NR	NR	25	Pouch
Knupper	2006	Stapled	UC	NR	3	Pouch
Walker	2006	HS	NR	Dysplastic colon & rectum	17	Pouch
Das	2007	HS	UC	UC	25	ATZ
Ota	2007	HS	NR	UC	7	Rectal stump
Ruffolo	2007	Stapled	Carcinoma	CA colon at two sites	3	ATZ
Koh	2008	Stapled	NR	NR	14	Pouch inlet
Pedersen	2008	HS	HGD	CA colon, dysplastic colon	11	Rectal stump
Chia	2008	Stapled	UC	CA	3	ATZ

<sup>1</sup>Excludes articles not in English and one study using Cavitron Ultrasonic Surgical Aspirator technique for rectal mucosal stripping; <sup>2</sup>Yr to presentation of carcinoma after RPC IPAA; HS: Handsewn anastomosis; Stapled: Stapled anastomosis; NR: Not recorded or unknown; UC: Ulcerative colitis, HGD: High grade dysplasia; CA: Carcinoma; LGD: Low grade dysplasia.

malignant transformation. Yet, Swedish research has demonstrated that although the pouch itself may undergo metaplasia, there has been no progression to carcinoma; dysplasia occurred in less than 4.4% of patients; no high-grade was observed; and experienced pathologists did not even agree on the presence of dysplasia itself<sup>[32]</sup>. None of these patients had documented dysplasia or carcinoma in the surgical specimen preoperatively. When reviewing the cases of carcinoma following RPC IPAA, it is important to note that all but three patients had documented dysplasia or carcinoma within the original surgical specimen<sup>[31]</sup>. Given these data and the extensive evidence for the development of carcinoma in ulcerative colitis patients following dysplastic changes of the colon, we believe that it is appropriate to label dysplasia as a marker for “mucosal instability.” Therefore, it is our belief that the presence of dysplasia or carcinoma, irrespective of the severity or location, should preclude a stapled RPC IPAA.

The presence of dysplasia or malignancy within the ATZ raises concern regarding treatment. Invasive malignancy requires a complete IPAA excision and end ileostomy. On the other hand, clear data regarding management of dysplastic changes within the ATZ do not exist. Dysplasia may even sometimes be self-limiting. Interestingly, several studies have shown regression of low-grade and even high-grade dysplasia to normal mucosa in some patients by serial biopsies<sup>[28,30]</sup>, which is consistent with findings seen in the colon and rectum<sup>[33]</sup>.

Most authors recommend completion mucosectomy with pouch advancement for high-grade dysplasia and for recurrent or persistently positive biopsies of low-grade dysplasia<sup>[28,30]</sup>. Dysplastic changes may be a marker for mucosal instability and the risk of developing carcinoma in this setting should be eradicated.

## CONCLUSION

Preserving the ATZ offers improved long-term function, clinical outcomes, and decreased postoperative complications and pouch failure; however, ATZ preservation carries a small risk for developing dysplasia or malignancy. As a result of the risk of developing dysplasia or cancer, a selective approach to stapled RPC IPAA should be undertaken, based on the presence of dysplasia, irrespective of the location and severity. Stapled RPC IPAA, and therefore preservation of the ATZ, should be reserved for those patients in whom multiple preoperative endoscopic biopsies rule out dysplasia or carcinoma in the entire colon. Transanal mucosectomy and handsewn IPAA should be performed in patients with biopsy-proven dysplasia, irrespective of the location and severity. Due to the significant inter-observer discrepancies noted, the presence of dysplasia should be confirmed by two independent pathologists. If these resection guidelines are utilized, it is believed that cancer risk can be further reduced, especially if postoperative endoscopic surveillance is employed.



## REFERENCES

- 1 **Fenger C.** The anal transitional zone. Location and extent. *Acta Pathol Microbiol Scand* [A] 1979; **87A**: 379-386
- 2 **Thompson-Fawcett MW**, Warren BF, Mortensen NJ. A new look at the anal transitional zone with reference to restorative proctocolectomy and the columnar cuff. *Br J Surg* 1998; **85**: 1517-1521
- 3 **Duthie HL**, Gairns FW. Sensory nerve-endings and sensation in the anal region of man. *Br J Surg* 1960; **47**: 585-595
- 4 **Duthie HL**, Bennett RC. The relation of sensation in the anal canal to the functional anal sphincter: a possible factor in anal continence. *Gut* 1963; **4**: 179-182
- 5 **Miller R**, Bartolo DC, Cervero F, Mortensen NJ. Differences in anal sensation in continent and incontinent patients with perineal descent. *Int J Colorectal Dis* 1989; **4**: 45-49
- 6 **Miller R**, Bartolo DC, Cervero F, Mortensen NJ. Anorectal temperature sensation: a comparison of normal and incontinent patients. *Br J Surg* 1987; **74**: 511-515
- 7 **Miller R**, Bartolo DC, Orrom WJ, Mortensen NJ, Roe AM, Cervero F. Improvement of anal sensation with preservation of the anal transition zone after ileoanal anastomosis for ulcerative colitis. *Dis Colon Rectum* 1990; **33**: 414-418
- 8 **Saigusa N**, Kurahashi T, Nakamura T, Sugimura H, Baba S, Konno H, Nakamura S. Functional outcome of stapled ileal pouch-anal canal anastomosis versus handsewn pouch-anal anastomosis. *Surg Today* 2000; **30**: 575-581
- 9 **Sagar PM**, Holdsworth PJ, Johnston D. Correlation between laboratory findings and clinical outcome after restorative proctocolectomy: serial studies in 20 patients with end-to-end pouch-anal anastomosis. *Br J Surg* 1991; **78**: 67-70
- 10 **Tuckson W**, Lavery I, Fazio V, Oakley J, Church J, Milsom J. Manometric and functional comparison of ileal pouch anal anastomosis with and without anal manipulation. *Am J Surg* 1991; **161**: 90-95; discussion 95-96
- 11 **Johnston D**, Holdsworth PJ, Nasmyth DG, Neal DE, Primrose JN, Womack N, Axon AT. Preservation of the entire anal canal in conservative proctocolectomy for ulcerative colitis: a pilot study comparing end-to-end ileoanal anastomosis without mucosal resection with mucosal proctectomy and endo-anal anastomosis. *Br J Surg* 1987; **74**: 940-944
- 12 **Nasmyth DG**, Johnston D, Godwin PG, Dixon MF, Smith A, Williams NS. Factors influencing bowel function after ileal pouch-anal anastomosis. *Br J Surg* 1986; **73**: 469-473
- 13 **Neal DE**, Williams NS, Johnston D. Rectal, bladder and sexual function after mucosal proctectomy with and without a pelvic reservoir for colitis and polyposis. *Br J Surg* 1982; **69**: 599-604
- 14 **Lovegrove RE**, Constantinides VA, Heriot AG, Athanasiou T, Darzi A, Remzi FH, Nicholls RJ, Fazio VW, Tekkis PP. A comparison of hand-sewn versus stapled ileal pouch anal anastomosis (IPAA) following proctocolectomy: a meta-analysis of 4183 patients. *Ann Surg* 2006; **244**: 18-26
- 15 **Reilly WT**, Pemberton JH, Wolff BG, Nivatvongs S, Devine RM, Litchy WJ, McIntyre PB. Randomized prospective trial comparing ileal pouch-anal anastomosis performed by excising the anal mucosa to ileal pouch-anal anastomosis performed by preserving the anal mucosa. *Ann Surg* 1997; **225**: 666-676; discussion 676-677
- 16 **Choen S**, Tsunoda A, Nicholls RJ. Prospective randomized trial comparing anal function after hand sewn ileoanal anastomosis with mucosectomy versus stapled ileoanal anastomosis without mucosectomy in restorative proctocolectomy. *Br J Surg* 1991; **78**: 430-434
- 17 **Luukkonen P**, Jarvinen H. Stapled vs hand-sutured ileoanal anastomosis in restorative proctocolectomy. A prospective, randomized study. *Arch Surg* 1993; **128**: 437-440
- 18 **Remzi FH**, Church JM, Bast J, Lavery IC, Strong SA, Hull TL, Harris GJ, Delaney CP, O'Riordain MG, McGannon EA, Fazio VW. Mucosectomy vs. stapled ileal pouch-anal anastomosis in patients with familial adenomatous polyposis: functional outcome and neoplasia control. *Dis Colon Rectum* 2001; **44**: 1590-1596
- 19 **Michelassi F**, Lee J, Rubin M, Fichera A, Kasza K, Karrison T, Hurst RD. Long-term functional results after ileal pouch anal restorative proctocolectomy for ulcerative colitis: a prospective observational study. *Ann Surg* 2003; **238**: 433-441; discussion 442-445
- 20 **Fukushima T**, Sugita A, Koganei K, Shinozaki M. The incidence and outcome of pelvic sepsis following handsewn and stapled ileal pouch anal anastomoses. *Surg Today* 2000; **30**: 223-227
- 21 **Ziv Y**, Fazio VW, Church JM, Lavery IC, King TM, Ambrosetti P. Stapled ileal pouch anal anastomoses are safer than handsewn anastomoses in patients with ulcerative colitis. *Am J Surg* 1996; **171**: 320-323
- 22 **MacRae HM**, McLeod RS, Cohen Z, O'Connor BI, Ton EN. Risk factors for pelvic pouch failure. *Dis Colon Rectum* 1997; **40**: 257-262
- 23 **Heppell J**, Weiland LH, Perrault J, Pemberton JH, Telander RL, Beart RW Jr. Fate of the rectal mucosa after rectal mucosectomy and ileoanal anastomosis. *Dis Colon Rectum* 1983; **26**: 768-771
- 24 **O'Connell PR**, Pemberton JH, Weiland LH, Beart RW Jr, Dozois RR, Wolff BG, Telander RL. Does rectal mucosa regenerate after ileoanal anastomosis? *Dis Colon Rectum* 1987; **30**: 1-5
- 25 **Lavery IC**, Sirimarco MT, Ziv Y, Fazio VW. Anal canal inflammation after ileal pouch-anal anastomosis. The need for treatment. *Dis Colon Rectum* 1995; **38**: 803-806
- 26 **Fichera A**, Ragauskaitė L, Silvestri MT, Elisseou NM, Rubin MA, Hurst RD, Michelassi F. Preservation of the anal transition zone in ulcerative colitis. Long-term effects on defecatory function. *J Gastrointest Surg* 2007; **11**: 1647-1652; discussion 1652-1653
- 27 **Silvestri MT**, Hurst RD, Rubin MA, Michelassi F, Fichera A. Chronic inflammatory changes in the anal transition zone after stapled ileal pouch-anal anastomosis: is mucosectomy a superior alternative? *Surgery* 2008; **144**: 533-537; discussion 537-539
- 28 **Ziv Y**, Fazio VW, Sirimarco MT, Lavery IC, Goldblum JR, Petras RE. Incidence, risk factors, and treatment of dysplasia in the anal transitional zone after ileal pouch-anal anastomosis. *Dis Colon Rectum* 1994; **37**: 1281-1285
- 29 **Ziv Y**, Fazio VW, Strong SA, Oakley JR, Milsom JW, Lavery IC. Ulcerative colitis and coexisting colorectal cancer: recurrence rate after restorative proctocolectomy. *Ann Surg Oncol* 1994; **1**: 512-515
- 30 **Remzi FH**, Fazio VW, Delaney CP, Preen M, Ormsby A, Bast J, O'Riordain MG, Strong SA, Church JM, Petras RE, Gramlich T, Lavery IC. Dysplasia of the anal transitional zone after ileal pouch-anal anastomosis: results of prospective evaluation after a minimum of ten years. *Dis Colon Rectum* 2003; **46**: 6-13
- 31 **Lee SW**, Sonoda T, Milsom JW. Three cases of adenocarcinoma following restorative proctocolectomy with hand-sewn anastomosis for ulcerative colitis: a review of reported cases in the literature. *Colorectal Dis* 2005; **7**: 591-597
- 32 **Borjesson L**, Willen R, Haboubi N, Duff SE, Hulten L. The risk of dysplasia and cancer in the ileal pouch mucosa after restorative proctocolectomy for ulcerative proctocolitis is low: a long-term term follow-up study. *Colorectal Dis* 2004; **6**: 494-498
- 33 **Woolrich AJ**, DaSilva MD, Korelitz BI. Surveillance in the routine management of ulcerative colitis: the predictive value of low-grade dysplasia. *Gastroenterology* 1992; **103**: 431-438