

• BRIEF REPORTS •

# Ischemic preconditioning protects liver from hepatectomy under hepatic inflow occlusion for hepatocellular carcinoma patients with cirrhosis

Shao-Qiang Li, Li-Jian Liang, Jie-Fu Huang, Zhi Li

**Shao-Qiang Li, Li-Lian Liang, Jie-Fu Huang**, Department of Hepatobiliary Surgery, the First Affiliated Hospital, Sun Yat-sen University, Guangzhou 510080, Guangdong Province, China

**Zhi Li**, Department of Pathology, Sun Yat-sen University, Guangzhou 510080, Guangdong Province, China

**Correspondence to:** Professor Li-Jian Liang, MD, PhD. Department of Hepatobiliary Surgery, the First Affiliated Hospital, Sun Yat-sen University, Guangzhou 510080, Guangdong Province, China. lianglijian@163.net

**Telephone:** +86-20-87755766 Ext. 8096

**Fax:** +86-20-87755766 Ext. 8663

**Received:** 2003-11-27 **Accepted:** 2003-12-22

## Abstract

**AIM:** To investigate the protective effect of ischemic preconditioning (IPC) on hepatocellular carcinoma (HCC) patients with cirrhosis undergoing hepatic resection under hepatic inflow occlusion (HIO) and its possible mechanism.

**METHODS:** Twenty-nine consecutive patients with resectable HCC were randomized into two groups: IPC group: before HIO, IPC with 5 min of ischemia and 5 min of reperfusion was given; control group: no IPC was given. Liver functions, hepatic Caspase-3 activity, and apoptotic cells were compared between these two groups.

**RESULTS:** On postoperative days (POD) 1, 3 and 7, the aspartate transaminase (AST) and alanine transaminase (ALT) levels in the IPC group were significantly lower than those in the control group ( $P < 0.05$ ). On POD 3 and 7, the total bilirubin level in the IPC group was significantly lower than that in the control group ( $P < 0.05$ ). On POD 1, the albumin level in the IPC group was higher than that in the control group ( $P = 0.053$ ). After 1 h of reperfusion, both hepatic Caspase-3 activity and apoptotic sinusoidal endothelial cells in the IPC group were significantly lower than those in the control group ( $P < 0.05$ ).

**CONCLUSION:** IPC has a potential protective effect on HCC patients with cirrhosis. Its protective mechanism underlying the suppression of sinusoidal endothelial cell apoptosis is achieved by inhibiting Caspase-3 activity.

Li SQ, Liang LJ, Huang JF, Li Z. Ischemic preconditioning protects liver from hepatectomy under hepatic inflow occlusion for hepatocellular carcinoma patients with cirrhosis. *World J Gastroenterol* 2004; 10(17): 2580-2584

<http://www.wjgnet.com/1007-9327/10/2580.asp>

## INTRODUCTION

Hepatic inflow occlusion (HIO), also called Pringle's maneuver<sup>[1]</sup>, is an effective and simple technique to control blood loss from the raw surface during hepatic parenchymal transaction, and

has been widely used during hepatectomy. However, HIO could also result in hepatic ischemic-reperfusion (I/R) injury, especially in case of cirrhosis. It is generally accepted that cirrhotic liver is particularly sensitive to ischemia. Although warm ischemia for cirrhotic liver should not exceed 30 min<sup>[2]</sup>, prolonged HIO might cause dysfunction of the remnant liver, which was a major risk factor associated with postoperative morbidity and mortality<sup>[3]</sup>. Therefore, therapeutic modalities to ameliorate this injury are critically important in liver surgery.

Ischemic preconditioning (IPC), defined as giving a short period of ischemia and reperfusion and subsequently sustaining a prolonged ischemic insult, was first described by Murry *et al.*<sup>[4]</sup> in 1986, and then this protective phenomenon was found in various visceral organs including the liver<sup>[5-9]</sup>.

However, up to now, the data of IPC available were most focused on animal models. Recently, Clavien *et al.*<sup>[10]</sup> reported the first clinical trial, suggesting a beneficial effect of IPC during major hepatectomy on patients who were subjected to 30 min of ischemia. But there was no cirrhotic case in Clavien's series. In China and other Asia areas, more than 80% of hepatocellular carcinoma (HCC) patients had underlying cirrhosis or hepatitis due to hepatitis B virus infection<sup>[11]</sup>. Whether IPC has the similar protective effect on I/R injury encountered in hepatectomy for cirrhotic liver is unclear. Hence, we conducted this prospective randomized clinical trial on cirrhotic HCC patients to test whether IPC could protect cirrhotic liver against I/R injury during tumor resection under HIO, and to explore its possible protective mechanism.

## MATERIALS AND METHODS

### Patients

Fifty-six consecutive patients with HCC were treated at the Department of Hepatobiliary Surgery, the First Affiliated Hospital of Sun Yat-Sen University between January 1, 2001 and April 30, 2001. Among them, 29 patients whose tumors were considered to be resectable after preoperative investigations, including liver function tests, liver function reserve (oral glucose tolerance test, OGTT)<sup>[12]</sup>, abdominal ultrasound, CT assessment and laparotomy, were recruited in this study. The resectable criteria we used were as follows. (1) The general condition of the patients was good and they could tolerate hepatectomy. (2) The tumor did not extend beyond half of the liver and had no distant metastasis. (3) Liver function belonged to Child A or B and liver function reserve was type P<sub>1</sub> or P<sub>2</sub> according to OGTT, which is a test widely used to evaluate liver function reserve<sup>[12]</sup>. Briefly, patients were fasted overnight, and the fast blood glucose (FBS) was measured next morning, then 75 g of glucose diluted in pure water was given to the patients orally. One and 2 h after glucose solution was drunk, blood glucose concentration (BGC) was measured respectively. If BGC after 2 h was still higher than that after 1 h, it was the linear type (L type). If BGC after 2 h was between the FBS and that after 1 h, it was the parabolic type 2 (P<sub>2</sub> type). If BGC after 2 h was lower than 7.3 μmol/L, it was parabolic type 1 (P<sub>1</sub> type). P<sub>1</sub> type indicated the best liver function reserve, and patients could tolerate right

or left hepatectomy. P<sub>2</sub> type was moderate, and patients could tolerate segmentectomy or irregular hepatectomy. L type indicated the poor liver function reserve, and patients could only tolerate local tumor resection. The other 27 unresectable cases were excluded.

Then 29 resectable cases were randomized into IPC group ( $n = 14$ ) and control group groups ( $n = 15$ ) by permuted block without stratification. Our previous study indicated that IPC with 5 min of ischemia and 5 min of reperfusion produced the best protection on cirrhotic rat liver I/R model<sup>[13]</sup>. Therefore, IPC with these time intervals was applied in these patients. Prior to liver parenchymal transection under HIO, IPC with 5 min of ischemia and 5 min of reperfusion was conducted in the IPC group. No IPC was given prior to liver parenchymal transection performed under HIO in the control group.

This protocol was performed under the consent of patients approved by the Ethical Committee of Sun Yat-sen University.

### Procedures and biopsy

General anesthesia was performed. Bilateral subcostal incision was made. A further abdominal exploration was conducted to exclude intra-abdominal metastasis. After mobilization of the liver prior to parenchymal transection, HIO was achieved by clamping the portal pedicles using a tourniquet. Blood inflow was initiated when hemostasis was achieved after removal of the tumor. The procedures available in these patients included irregular hepatectomy, segmentectomy and right/left hepatectomy according to the tumor's location and liver function tests. Liver parenchyma was transected by diathermy and crushing hepatic tissue with an artery forceps. Tubular structures on the raw surface were divided and ligated. All hepatectomies were finished within one time of HIO in our series, and the time of HIO not including the ischemic phase of IPC in the IPC group were recorded. Intraoperative blood loss was accurately calculated from the suction bottles and surgical pads. No cell saver was used in our series. Before HIO and 1 h after reperfusion, a small piece of liver tissue was harvested by wedge resection in remnant liver. The procedures were performed by the same surgical team.

### Liver function test

Peripheral blood was sampled before operation and on postoperative days (POD) 1, 3, 7. Aspartate transaminase (AST), alanine transaminase (ALT), total bilirubin (TBIL), albumin (ALB) were measured using an auto biochemical analyzer (HITACHI 7170A, Japan).

### Hepatic Caspase-3 activity assay

Caspase-3 activity was quantified by proteolytic cleavage of the fluorogenic substrate 7-amino-4-trifluoro-methylcoumarin-conjugated Asp-Glu-Val-Asp tetrapeptide (AMC-DEVD)<sup>[14]</sup>. Briefly, fresh liver tissue (20 mg) was homogenized in a lysis buffer at 4 °C. After 4 times of freezing and thawing, lysates were centrifuged at 15 000 *g* for 10 min, supernatants were collected. Then Caspase-3 activity was measured using a fluorescence spectrophotometer (HITACHI F-3 010, Japan) and a Caspase-3 fluorescent kit (Sigma Co. USA) according to the manufacturer's instructions. Caspase-3 activity was expressed as nmol AMC release per hour per mg liver tissue.

### TUNEL assay

Apoptosis was detected by terminal deoxynucleotidyl mediated nick end labeling (TUNEL) assay<sup>[15]</sup>. Paraffin-embedded liver tissue was cut into 5- $\mu$ m thick sections. After deparaffinized in series of alcohol solutions, a TUNEL kit (Boehringer Mannheim Co. Germany) was used according to the manufacturer's protocols. Five high power fields ( $\times 400$ ) were selected randomly in each specimen, for which apoptotic cells were calculated by a pathologist.

### Statistical analysis

Data are expressed as mean $\pm$ SD. Means were compared between these two groups by *t* test (continuous data) or chi-square test (categorical data). *P* value less than 0.05 was considered statistically significant.

## RESULTS

### Clinical characteristics of these two groups

The clinical characteristics (Table 1) including age, gender, Child's classification, tumor size, operation procedure, operation time, liver ischemic time and blood loss were compared between these two groups, and there was no statistical significance, indicating that the characteristics of the two groups were homogeneous and comparable.

**Table 1** clinical characteristics of these two groups

Data	IPC group	control group	<i>P</i> value
Age (yr)	50.4 $\pm$ 10.7	49.5 $\pm$ 10.3	0.605
Gender			0.684
Male	12	12	
Female	2	3	
Child's classification			0.684
Grade A	12	12	
Grade B	2	3	
Grade C	0	0	
OGTT			0.867
P <sub>1</sub> type	3	4	
P <sub>2</sub> type	8	9	
L type	4	3	
Cirrhosis <sup>1</sup>			0.316
(+)	13	12	
(-)	1	3	
Tumor size (cm)	7.1 $\pm$ 3.6	7.9 $\pm$ 2.9	0.544
Procedures			0.971
Right/left hepatectomy	2	2	
Segmentectomy	4	4	
Irregular hepatectomy	8	9	
Operation times (min)	191.3 $\pm$ 74.9	208.2 $\pm$ 45.3	0.485
Ischemic times (min)	18.0 $\pm$ 3.6	17.4 $\pm$ 2.3	0.602
(Range)	(15-25)	(13-22)	
Blood loss (mL)	469.2 $\pm$ 292.6	602.0 $\pm$ 310.6	0.257

<sup>1</sup>Cirrhosis: (+) refers to macroscopic cirrhosis, which was diagnosed during surgery, (-) refers to that we could not diagnose cirrhosis during surgery by naked eyes, however, it was diagnosed mild cirrhosis and hepatitis by microscopic pathology. The etiology of cirrhosis was hepatitis B virus infection in our series.

### IPC protected cirrhotic liver from I/R injury

Serum AST and ALT levels were sensitive parameters to assess the severity of liver injury. As shown in Table 2, on postoperative d 1, 3, 7, the AST and ALT levels in the IPC group were significantly lower than those in the control group ( $P < 0.05$ ). On postoperative d 3, 7, the TBIL levels in the IPC group were also lower than those in the control group ( $P < 0.05$ ). On postoperative d 1, the ALB level in the IPC group was higher than that in the control group, but it did not reach statistical significance. These data suggest that IPC could effectively protect cirrhotic liver from I/R injury. I/R injury could inhibit albumin synthesis, however IPC could ameliorate this albumin-synthesis inhibition.

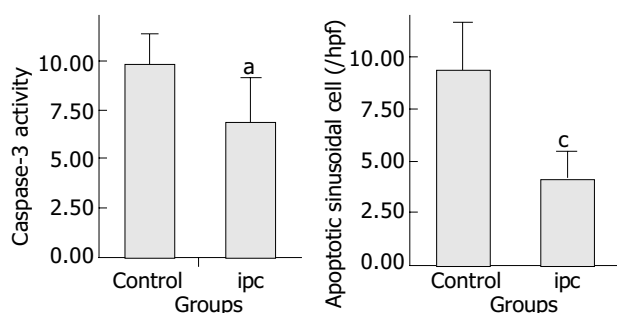
**Table 2** Comparison of liver functions between two groups before and after operation

Date	AST (U/L)		ALT (U/L)		TBIL ( $\mu\text{mol/L}$ )		ALB (g/L)	
	Control	IPC	Control	IPC	Control	IPC	Control	IPC
Preop	64.7 $\pm$ 39.2	60.1 $\pm$ 55.4	56.7 $\pm$ 53.9	54.8 $\pm$ 45.0	22.6 $\pm$ 13.1	18.9 $\pm$ 7.4	41.2 $\pm$ 5.6	40.6 $\pm$ 3.7
POD1	1856.4 $\pm$ 310.9	433.8 $\pm$ 143.8 <sup>b</sup>	802.9 $\pm$ 280.1	430.9 $\pm$ 179.4 <sup>b</sup>	33.1 $\pm$ 23.9	26.7 $\pm$ 10.3	32.9 $\pm$ 4.6	36.2 $\pm$ 3.9
POD 3	409.6 $\pm$ 197.4	156.7 $\pm$ 52.5 <sup>b</sup>	417.3 $\pm$ 162.6	200.9 $\pm$ 88.6 <sup>b</sup>	49.1 $\pm$ 35.4	25.9 $\pm$ 9.2 <sup>a</sup>		
POD 7	85.3 $\pm$ 45.5	56.5 $\pm$ 18.9 <sup>a</sup>	130.1 $\pm$ 49.0	89.9 $\pm$ 42.8 <sup>a</sup>	39.7 $\pm$ 29.3	22.8 $\pm$ 8.0 <sup>a</sup>		

Note: preop = preoperation. <sup>a</sup> $P < 0.05$ , vs control (independent  $t$  test); <sup>b</sup> $P < 0.01$ , vs control (independent  $t$  test).

### Postoperative mortality, morbidity and hospitalized days

There was no operative and hospital mortality in both groups. The common postoperative morbidity was pleural effusion and liver failure. Pleural effusion was confirmed by chest X-ray. Postoperative liver failure was defined as the total bilirubin was higher than 2 times of its normal level, and massive ascites occurred. Pleural effusion occurred in 2 cases (14.3%) of the IPC group, and in 5 cases (33.3%) of the control group ( $P = 0.390$ ), who needed repeated pleural tapping. No in the IPC group was complicated with liver failure after surgery. However, liver failure occurred in 3 cases of the control group after operation. These 3 patients recovered after conservative treatment. Other postoperative complications including subphrenic collection were found in 2 cases of the control group, who were treated by fine needle aspiration guided by ultrasound. Bile leakage from the transection surface was found in 1 case of the IPC group, who was cured by local drainage. No wound infection occurred in both groups. The mean hospitalized time of the IPC group was 12.8 d, which was significantly shorter than that of the control group (12.8 $\pm$ 3.1 d vs 18.6 $\pm$ 9.1 d,  $P = 0.034$ ).



**Figure 1** Comparison of Caspase-3 activity and SEC apoptosis between control group and IPC group <sup>a</sup> $P = 0.047$ , vs control, <sup>c</sup> $P = 0.002$ , vs control, ( $t$  test) (caspase-3 activity unit: nmol AMC · h<sup>-1</sup> · mg<sup>-1</sup> (tissue)) hpf: high power field.

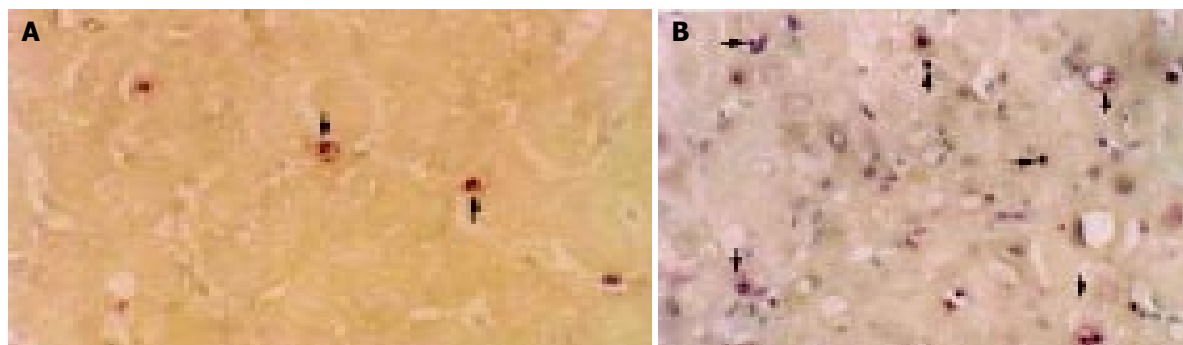
### Effect of IPC on Caspase-3 activity and apoptosis

To investigate the effect of IPC on Caspase-3 activity and apoptosis, 5 cases in each group were selected prospectively, whose hepatic Caspase-3 activity and apoptotic cells were detected respectively. One hour after reperfusion, the hepatic Caspase-3 activity in the IPC group was significantly lower than that in the control group ( $P < 0.05$ ), and subsequently, the apoptotic sinusoidal endothelial cells (SECs) in the IPC group were also less than those in the control group ( $P < 0.05$ ) (Figures 1, 2). Only few hepatocytes underwent apoptosis in the control group in this checking time point (Figure 2). These data indicated that IPC inhibited Caspase-3 activity and subsequently SEC apoptosis in the remnant liver.

### DISCUSSION

Hemorrhage is the major lethal factor during hepatic resection. Hemostasis can be achieved by HIO or total vascular occlusion. The latter nevertheless was the safe choice for patients whose tumor involved major hepatic veins and inferior vena cava<sup>[16]</sup>. But clinically, the vast majority of liver resections do not need this method for its detrimental effect of systemic circulation disturbance. HIO or Pringle's maneuver, which has the least hemodynamic effect, has been widely used in liver surgery<sup>[17]</sup>. However, HIO could also result in liver I/R injury, which is one of the major factors leading to postoperative liver dysfunction. Cirrhotic liver is very vulnerable to ischemic injury. Though warm ischemia for cirrhotic liver should not exceed 30 min, and the majority of liver resections could be finished within this limit interval by using diathermy and crushing hepatic tissue with an artery forceps, the deleterious effect of ischemia could not be neglected. In order to minimize liver I/R injury, intermittent hepatic inflow occlusion (iHIO) has been used in HCC resection<sup>[18,19]</sup>. However, massive bleeding might result from iHIO during reperfusion interval, which might increase blood transfusion and the possibility of postoperative morbidity and tumor recurrence<sup>[20]</sup>.

Our results demonstrated that HIO could cause massive



**Figure 2** Typical features of apoptosis after 1 h of reperfusion (TUNEL assay,  $\times 200$ ). Bold arrows show the SEC apoptosis and the black arrows indicate scanty of hepatocyte apoptosis. A: IPC group, B: control group.

liver injury and inhibit albumin synthesis in cirrhotic patients. However, IPC could significantly protect cirrhotic liver from I/R injury during hepatic resection under hepatic inflow occlusion in cirrhotic HCC patients. These were represented by a dramatically decrease in postoperative AST, ALT and TBIL levels; a relatively higher serum albumin level; an uneventful postoperative course and a relatively short hospital stay in the IPC group.

IPC is a simple procedure, which can produce dramatic protective effect on I/R injury. However, its clinical application is rare.

The protective mechanism of IPC has not been fully understood. Intrinsic nitric oxide (NO) synthesis, adenosine release<sup>[18]</sup> and decreasing leukocyte/endothelial cell interactions<sup>[21]</sup> have been reported to be the protective mechanisms underlying I/R injury.

Apoptosis, or programmed cell death, which is a distinct form of cell death from necrosis, has been documented to be a pivotal mechanism responsible for I/R injury encountered in liver surgery and liver graft preservation<sup>[22-25]</sup>. However, this cell pathology was challenged by other authors, who documented that cell necrosis was the major cell death in rat liver I/R model subjected to 60 or 120 min of ischemia<sup>[26]</sup>. Jaeschke *et al.*<sup>[27]</sup>, believed that both apoptosis and necrosis occurred in liver I/R. Actually, in our previous cirrhotic rat liver I/R model, we used H&E staining, TUNEL assay and electron microscope to investigate the cellular pathology, and found that there was no obvious necrosis but massive hepatocyte apoptosis mediated by Fas apoptotic pathway subjected to 30 min of liver ischemia and 6 h of reperfusion<sup>[28]</sup>. This discrepancy might be due to the different time of ischemia and reperfusion used in each experiment.

In this clinical trial, we found that the major cell type undergoing apoptosis in the control group was SECs subjected to 1 h of reperfusion, only a few apoptotic hepatocytes were found at this checking time point. However, in our previous animal model<sup>[28]</sup>, after 6 h of reperfusion, massive apoptotic hepatocytes were seen, indicating that the cell type undergoing apoptosis might be time dependent. In the rat liver cell apoptosis model induced by intraperitoneal injection of Fas antibody<sup>[29]</sup> and liver graft cold I/R model<sup>[25]</sup>, 1 h after antibody administration or reperfusion, SEC apoptosis was predominant. However, 2 to 6 h after antibody administration or reperfusion, hepatocytes were the major cell type undergoing apoptosis. Though we did not check apoptosis after 6 h of reperfusion in this clinical trial, we believed that during this period of time, hepatocytes might undergo apoptosis predominantly, thus subsequently resulting in liver injury and clinical manifestations.

As to the cellular mechanism of IPC related to apoptosis, Yadav *et al.*<sup>[30]</sup>, reported that the protective mechanism of IPC underlying hepatocyte and SEC apoptosis was achieved by inhibiting Caspase-3. It has been found that caspase-3 is a cysteine specific protease, an "executor" leading to DNA fragmentation in apoptotic signal cascades<sup>[31]</sup>. We demonstrated that IPC could protect cirrhotic liver from I/R injury by inhibiting hepatocyte and SEC apoptosis through down-regulation of Fas expression and suppression of Caspase-3 activity in cirrhotic rat liver I/R model<sup>[13]</sup>. In this study, we demonstrated again that the protective mechanism of IPC against liver I/R injury in cirrhotic patients was achieved by inhibiting Caspase-3 activity and subsequently apoptosis.

Why IPC down-regulates Caspase-3 activity is still under investigation. IPC could result in inhibition of intrinsic NO synthesis. *In vitro* and *in vivo* studies indicated that NO could inhibit Caspase-3 by S-nitrosation in Cys-163 residue of Caspase-3<sup>[32]</sup>.

In conclusion, IPC can protect potentially cirrhotic liver against I/R injury when hepatic resection is performed under hepatic inflow occlusion in HCC patients with cirrhosis. Its protective mechanism underlying SEC apoptosis is achieved

by inhibiting caspase-3 activity. IPC is a simple procedure with a potential protective effect, and it is recommended for clinical application.

## REFERENCES

- 1 **Pringle JH.** Notes on the arrest of hepatic hemorrhage due to trauma. *Ann Surg* 1908; **48**: 541-549
- 2 **Nagasue N, Uchida M, Kubota H, Hayashi T, Kohno H, Nakamura T.** Cirrhotic livers can tolerate 30 minutes ischaemia at normal environmental temperature. *Eur J Surg* 1995; **161**: 181-186
- 3 **Belghiti J, Noun R, Zante E, Ballet T, Sauvanet A.** Portal triad clamping or hepatic vascular exclusion for major liver resection. A controlled study. *Ann Surg* 1996; **224**: 155-161
- 4 **Murry CE, Jennings RB, Reimer KA.** Preconditioning with ischemia: a delay of lethal cell injury in ischemic myocardium. *Circulation* 1986; **74**: 1124-1136
- 5 **Karck M, Tanaka S, Bolling SF, Simon A, Su TP, Oeltgen PR, Haverich A.** Myocardial protection by ischemic preconditioning and delta-opioid receptor activation in the isolated working rat heart. *J Thorac Cardiovasc Surg* 2001; **122**: 986-992
- 6 **Sola A, De Oca J, Gonzalez R, Prats N, Rosello-Catafau J, Gelpi E, Jaurrieta E, Hotter G.** Protective effect of ischemic preconditioning on cold preservation and reperfusion injury associated with rat intestinal transplantation. *Ann Surg* 2001; **234**: 98-106
- 7 **Ogawa T, Mimura Y, Hiki N, Kanauchi H, Kaminishi M.** Ischaemic preconditioning ameliorates functional disturbance and impaired renal perfusion in rat ischaemia-reperfused kidneys. *Clin Exp Pharmacol Physiol* 2000; **27**: 997-1001
- 8 **Peralta C, Prats N, Xaus C, Gelpi E, Rosello-Catafau J.** Protective effect of liver ischemic preconditioning on liver and lung injury induced by hepatic ischemia-reperfusion in the rat. *Hepatology* 1999; **30**: 1481-1489
- 9 **Yoshizumi T, Yanaga K, Soejima Y, Maeda T, Uchiyama H, Sugimachi K.** Amelioration of liver injury by ischaemic preconditioning. *Br J Surg* 1998; **85**: 1636-1640
- 10 **Clavien PA, Yadav S, Sindram D, Bentley RC.** Protective effects of ischemic preconditioning for liver resection performed under inflow occlusion in humans. *Ann Surg* 2000; **232**: 155-162
- 11 **Tang ZY, Yu YQ, Zhou XD, Ma ZC, Yang R, Lu JZ, Lin ZY, Yang BH.** Surgery of small hepatocellular carcinoma. Analysis of 144 cases. *Cancer* 1989; **64**: 536-541
- 12 **Lü MD, Huang JF, Liang LJ, Peng BG.** Oral glucose tolerance test and glucagons loading test as useful parameters for evaluating liver functional reserve. *Zhonghua Waike Zazhi* 1993; **31**: 532-534
- 13 **Li SQ, Liang LJ, Huang JF.** Effects of ischemic preconditioning on hepatocyte apoptosis induced by hepatic ischemia-reperfusion in cirrhotic rats. *Zhongguo Bingli Shengli Zazhi* 2002; **18**: 55-58
- 14 **Enari M, Talanian RV, Wong WW, Nagata S.** Sequential activation of ICE-like and CPP32-like proteases during Fas-mediated apoptosis. *Nature* 1996; **380**: 723-726
- 15 **Gavrieli Y, Sherman Y, Ben-Sasson SA.** Identification of programmed cell death in situ via specific labeling of nuclear DNA fragmentation. *J Cell Biol* 1992; **119**: 493-501
- 16 **Huguet C, Gavelli A, Chieco PA, Bona S, Harb J, Joseph JM, Jobard J, Gramaglia M, Lasserre M.** Liver ischemia for hepatic resection: where is the limit? *Surgery* 1992; **111**: 251-259
- 17 **Man K, Fan ST, Ng IO, Lo CM, Liu CL, Wong J.** Prospective evaluation of Pringle maneuver in hepatectomy for liver tumors by a randomized study. *Ann Surg* 1997; **226**: 704-713
- 18 **Selzner N, Rudiger H, Graf R, Clavien PA.** Protective strategies against ischemic injury of the liver. *Gastroenterology* 2003; **125**: 917-936
- 19 **Belghiti J, Noun R, Malafosse R, Jagot P, Sauvanet A, Pierangeli F, Marty J, Farges O.** Continuous versus intermittent portal triad clamping for liver resection: a controlled study. *Ann Surg* 1999; **229**: 369-375
- 20 **Asahara T, Katayama K, Itamoto T, Yano M, Hino H, Okamoto Y, Nakahara H, Dohi K, Moriaki K, Yuge O.** Perioperative blood transfusion as a prognostic indicator in patients with

- hepatocellular carcinoma. *World J Surg* 1999; **23**: 676-680
- 21 **Cheng XD**, Jiang XC, Liu YB, Peng CH, Xu B, Peng SY. Effect of ischemic preconditioning on P-selectin expression in hepatocytes of rats with cirrhotic ischemia-reperfusion injury. *World J Gastroenterol* 2003; **9**: 2289-2292
- 22 **Kohli V**, Selzner M, Madden JF, Bentley RC, Clavien PA. Endothelial cell and hepatocyte deaths occur by apoptosis after ischemia-reperfusion injury in the rat liver. *Transplantation* 1999; **67**: 1099-1105
- 23 **Gao W**, Bentley RC, Madden JF, Clavien PA. Apoptosis of sinusoidal endothelial cells is a critical mechanism of preservation injury in rat liver transplantation. *Hepatology* 1998; **27**: 1652-1660
- 24 **Sasaki H**, Matsuno T, Tanaka N, Orita K. Activation of apoptosis during the reperfusion phase after rat liver ischemia. *Transplant Proc* 1996; **28**: 1908-1909
- 25 **Natori S**, Selzner M, Valentino KL, Fritz LC, Srinivasan A, Clavien PA, Gores GJ. Apoptosis of sinusoidal endothelial cells occurs during liver preservation injury by a caspase-dependent mechanism. *Transplantation* 1999; **68**: 89-96
- 26 **Gujral JS**, Bucci TJ, Farhood A, Jaeschke H. Mechanism of cell death during warm hepatic ischemia-reperfusion in rats: apoptosis or necrosis? *Hepatology* 2001; **33**: 397-405
- 27 **Jaeschke H**, Lemasters JJ. Apoptosis versus oncotic necrosis in hepatic ischemia/reperfusion injury. *Gastroenterology* 2003; **125**: 1246-1257
- 28 **Li SQ**, Liang LJ, Huang JF, Li Z. Hepatocyte apoptosis induced by hepatic ischemia-reperfusion injury in cirrhotic rats. *Hepatobiliary Pancreat Dis Int* 2003; **2**: 102-105
- 29 **Wanner GA**, Mica L, Wanner-Schmid E, Kolb SA, Hentze H, Trentz O, Ertel W. Inhibition of caspase activity prevents CD95-mediated hepatic microvascular perfusion failure and restores Kupffer cell clearance capacity. *FASEB J* 1999; **13**: 1239-1248
- 30 **Yadav SS**, Sindram D, Perry DK, Clavien PA. Ischemic preconditioning protects the mouse liver by inhibition of apoptosis through a caspase-dependent pathway. *Hepatology* 1999; **30**: 1223-1231
- 31 **Schulz JB**, Weller M, Moskowitz MA. Caspases as treatment targets in stroke and neurodegenerative diseases. *Ann Neurol* 1999; **45**: 421-429
- 32 **Rossig L**, Fichtlscherer B, Breitschopf K, Haendeler J, Zeiher AM, Mulsch A, Dimmeler S. Nitric oxide inhibits caspase-3 by S-nitrosation *in vivo*. *J Biol Chem* 1999; **274**: 6823-6826

Edited by Wang XL and Xu FM