

Significance of perigastric lymph node involvement in periampullary malignant tumor

De-Qing Mu, You-Shu Peng, Feng-Guo Wang, Qiao-Jian Xu

De-Qing Mu, You-Shu Peng, Department of Surgery of the Second Affiliated Hospital, Medical College of Zhejiang University, Hangzhou 3100031, Zhejiang Province, China

Feng-Guo Wang, Department of Pathology of the Second Affiliated Hospital, Medical College of Zhejiang University, Hangzhou 310009, Zhejiang Province, China

Qiao-Jian Xu, Undergraduate Medical College of Zhejiang University, Hangzhou 310009, Zhejiang Province, China

Correspondence to: Dr. De-Qing Mu, Department of Surgery of the Second Affiliated Hospital, Medical College of Zhejiang University, Hangzhou 310009, Zhejiang Province, China. samier-1969@163.com
Telephone: +86-571-87783762

Received: 2003-05-11 **Accepted:** 2003-06-27

Abstract

AIM: To determine the perigastric lymph node involvement in periampullar tumors, in an attempt to optimize the surgical treatment of pylorus- preserving pancreatoduodenectomy.

METHODS: We retrospectively investigated the frequency of lymph nodes involvement in perigastric regions. Distribution and number of involved lymph nodes were examined from 112 patients with carcinoma of pancreas, 59 patients with distal bile duct carcinoma, and 41 patients with carcinoma of the papilla of Vater.

RESULTS: The frequency of lymphatic spread of carcinoma in pancreas; distal bile duct and papilla of Vater was 18.7%, 1.9%, 2.5% respectively. With regard to the mode of lymphatic spread in perigastric region, Infrapyloric nodes of carcinoma of the head of pancreas predominated over others, in carcinomas of the distal bile duct and the papilla of Vater, the left gastric artery, and the greater curvature lymph nodes was the only sole sites, respectively.

CONCLUSION: Understanding perigastric lymphatic involvement in periampullary tumors may be helpful for choosing the appropriate surgical approaches to pancreatoduodenectomy with preservation of pylorus.

Mu DQ, Peng YS, Wang FG, Xu QJ. Significance of perigastric lymph node involvement in periampullary malignant tumor. *World J Gastroenterol* 2004; 10(4): 614-616
<http://www.wjgnet.com/1007-9327/10/614.asp>

INTRODUCTION

Since the first pancreaticoduodenectomy was successfully performed, there have been many controversies^[1-3] among surgeons about the preservation of pylorus during pancreatoduodenectomy is the adequate strategy in periampullar malignant tumors. Usually the decision of pylorus-preserving is decided by the presence or absence of positive lymph node involvement in the perigastric lymph nodes. The goal of our study is to determine the perigastric lymph node involvement in periampullary tumors and to perform appropriate surgical

procedures for “periampullary tumors”.

MATERIALS AND METHODS

Materials

Specimens obtained from 112 patients with carcinoma of the pancreas of head including 23 cases of small carcinoma of pancreas, 51 patients of carcinoma of distal bile duct, 41 cases of carcinoma of the papilla of Vater. They all underwent consecutive resection at our Department of Surgery between January 1990 to December 2000. The 112 patients with carcinoma of pancreas were composed of 79 men and 33 women with a mean age of 67 years (range 41 to 73 years). The 51 patients with carcinoma of the distal bile duct were composed of 39 men and 12 women averaging at age of 61 years (range 39-81 years). The 41 patients with carcinoma of the papilla of Vater were composed of 27 men and 14 women averaging at age of 69.4 years (rang 47-79 years).

Methods

Patients with periampullar malignant tumors received radical operation. Primary group (N1) and secondary group (N2) lymph nodes were cleared together with neighboring connective tissue. The tertiary group(N3) lymph nodes with neighboring connective were appropriately cleared (Figures 1A and 1B).

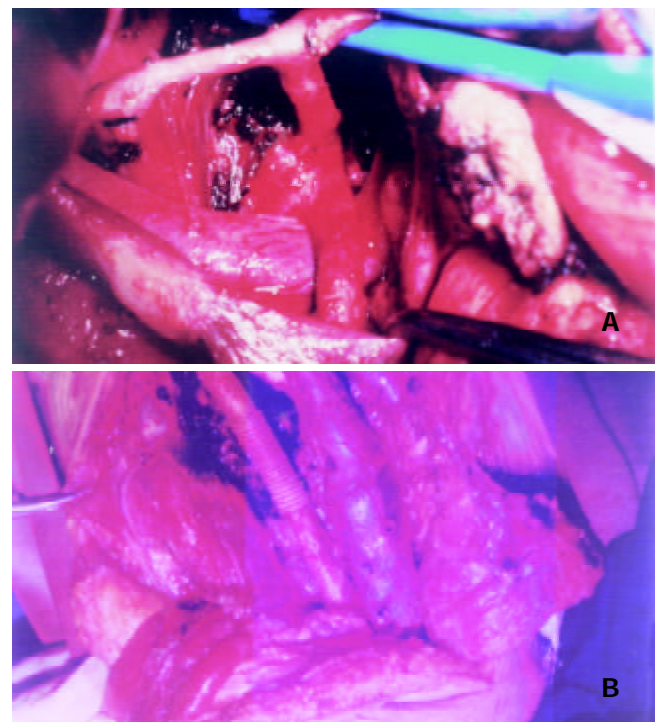


Figure 1 A and B Ranges of lymphatic and neighboring connective tissue dissection in periampullary malignant tumors. In Figure 1A n1, n2 and n3 (N07) nodes were cleared with neighboring connective tissue, In Figure 1B n2 nodes (N016) and connective tissue around the major vessels including aorta and inferior vein were cleared.

Immediately after operation The tumor locations were determined by close observation of the resected specimens. Lymph nodes macroscopically identified were separated from the fresh surgical specimen with the surrounding fatty tissues, in which small lymph nodes might be contained. Both the nodes and fatty tissues were embeded and cut into 5 µm sections and examined microscopically. Based on the guidelines of the General rules for Surgical and Pathological studies on Cancer of Pancreas by the Japanese society of Pancreatic Surgery^[3] (4rd edition, 1996), General Rules for Surgical and Pathological studies on cancer of Biliary Tract by the Japanese Society of Biliary Surgery (4rd edition 1997), perigastric lymph nodes were classified as right cardiac lymph nodes, left cardiac lymph nodes, lesser curvature lymph nodes, great curcature lymph nodes, suprapyloric lymph nodes, infrapyloric lymph nodes. Metastatic lymph nodes of carcinoma were confirmed by microscopic examination and the percentage of positive lymph nodes was calculated using the formula: [the number of sites positive for carcinoma metastasis]/[the number of sites dissected actually].

RESULTS

The number of dissected lymph nodes in each case range between seven and 19(mean 12) in patients with carcinoma of the pancreas of head,between 4 and 15(mean 9.7) in those with carcinoma of the distal bile duct,and between 3 and 16(mean 10.4) in those with carcinoma of the papilla of Vater.

The frequency of lymph node involvement was 18.7% of the patients with advanced carcinoma of the pancreas of head had perigastric lymph node involvement,5.6% patients with small carcinoma of pancreas had perigastric node involvement localized to the number 5 and 6, 1.9% patients with carcinoma of the distal bile duct had perigastric lymph node involvement in N₀7, 1.2% patients with carcinoma of the papilla of Vater had perigastric lymph node involvement only identified in N₀4. Pathological metastatic rates to perigastric regional lymph nodes in resected cases of carcinoma of periampulla are shown in Table1.

Table 1 Perigastric lymph node involvement in patients with carcinoma of periampulla

Carcinoma of pancreas			Carcinoma of distal bile duct			Carcinoma of papilla of Vater		
No	%	I/II	No	%	I/II	No	%	I/II
1	-	-	1	-	-	1	-	-
2	-	-	2	-	-	2	-	-
3	2.2	28/1261	3	0	0/145	3	0	0/498
4	1.2	17/1412	4	0	0/197	4	5.1	19/376
5	2.2	29/1319	5	0	0/216	5	0	0/512
6	7.2	116/1623	6	0	0/207	6	0	0/419
7	3.5	42/1174	7	3.1	17/557	7	0	0/517

I/II[the number of the sites positive for carcinoma metastasis]/[the number of sites dissected actually].

DISCUSSION

In this current study, periampulla cancer, includes three categories,namely carcinoma of ampulla, carcinoma of distal common bile duct, carcinonoma of pancreatic head.

Standard whipple operation for the treatment of resectable tumors of the periampullary region involves a radical pancreatoduodenectomy with an extensive gastric resection. The modified Whipple operation aims to preserve the stomach, pylorus and proximal duodenum so as to decreas

postgastrectomy complications and improve the patient' s quality of life. However, there were still many postoperative complications after pylorus-preserving pancreatoduodenectomy (PPPD)^[4,5]. In addition, in malignant periampullary tumor the patient' s quality of life after resection depended more on recurrence of malignant diseases than on physiologic alterations related to the resection and reconstruction^[6,7]. There might exist two kinds of recurrence after PPPD, one was the possibility of cancerous infiltration of duodenal and gastric margins through lymph vessels^[8], the other was the perigastric region node involvement. Individual lymph nodes have been histologically proved metastasis to perigastric region. According to our investigation, the rate of metastasis to perigastric lymph nodes in patients with carcinoma of pancreas was 18.7%. In those with other types of periampullary carcinomas, such as carcinoma of the ampulla, distal bile duct, the rate was 1.9% and 1.2% respectively. The involved sites were extremely limited^[9-14]. So far as carcinoma of the pancreas of head concernd even small carcinoma of pancreas has a higher perigastric lymph node involvement^[15,16].

The presence of metastatic cancer in lymph nodes excised during pancreatoduodenectomy is generally accepted as an evidence of a surgically incurable disease, and lymph node dissection may therefore be considered as a prognostic factor. PPPD could not remove peripyloric or celiac lymph nodes. The expected 5-year survival rate after PPPD without perigastric lymph node clearance range from 30% to 50% in patients with carcinoma of the ampulla of Vater or the distal bile duct^[9,17,18]. However, impact on the negative survival of metastatic lymph nodes of carcinoma of pancreatic head has been observed in many studies and was associated with high rates of local and regional recurrence after PPPD^[19,20]. Taking all these into account, we hold that PPPD may be acceptable for carcinoma of the ampulla of Vater, distal bile duct. It may be indicated for carcinoma of pancreas of head if perigastric node involvement is not observed.

REFERENCES

- 1 **Miyazaki I**, Kayahara M, Nagakawa T. Changes in lymph node dissection for pancreatic cancer. *Nippon Geka Gakkai Zasshi* 1997; **98**: 610-614
- 2 **Ogata Y**, Hishinuma S. The impact of pylorus-preserving pancreatoduodenectomy on surgical treatment for cancer of the pancreatic head. *J Hepatobiliary Pancreat Surg* 2002; **9**: 223-232
- 3 **Roher HD**, Heise JW, Goretzki PE. Stomach saving duodenopan-creatotomy. Indications and contraindications. The most important surgical steps. *Zentralbl Chir* 2000; **125**: 961-965
- 4 **Sakaguchi T**, Nakamura S, Suzuki S, Kojima Y, Tsuchiya Y, Konno H, Nakaoka J, Nishiyama R. Marginal ulceration after pylorus-preserving pancreaticoduodenectomy. *J Hepatobiliary Pancreat Surg* 2000; **7**: 193-197
- 5 **Park YC**, Kim SW, Jang JY, Ahn YJ, Park YH. Factors influencing delayed gastric emptying after pylorus-preserving pancreatod- uodenectomy. *J Am Coll Surg* 2003; **196**: 859-865
- 6 **McLeod RS**. Quality of life, nutritional status and gastrointesti- nal hormone profile following the Whipple procedure. *Ann Oncol* 1999; **10**(Suppl 4): 281-284
- 7 **van Berge Henegouwen MI**, Moojen TM, van Gulik TM, Rauws EA, Obertop H, Gouma DJ. Postoperative weight gain after stan- dard Whipple' s procedure versus pylorous-preserving pancreatoduodenectomy: the influence of tumour status. *Br J Surg* 1998; **85**: 922-926
- 8 **Sharp KW**, Ross CB, Halter SA, Morrison JG, Richards WO, Wil- liams LF, Sawyers JL. Pancreatoduodenectomy with pyloric pres- ervation for carcinoma of the pancreas: a cautionary note. *Surg- ery* 1989; **105**: 645-653
- 9 **Sasaki R**, Takahashi M, Funato O, Nitta H, Murakami H, Kawamura H, Suto T, Kanno S, Saito K. Prognostic significance of lymph node involvement in middle and distal bile duct cancer. *Surgery* 2001; **129**: 677-683

- 10 **Kayahara M**, Nagakawa T, Ohta T, Kitagawa H, Tajima H, Miwa K. Role of nodal involvement and the periductal soft-tissue margin in middle and distal bile duct cancer. *Ann Surgery* 1999; **229**: 76-83
- 11 **Yoshida T**, Shibata K, Yokoyama H, Morii Y, Matsumoto T, Sasaki A, Kitano S. Patterns of lymph node metastasis in carcinoma of the distal bile duct. *Hepatogastroenterology* 1999; **46**: 1595-1598
- 12 **Yoshida T**, Matsumoto T, Sasaki A, Morii Y, Shibata K, Ishio T, Kitano S. Lymphatic spread differs according to tumor location in extrahepatic bile duct cancer. *Hepatogastroenterology* 2003; **50**: 17-20
- 13 **Shirai Y**, Ohtani T, Tsukada K, Hatakeyama K. Patterns of lymphatic spread of carcinoma of the ampulla of Vater. *Br J Surg* 1997; **84**: 1012-1016
- 14 **Yoshida T**, Matsumoto T, Shibata K, Yokoyama H, Morii Y, Sasaki A, Kitano S. Patterns of lymph node metastasis in carcinoma of the ampulla of Vater. *Hepatogastroenterology* 2000; **47**: 880-883
- 15 **Ishikawa O**, Ohigashi H, Sasaki Y, Kabuto T, Furukawa H, Nakamori S, Imaoka S, Iwanaga T, Kasugai T. Practical grouping of positive lymph nodes in pancreatic head cancer treated by an extended pancreatectomy. *Surgery* 1997; **121**: 244-249
- 16 **Kayahara M**, Nagakawa T, Kobayashi H, Mori K, Nakano T, Kadoya N, Ohta T, Ueno K, Miyazaki I. Lymphatic flow in carcinoma of the head of the pancreas. *Cancer* 1992; **70**: 2061-2066
- 17 **Roberts RH**, Krige JE, Bornman PC, Terblanche J. Pancreaticoduodenectomy of ampullary carcinoma. *Am Surg* 1999; **65**: 1043-1048
- 18 **Takao S**, Aikou T, Shintchi H, Uchikura K, Kubo M, Imamura H, Maenohara S. Comparison of relapse and long-term survival between pylorus-preserving and Whipple pancreaticoduodenectomy in periampullary cancer. *Am J Surg* 1998; **176**: 467-470
- 19 **Benassai G**, Mastroiella M, Quarto G, Cappiello A, Giani U, Forestieri P, Mazzeo F. Factors influencing survival after resection for ductal adenocarcinoma of the head of the pancreas. *J Surg Oncol* 2000; **73**: 212-218
- 20 **Millikan KW**, Deziel DJ, Silverstein JC, Kanjo TM, Christein JD, Doolas A, Prinz RA. Prognostic factors associated with respectable adenocarcinoma of the head of the pancreas. *Am Surg* 1999; **65**: 618-623

Edited by Zhu LH and Wang XL