

• *H pylori* •

## Trisomy 3 may predict a poor response of gastric MALT lymphoma to *Helicobacter pylori* eradication therapy

Sawako Taji, Kenichi Nomura, Yosuke Matsumoto, Hideaki Sakabe, Naohisa Yoshida, Shoji Mitsufuji, Kazuhiro Nishida, Shigeo Horiike, Shigeo Nakamura, Masuji Morita, Masafumi Taniwaki

**Sawako Taji, Naohisa Yoshida, Shoji Mitsufuji**, Molecular Gastroenterology and Hepatology, Kyoto Prefectural University of Medicine Graduate School of Medical Science, Kyoto, Japan

**Kenichi Nomura, Yosuke Matsumoto, Kazuhiro Nishida, Shigeo Horiike**, Molecular Hematology and Oncology, Kyoto Prefectural University of Medicine Graduate School of Medical Science, Kyoto, Japan

**Hideaki Sakabe**, Department of Internal Medicine, Kohka Public Hospital, Kohka, Rokusin 3-39, Kohka-Minakuchi, Shiga 528-0014, Japan

**Shigeo Nakamura**, Department of Pathology and Clinical Laboratories, Aichi Cancer Center Hospital, Chikusa-ku, Nagoya 464-8681, Japan

**Masuji Morita**, School of Nursing, Kyoto Prefectural University of Medicine Graduate School of Medical Science, Kyoto, Japan

**Masafumi Taniwaki**, Clinical Molecular Genetics and Laboratory Medicine, Kyoto Prefectural University of Medicine Graduate School of Medical Science, Kyoto, Japan

**Correspondence to:** Kenichi Nomura, M.D., Ph.D., Molecular Hematology and Oncology, Kyoto Prefectural University of Medicine Graduate School of Medical Science, Kawaramachi Hirokoji, Kamigyo-ku, 602-8566 Kyoto, Japan. nomuken@sun.kpu-m.ac.jp

**Telephone:** +81-75-2515521 **Fax:** +81-75-2510710

**Received:** 2004-04-30 **Accepted:** 2004-06-25

### Abstract

**AIM:** To investigate the relation of the response to *Helicobacter pylori* eradication therapy to the depth of tumor invasion and chromosome abnormalities in patients with mucosa-associated lymphoid tissue (MALT) lymphoma and to determine the clinical value of aneuploidy.

**METHODS:** We studied 13 patients with localized gastric MALT lymphoma of stage E1. Before eradication therapy, the depth of tumor invasion was assessed by endoscopic ultrasonography in 8 patients and by endoscopic examination and gastrointestinal series in the remaining patients. To detect chromosomal abnormalities, paraffin-embedded tissue sections of diagnostic biopsy specimens underwent tissue-fluorescence *in situ* hybridization (FISH), using chromosome-specific  $\alpha$ -satellite DNA probes for chromosomes 3,7,12, and 18 and YAC clones for t(11;18)(q21;q21).

**RESULTS:** Seven of the 13 patients had complete regression (CR) in response to *H pylori* eradication therapy. No patient with CR had submucosal tumor invasion. Trisomy 18 was seen in 1 patient with CR, and both trisomies 12 and 18 were present in another patient with CR. All patients with no response or progressive disease had deep submucosal tumor invasion and showed t(11;18)(q21;q21) or trisomy 3. Trisomy 7 was not detected in this series of patients.

**CONCLUSION:** The depth of tumor invasion is an accurate predictor of the response of stage E1 MALT lymphoma to *H pylori* eradication therapy and is closely associated with the presence of chromosomal abnormalities. Trisomy 3 may

predict the aggressive development of MALT lymphoma.  
© 2005 The WJG Press and Elsevier Inc. All rights reserved.

**Key words:** *Helicobacter pylori* infection; Gastric MALT lymphoma; Trisomy 3

Taji S, Nomura K, Matsumoto Y, Sakabe H, Yoshida N, Mitsufuji S, Nishida K, Horiike S, Nakamura S, Morita M, Taniwaki M. Trisomy 3 may predict a poor response of gastric MALT lymphoma to *Helicobacter pylori* eradication therapy. *World J Gastroenterol* 2005; 11(1): 89-93

<http://www.wjgnet.com/1007-9327/11/89.asp>

### INTRODUCTION

In 1993, mucosa-associated lymphoid tissue (MALT) lymphoma was reported to regress after eradication of *Helicobacter pylori* (*H pylori*)<sup>[1]</sup>. Subsequently, this response to successful eradication of *H pylori* has been consistently confirmed in large series of patients<sup>[2-10]</sup>. *H pylori* eradication therapy is now considered the treatment of choice for MALT lymphoma. However, 20% to 30% of patients with MALT lymphoma do not respond to such a therapy<sup>[2-10]</sup>. To improve the prediction of response, various prognostic factors have been proposed, including endoscopic findings<sup>[6]</sup>, *H pylori* infection<sup>[6,7]</sup>, histological grade<sup>[3,4]</sup>, clinical stage<sup>[5-8]</sup>, and t(11;18)(q21;q21). Clinical stage and t(11;18)(q21;q21) are now considered the most reliable and useful prognostic factors. *H pylori* eradication therapy is generally ineffective against advanced MALT lymphoma, but some stage E1 cases are also resistant. Studies using endoscopic ultrasonography (EUS) have shown that the depth of tumor invasion is an accurate predictor of response in patients with stage E1 disease. Intramucosal tumors have a high rate of complete regression, whereas those with submucosal or deeper invasion have a low rate of regression.

t(11;18)(q21;q21) and aneuploidy are recurrent chromosomal abnormalities in MALT lymphoma. Chromosomal abnormalities are considered as the signs of biological malignancy and, in fact, MALT lymphoma positive for t(11;18)(q21;q21) does not respond to *H pylori* eradication therapy, irrespective of disease stage<sup>[11-15]</sup>. As for aneuploidy, clinical data on trisomies is scant. We developed a fluorescence *in situ* hybridization (FISH) technique for the analysis of small paraffin-embedded tissue sections and used this technique to investigate the correlation of chromosomal abnormalities with the depth of tumor invasion in stage E1 MALT lymphoma and to determine the clinical value of aneuploidy.

### MATERIALS AND METHODS

#### Patients

Thirteen patients with gastric MALT lymphoma were studied. The patients were given a diagnosis of gastric MALT lymphoma at, or were referred to, our clinics and Kohka Public Hospital from January 1995 to December 2001. Diagnosis was based on

histological evidence of MALT lymphoma as assessed by Isaacson's criteria and Wotherspoon's scoring system on examination of endoscopic biopsy specimens or surgically resected specimens<sup>[1]</sup>. *H. pylori* infection was diagnosed on the basis of histological examination, culture studies, serological tests, <sup>13</sup>C-urea breath tests, and rapid urease tests. Immunohistochemical analysis was performed with the use of keratin, EMA, LCA, L26, and UCHL-1. Surface marker analysis was performed on paraffin-embedded biopsy specimens by anti-CD20, CD3, CD5, CD10, CD45, CD23, and CD33 antibodies (DAKO Corporation, Carpinteria, CA) to confirm B cell lineage. Clinical stage was evaluated according to the Ann Arbor system modified by Musshoff<sup>[16]</sup>. Patients were examined by routine laboratory tests, physical examination, chest radiographs, thoracic and abdominal computerized tomography (CT) scans, 99 m gallium scintigraphy, and bone marrow aspiration (done in 2 patients). In 8 patients, the depth of tumor invasion in the gastric wall was evaluated by EUS with an Olympus transendoscopic miniature ultrasonic probe (UM-2R or UM-3R; Olympus Optical Co. Ltd., Tokyo, Japan). In the remaining patients, the depth of invasion was assessed by endoscopic examination and gastrointestinal series. The eradication regimens consisted of lansoprazole 40 mg, amoxicillin 1 g, and clarithromycin 500 mg, given orally for 14 d.

Patients underwent their first follow-up upper gastrointestinal endoscopic examination 6 wk after the completion of eradication therapy to examine the status of *H. pylori* infection. Follow-up endoscopy and EUS were done every 12 wk until evidence of histological remission was obtained. At follow-up examinations, at least six biopsy specimens were taken from each tumor as well as from suspicious areas and examined histologically. Regression of disease was assessed on the basis of both endoscopic and histological findings. Endoscopic response was classified into four subgroups: disappeared, partially regressed, no change, or worsened. Histological assessment was done according to Wotherspoon's scoring system and patients were divided into three subgroups: grade 0-2, grade 3, and grade 4-5. Complete histological remission was defined as a Wotherspoon's score of 2 or less for all histological sections of the biopsy specimens.

Both endoscopic and histological improvements were defined as complete remission (CR). Stable disease (SD) was defined as grade 4-5 histological findings during follow-up, with improvement in endoscopic findings. Other findings were evaluated as partial response (PR). Progressive disease (PD) was defined as clear signs of advancing disease stage.

### Statistical analysis

The association between discrete variables was assessed with Mann-Whitney's *U* test. *P* < 0.05 was considered statistically significant.

### Tissue-FISH

As reported previously, we used a technique for FISH with  $\alpha$ -satellite DNA probes for chromosomes 3, 7, 12, and 18 and two YAC clones (y9664, y943b8) for t(11;18)(q21;q21) (Kindly provided by Dr. Seto). YAC y9664 was centromerically assigned to the API2 gene at band 11q21 and YAC y943b8 telomerically to the MALT1 gene breakpoint at 18q21<sup>[17-21]</sup>. After amplification of human sequences by Alu-PCR, probes were generated by nick translation with biotin-16-dUTP.

Six-micrometer-thick sections of paraffin-embedded tissue were placed on silane-coated glass slides. The slides were baked at 56 °C for 2 h to promote tissue adherence to the slides and deparaffinized in xylene and rehydrated in a series of alcohol (100%, 85%, 70%). Then, the slides were treated with 0.2 mol/L HCl for 20 min, 2×SSC (0.3 mol/L sodium chloride and 0.03 mol/L

sodium citrate) at 80 °C for 20 min, and 0.05 mg/mL proteinase K in TEN (0.05 mol/L Tris-HCl at pH 7.8, 0.01 mol/L EDTA, and 0.01 mol/L NaCl buffer) for 10 min at 37 °C. To allow adequate digestion, the time for treatment with proteinase K solution was modified according to section thickness. After digestion, the slides were immersed in 16 g/L formaldehyde in phosphate-buffered saline for 10 min and dehydrated in a graded series of alcohol (70%, 85%, and 100%). FISH probes were applied to the tissues, covered with slide glasses, heated to 90 °C to denature the probes and target DNA, and incubated at 42 °C overnight. The slides were placed in 2×SSC/50% formamide for 5 min each at 42 °C, washed in 2×SSC/0.03 mg/L DAPI, cover-slipped, and examined with a fluorescence microscope. We used a CCD camera (Sensys0400-GI; Photometrics Ltd., Tucson, AZ, USA) to document the results.

### Determination of slice thickness

Determination of slice thickness was a crucial issue for tissue-FISH, because thin slices would easily cut off signals, resulting in underestimation of the chromosome copy number. Sections of archival tissue should be within 6  $\mu$ m thick. We tested sections of different thickness (2.5-6.0  $\mu$ m). Sections 6  $\mu$ m in thickness provided many intact nuclei and signals. To examine the accuracy for this thickness, we performed double-color FISH for 5 cases. Two cases of chronic gastritis were included as controls. When 6  $\mu$ m thick sections were used, perfect signals (4 signals) were detected in 52.6% to 82.9% (mean 66.7%) of cells.

### Evaluation of numerical chromosome aberrations by single color FISH

Conventional fluorescence microscopy was used to score the copy number of chromosome 3, 7, 12, and 18 signals. The number of signal spots on a minimum of 100 to 300 non-overlapping nuclei was counted. We counted only intact, non-overlapping nuclei with clear counterstaining that were of a similar size and an intensity. Nuclei with paired spots (split spots) were counted as having one signal. The cut-off values for interphase analysis were based on the data obtained from three cases of chronic gastritis.

### Evaluation of t(11;18)(q21;q21)

At least 100 nuclei per slide were evaluated. Derivative signal constellations with one signal pair and one separate red and green signal per nucleus were counted. The cut-off level was determined by examining three cases of chronic gastritis as negative controls.

## RESULTS

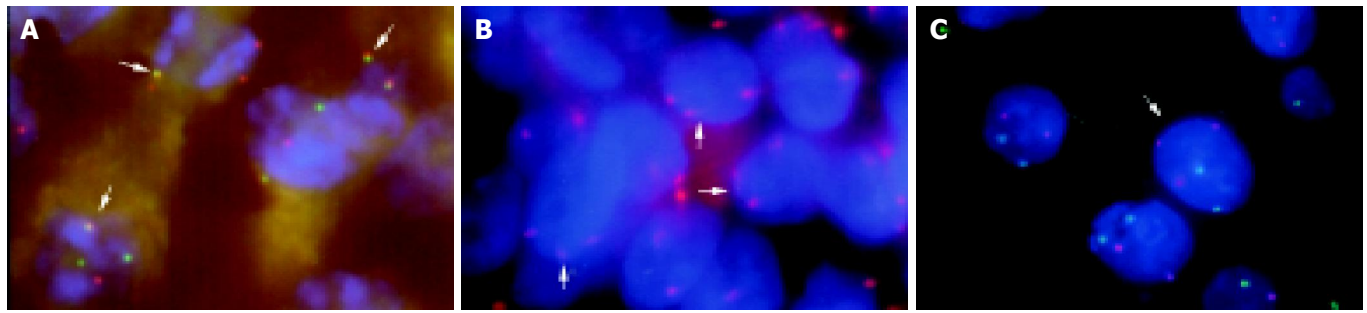
### Clinicopathologic features of the patients

Seven men and 6 women with a mean age of 55.0 years (range 49 to 72) were studied. On the basis of endoscopic findings, MALT lymphomas were classified as superficial spreading type in 10 patients, mass forming type in 2, and diffuse infiltrating type in 1. All but one patient had *H. pylori* infection. *H. pylori* was successfully eradicated in all patients with infection.

All patients had stage EI disease, with no high-grade components. The depth of tumor invasion was intramucosal in 7 of the 13 patients. The other 6 patients had deep submucosal invasion (Table 1).

### Tumor response

Among the 13 patients, 7 showed gross tumor regression (No. 1, 2, 3, 4, 5, 6, and 7) at the first follow-up endoscopic examination. In all patients with CR, the time for regression after antibiotic therapy was within 8 mo (range, 1 to 8). The complete remission rate was 53.8%. One patient had PR (No. 8). Three patients had NR (No. 9, 10 and 11). Patient 9 had spontaneous regression



**Figure 1** Results of tissue-FISH. A: Three signals of the chromosome 3 centromere detected in tumor nuclei by double-color FISH on paraffin-embedded tissue sections (No.7); B: Arrows indicate API2/MALT1 fusion signals due to a t(11;18)(q21;q21) (No.10) (arrows); C: A tumor cell with three red signals for chromosome 3 and two green signals for chromosome 18 (arrows).

**Table 1** Clinicopathological data of 13 patients with gastric MALT lymphoma

Case No.	Sex/Age(yr)	Hp.	Endoscopic findings #	Depth	Response	Time for regression (mo)	Second therapy	Follow-up (mo)
1	M/72	(+)	SS	m	CR	8	(-)	105
2	F/69	(+)	SS	m	CR	2	(-)	81
3	F/73	(+)	SS	m	CR	1	(-)	41
4	F/55	(+)	SS	m	CR	6	(-)	30
5	F/60	(+)	SS	m <sup>2</sup>	CR	2.5	(-)	35
6	F/50	(+)	SS	m <sup>2</sup>	CR	1	(-)	26
7	M/72	(+)	SS	m <sup>2</sup>	CR	4	(-)	26
8	M/49	(-)	SS	Sm	PR	(-)	observation	49
9	M/71	(+)	SS	Sm	NR	(-)	observation	45
10	M/68	(+)	MF	Sm	NR	(-)	EMR	29
11	M/49	(+)	DI	Sm	NR	(-)	Rituximab→RT	23
12	F/59	(+)	MF	Sm <sup>1</sup>	PD	(-)	Gastrectomy	91
13	M/69	(+)	SS	Sm <sup>2</sup>	PD	(-)	CHOP	26

Abbreviations: SS, superficial spreading; MF, mass forming; DI, diffuse infiltrating; CHOP, cyclophosphamide, doxorubicin, vincristine, prednisolone; EMR, endoscopic mucosal resection. <sup>1</sup>Assessed by samples resected surgically; <sup>2</sup>assessed by the endoscopic and gastrointestinal X ray examination.

and was observed without additional therapy. Patient 10 received endoscopic mucosal resection as an additional therapy. However, residual tumor was suspected on histological examination. Patient 11 was given anti-CD20 antibody therapy (rituximab) and radiation therapy.

Two of the 13 patients had PD (No. 12 and 13). Patient 12 received surgical resection and remained in remission for 36 mo. Patient 13 showed no evidence of regression and was given cyclophosphamide, doxorubicin, vincristine, and prednisolone (CHOP) chemotherapy. However, systemic disease developed.

**Table 2** Results of tissue-FISH

Case No.	Chromosome aberration				
	+3	+7	+12	+18	t(11;18)
1	0	0	NA	0	NA
2	4	2	2.5	14.2	4
3	0	0	0	4	NA
4	2	0	0	0	0
5	2.5	0	0	3.5	2
6	2	3	0	2	0
7	3	0	24	49	4
8	10	4	0	4	1
9	19	0	1	1	19
10	2.5	3	2	2.5	17
11	0	3	3	0	38
12	1	1	2	3	24
13	3	2	1.8	3.2	22

NA: not available.

### Follow up

At a mean follow-up time of 43.5 mo (range 12-91 mo), all patients with CR were alive and free of lymphoma. The mean disease-free survival during the study period was 31.6 mo (range 8.0-83.0 mo).

### Tissue-FISH analysis

In control patients, cells with three signals were detected within the range of 1.6% to 2.89%. The cut-off value for trisomy was calculated from the mean±SD and estimated to be 4.06%. For t(11;18)(q21;q21), the cut-off value was 3.7% for fusion between 11q21 and 18q21. Trisomy 3 was seen in 3 patients (20%) (No. 8, 9 and 12). Trisomy 7 was not found. Trisomy 12 was present in 1 patient (No. 7) (6.1%), and trisomy 18 was present in 2 patients (No. 2 and 7) (20%). t(11;18)(q21;q21) was seen in 4 patients (No. 9, 10, 11, 13). The data are shown in Table 2 and Figure 1.

### Statistical analysis

The response rate was not affected by tumor grade, but was affected by the depth of tumor invasion. The response of intramucosal lymphomas differed significantly from that of deep submucosal lymphomas ( $P<0.01$ ). Trisomy 3 was associated with the response to eradication therapy ( $P<0.01$ ). Trisomy 3 or t(11;18) was closely associated with the depth of tumor invasion ( $P<0.01$ ).

### DISCUSSION

Our study showed that patients harboring trisomy 3 or t(11;18)

(q21;q21) were resistant to *H. pylori* eradication therapy. The close relation of trisomy 3 to EUS findings suggests that trisomy 3 has some role in the development of MALT lymphoma, but this remains to be confirmed. However, Dierlamm *et al*<sup>[22]</sup> showed that the minimal overrepresented region involves 3q21-23 and 3q25-29 by comparative genomic hybridization. The BCL6 proto-oncogene, located on 3q27, which is rearranged in some marginal zone B-cell lymphomas, is one of the candidate genes residing in these critical regions. In patients 8 and 9 harboring trisomy 3, repeated biopsy showed residual tumor cells despite improvement in endoscopic findings after eradication therapy. This finding suggests that most tumor cells in these patients did not yet obtain a malignant nature and that these cells were regressed after eradication therapy.

As for other types of aneuploidy, we detected trisomies 7, 12, and 18 in 0%, 6.1%, and 20% of our patients. Previous studies have estimated that trisomy 7 can be detected in 3% to 15% of patients, trisomy 12 in 3% to 38%, and trisomy 18 in 7% to 36%<sup>[23-28]</sup>. The roles of trisomies 12 and 18 are not clear. Our one patient harboring both trisomies 12 and 18 remained in CR for 12 mo, and another patient who had trisomy 18 remained in CR for 54 mo. These findings may indicate that trisomies 12 and 18 do not convey resistance to eradication therapy in gastric MALT lymphoma. However, the small size of our study group could not permit this conclusion to be drawn with confidence.

Tissue-FISH is a useful technique, but could underestimate the actual chromosome copy number because of sliced nuclei<sup>[29,30]</sup>. To test the C index of tissue-FISH with 6  $\mu$ m thick sections, we performed double color FISH, and found that double color FISH yielded a high proportion of nuclei with four signals and confirmed that trisomy was negative in 3 negative cases and 2 cases of gastritis. Double color FISH also found a similar percentage of cells positive for trisomy to that derived by single color FISH in one positive case. These results indicate that 6  $\mu$ m thick sections provide an adequate sensitivity for the detection of aneuploidy.

In conclusion, t(11;18)(q21;q21) and trisomy 3 closely relate to the extent of tumor invasion, and trisomy 3 indicates a poor prognosis in gastric MALT lymphoma. Further studies are necessary to define the relation between tumor progression and chromosomal abnormalities in this disease.

## REFERENCES

- 1 Wotherspoon AC, Doglioni C, Diss TC, Pan L, Moschini A, de Boni M, Isaacson PG. Regression of primary low-grade B-cell gastric lymphoma of mucosa-associated lymphoid tissue type after eradication of *Helicobacter pylori*. *Lancet* 1993; **342**: 575-577
- 2 Roggero E, Zucca E, Pinotti G, Pascarella A, Capella C, Savio A, Pedrinis E, Paterlini A, Venco A, Cavalli F. Eradication of *Helicobacter pylori* infection in primary low-grade gastric lymphoma of mucosa-associated lymphoid tissue. *Ann Intern Med* 1995; **122**: 767-769
- 3 Thiede C, Morgner A, Alpen B, Wundisch T, Herrmann J, Ritter M, Ehninger G, Stolte M, Bayerdorffer E, Neubauer A. What role does *Helicobacter pylori* eradication play in gastric MALT and gastric MALT lymphoma? *Gastroenterology* 1997; **113**: S61-S64
- 4 Boot H, de Jong D, van Heerde P, Taal B. Role of *Helicobacter pylori* eradication in high-grade MALT lymphoma. *Lancet* 1995; **346**: 448-449
- 5 Sackmann M, Morgner A, Rudolph B, Neubauer A, Thiede C, Schulz H, Kraemer W, Boersch G, Rohde P, Seifert E, Stolte M, Bayerdorffer E. Regression of gastric MALT lymphoma after eradication of *Helicobacter pylori* is predicted by endosonographic staging. MALT Lymphoma Study Group. *Gastroenterology* 1997; **113**: 1087-1090
- 6 Ruskone-Fourmestreaux A, Lavergne A, Aegerter PH, Megraud F, Palazzo L, de Mascarel A, Molina T, Rambaud JL. Predictive factors for regression of gastric MALT lymphoma after anti-*Helicobacter pylori* treatment. *Gut* 2001; **48**: 297-303
- 7 Steinbach G, Ford R, Gloor G, Sample D, Hagemester FB, Lynch PM, McLaughlin PW, Rodriguez MA, Romaguera JE, Sarris AH, Younes A, Luthra R, Manning JT, Johnson CM, Lahoti S, Shen Y, Lee JE, Winn RJ, Genta RM, Graham DY, Cabanillas FF. Antibiotic treatment of gastric lymphoma of mucosa-associated lymphoid tissue. An uncontrolled trial. *Ann Intern Med* 1999; **131**: 88-95
- 8 Nakamura S, Matsumoto T, Suekane H, Takeshita M, Hizawa K, Kawasaki M, Yao T, Tsuneyoshi M, Iida M, Fujishima M. Predictive value of endoscopic ultrasonography for regression of gastric low grade and high grade MALT lymphomas after eradication of *Helicobacter pylori*. *Gut* 2001; **48**: 454-460
- 9 Bayerdorffer E, Neubauer A, Rudolph B, Thiede C, Lehn N, Eidt S, Stolte M. Regression of primary gastric lymphoma of mucosa-associated lymphoid tissue type after cure of *Helicobacter pylori* infection. MALT Lymphoma Study Group. *Lancet* 1995; **345**: 1591-1594
- 10 Neubauer A, Thiede C, Morgner A, Alpen B, Ritter M, Neubauer B, Wundisch T, Ehninger G, Stolte M, Bayerdorffer E. Cure of *Helicobacter pylori* infection and duration of remission of low-grade gastric mucosa-associated lymphoid tissue lymphoma. *J Natl Cancer Inst* 1997; **89**: 1350-1355
- 11 Ott G, Katzenberger T, Greiner A, Kalla J, Rosenwald A, Heinrich U, Ott MM, Muller-Hermerlink HK. The t(11;18)(q21;q21) chromosome translocation is a frequent and specific aberration in low-grade but not high-grade malignant non-Hodgkin's lymphomas of the mucosa-associated lymphoid tissue (MALT-) type. *Cancer Res* 1997; **57**: 3944-3948
- 12 Liu H, Ruskone-Fourmestreaux A, Lavergne-Slove A, Ye H, Molina T, Bounnik Y, Hamoudi RA, Diss TC, Dogan A, Megraud F, Rambaud JC, Du MQ, Isaacson PG. Resistance of t(11;18) positive gastric mucosa-associated lymphoid tissue lymphoma to *Helicobacter pylori* eradication therapy. *Lancet* 2001; **357**: 39-40
- 13 Liu H, Ye H, Dogan A, Ranaldi R, Hamoudi RA, Bearzi I, Isaacson PG, Du MQ. T(11;18)(q21;q21) is associated with advanced mucosa-associated lymphoid tissue lymphoma that expresses nuclear BCL10. *Blood* 2001; **98**: 1182-1187
- 14 Liu H, Ye H, Ruskone-Fourmestreaux A, De Jong D, Pileri S, Thiede C, Lavergne A, Boot H, Calzetti G, Wundisch T, Molina T, Taal BG, Elena S, Thomas T, Zinzani PL, Neubauer A, Stolte M, Hamoudi RA, Dogan A, Isaacson PG, Du MQ. T(11;18) is a marker for all stage gastric MALT lymphomas that will not respond to *H. pylori* eradication. *Gastroenterology* 2002; **122**: 1286-1294
- 15 Inagaki H, Okabe M, Seto M, Nakamura S, Ueda R, Eimoto T. API2-MALT1 fusion transcripts involved in mucosa-associated lymphoid tissue lymphoma: multiplex RT-PCR detection using formalin-fixed paraffin-embedded specimens. *Am J Pathol* 2001; **158**: 699-706
- 16 Musshoff K. Clinical staging classification of non-Hodgkin's lymphomas (author's transl). *Strahlentherapie* 1977; **153**: 218-221
- 17 Akagi T, Motegi M, Tamura A, Suzuki R, Hosokawa Y, Suzuki H, Ota H, Nakamura S, Morishima Y, Taniwaki M, Seto M. A novel gene, MALT1 at 18q21, is involved in t(11;18)(q21;q21) found in low-grade B-cell lymphoma of mucosa-associated lymphoid tissue. *Oncogene* 1999; **18**: 5785-5794
- 18 Nomura K, Sekoguchi S, Ueda K, Nakao M, Akano Y, Fujita Y, Yamashita Y, Horiike S, Nishida K, Nakamura S, Taniwaki M. Differentiation of follicular from mucosa-associated lymphoid tissue lymphoma by detection of t(14;18) on single-cell preparations and paraffin-embedded sections. *Genes Chromosomes Cancer* 2002; **33**: 213-216
- 19 Nomura K, Yoshino T, Nakamura S, Akano Y, Tagawa H, Nishida K, Seto M, Nakamura S, Ueda R, Yamagishi H, Taniwaki M. Detection of t(11;18)(q21;q21) in marginal zone lymphoma of mucosa-associated lymphocytic tissue type on paraffin-embedded tissue sections by using fluorescence in situ hybridization. *Cancer Genet Cytogenet* 2003; **140**: 49-54
- 20 Matsumoto Y, Nomura K, Matsumoto S, Ueda K, Nakao M, Nishida K, Sakabe H, Yokota S, Horiike S, Nakamine H,

- Nakamura S, Taniwaki M. Detection of t(14;18) in follicular lymphoma by dual-color fluorescence in situ hybridization on paraffin-embedded tissue sections. *Cancer Genet Cytogenet* 2004; **150**: 22-26
- 21 **Yoshida N**, Nomura K, Matsumoto Y, Nishida K, Wakabayashi N, Konishi H, Mitsufuji S, Kataoka K, Okanoue T, Taniwaki M. Detection of BCL2-IGH rearrangement on paraffin-embedded tissue sections obtained from a small submucosal tumor of the rectum in a patient with recurrent follicular lymphoma. *World J Gastroenterol* 2004; **10**: 2602-2604
  - 22 **Dierlamm J**, Wlodarska I, Michaux L, Stefanova M, Hinz K, Van Den Berghe H, Hagemeijer A, Hossfeld DK. Genetic abnormalities in marginal zone B-cell lymphoma. *Hematol Oncol* 2000; **18**: 1-13
  - 23 **Wotherspoon AC**, Finn TM, Isaacson PG. Trisomy 3 in low-grade B-cell lymphomas of mucosa-associated lymphoid tissue. *Blood* 1995; **85**: 2000-2004
  - 24 **Dierlamm J**, Pittaluga S, Wlodarska I, Stul M, Thomas J, Boogaerts M, Michaux L, Driessen A, Mecucci C, Cassiman JJ, De Wolf-Peeters C, Van den Berghe H. Marginal zone B-cell lymphomas of different sites share similar cytogenetic and morphologic features. *Blood* 1996; **87**: 299-307
  - 25 **Ott G**, Kalla J, Steinhoff A, Rosenwald A, Katzenberger T, Roblick U, Ott MM, Muller-Hermelink HK. Trisomy 3 is not a common feature in malignant lymphomas of mucosa-associated lymphoid tissue type. *Am J Pathol* 1998; **153**: 689-694
  - 26 **Blanco R**, Lyda M, Davis B, Kraus M, Fenoglio-Preiser C. Trisomy 3 in gastric lymphomas of extranodal marginal zone B-cell (mucosa-associated lymphoid tissue) origin demonstrated by FISH in intact paraffin tissue sections. *Hum Pathol* 1999; **30**: 706-711
  - 27 **Brynes RK**, Almaguer PD, Leathery KE, McCourty A, Arber DA, Medeiros LJ, Nathwani BN. Numerical cytogenetic abnormalities of chromosomes 3, 7, and 12 in marginal zone B-cell lymphomas. *Mod Pathol* 1996; **9**: 995-1000
  - 28 **Dierlamm J**, Michaux L, Wlodarska I, Pittaluga S, Zeller W, Stul M, Griel A, Thomas J, Boogaerts M, Delaere P, Cassiman JJ, de Wolf-Peeters C, Mecucci C, Van den Berghe H. Trisomy 3 in marginal zone B-cell lymphoma: a study based on cytogenetic analysis and fluorescence in situ hybridization. *Br J Haematol* 1996; **93**: 242-249
  - 29 **Aubele M**, Zitzelsberger H, Szucs S, Werner M, Braselmann H, Hutzler P, Rodenacker K, Lehmann L, Minkus G, Hofler H. Comparative FISH analysis of numerical chromosome 7 abnormalities in 5-micron and 15-micron paraffin-embedded tissue sections from prostatic carcinoma. *Histochem Cell Biol* 1997; **107**: 121-126
  - 30 **Thompson CT**, LeBoit PE, Nederlof PM, Gray JW. Thick-section fluorescence in situ hybridization on formalin-fixed, paraffin-embedded archival tissue provides a histogenetic profile. *Am J Pathol* 1994; **144**: 237-243

Edited by Wang XL Proofread by Zhu LH