

• CASE REPORT •

## Carcinoid tumor of the duodenum and accessory papilla associated with polycythemia vera

Horng-Yuan Wang, Ming-Jen Chen, Tsen-Long Yang, Ming-Chih Chang, Yu-Jan Chan

Horng-Yuan Wang, Ming-Jen Chen, Division of Gastroenterology, Department of Internal Medicine, Mackay Memorial Hospital, Taipei, Taiwan, China  
Tsen-Long Yang, Department of Surgery, Mackay Memorial Hospital, Taipei, Taiwan, China  
Ming-Chih Chang, Division of Hematology, Department of Internal Medicine, Mackay Memorial Hospital, Taipei, Taiwan, China  
Yu-Jan Chan, Department of Pathology, Mackay Memorial Hospital, Taipei, Taiwan, China  
Correspondence to: Dr. Horng-Yuan Wang, No. 92, Sec. 2, Chungshan North Road, Taipei, Taiwan, China. hywang@ms2.mmh.org.tw  
Telephone: +886-2-25433535-2260 Fax: +886-2-25433642  
Received: 2004-10-19 Accepted: 2004-11-29

© 2005 The WJG Press and Elsevier Inc. All rights reserved.

**Key words:** Carcinoid tumor; Accessory papilla; Polycythemia vera

Wang HY, Chen MJ, Yang TL, Chang MC, Chan YJ. Carcinoid tumor of the duodenum and accessory papilla associated with polycythemia vera. *World J Gastroenterol* 2005; 11(24): 3794-3796  
<http://www.wjgnet.com/1007-9327/11/3794.asp>

### Abstract

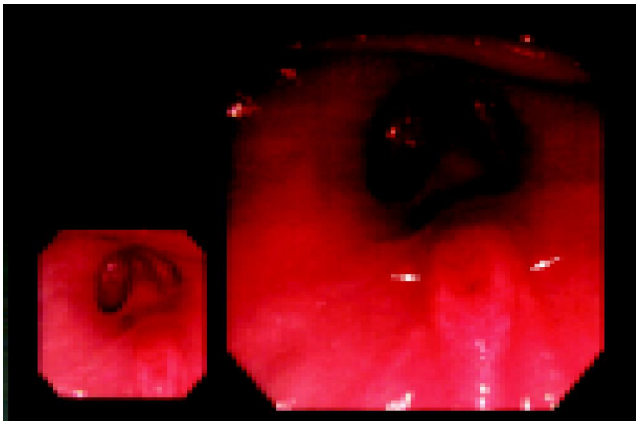
Carcinoid tumors have been reported in a wide range of organs but most frequently involve the gastrointestinal tract; however, duodenal carcinoid tumors are rare. We report a 50-year-old male patient complaining of multiple melenas for 3 wk. The panendoscopy and endoscopic retrograde cholangiopancreatography revealed swelling accessory papilla with an ulcer. The biopsy taken showed a carcinoid tumor. The lesion was removed by wide resection. Patient was found to have an abnormal blood cell count during the follow-up period with elevated levels of hemoglobin and hematocrit of 21.2 g/dL and 63.5%, respectively, thrombocytosis of 501 000/ $\mu$ L, and leukocytosis of 20 410/ $\mu$ L. He was diagnosed as a polycythemia vera by a hematologist after further evaluation. He received periodic phlebotomy and hydroxyurea treatment. The response was good and his hematocrit was stabilized by periodic phlebotomy in the range of 44-49% during the last 2 years. The possible origin of UGI bleeding by a duodenal carcinoid tumor, although rare, should be considered. There has been one case report of a duodenal carcinoid tumor that involved accessory papilla of the pancreas divisum and one case report of metastatic carcinoid tumor associated with polycythemia vera. It is different in our patient as compared with the latter report, which mentioned a polycythemia vera patient who was found to have a metastatic carcinoid in the 17 years follow-up period. Chemotherapy had been given before the carcinoid tumor was revealed. Our patient had no previous chemotherapy for polycythemia vera before he was found to have duodenal carcinoid tumor; this excludes the possibility of chemotherapy induced carcinoid tumor, although it had been suspected in the previous report. In our patient, the existence of both diseases may be by predisposition of each other since both diseases have an increased incidence of other neoplasm, or they may be coexistent incidentally.

### INTRODUCTION

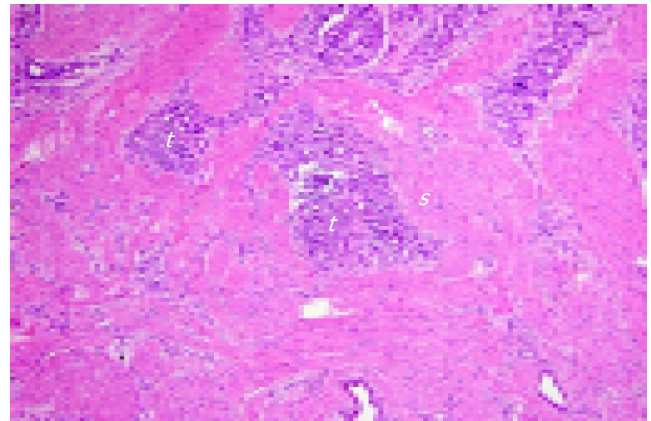
Carcinoid tumors have been reported in a wide range of organs but most frequently involve the gastrointestinal tract; however, the duodenal carcinoid tumors are rare<sup>[1]</sup>. There has been one case report of a duodenal carcinoid tumor that involved accessory papilla of the pancreas divisum<sup>[2]</sup> and one case report of metastatic carcinoid tumor associated with polycythemia vera<sup>[3]</sup>. Here, we report a case where a duodenal carcinoid tumor that involved the rare location in accessory papilla was later found to have rare association with polycythemia vera.

### CASE REPORT

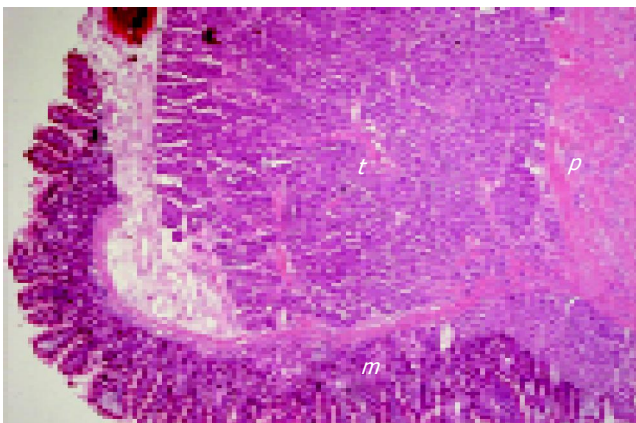
The patient is a 50-year-old male; he does not smoke nor drink and was quite healthy except for a previous history of distal fibular fracture about 3 years ago. He complained of multiple melenas without symptoms of dizziness, weakness nor fainting for 3 wk. The panendoscopy examination revealed swelling accessory papilla with ulcer (Figure 1); however, the biopsy taken then showed no evidence of malignancy. Endoscopic retrograde cholangiopancreatography was done later and the biopsy taken showed a carcinoid tumor. The X-ray film showed a normal pancreatic duct. His abdominal CT had no specific finding except fatty liver. Operation via transduodenal resection at second portion was done and revealed a 1-cm tumor with ulcer and bleeding; wide resection for this tumor was performed. The postoperative pathology showed duodenal mucosa, submucosa, and an accessory papilla with pancreatic duct structure and a well-developed muscular coat. A well-defined but unencapsulated carcinoid tumor (Figure 2) about 0.9 cm in greatest dimension is found in the deep portion of duodenal mucosa over the papilla and in submucosa around the ductal wall of the papilla. The tumor cells are uniform with round nuclei, arranged in small solid nests or glandular (acinar) structure. The cells are positive for cytokeratin



**Figure 1** Swelling accessory papilla with ulcer (arrows) by endoscopy.



**Figure 3** Tumor cells (t) with glandular pattern infiltrate the smooth muscle bundles of papilla (s). (H&E stain, ×40).



**Figure 2** Tumor cells (t) in deep portion of duodenal mucosa (m) over the papilla and in submucosa around the ductal wall of papilla (p). (H&E stain, ×20).

and chromogranin A. Mucin stain is focally positive at the luminal border. Tumor cells also infiltrate the smooth muscle bundles of papilla (Figure 3). There is no definite lymphatic-capillary permeation. The features indicate a carcinoid tumor in the mucosa and submucosa of duodenum involving the accessory papilla. Patient's postoperative condition was smooth except jaundice was observed with elevated bilirubin (T/D: 0.9/2.6 mg/dL), alkaline phosphatase (114 U/L), AST (96 U/L) and ALT (182 U/L) on the eight postoperative day. He gradually recovered after 1 mo.

The patient was found to have an abnormal blood cell count during the follow-up with elevated hemoglobin and hematocrit of 21.2 g/dL and 63.5%, respectively; thrombocytosis of 501 000/ $\mu$ L and leukocytosis of 20 410/ $\mu$ L were also noticed. He was found to have elevated leukocyte alkaline phosphatase of 209 but had a normal erythropoietin (16.96 mU/mL) and O<sub>2</sub> saturation (97%). He was diagnosed as polycythemia vera after further evaluation by hematologist and received phlebotomy at first but the effect was not obvious. Hydroxyurea 1 000 mg/d was prescribed later for 2 mo and the response was good. In the past 2 years, his hematocrit was stabilized by periodic phlebotomy in the range of 44-49%. Patient was followed up in the OPD for more than 3 years.

## DISCUSSION

Carcinoid tumors are thought to arise from neuroendocrine cells that line the tract<sup>[1]</sup>. The overall incidence of carcinoid tumors in the United States has been about 1-2 cases per 100 000 people<sup>[4,5]</sup>. Carcinoid tumors have been reported in a wide range of organs but most frequently involve the gastrointestinal tract and the bronchopulmonary system<sup>[1]</sup>. In a report by USA, carcinoid tumors happen most frequently in the gastrointestinal tract (67.5%) and then the respiratory tract (25.3%). Small bowel (41.8%) is the most frequent site of the gastrointestinal carcinoid tumors, followed by the rectum (27.4%) and the appendix (24.1%)<sup>[1]</sup>. The duodenal carcinoid tumors are rare; the frequency is about 2-4% in all carcinoid tumors<sup>[1]</sup>.

A report by Japan, which compares the duodenal carcinoid tumors with that in other organs, showed an average age of 55.9 years, a relative small average tumor size of 17.7 mm, a relative low metastasis rate of 27.4%, a high postoperative survival rate of 83.3%, and a reasonable incidence of the carcinoid syndrome of 3.1%<sup>[6]</sup>. They are usually small, solitary lesions confined to the duodenal mucosa had a 5-year death rate of 5.3%<sup>[7]</sup>. The 5-year survival rate for all carcinoid tumors, regardless of site, was 67.2%<sup>[1]</sup>.

The duodenal carcinoid tumors, unlike carcinoid tumors of the jejunum and ileum, have a location advantage and are often discovered endoscopically<sup>[7]</sup>. There are fewer than 80 reported cases of carcinoid tumors of the ampulla Vater in the literature<sup>[8,9]</sup>. A carcinoid tumor at the accessory papilla as in our case has rarely been reported before. There is only one case report of panniculitis with a carcinoid tumor on the accessory papilla of the pancreatic divisum which was reported by a French group<sup>[2]</sup>.

The advantageous location makes it easier to discover the tumor in comparison to carcinoid tumors, which are located more distally in the small intestine. Carcinoid tumors are associated with an increased incidence of secondary primary malignancies, especially adenocarcinoma<sup>[10]</sup>. The large intestine is the most common site for synchronous primary malignancies to occur with gastrointestinal carcinoid tumors<sup>[11,12]</sup>. Duodenal carcinoid tumors associated with

synchronous primary tumors have been rarely reported and have been noted to be associated with gastric leiomyoblastoma<sup>[13]</sup> and adenocarcinoma of gastro-esophageal junction<sup>[10]</sup>. There have been three case reports describing the development of isolated carcinoid tumors in patients with myelofibrosis<sup>[14,15]</sup>. Two cases are rectal carcinoid tumors and one case is bronchial carcinoid tumor. Only one case report of polycythemia vera associated with metastatic carcinoid is found in the literature<sup>[3]</sup>. It is a polycythemia vera patient, who was found to have a metastatic carcinoid tumor in the 17-years follow-up period. The patient had received hydroxyurea treatment for the polycythemia vera before the discovery of the carcinoid tumor. Our patient was never diagnosed as a polycythemia vera patient before the duodenal carcinoid tumor was found. Therefore, no treatment-related condition as the case we mentioned above needs to be considered, and although the polycythemia vera was diagnosed after duodenal carcinoid tumor, it may still have existed long before the development of the duodenal carcinoid tumor. In our patient, the existence of both diseases may be by predisposition of each other since both diseases have an increased incidence of other neoplasm, or they may be coexistent incidentally.

## REFERENCES

- 1 **Modlin IM**, Lye KD, Kidd M. A 5-decade analysis of 13,715 carcinoid tumors. *Cancer* 2003; **97**: 934-959
- 2 **Ottas O**, Barthet M, De Troyer J, Franck F, Garcia S. Pancreatic panniculitis with intraductal carcinoid tumor of the pancreas divisum. *Ann Dermatol Venereol* 2004; **131**: 466-469
- 3 **Sham RL**, von Doenhoff L, Dipola J, Shah A, Pande P, Bennet JM. Polycythemia vera associated with metastatic carcinoid. *Cancer Invest* 1996; **14**: 120-123
- 4 **Godwin JD**. Carcinoid tumors. An analysis of 2 837 cases. *Cancer* 1975; **36**: 560-569
- 5 **Modlin IM**, Sandor A. An analysis of 8305 cases of carcinoid tumors. *Cancer* 1997; **79**: 813-829
- 6 **Soga J**. Endocrinocarcinomas (carcinoids and their variants) of the duodenum. An evaluation of 927 cases. *J Exp Clin Cancer Res* 2003; **22**: 349-363
- 7 **Burke AP**, Sobin LH, Federspiel BH, Shekitka KM, Helwig EB. Carcinoid tumors of the duodenum. A clinicopathologic study of 99 cases. *Arch Pathol Lab Med* 1990; **114**: 700-704
- 8 **Bornstein-Quevedo L**, Gamboa-Dominguez A. Carcinoid tumors of the duodenum and ampulla of Vater: a clinicomorphologic, immunohistochemical, and cell kinetic comparison. *Hum Pathol* 2001; **32**: 1252-1256
- 9 **Suzuki H**, Kuwano H, Masuda N, Tuboi K, Wada S, Saitoh T, Kanoh K, Nomoto K, Shimura T. Carcinoid of the papilla of Vater; a case report. *Hepatogastroenterology* 2003; **50**: 371-373
- 10 **McCabe HL**. Adenocarcinoma of the gastro-oesophageal junction with a synchronous carcinoid of the duodenum. *Postgrad Med J* 2001; **77**: 255-256
- 11 **Gerstle JT**, Kauffman GL, Koltun WA. The incidence, management, and outcome of patients with gastrointestinal carcinoids and second primary malignancies. *J Am Coll Surg* 1995; **180**: 427-432
- 12 **Berner M**. Digestive carcinoids and synchronous malignant tumors. *Helv Chir Acta* 1993; **59**: 757-766
- 13 **Campbell DM**, McDermott EW, O'Dwyer PJ, Murphy JJ. Duodenal carcinoid tumour associated with gastric leiomyoblastoma. *Eur J Surg Oncol* 1992; **18**: 296-297
- 14 **Nelson RL**. The association of carcinoid tumors of the rectum with myelofibrosis: report of two cases. *Dis Colon Rectum* 1981; **24**: 548-549
- 15 **Lara JF**, Rosen PP. Extramedullary hematopoiesis in a bronchial carcinoid tumor. An unusual complication of agnogenic myeloid metaplasia. *Arch Pathol Lab Med* 1990; **114**: 1283-1285

Science Editor Li WZ Language Editor Elsevier HK