

• CASE REPORT •

Calcified reticulate rind sign: A characteristic feature of gossypiboma on computed tomography

Yi-Ying Lu, Yun-Chung Cheung, Sheung-Fat Ko, Shu-Hang Ng

Yi-Ying Lu, Yun-Chung Cheung, Sheung-Fat Ko, Shu-Hang Ng, Department of Diagnostic Radiology, Chang Gung Memorial Hospital, Taiwan, China

Yun-Chung Cheung, Sheung-Fat Ko, Shu-Hang Ng, College of Medicine and School of Medical Technology, Chang Gung University, Taiwan, China

Correspondence to: Shu-Hang Ng, MD, Department of Diagnostic Radiology, Chang Gung Memorial Hospital at Linkou, 5-Fu-Shing Street, Kwei Shan, TaoYuan, Taiwan, China. shng@adm.cgmh.org.tw

Telephone: +886-3-3281200-2574 Fax: +886-2-25469220

Received: 2004-12-17 Accepted: 2005-01-13

Abstract

We herein report a gossypiboma resulting from a retained surgical swab, which had been left in peritoneum for 20 years after appendectomy. CT revealed a cystic mass with a calcified reticulate rind. Subsequent surgery and pathological examination showed a gossypiboma. A simple experiment, using a barium-soaked surgical swab demonstrating similar CT appearance, supported our postulation that calcium deposition on the reticulated fibers of a surgical swab could generate such a characteristic "calcified reticulate rind" sign. We believe that identification of this CT sign facilitates the diagnosis of gossypibomas.

© 2005 The WJG Press and Elsevier Inc. All rights reserved.

Key words: Gossypiboma; Textiloma; Retained surgical swab; CT

Lu YY, Cheung YC, Ko SF, Ng SH. Calcified reticulate rind sign: A characteristic feature of gossypiboma on computed tomography. *World J Gastroenterol* 2005; 11(31): 4927-4929 <http://www.wjgnet.com/1007-9327/11/4927.asp>

INTRODUCTIONS

Gossypiboma (also called textiloma), an infrequent complication of surgery, is a mass lesion owing to a retained surgical swab surrounded by foreign-body reaction. Because the symptoms of gossypiboma usually are non-specific and may appear years after surgery, awareness of a gossypiboma usually comes from imaging studies^[1,2]. The most specific imaging finding of a gossypiboma is a radiopaque marker on plain radiography, followed by entrapment of air bubbles in a spongiform pattern on CT^[1,2]. However, it is difficult to diagnose some long-lasting gossypibomas with these two

imaging findings because the surgical swabs used long time ago may not contain radiopaque markers, surrounding calcifications increased with time may mask radiopaque markers, and gas bubbles within a gossypiboma do not last for years. Herein, we describe a long-lasting gossypiboma with the "calcified reticulate rind" on CT which may ascribe to long-standing deposition of calcifications along the network architecture of a surgical swab. Identification of this novel CT feature may help doctors to diagnose some long-lasting gossypibomas.

CASE REPORT

A 43-year-old man sought medical attention due to progressive abdominal fullness and right flank pain for 2 mo. He denied fever, chill, nausea, vomiting, constipation, dysuria, gross hematuria, or body weight loss. Physical examination revealed a soft mass at the right lower quadrant of his abdomen. The blood cell count, blood chemistries, and urinalysis were all within the normal range. He received appendectomy at another hospital 20 years ago and also underwent bilateral vasectomy for contraception at our hospital 4 mo prior to this admission.

Abdominal radiograph revealed a round pelvic mass with a calcified rim (Figure 1). Intravenous urogram revealed right moderate hydronephrosis due to distal ureteral compression by the pelvic mass. Pre-enhanced CT scan demonstrated a 10-cm cystic lesion, with a thick calcified rind, which exhibited a reticulate pattern (Figures 2 and 3). Enhanced CT showed no abnormal contrast enhancement. During laparotomy, a 10 cm×10 cm cystic lesion with a well-defined fibrotic wall was disclosed in the pelvic cavity. Adhesion of the lesion to the right lower ureter was also noted. On gross examination, a piece of gauze of about 10 cm×4 cm×0.2 cm containing necrotic debris was removed from the thick-wall cystic lesion. Microscopic examination revealed suture granuloma, cholesterol clefts, fibrinoid necrosis, fibrosis, and calcification on the capsule. The final diagnosis was gossypiboma, plausibly resulted from the retained gauze during the appendectomy performed 20 years ago.

We postulated that the "calcified reticulate rind" in this gossypiboma might result from a gradual calcium deposition along the fiber network of the surgical swab. A simple experiment was performed for correlation. We soaked a piece of surgical swab with radiopaque marker in diluted barium. After drying the swab and wrapping it into a mass, we scanned it with CT. CT revealed a reticulate rind pattern (Figures 2 and 3), similar to that of the "calcified reticulate rind" of the gossypiboma noted in our case.

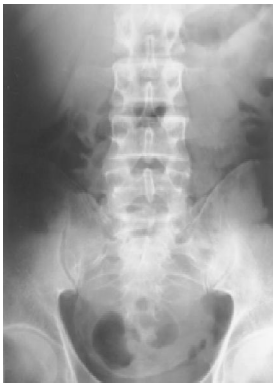

Figure 1 A round mass in pelvis with rim calcification on the abdominal plain radiograph.

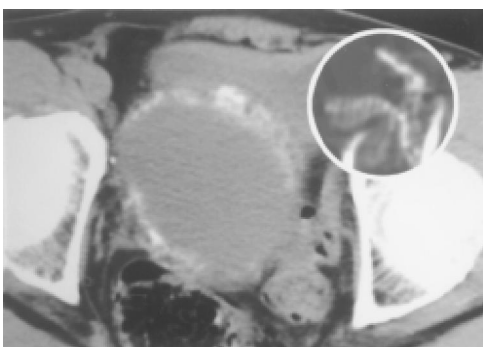


Figure 2 A cystic lesion in pelvic cavity with a thick "calcified reticulate rind" demonstrated by pre-enhanced CT scan.

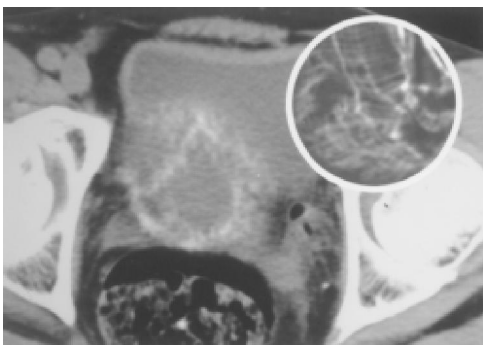


Figure 3 "Calcified reticulate rind" on another level (2 cm below Figure 2) demonstrated by pre-enhanced CT scan.

DISCUSSION

The term gossypiboma is derived from the Latin word gossypium, meaning cotton, and Kiswahili word boma, meaning place of concealment. This is an uncommon surgical complication with an estimated incidence of 1/1 500^[3]. Gossypibomas are most frequently discovered in the abdomen. However, their occurrences in the thorax^[4], extremity^[5], central nervous system^[6], and breast^[7] have also been reported. Pathologically, there are two types of foreign body reactions in gossypibomas. One is an aseptic fibrous response resulting in adhesion, encapsulation, and

granuloma, and the other is an exudative reaction leading to cyst or abscess formation^[8].

The most impressive imaging finding of gossypibomas is the curved or banded radiopaque lines on plain radiograph or CT, which represent the radiopaque markers of the surgical swabs. However, calcification depositions over the surgical gauze may mask the characteristic radiopaque markers, and some surgical swabs used long time ago may not have radiopaque markers. Hence, such radiographic finding may not be seen in every gossypiboma. On CT, a gossypiboma may manifest as a cystic lesion with internal spongiform appearance with mottled gas bubbles, hyperdense capsule, concentric layering, or mottled mural calcifications^[4,9-12]. In a series of 13 cases of gossypiboma found 3 mo to 8 years after surgery, Lars Kopka *et al.*^[2] suggested that the spongiform pattern with entrapped gas bubbles is the most specific CT finding for gossypibomas with an incidence of 54%. They also found that gas bubbles within a gossypiboma decrease slowly with time in an experiment. On MRI, gossypibomas may appear as a low-signal-intensity lesion on T2-weighted images with wavy, striped or spotted appearances^[13-15].

In our case, the gossypiboma might be due to the retention of the gauze during appendectomy 20 years ago. We could not find the conventional characteristic imaging findings of gossypibomas, such as the radiopaque markers and the spongiform pattern with entrapped air bubbles. The plausible explanations are that most surgical swabs at that moment usually contain no radiopaque markers while the air bubbles are completely absorbed after such a long duration of 20 years. Instead, this unique case demonstrated a novel imaging feature of gossypiboma, so-called the "calcified reticulate rind" sign which is probably formed by gradual deposition of calcifications along the fiber network of the surgical gauze. To our knowledge, this CT feature of gossypiboma has not been previously reported.

In summary, this report documents a unique case of gossypiboma that exhibits a "calcified reticulate rind", a characteristic feature of gossypiboma.

REFERENCES

- 1 Willian RG, Bragg DG, Nelson JA. Gossypiboma-the problem of the retained surgical sponge. *Radiology* 1978; **129**: 323-326
- 2 Kopka L, Fischer U, Gross AJ, Funke M, Oestmann JW, Grabbe E. CT of retained surgical sponges (textilomas): pitfalls in detection and evaluation. *J Comput Assist Tomogr* 1996; **20**: 919-923
- 3 Rappaport W, Haynes K. The retained surgical sponge following intra-abdominal surgery. A continuing problem. *Arch Surg* 1990; **125**: 405
- 4 Sheehan RE, Sheppard MN, Hansell DM. Retained intrathoracic surgical swab: CT appearances. *J Thorac Imaging* 2000; **15**: 61-64
- 5 Abdul-Karim FW, Benevenia J, Pathria MN, Makley JT. Case report 736: Retained surgical sponge (gossypiboma) with a foreign body reaction and remote and organizing hematoma. *Skeletal Radiol* 1992; **21**: 466-469
- 6 Mathew JM, Rajshekhar V, Chandy MJ. MRI features of neurosurgical gossypiboma: report of two cases. *Neuroradiology* 1996; **38**: 468-469
- 7 El Khoury M, Mignon F, Tardivon A, Mesurolle B, Rochard F, Mathieu MC. Retained surgical sponge or gossypiboma of

- the breast. *Eur J Radiol* 2002; **42**: 58-61
- 8 **Olnick HM**, Weens HS, Robers JV Jr. Radiological diagnosis of retained surgical sponges. *J Am Med Assoc* 1955; **159**: 1525-1527
- 9 **Buy JN**, Hubert C, Ghossain MA, Malbec L, Bethoux JP, Ecoiffier J. Computed tomography of retained abdominal sponges and towels. *Gastrointest Radiol* 1989; **14**: 41-45
- 10 **Kokubo T**, Itai Y, Ohtomo K, Yoshikawa K, Iio M, Atomi Y. Retained surgical sponges: CT and US appearance. *Radiology* 1987; **165**: 415-418
- 11 **Choi BI**, Kim SH, Yu ES, Chung HS, Han MC, Kim CW. Retained surgical sponge: diagnosis with CT and sonography. *AJR Am J Roentgenol* 1988; **150**: 1047-1050
- 12 **Parienty RA**, Pradel J, Lepreux JF, Nicodeme C, Dologa M. Computed tomography of sponges retained after laparotomy. *J Comput Assist Tomogr* 1981; **5**: 187-189
- 13 **Kuwashima S**, Yamato M, Fujioka M, Ishibashi M, Kogure H, Tajima Y. MR findings of surgically retained sponges and towels: report of two cases. *Radiat Med* 1993; **11**: 98-101
- 14 **Sugimura H**, Tamura S, Kakitsubata Y, Kakitsubata S, Uwada O, Kihara Y, Nagatomo M, Watanabe K. Magnetic resonance imaging of retained surgical sponges. Case report. *Clin Imaging* 1992; **16**: 259-262
- 15 **Roumen RM**, Weerdenburg HP. MR features of a 24-year-old gossypiboma. A case report. *Acta Radiol* 1998; **39**: 176-178

Science Editor Wang XL and Guo SY Language Editor Elsevier HK