

• CASE REPORT •

Recurrent thrombotic occlusion of a transjugular intrahepatic portosystemic stent-shunt due to activated protein C resistance

Elmar Siewert, Jan Salzmann, Edmund Purucker, Karl Schürmann, Siegfried Matern

Elmar Siewert, Jan Salzmann, Edmund Purucker, Siegfried Matern, Department of Internal Medicine III, Aachen University, Aachen, Germany

Karl Schürmann, Department of Diagnostic Radiology, Aachen University, Aachen, Germany

Correspondence to: Dr. Elmar Siewert, Pauwelsstr. 30, Department of Internal Medicine III, Aachen University, Aachen D-52074, Germany. siewert@rwth-aachen.de

Telephone: +49-241-8088634 Fax: +49-241-8082455

Received: 2004-12-30 Accepted: 2005-01-13

Abstract

The transjugular intrahepatic portosystemic stent-shunt (TIPS) has successfully been used in the management of refractory variceal bleeding and ascites in patients with portal hypertension. Major drawbacks are the induction of hepatic encephalopathy and shunt dysfunction. We present a 59-year-old woman with alcoholic liver cirrhosis who received a TIPS because of recurrent bleeding from esophageal varices. Stent occlusion occurred 4 mo after placement of the TIPS. Laboratory testing revealed resistance to activated protein C (APC). Combination therapy with low-dose enoxaparin and clopidogrel could not prevent her recurrent stent occlusion. Finally, therapy with high-dose enoxaparin was sufficient to prevent further shunt complications up to now (follow-up period of 1 year). In conclusion, early occlusion of a TIPS warrants testing for thrombophilia. If risk factors are confirmed, anticoagulation should be intensified. There are currently no evidence-based recommendations regarding the best available anticoagulant therapy and surveillance protocol for patients with TIPS.

© 2005 The WJG Press and Elsevier Inc. All rights reserved.

Key words: Transjugular intrahepatic portosystemic stent-shunt; Resistance to activated protein C; Factor V-Leiden; Thrombophilia; Thrombosis

Siewert E, Salzmann J, Purucker E, Schürmann K, Matern S. Recurrent thrombotic occlusion of a transjugular intrahepatic portosystemic stent-shunt due to activated protein C resistance. *World J Gastroenterol* 2005; 11(32): 5064-5067
<http://www.wjgnet.com/1007-9327/11/5064.asp>

INTRODUCTION

Cirrhosis, the common end stage of various chronic liver diseases, results from the necrosis of liver cells and increased

connective tissue production (fibrosis) with nodule formation. The distorted liver architecture interferes with liver function and blood flow, thereby producing the clinical features of impaired liver cell function and portal hypertension. When the portal vein pressure, which normally is around 7 mmHg, rises above 14 mmHg, splenomegaly, ascites and collaterals develop between the portal and systemic circulation^[1]. Ascites can be treated by diuretics and paracentesis, and esophago-gastric varices by β -blockers, vasoactive drugs (octreotide, terlipressin) and endoscopic procedures (variceal band ligation, sclerotherapy) respectively^[1]. Alternatively, a transjugular intrahepatic portosystemic stent-shunt (TIPS) which leads to portal decompression can be inserted by creation of a communication between a central hepatic vein and an intrahepatic branch of the portal vein. The idea of creating an intrahepatic shunt was first introduced more than 30 years ago^[2]. The use of an expandable metal stent was further developed in the 1980s. The relative ease with which the stent can be placed has led to the widespread use of TIPS for the treatment of many complications of portal hypertension (acute variceal hemorrhage, prevention of re-bleeding from varices, control of ascites, hepato-renal failure, hepato-pulmonary syndrome and hepatic hydrothorax^[3-7]), acute and chronic Budd-Chiari syndrome^[8] or portal vein thrombosis^[9-11]. We report a 59-year-old woman with alcoholic liver cirrhosis, who had recurrent TIPS occlusion after having received a TIPS because of variceal bleeding. Thrombophilia results from resistance to activated protein C (APC) and demands intensification of anticoagulant therapy, which prevents further stent dysfunction.

CASE REPORT

History and examination

Alcoholic liver cirrhosis (Child-Pugh class A) in a 59-year-old woman was complicated by recurrent hemorrhages from esophago-gastric varices. Finally, she was referred to our clinic with the request that a TIPS should be inserted. The past medical history was uneventful, except for an appendectomy at age 12, a hysterectomy because of intramural uterine fibroids and surgery for varicose veins. There was no history of venous thrombosis or embolism, but an episode of transient ischemic attack seemed to have occurred because the patient reported a brief episode of aphasia and weakness in her right arm, 3 years ago. She admitted alcohol dependence for a period of approximately 5 years.

Examination revealed that she was in slightly reduced general health condition and nutritional status with a

BMI of 20.8 kg/m² (58 kg, 1.67 m). There was neither lymphadenopathy nor jaundice nor edema. Some facial telangiectasia and spider naevi on the upper chest could be found, but no palmar erythema or other skin liver signs. Blood pressure was 115/60 mmHg, heart beats were regular at 74/min. Examination of the cardiovascular, respiratory, and abdominal systems was normal.

Blood tests and investigations

Routine laboratory testing revealed the following pathological parameters (normal range): hemoglobin 82 g/L (120-160 g/L), MCV 98 fL (<93 fL), platelets 104 000 G/L (150 000-350 000 G/L), aPTT (activated partial thromboplastin time) 46 s (28-45 s), INR 1.1 and Quick 75% (70-100%), CRP 25 mg/L (<5 mg/L), total protein 54 g/L (66-83 g/L), albumin 28 g/L (34-48 g/L), γ -globulins 22% (14-19%), total bilirubin 1.2 mg/dL (<1.1 mg/dL), γ -GT 120 U/L (<19 U/L), alkaline phosphatase 206 U/L (<180 U/L), pseudocholinesterase 2 127 U/L (>3 500 U/L). Serologically, there was no evidence for current or previous hepatitis A, B, or C.

On abdominal ultrasound, liver size was reduced to 9.6 cm in the right mid-clavicular line, the surface was irregular, the echogenicity enhanced. The spleen was enlarged to 15 cm×5 cm with no ascites. Color Doppler sonography demonstrated orthograde flow in the portal vein, but velocity was reduced to 4 cm/s on duplex sonography. Gastroscopy confirmed the fourth grade esophageal varices with scarring due to previous sclerotherapy, fundal gastric varices, and hypertensive gastropathy.

Treatment and follow-up

A TIPS (expandable metal Wallstent, Boston Scientific/Ratingen Germany, 10 mm in diameter) was inserted without any short-term complications. Post-interventionally, 75 mg of clopidogrel, an inhibitor of platelet aggregation, was taken orally once daily, and the patient was discharged from the hospital. The portocaval pressure gradient decreased from 24 to 7 mmHg. On an outpatient-visit 4 mo later, the patient was in good general health and asymptomatic, but color Doppler sonography and duplex sonography revealed thrombotic occlusion of the TIPS. Therefore, she was re-admitted to our hospital. Gastroscopy again found the fourth grade esophageal varices (Figure 1A). Shunt angiography verified TIPS occlusion (Figure 2A), and shunt revision was successfully performed (Figure 2B). Control gastroscopy confirmed excellent size reduction of the varices (Figure 1B). Additionally, screening laboratory testing for thrombophilia was initiated, and heterozygous factor V-Leiden resulting in resistance to APC was identified by PCR. Therefore, clopidogrel medication was supplemented with daily subcutaneous self-injections of 40 mg enoxaparin, a low molecular weight heparin. Intensified anticoagulation could not prevent the recurrent stent occlusion 2 mo after revision of the shunt, which became obvious on routine color Doppler examination after an additional 2 mo. Once again, TIPS revision was successfully performed. Due to repeated thrombosis, anticoagulant therapy was further intensified. In addition to clopidogrel, high-dose enoxaparin (60 mg twice daily s.c.) was initiated, which was sufficient to

prevent further shunt complications up to now, i.e. a follow-up period of 1 year.

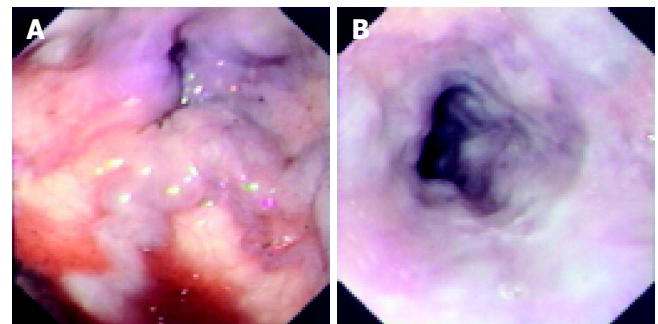


Figure 1 Esophageal varices before (A) and after (B) TIPS revision.

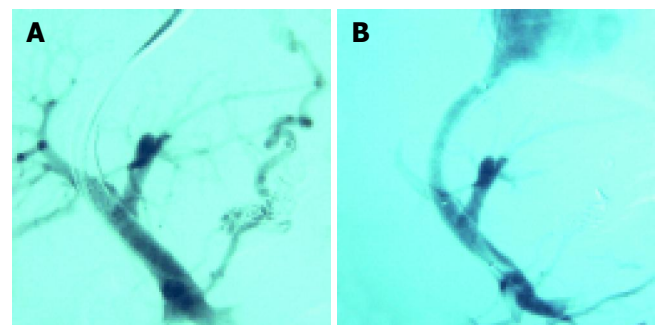


Figure 2 Shunt angiography before (A) and after (B) TIPS revision.

DISCUSSION

Though TIPS placement is used as a treatment modality for the complications of portal hypertension, only in the case of refractory ascites (four randomized controlled trials) and recurrent variceal hemorrhage, as in the patient presented here (12 randomized controlled trials), TIPS has been compared to other forms of therapy. The superiority of TIPS with regard to symptom control could be demonstrated, whereas insertion of a TIPS could not improve survival. TIPS is widely accepted as the main second-line treatment option for acute variceal hemorrhage not responding to other treatment options^[3-7,12,13].

On the one hand, TIPS is an elegant therapeutic procedure with a low (1-2%) procedure-related mortality^[4,5,7] thus offering the chance of taking a diagnostic transjugular liver biopsy in patients with advanced liver cirrhosis. Moreover, TIPS does not hamper or exclude future liver transplantation because normal anatomy of the extrahepatic vessels is preserved. Indeed, it can serve as a valuable bridging procedure to liver transplantation. On the other hand, placement of a TIPS can be complicated by substantial acute and chronic morbidity^[3,4,14] (Table 1). The major long-term drawback of TIPS besides the induction or worsening of hepatic encephalopathy^[15,16] is stent dysfunction due to occlusion or stenosis. Meta-analysis indicates that within 2 years of TIPS creation, re-intervention to re-establish or maintain the patency of the shunt is required in 70-90% of patients, and total occlusion occurs in 20-40% of patients.

Nevertheless the secondary or assisted patency rate during a 2- to 5-year follow-up period is between 72% and 91%^[3,16-20].

Stent occlusion during the first month after TIPS placement is mainly a consequence of shunt thrombosis, thereafter, shunt stenosis in most cases is the result of pseudointimal hyperplasia^[3-5,20]. We described a patient with repeated shunt thrombosis for a longer time period due to resistance to APC. Hence, in patients with recurrent thrombotic TIPS occlusion, hypercoagulopathy as a risk factor for shunt complications should be ruled out. APC resistance (or Factor V-Leiden) as a cause of familial thrombophilia was first described in 1993^[21]. A point mutation in the gene encoding factor V (G1691A) leads to a conformational change at the site, where factor Va is cleaved by APC and thereby inactivated. Prolonged activation of factor V results in hypercoagulopathy. Heterozygous factor V mutation carriers have a 5-10-fold increased risk of thromboembolic events, and in patients with homozygous factor V mutation, the risk shoots up further^[22,23]. Prevalence of the mutation is about 5% in the normal population, and inheritance follows an autosomal dominant manner. Other major causes of inherited and acquired thrombophilia which have to be excluded are listed in Table 2.

In the patient described here, escalation of anticoagulation combining the usually given inhibitors of platelet aggregation with low molecular weight heparin in therapeutic dosage was sufficient to prevent further shunt occlusions. However, no data are currently available on the optimal anticoagulant therapy to prevent shunt occlusion. When a TIPS is placed for the prevention of variceal re-bleeding, peri-interventional anticoagulation with heparin is recommended to reduce early shunt occlusion^[17]. Additional therapy with the inhibitors of platelet aggregation, ticlopidine and trapidil for 6 mo after initial intravenous heparin for 24 h significantly reduces the rate of TIPS stenosis^[24]. In a recent review article, the use of subcutaneous low-dose low molecular weight heparin for 4 wk, together with trapidil and ticlopidine for 12 mo^[3] is suggested. Higher dosage of heparin seems to be necessary in patients with thrombophilia, but in a controlled trial, phenprocoumon does not reduce the risk of early stent occlusion or later stent stenosis in patients without hypercoagulopathy^[25]. Moreover, since the risk of bleeding is significant in patients with cirrhosis, the use of oral anticoagulants with long half-lives is problematic. Alternatively, coated stents or drug-eluting stents can probably protect against shunt thrombosis, and preliminary results indicate that the rates of stent thrombosis and occlusion can be reduced^[26-30]. However, patients must be selected more carefully, because covered stents have a higher risk of hepatic encephalopathy^[31].

The high rates of shunt dysfunction with the resulting risk of re-bleeding ask for a surveillance program of TIPS patients. Unfortunately, follow-up protocols differ significantly between centers because the optimal regime is unknown. Duplex ultrasonography at intervals of 3-6 mo has been practiced in most studies exhibiting a sensitivity of 53-100% and a specificity of 62-98% in detecting shunt insufficiency^[3,4,17], although a recent study has reported a poorer sensitivity of only 35%^[32]. However, the finding of shunt dysfunction does not always make shunt revision

mandatory. When duplex sonography confirms TIPS occlusion or when the technique does not yield a clear result, an endoscopic re-evaluation is followed. Only when significant varices can be demonstrated, shunt angiography with measurement of the portal-venous pressure gradient is necessary and clearly discriminates whether radiological shunt revision is indicated or not.

In conclusion, TIPS is an elegant procedure which simultaneously serves as a diagnostic and therapeutic tool in patients with complications of portal hypertension. Shunt dysfunction by thrombosis or neointimal proliferation, the major complication besides worsening of hepatic encephalopathy, may be reduced temporarily by using inhibitors of thrombocyte aggregation and (low molecular weight) heparin. Repeated thrombotic TIPS occlusion is mostly due to thrombophilia, which requires more extensive laboratory testing to detect the underlying inherited or acquired coagulation disorder(s).

Table 1 Complications of TIPS

Acute complications	Chronic complications
Transcapsular puncture	Deterioration of liver function
Intrahepatic hematoma	New or worsened hepatic encephalopathy
Intraperitoneal bleed	TIPS dysfunction (thrombosis, stenosis)
Fistulae:	Hyperdynamic circulation and cardiac failure
Hemobilia	
Arterio-portal fistulae	
Malpuncture of other organs	
Portal vein thrombosis	
TIPS dislocation	
Infections and sepsis	
Hemolysis	
Contrast media-related complications:	
Allergic reactions	
Acute renal failure	
Cardiac arrhythmias/myocardial infarction	

Table 2 Causes of thrombophilia

Hereditary causes	Acquired causes
Resistance to APC = Factor V-Leiden (Factor V gene mutation G1691A)	Antiphospholipid syndrome
Prothrombin gene mutation (G20210A)	Lupus anticoagulant
Antithrombin III deficiency	Malignancy and myeloproliferative disorders
Hyperhomocysteinemia (MTHFR mutation)	Hyperviscosity (multiple myeloma)
Protein C deficiency	Cardiac failure and any type of shock
Protein S deficiency	
Dysfibrinogenemia	Nephrotic syndrome
Increased factor VIII and PAI-1	Liver cirrhosis
Plasminogen deficiency	Protein-losing enteropathy
tPA deficiency	Chronic inflammatory bowel disease
	Hemolytic uremic syndrome
	Thrombotic thrombocytopenic purpura
	Post-surgery, post-traumatic, immobilization
	Oral contraceptives and smoking
	Obesity
	Pregnancy
	Geriatric patients

REFERENCES

- 1 **Sherlock S**, Dooley J. Diseases of the liver and biliary system. 10th ed. Oxford: *Blackwell Sci Pub* 1997: 135-180
- 2 **Rosch J**, Hanafee W, Snow H, Barenfus M, Gray R. Transjugular intrahepatic portacaval shunt. An experimental work. *Am J Surg* 1971; **121**: 588-592
- 3 **Rossle M**, Grandt D. TIPS: an update. *Best Pract Res Clin Gastroenterol* 2004; **18**: 99-123
- 4 **Boyer TD**. Transjugular intrahepatic portosystemic shunt: current status. *Gastroenterology* 2003; **124**: 1700-1710
- 5 **Rosado B**, Kamath PS. Transjugular intrahepatic portosystemic shunts: an update. *Liver Transpl* 2003; **9**: 207-217
- 6 **McCashland TM**. Current use of transjugular intrahepatic portosystemic shunts. *Curr Gastroenterol Rep* 2003; **5**: 31-38
- 7 **Hassoun Z**, Pomier-Layrargues G. The transjugular intrahepatic portosystemic shunt in the treatment of portal hypertension. *Eur J Gastroenterol Hepatol* 2004; **16**: 1-4
- 8 **Menon KV**, Shah V, Kamath PS. The Budd-Chiari-Syndrome. *N Engl J Med* 2004; **350**: 578-585
- 9 **Jiang ZB**, Shan H, Shen XY, Huang MS, Li ZR, Zhu KS, Guan SH. Transjugular intrahepatic portosystemic shunt for palliative treatment of portal hypertension secondary to portal vein tumor thrombosis. *World J Gastroenterol* 2004; **10**: 1881-1844
- 10 **Bilbao JL**, Elorz M, Vivas I, Martinez-Cuesta A, Bastarrika G, Benito A. Transjugular intrahepatic portosystemic shunt (TIPS) in the treatment of venous symptomatic chronic portal thrombosis in non-cirrhotic patients. *Cardiovasc Intervent Radiol* 2004; **27**: 474-480
- 11 **Opitz T**, Buchwald AB, Lorf T, Awuah D, Ramadori G, Nolte W. The transjugular intrahepatic portosystemic stent-shunt (TIPS) as rescue therapy for complete Budd-Chiari syndrome and portal vein thrombosis. *Z Gastroenterol* 2003; **41**: 413-418
- 12 **Lata J**, Hulek P, Vanasek T. Management of acute variceal bleeding. *Dig Dis* 2003; **21**: 6-15
- 13 **Ferguson JW**, Tripathi D, Hayes PC. Review article: the management of acute variceal bleeding. *Aliment Pharmacol Ther* 2003; **18**: 253-262
- 14 **Kamath PS**, McKusick MA. Transvenous intrahepatic portosystemic shunts. *Gastroenterology* 1996; **111**: 1700-1705
- 15 **Luca A**, D'Amico G, La Galla R, Midiri M, Morabito A, Pagliaro L. TIPS for prevention of recurrent bleeding in patients with cirrhosis: meta-analysis of randomized clinical trials. *Radiology* 1999; **212**: 411-421
- 16 **Papatheodoridis GV**, Goulis J, Leandro G, Patch D, Burroughs AK. Transjugular intrahepatic portosystemic shunt compared with endoscopic treatment for prevention of variceal rebleeding: A meta-analysis. *Hepatology* 1999; **30**: 612-622
- 17 **Rossle M**, Siegerstetter V, Huber M, Ochs A. The first decade of the transjugular intrahepatic portosystemic shunt (TIPS): state of the art. *Liver* 1998; **18**: 73-89
- 18 **Tripathi D**, Helmy A, Macbeth K, Balata S, Lui HF, Stanley AJ, Redhead DN, Hayes PC. Ten years' follow-up of 472 patients following transjugular intrahepatic portosystemic stent-shunt insertion at a single centre. *Eur J Gastroenterol Hepatol* 2004; **16**: 9-18
- 19 **ter Borg PC**, Hollemans M, Van Buuren HR, Vleggaar FP, Groeneweg M, Hop WC, Lameris JS. Transjugular intrahepatic portosystemic shunts: long-term patency and clinical results in a patient cohort observed for 3-9 years. *Radiology* 2004; **231**: 537-545
- 20 **van Buuren HR**, ter Borg PC. Transjugular intrahepatic portosystemic shunt (TIPS): indications and long-term patency. *Scand J Gastroenterol Suppl* 2003; **239**: 100-104
- 21 **Dahlback B**, Carlsson M, Svensson PJ. Familial thrombophilia due to a previously unrecognized mechanism characterized by poor anticoagulant response to activated protein C: prediction of a cofactor to activated protein C. *Proc Natl Acad Sci USA* 1993; **90**: 1004-1008
- 22 **Ridker PM**, Miletich JP, Stampfer MJ, Goldhaber SZ, Lindpaintner K, Hennekens CH. Factor V Leiden and risks of recurrent idiopathic venous thromboembolism. *Circulation* 1995; **92**: 2800-2802
- 23 **Dulicek P**, Maly J, Safarova M. A prospective study of asymptomatic carriers of the factor V Leiden mutation to determine the incidence of venous thromboembolism. *Ann Intern Med* 2001; **135**: 322-327
- 24 **Siegerstetter V**, Huber M, Ochs A, Blum HE, Rossle M. Platelet aggregation and platelet-derived growth factor inhibition for prevention of insufficiency of the transjugular intrahepatic portosystemic shunt: a randomized study comparing trapidil plus ticlopidine with heparin treatment. *Hepatology* 1999; **29**: 33-38
- 25 **Sauer P**, Theilmann L, Herrmann S, Bruckner T, Roeren T, Richter G, Stremmel W, Stiehl A. Phenprocoumon for prevention of shunt occlusion after transjugular intrahepatic portosystemic stent shunt: a randomized trial. *Hepatology* 1996; **24**: 1433-1436
- 26 **Rossi P**, Salvatori FM, Fanelli F, Bezzi M, Rossi M, Marcelli G, Pepino D, Riggio O, Passariello R. Polytetrafluoroethylene-covered nitinol stent-graft for transjugular intrahepatic portosystemic shunt creation: 3-year experience. *Radiology* 2004; **231**: 820-830
- 27 **Charon JP**, Alaeddin FH, Pimpalwar SA, Fay DM, Olliff SP, Jackson RW, Edwards RD, Robertson IR, Rose JD, Moss JG. Results of a retrospective multicenter trial of the Viatorr expanded polytetrafluoroethylene-covered stent-graft for transjugular intrahepatic portosystemic shunt creation. *J Vasc Interv Radiol* 2004; **15**: 1219-1230
- 28 **Haskal ZJ**, Weintraub JL, Susman J. Recurrent TIPS thrombosis after polyethylene stent-graft use and salvage with polytetrafluoroethylene stent-grafts. *J Vasc Interv Radiol* 2002; **13**: 1255-1259
- 29 **Cejna M**, Peck-Radosavljevic M, Thurnher SA, Hittmair K, Schoder M, Lammer J. Creation of transjugular intrahepatic portosystemic shunts with stent-grafts: initial experiences with a polytetrafluoroethylene-covered nitinol endoprosthesis. *Radiology* 2001; **221**: 437-446
- 30 **Bureau C**, Garcia-Pagan JC, Otal P, Pomier-Layrargues G, Chabbert V, Cortez C, Perreault P, Peron JM, Abrahams JG, Bouchard L, Bilbao JL, Bosch J, Rousseau H, Vinel JP. Improved clinical outcome using polytetrafluoroethylene-coated stents for TIPS: result of a randomized study. *Gastroenterology* 2004; **126**: 469-475
- 31 **Rossle M**, Mullen KD. Long-term patency is expected with covered TIPS stents: this effect may not always be desirable! *Hepatology* 2004; **40**: 495-497
- 32 **Owens CA**, Bartolone C, Warner DL, Aizenstein R, Hibblen J, Yaghamai B, Wiley TE, Layden TJ. The inaccuracy of duplex ultrasonography in predicting patency of transjugular intrahepatic portosystemic shunts. *Gastroenterology* 1998; **114**: 975-980

Science Editor Wang XL and Guo SY Language Editor Elsevier HK