

• CLINICAL RESEARCH •

# Narrow portion of the terminal choledochus is a cause of upstream biliary dilatation in patients with anomalous union of the pancreatic and biliary ducts

Tatsuya Nomura, Yoshio Shirai, Toshifumi Wakai, Naoyuki Yokoyama, Jun Sakata, Katsuyoshi Hatakeyama

Tatsuya Nomura, Yoshio Shirai, Toshifumi Wakai, Naoyuki Yokoyama, Jun Sakata, Katsuyoshi Hatakeyama, Division of Digestive and General Surgery, Niigata University Graduate School of Medical and Dental Sciences, 1 Asahimachi-dori, Niigata, 951-8510, Japan

Correspondence to: Dr. Yoshio Shirai, Division of Digestive and General Surgery, Niigata University Graduate School of Medical and Dental Sciences, 1 Asahimachi-dori, Niigata, 951-8510, Japan. shiray@med.niigata-u.ac.jp

Telephone: +81-25-227-2228 Fax: +81-25-227-0779

Received: 2005-04-13 Accepted: 2005-04-30

AUPBD, may be a cause of biliary dilatation in patients with AUPBD.

© 2005 The WJG Press and Elsevier Inc. All rights reserved.

**Key words:** Anomalous; Biliary dilatation; Congenital biliary dilatation; Congenital choledochal cyst; Terminal choledochus; Cholangiopancreatography

Nomura T, Shirai Y, Wakai T, Yokoyama N, Sakata J, Hatakeyama K. Narrow portion of the terminal choledochus is a cause of upstream biliary dilatation in patients with anomalous union of the pancreatic and biliary ducts. *World J Gastroenterol* 2005; 11(41):6503-6507  
<http://www.wjgnet.com/1007-9327/11/6503.asp>

## Abstract

**AIM:** To clarify the pathogenesis of biliary dilatation associated with anomalous union of the pancreatic and biliary ducts (AUPBD).

**METHODS:** Direct cholangiopancreatograms of 350 adult patients with or with suspicion of hepatobiliary or pancreatic disorders were reviewed. AUPBD was diagnosed cholangiopancreatographically, when the pancreaticobiliary ductal union was located above the narrow distal segment of the bile duct, which represents the action of the sphincter of Oddi. The narrow portion of the terminal choledochus was defined as symmetrical stricture of the common bile duct just above the pancreaticobiliary ductal union.

**RESULTS:** AUPBD was found in 36 patients. Among cholangiopancreatographic features, the narrow portion of the terminal choledochus was the most pathognomonic for AUPBD (accuracy, 98%); it was present in 29 (81%) patients with AUPBD, but was not found in any patients without AUPBD. Among patients with AUPBD, biliary dilatation (>10 mm) was more frequent in those with the narrow portion of the terminal choledochus (23/29) than in those without (2/7;  $P = 0.018$ ) AUPBD. Among the patients with both AUPBD and the narrow portion of the terminal choledochus, there was a strong negative correlation between the minimum diameter of the narrow portion and the maximum diameter of the choledochus ( $r = -0.78$ ,  $P < 0.001$ ), suggesting that the degree of biliary narrowing at the narrow portion correlates with that of upstream biliary dilatation.

**CONCLUSION:** The narrow portion of the terminal choledochus, a pathognomonic radiologic feature of

## INTRODUCTION

Anomalous union of the pancreatic and biliary ducts (AUPBD) is an uncommon congenital condition, which predisposes to various pancreaticobiliary disorders including congenital choledochal cyst<sup>[1-5]</sup>, biliary cancer<sup>[6-8]</sup>, and pancreatitis<sup>[9-12]</sup>, and is more commonly seen in Asian than in Western countries<sup>[13]</sup>. This anomaly is defined as the pancreaticobiliary ductal union located above the action of the sphincter of Oddi as first described by Babbitt<sup>[1]</sup>. Although direct cholangiopancreatography is the most reliable means of detecting this anomaly<sup>[14-16]</sup>, the pathognomonic cholangiopancreatographic features of AUPBD have not been fully delineated.

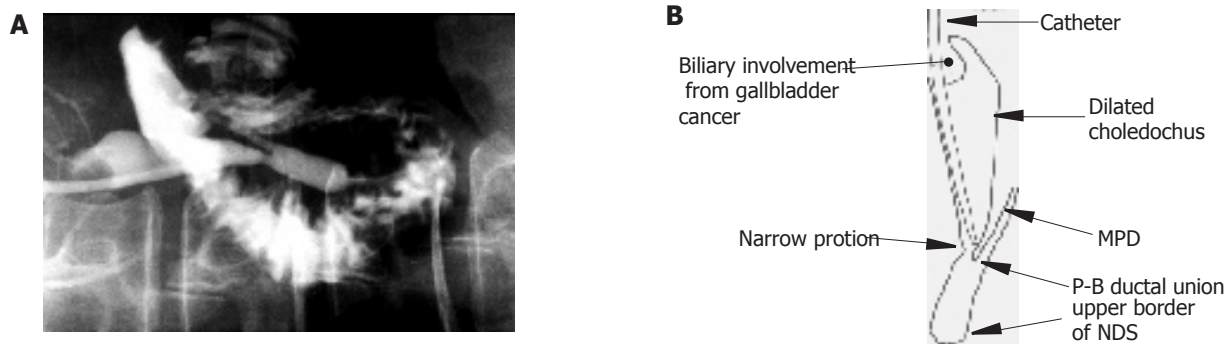
AUPBD is frequently accompanied by biliary dilatation<sup>[1-5]</sup>, but some patients with AUPBD show no biliary dilatation<sup>[8,17]</sup>. The causal relationship between AUPBD and biliary dilatation associated with this anomaly has not been fully established.

The aims of this study were to elucidate the cholangiopancreatographic features specific to AUPBD and to clarify the pathogenesis of biliary dilatation associated with AUPBD, by analyzing direct cholangiopancreatograms of 350 Japanese adult patients with or without AUPBD.


## MATERIALS AND METHODS

### Patients

From January 1988 to July 1999, 535 consecutive adult patients with or with suspicion of hepatobiliary or pancreatic disorders underwent direct cholangiopancrea-



**Figure 1** Endoscopic retrograde cholangiopancreatogram in a 55-year-old woman with gallbladder cancer associated with AUPBD and cylindrical biliary dilatation (A). Diagram of the cholangiopancreatogram (B). The minimum diameter of the narrow portion of the terminal choledochus is 4 mm, and the maximum diameter of the upstream choledochus is 15 mm. AUPBD: anomalous union of the pancreatic and biliary ducts; NDS: narrow distal segment; P-B ductal union: pancreaticobiliary ductal union; narrow portion: narrow portion of the terminal choledochus; MPD: main pancreatic duct.



**Figure 2** Endoscopic retrograde cholangiopancreatogram in a 21-year-old woman with AUPBD and cystic biliary dilatation (A). Diagram of the cholangiopancreatogram (B). The minimum diameter of the narrow portion of the terminal choledochus is 1.5 mm, and the maximum diameter of the upstream choledochus is 57 mm. Proximal dilatation of the MPD is also seen. AUPBD: anomalous union of the pancreatic and biliary ducts; NDS: narrow distal segment; P-B ductal union: pancreaticobiliary ductal union; narrow portion: narrow portion of the terminal choledochus; GB: gallbladder; MPD: main pancreatic duct.

tography before surgical intervention in our hospital. All were Japanese. Direct cholangiopancreatography included endoscopic retrograde cholangiopancreatography (ERCP) and percutaneous transhepatic cholangiography (PTC). One hundred and seventy-six patients were excluded due to biliary involvement from pancreaticobiliary malignancies which precluded opacification of the pancreaticobiliary ductal union, lack of opacification of one or both ducts, or failure to localize the pancreaticobiliary ductal union despite opacification of both ductal systems. Nine patients in whom the common bile and main pancreatic ducts entered separately into the duodenum were also excluded. The remaining 350 patients, in whom ERCP ( $n = 324$ ) or PTC ( $n = 26$ ) opacified the pancreaticobiliary ductal union, formed the basis of this retrospective study, including 174 women and 176 men with ages ranging from 18 to 86 years (median, 61 years). They included 118 patients with biliary malignancy, 118 with gallstone disease, 27 with liver tumor, 17 with pancreatic cancer, 16 with congenital choledochal cyst, 11 with chronic pancreatitis, and 43 with miscellaneous disorders.

#### **Cholangiopancreatographic diagnosis of AUPBD**

Although the criteria for AUPBD have not been standardized, the essential feature of this condition is the

pancreaticobiliary ductal union located above the action of the sphincter of Oddi as first described by Babbitt<sup>[1]</sup>. Thus, in this study, AUPBD was diagnosed cholangiopancreatographically when the pancreaticobiliary ductal union was located above the narrow distal segment (NDS), which represents the functional region of the sphincter of Oddi (Figures 1 and 2)<sup>[8,16,17]</sup>.

#### **Terminology of cholangiopancreatographic features**

Direct cholangiopancreatograms were reviewed in each of our patients to elucidate the presence or absence of the following major radiologic features: narrow portion of the terminal choledochus, biliary dilatation, and proximal dilatation of the main pancreatic duct.

The narrow portion of the terminal choledochus was defined as symmetrical stricture of the common bile duct just above the pancreaticobiliary ductal union and is a synonym for “stenosis of the distal choledochus”<sup>[3]</sup>, “narrow segment distal to the common bile duct”<sup>[18]</sup>, “narrow segment of the terminal bile duct”<sup>[19]</sup>, “narrow portion of the choledochus”<sup>[20]</sup>, “narrow segment of the common bile duct distal to choledochal cyst”<sup>[21]</sup>, and “narrowed duct segment distal to the biliary cyst”<sup>[22]</sup>. The narrow portion of the terminal choledochus was always located just below choledochal cysts, when cysts were

**Table 1** Diagnostic accuracy of cholangiopancreatographic features for the detection of AUPBD

Cholangiopancreatographic feature	Sensitivity(%)	Specificity(%)	Positive predictive value (%)	Negative predictive value (%)	Accuracy(%)
Narrow portion of the terminal choledochus ( <i>n</i> = 29)	81	100	100	98	98
Biliary dilatation (>10 mm) ( <i>n</i> = 25)	69	68	20	95	68
Proximal dilatation of the main pancreatic duct (>5 mm) ( <i>n</i> = 7)	19	100	100	91	92

AUPBD: anomalous union of the pancreatic and biliary ducts.

present. The minimum diameter of the narrow portion of the terminal choledochus (if any) and the maximum diameter of the upstream choledochus were measured on cholangiopancreatograms in each patient (Figures 1 and 2).

Biliary dilatation was defined as a diameter exceeding 10 mm<sup>[17]</sup>. Biliary dilatation was classified as cystic, fusiform, or cylindrical based on its contours on cholangiopancreatogram<sup>[23]</sup>.

Proximal dilatation of the main pancreatic duct was defined as the proximal portion of the main pancreatic duct with a diameter exceeding 5 mm<sup>[24,25]</sup>.

Kune first demonstrated that the NDS of the bile duct as visualized on cholangiopancreatography represents the functional region of the sphincter of Oddi<sup>[26-28]</sup>. The NDS was defined as the region lying between the upper border of the “notch” of the bile duct, sudden narrowing of the choledochal lumen just above the ampulla of Vater<sup>[29]</sup>, and the orifice of the ampulla of Vater (Figures 1 and 2).

### Statistical analysis

Statistics were calculated with the SPSS 9.0 J software package for Windows (SPSS Japan Inc., Tokyo, Japan). Fisher's exact test and the Spearman's rank correlation were used for data analysis. *P* values of <0.05 were accepted as statistically significant.

## RESULTS

AUPBD was diagnosed in 36 patients (10%) on direct cholangiopancreatograms, including 27 women and 9 men. They had concomitant pancreaticobiliary disorders, including congenital choledochal cyst (*n* = 16), gallbladder cancer (*n* = 13), benign gallbladder polyps (*n* = 3), chronic pancreatitis (*n* = 2), carcinoma of the common bile duct (*n* = 1), and adenomyomatosis of the gallbladder (*n* = 1).

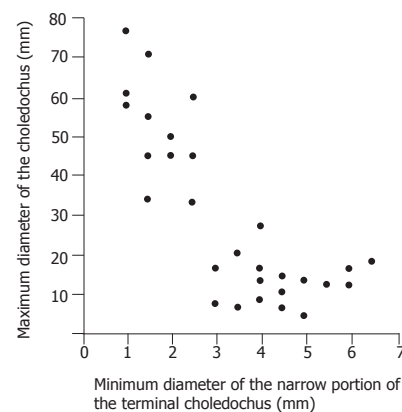
### Cholangiopancreatographic features specific to AUPBD

The accuracy of cholangiopancreatographic features for the detection of AUPBD is summarized in Table 1. The narrow portion of the terminal choledochus was present in 29 (81%) patients with AUPBD, but was not found in any patients without AUPBD.

### Relationship between the narrow portion of the terminal choledochus and upstream biliary dilatation

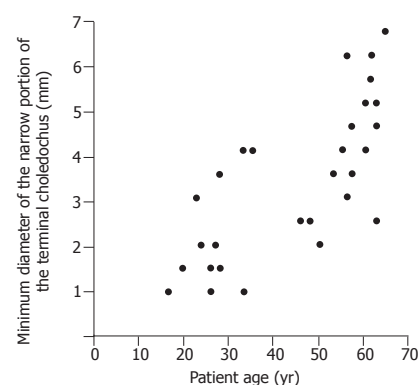
In 36 patients with AUPBD, biliary dilatation was more frequent in patients with the narrow portion of the terminal choledochus (23/29, 79%) than in those without (2/7, 28%; *P* = 0.018) AUPBD. Thus, the presence of the narrow portion of the terminal choledochus was associated with upstream biliary dilatation.

Among the 29 patients with both AUPBD and the narrow portion of the terminal choledochus, there was a strong negative correlation between the minimum diameter of the narrow portion of the terminal choledochus and the maximum diameter of the upstream choledochus (*r* = -0.78, *P* < 0.001) (Figure 3). Thus, the degree of biliary narrowing at the narrow portion of the terminal choledochus correlated with that of upstream biliary dilatation.

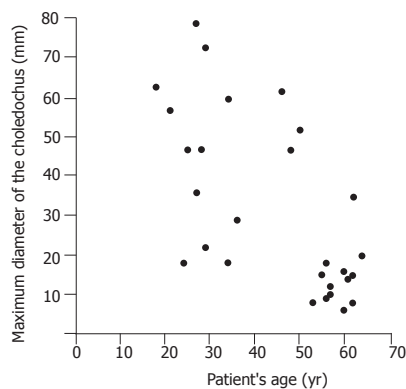


**Figure 3** There was a strong negative correlation between the minimum diameter of the narrow portion of the terminal choledochus and the maximum diameter of the upstream choledochus (*r* = -0.78, *P* < 0.001).

Also, among the 29 patients with both AUPBD and the narrow portion of the terminal choledochus, a strong positive correlation was noted between patient's age and the minimum diameter of the narrow portion of the terminal



**Figure 4** Patient's age was strongly correlated with the minimum diameter of the narrow portion of the terminal choledochus (*r* = 0.78, *P* < 0.001).



**Figure 5** Patient's age was negatively correlated with the maximum diameter of the choledochus ( $r = -0.53$ ,  $P = 0.001$ ).

choledochus ( $r = 0.78$ ,  $P < 0.001$ ) (Figure 4), whereas there was a negative correlation between patient's age and the maximum diameter of the choledochus ( $r = -0.53$ ,  $P = 0.001$ ) (Figure 5). Thus, younger the patient, the more marked were the biliary narrowing at the narrow portion of the terminal choledochus and upstream biliary dilatation.

## DISCUSSION

The narrow portion of the terminal choledochus is a characteristic feature of congenital biliary dilatation<sup>[18-22]</sup>. The current study demonstrated that it is also a pathognomonic feature of AUPBD. AUPBD is often associated with congenital biliary dilatation<sup>[2-5]</sup>. Thus, we hypothesized that the narrow portion of the terminal choledochus contributes to the development of upstream biliary dilatation frequently seen in AUPBD patients.

Previous studies from Japan reported a prevalence of AUPBD on ERCP ranging from 1.5% to 3.2%<sup>[6,10,30]</sup>. The extremely high prevalence of AUPBD in our series (10%) may be explained by the fact that our hospital is a tertiary referral center and that only surgical patients were included in this study.

While pancreaticobiliary ductal union located above the sphincteric action<sup>[16,17,31]</sup>, long common channel<sup>[10,30]</sup>, and concomitant cystic biliary dilatation<sup>[2-5]</sup> have been advocated as characteristic radiologic findings, the diagnostic significance of the narrow portion of the terminal choledochus has not been emphasized. The current study revealed that the narrow portion is present in most adult patients with AUPBD and is a pathognomonic radiologic feature of AUPBD. The narrow portion of the terminal choledochus is an important finding when diagnosing AUPBD by direct cholangiopancreatography.

Previous studies suggested that the narrow portion of the terminal choledochus may lead to the development of congenital biliary dilatation in pediatric patients<sup>[18,32,33]</sup>. Ito *et al*<sup>[18]</sup> reported that the length rather than the width of the narrow portion of the terminal choledochus is positively correlated with the degree of upstream choledochal dilatation in children with congenital biliary dilatation.

Experimental studies revealed that bile duct obstruction causes cystic biliary dilatation in young animals, while it leads to cylindrical, not cystic, biliary dilatation in adult animals<sup>[32,34,35]</sup>, suggesting that increased intraluminal pressure leads to cystic dilatation of the bile duct, only if the ductal wall is immature. This may explain the fact that cystic biliary dilatation is more common in pediatric patients<sup>[6,36]</sup> and that the degree of biliary dilatation was more marked in younger patients in our series. The current study is the first demonstration that biliary narrowing at the narrow portion correlates with upstream biliary dilatation even in adult patients with AUPBD. In summary, increased intraluminal pressure due to the narrow portion of the terminal choledochus may cause upstream biliary dilatation in both pediatric and adult patients with AUPBD, although the form of upstream biliary dilatation appears to differ between pediatric and adult patients.

Another possible cause of biliary dilatation in patients with AUPBD is the reflux of pancreatic juice into the bile duct. It has been reported that the refluxed pancreatic juice into the bile duct may lead to increased intraluminal pressure and dilatation of the bile duct<sup>[1,37,38]</sup>. However, the strong negative correlation between the minimum diameter of the narrow portion of the terminal choledochus and the maximum diameter of the upstream choledochus in the current study suggests that increased intraluminal pressure due to biliary narrowing, rather than refluxed pancreatic juice, may cause upstream biliary dilatation in patients with AUPBD.

Kusunoki *et al*<sup>[20,39]</sup> reported the presence of "oligoganglionosis" in the choledochal wall just below the cystic dilatation in patients with congenital choledochal cyst, suggesting that autonomic dysfunction at the "oligoganglionic" segment of the bile duct may play a role in the development of upstream biliary dilatation. This "oligoganglionic" segment appears to correspond to the narrow portion of the terminal choledochus, as defined in the current study, and may functionally obstruct biliary passage through the segment. It is unknown, however, whether the "oligoganglionosis" was present in our patients because histologic specimens of the narrow portion of the terminal choledochus were not available in any of our patients.

The limitations of the current study include the fact that it was retrospective, and that 176 patients were excluded due to inadequate opacification of the pancreaticobiliary ductal system. However, we feel that these limitations did not significantly influence the outcome of the study because the correlations between variables were too marked to have resulted from chance. The current results are the clearest demonstration to date of the causal relationship between the narrow portion of the terminal choledochus and upstream biliary dilatation in patients with AUPBD.

In conclusion, the narrow portion of the terminal choledochus is a pathognomonic radiologic feature of AUPBD and may be a cause of biliary dilatation in patients with AUPBD.



## REFERENCES

- 1 **Babbitt DP.** Congenital choledochal cysts: new etiological concept based on anomalous relationships of the common bile duct and pancreatic bulb. *Ann Radiol* 1969; **12**: 231-240
- 2 **Kimura K,** Ohto M, Ono T, Tsuchiya Y, Saisho H, Kawamura K, Yogi Y, Karasawa E, Okuda K. Congenital cystic dilatation of the common bile duct: relationship to anomalous pancreaticobiliary ductal union. *Am J Roentgenol* 1977; **128**: 571-577
- 3 **Todani T,** Watanabe Y, Fujii T, Uemura S. Anomalous arrangement of the pancreatobiliary ductal system in patients with a choledochal cyst. *Am J Surg* 1984; **147**: 672-676
- 4 **Okada A,** Nakamura T, Higaki J, Okumura K, Kamata S, Oguchi Y. Congenital dilatation of the bile duct in 100 instances and its relationship with anomalous junction. *Surg Gynecol Obstet* 1990; **171**: 291-298
- 5 **Lipsett PA,** Pitt HA, Colombani PM, Boitnott JK, Cameron JL. Choledochal cyst disease. A changing pattern of presentation. *Ann Surg* 1994; **220**: 644-652
- 6 **Kimura K,** Ohto M, Saisho H, Unozawa T, Tsuchiya Y, Morita M, Ebara M, Matsutani S, Okuda K. Association of gallbladder carcinoma and anomalous pancreaticobiliary ductal union. *Gastroenterology* 1985; **89**: 1258-1265
- 7 **Misra SP,** Gulati P, Thorat VK, Vij JC, Anand BS. Pancreaticobiliary ductal union in biliary diseases. An endoscopic retrograde cholangiopancreatographic study. *Gastroenterology* 1989; **96**: 907-912
- 8 **Sandoh N,** Shirai Y, Hatakeyama K. Incidence of anomalous union of the pancreaticobiliary ductal system in biliary cancer. *Hepatogastroenterology* 1997; **44**: 1580-1583
- 9 **Misra SP,** Dwivedi M. Pancreaticobiliary ductal union. *Gut* 1990; **31**: 1141-1149
- 10 **Sugiyama M,** Atomi Y, Kuroda A. Pancreatic disorders associated with anomalous pancreaticobiliary junction. *Surgery* 1999; **126**: 492-497
- 11 **Guelrud M,** Morera C, Rodriguez M, Prados JG, Jaén D. Normal and anomalous pancreaticobiliary union in children and adolescents. *Gastrointest Endosc* 1999; **50**: 189-193
- 12 **Guelrud M,** Morera C, Rodriguez M, Jaen D, Pierre R. Sphincter of Oddi dysfunction in children with recurrent pancreatitis and anomalous pancreaticobiliary union: an etiologic concept. *Gastrointest Endosc* 1999; **50**: 194-199
- 13 **Sautereau D,** Sava P, Dupuy JF, Cessot F, Cubertafond P, Claude R, Pillegand B. Cancer des voies biliaires extra-hépatiques et anomalie de la jonction bilio-pancréatique. *Gastroenterol Clin Biol* 1989; **13**: 298-301
- 14 **Yamao K,** Mizutani S, Nakazawa S, Inui K, Kanemaki N, Miyoshi H, Segawa K, Zenda H, Kato T. Prospective study of the detection of anomalous connections of pancreatobiliary ducts during routine medical examinations. *Hepatogastroenterology* 1996; **43**: 1238-1245
- 15 **Matos C,** Nicaise N, Devière J, Cassart M, Metens T, Struyven J, Cremer M. Choledochal cysts: comparison of findings at MR cholangiopancreatography and endoscopic retrograde cholangiopancreatography in eight patients. *Radiology* 1998; **209**: 443-448
- 16 **Nomura T,** Shirai Y, Sandoh N, Nagakura S, Hatakeyama K. Cholangiographic criteria for anomalous union of the pancreatic and biliary ducts. *Gastrointest Endosc* 2002; **55**: 204-208
- 17 **Mori K,** Nagakawa T, Ohta T, Nakano T, Kayahara M, Kanno M, Ueno K, Izumi R, Miyazaki I. Association between gallbladder cancer and anomalous union of the pancreaticobiliary ductal system. *Hepatogastroenterology* 1993; **40**: 56-60
- 18 **Ito T,** Ando H, Nagaya M, Sugito T. Congenital dilatation of the common bile duct in children.-- The etiologic significance of the narrow segment distal to the dilated common bile duct. *Z Kinderchir* 1984; **39**: 40-45
- 19 **Matsumoto Y,** Uchida K, Nakase A, Honjo I. Clinicopathologic classification of congenital cystic dilatation of the common bile duct. *Am J Surg* 1977; **134**: 569-574
- 20 **Kusunoki M,** Saitoh N, Yamamura T, Fujita S, Takahashi T, Utsunomiya J. Choledochal cysts. Oligoganglioneurosis in the narrow portion of the choledochus. *Arch Surg* 1988; **123**: 984-986
- 21 **Suda K,** Matsumoto Y, Miyano T. Narrow duct segment distal to choledochal cyst. *Am J Gastroenterol* 1991; **86**: 1259-1263
- 22 **Matsumoto Y,** Fujii H, Itakura J, Mogaki MA, Matsuda M, Morozumi A, Fujino M, Suda K. Pancreaticobiliary maljunction: etiologic concepts on radiologic aspects. *Gastrointest Endosc* 2001; **53**: 614-619
- 23 **Todani T,** Watanabe Y, Narusue M, Tabuchi K, Okajima K. Congenital bile duct cysts. Classification, operative procedures, and review of thirty-seven cases including cancer arising from choledochal cyst. *Am J Surg* 1977; **134**: 263-269
- 24 **Rattner DW,** Schapiro RH, Warshaw AL. Abnormalities of the pancreatic and biliary ducts in adult patients with choledochal cysts. *Arch Surg* 1983; **118**: 1068-1073
- 25 **Wiedmeyer DA,** Stewart ET, Dodds WJ, Geenen JE, Vennes JA, Taylor AJ. Choledochal cyst : findings on cholangiopancreatography with emphasis on ectasia of the common channel. *Am J Roentgenol* 1989; **153**: 969-972
- 26 **Kune GA.** Surgical anatomy of common bile duct. *Arch Surg* 1964; **89**: 995-1004
- 27 **Kune GA.** The influence of structure and function in the surgery of the biliary tract. *Ann R Coll Surg Engl* 1970; **47**: 78-91
- 28 **Kune GA,** Sali A. The practice of biliary surgery. 2nd ed. Oxford: Blackwell Sci Pub 1980: 1-31
- 29 **Hand BH.** An anatomical study of the choledochoduodenal area. *Br J Surg* 1963; **50**: 486-494
- 30 **Kato O,** Hattori K, Suzuki T, Tachino F, Yuasa T. Clinical significance of anomalous pancreaticobiliary union. *Gastrointest Endosc* 1983; **29**: 94-98
- 31 **Nagata E,** Sakai K, Kinoshita H, Kobayashi Y. The relation between carcinoma of the gallbladder and an anomalous connection between the choledochus and the pancreatic duct. *Ann Surg* 1985; **202**: 182-190
- 32 **Miyano T,** Suruga K, Suda K. Abnormal choledochopancreatic ductal junction related to the etiology of infantile obstructive jaundice diseases. *J Pediatr Surg* 1979; **14**: 16-26
- 33 **Shimotake T,** Iwai N, Yanagihara J, Inoue K, Fushiki S. Innervation patterns in congenital biliary dilatation. *Eur J Pediatr Surg* 1995; **5**: 265-270
- 34 **Kato T,** Asakura Y, Kasai M. An attempt to produce choledochal cyst in puppies. *J Pediatr Surg* 1974; **9**: 509-513
- 35 **Spitz L.** Experimental production of cystic dilatation of the common bile duct in neonatal lambs. *J Pediatr Surg* 1977; **12**: 39-42
- 36 **Chaudhary A,** Dhar P, Sachdev A, Kumar N, Vij JC, Sarin SK, Broor SL, Sharma SS. Choledochal cysts - differences in children and adults. *Br J Surg* 1996; **83**: 186-188
- 37 **Ohkawa H,** Sawaguchi S, Yamazaki Y, Ishikawa A, Kikuchi M. Experimental analysis of the ill effect of anomalous pancreaticobiliary ductal union. *J Pediatr Surg* 1982; **17**: 7-13
- 38 **Oguchi Y,** Okada A, Nakamura T, Okumura K, Miyata M, Nakao K, Kawashima Y. Histopathologic studies of congenital dilatation of the bile duct as related to an anomalous junction of the pancreaticobiliary ductal system: clinical and experimental studies. *Surgery* 1988; **103**: 168-173
- 39 **Kusunoki M,** Yamamura T, Takahashi T, Kanto M, Ishikawa Y, Utsunomiya J. Choledochal cyst. Its possible autonomic involvement in the bile duct. *Arch Surg* 1987; **122**: 997-1000