

• CLINICAL RESEARCH •

Microscopic colitis: A retrospective study of clinical presentation in 53 patients

Zsolt Barta, Gabriella Mekkel, István Csípő, László Tóth, Szabolcs Szakáll, Gábor G. Szabó, Gyula Bakó, Gyula Szegedi, Margit Zeher

Zsolt Barta, Gabriella Mekkel, István Csípő, Gábor G. Szabó, Gyula Bakó, Gyula Szegedi, Margit Zeher, Third Department of Medicine, Faculty of Medicine, Medical and Health Science Centre, University of Debrecen, Debrecen, Hungary
László Tóth, Szabolcs Szakáll, Department of Pathology, Faculty of Medicine, Medical and Health Science Centre, University of Debrecen, Debrecen, Hungary

Correspondence to: Zsolt Barta, M.D., Third Department of Medicine, Faculty of Medicine, Medical and Health Science Centre, University of Debrecen, H-4012 Debrecen, Móricz Zs. krt 22, Hungary. mailtobarta@iibel.dote.hu

Telephone: +36-52-414-969 Fax: +36-52-414-969

Received: 2004-05-27 Accepted: 2004-07-22

Abstract

AIM: To evaluate the relationship between symptoms and microscopic colitis (MC) subtypes: to test whether collagenous colitis (CC) and/or lymphocytic colitis (LC) might be related to both constipation and diarrhea.

METHODS: A cohort of patients with independently confirmed typical histopathological changes was investigated. Fifty-three patients with histologically proved MC (46 with CC, 7 with LC) were included. The existence of diarrhea or constipation and the co-existence of autoimmune diseases were also investigated and all data were retrospectively analyzed.

RESULTS: Twenty-three (43.39%) of MC patients had chronic constipation (20 in CC, 3 in LC patients). Twenty-four (45.28%) of MC patients had autoimmune disease and the diagnosis of autoimmune disease was always prior to MC. Sjögren's syndrome was associated only with the constipation subgroup.

CONCLUSION: The Janus face of MC resembles the subgroups of irritable bowel syndrome. The co-existence of autoimmune diseases and MC is confirmed in both the constipation and diarrhea subgroups.

© 2005 The WJG Press and Elsevier Inc. All rights reserved.

Key words: Microscopic colitis; Constipation; Autoimmune

Barta Z, Mekkel G, Csípő I, Tóth L, Szakáll S, Szabó GG, Bakó G, Szegedi G, Zeher M. Microscopic colitis: A retrospective study of clinical presentation in 53 patients. *World J Gastroenterol* 2005; 11(9): 1351-1355
<http://www.wjgnet.com/1007-9327/11/1351.asp>

INTRODUCTION

The term "microscopic colitis" was first used in 1980^[1]. Notoriously, microscopic colitis (MC) is characterized by chronic watery diarrhea, a normal or near-normal gross appearance of the colonic mucosa, and a specific histological picture. Collagenous colitis (CC) has similar clinical and histological features. Lindstrom first described it in 1976 as an unusual cause of persistent watery diarrhea and he noted a large sub-epithelial band of collagen deposited in the rectum and colon^[2]. Current nomenclature uses MC as an umbrella term with two major subsets: CC (with chronic mucosal inflammation and a thickened sub-epithelial collagen band) and lymphocytic colitis (LC) (with inflammation but no collagen thickening). Thus, LC and CC are relatively "new" diseases with a normal colonoscopic appearance but with characteristic histopathological features. They are well-distinguished by the presence of the thickened sub-epithelial collagen table and can cause watery diarrhea. It is likely that they are a spectrum of one disease, but this is yet to be proven. Some authors have suggested that LC is an early stage of CC^[3-5]. By colonoscopy and barium enema the colon appears almost normal. Diagnosis is established by colonic biopsies. CC can be diagnosed from rectal or sigmoid colon biopsy specimens in more than 90% of cases. Arthralgias and various autoimmune conditions occur commonly in patients with MC and an association has been suggested^[6-8]. Whether CC is a distinct and separate autoimmune disease or a simple co-existence has not been clearly established.

Data on the pathophysiology of MC typically come from small studies that often give conflicting results. Several hypotheses have been raised, ranging from immune dysregulation and/or autoimmunity to drug effect and infection. It may be that the clinicopathological term of MC encompasses several different diseases with similar histological endpoints. MC (both CC and LC) can cause not only diarrhea but also constipation. Most often, constipation is short-lived and of little consequence in the ordinary population. However, chronic constipation does occur^[9]. It is not obvious whether the patients suffering from MC have diarrhea or constipation, all authors premise the axiom of diarrhea^[10]. On the other hand, diseases or symptoms (i.e., food protein-induced enterocolitis, diarrhea or constipation) involving the gastrointestinal system have been attributed to hypersensitive reactions to food. Many of these symptoms reflect the concept of "delayed" reactions. This notion presumes that certain clinical symptoms reflect allergies to food which develop over a period of hours or days (or longer) and are caused by immunologic mechanisms

other than immediate-type hypersensitivity^[11]. For example, cow-milk protein allergy should be considered as a cause of chronic refractory constipation in children, although the underlying mechanisms still require further investigation. Dogs and cats have a similar disorder as MC that resolves with a hypoallergenic diet^[12].

Our aim was to determine the natural clinical history of MC and to obtain more information on this disease on a cohort of patients from a register set-up at our clinic with independently confirmed typical histopathological changes. This study was designed to evaluate the relationship between symptoms and MC subtypes, to test whether CC and/or LC might be related to both constipation and diarrhea. We also investigated the co-existence of autoimmune diseases. All data were retrospectively analyzed.

MATERIALS AND METHODS

The diagnostic criteria were made on the histopathological features^[13]. The histological features recorded were crypt architecture distortion, the severity and distribution of inflammation, surface degeneration, the presence and thickness of a sub-epithelial collagen band (immunohistochemical demonstration of tenascin expression), intraepithelial lymphocytes, any excess of eosinophils or neutrophils and the presence of apoptosis. (Figure 1).

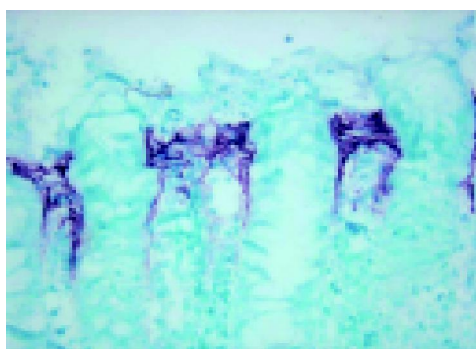

Figure 1 Colonic mucosa in CC (tenascin immunostaining, $\times 400$).

CC required a subepithelial collagen band of at least 10 μm and an increase in inflammatory infiltrate in the lamina propria (with a preponderance of plasma cells and lymphocytes). Patients showing a collagen band without any inflammatory infiltrate in the lamina propria were excluded. LC required an increase in the number of intraepithelial lymphocytes and also chronic inflammation in the lamina propria. This was assessed in a well-orientated part of the section. The lamina propria was considered to have an increase of chronic inflammatory cells if the normal gradient of decrease in inflammatory cells down the lamina propria was lost and if basal plasma cells were seen at the level of the upper border of the muscularis mucosae at more than one site^[14].

The Department of Pathology of the University of Debrecen certified the diagnosis of MC (46 with CC, 7 with LC) in the analyzed colonic biopsy specimens between

1994 and 2004. All these paraffin blocks were collected at the Department of Pathology. Two independent pathologists verified the subsequent sections and completed the check with additional investigations (intraepithelial lymphocytes, tenascin labeling of the collagen layer, mast cells and other lamina propria cell components). To avoid bias, all microscopic slides were coded prior to analysis by one observer and read blindly. With this, the histologically verified patients were re-examined at the Third Department of Medicine of the University of Debrecen (detailed history taking and symptoms). Adult patients of both sexes were included. None of the patients had an infectious disease. The medical records for these patients were previously reviewed by investigators and abstracted for patient characteristics. The diagnoses of gluten sensitive enteropathy (GSE), Crohn's disease, allergic asthma, rhinitis and urticaria were made using the formally accepted criteria. The diagnoses of systemic lupus erythematosus (SLE), rheumatoid arthritis (RA), Sjögren's syndrome (SS), undifferentiated connective tissue disease (UCTD) and Hashimoto thyroiditis were based on American Rheumatism Association criteria. Serum values of total IgE and antibodies to common food antigens (milk protein, egg protein, soy protein, tomato and hazelnut) were also determined and food allergens were detected by "Allergoset-IgE Food" kit (INTEX Diagnostika, Basel).

We used the definition of diarrhea in case of more than 3 bowel movements per day (greater than 250 g of liquid stool daily) for more than 1 mo. Most of the patients define their constipation by one or more symptoms: hard stools, infrequent stools (typically fewer than three per week), the need for excessive straining, a sense of incomplete bowel evacuation, and excessive time spent on the toilet or in unsuccessful defecation. An epidemiologic study of constipation in USA identified it as an inability to evacuate stool completely and spontaneously three or more times per week^[15]. A consensus definition of constipation (the Rome II criteria), used in current work, is shown in Table 1^[16].

Table 1 Rome II criteria for constipation in adults

Two or more of the following for at least 12 wk (not necessarily consecutive) in the preceding 12 mo:

- Straining >25% of bowel movements
- Lumpy or hard stools >25% of bowel movements
- Sensation of incomplete evacuation >25% of bowel movements
- Sensation of anorectic blockage >25% of bowel movements
- Manual maneuvers to facilitate >25% of bowel movements (e.g., digital evacuation or support of the pelvic floor)
- <3 bowel movements per week
- No loose stools, and insufficient criteria for irritable bowel syndrome met

Statistical analysis

Statistical analysis was performed using SPSS v11.0 and Microsoft Excel soft packs. Differences between groups were tested using the Fisher's exact test, independent samples *t*-test and Mann-Whitney test.

RESULTS

Fifty-three patients had a diagnosis of collagenous or LC

on the pathology database. All patients' biopsies were taken by colonoscopy because of abdominal pain and/or stool problems (diarrhea or constipation) or weight loss, and endoscopic evaluation demonstrated normal findings (the macroscopic picture was normal). Constipation was found in 23 patients (43.39%, 20 CC and 3 LC patients) and diarrhea in 30 patients (56.61%, 26 CC and 4 LC patients).

The average age of the CC and LC patients was 51.56 years (range 26-79) and 43.42 years (range 19-59). The average age of MC patients with constipation and diarrhea was 54.95 and 47.32 years, respectively. This association was significant ($P = 0.032$). The demographic data and symptoms for each type of colitis are given in Table 2.

Table 2 Demographic data and symptoms for each type of colitis

| | CC (n=46) Average age: 51.56, n (%) | LC (n=7) Average age: 43.42, n (%) |
|---------------------------------|--|---------------------------------------|
| Gender M/F | 21/25 | 2/5 |
| Diarrhea | 26 (56.52) | 4 (57.14) |
| Constipation | 20 (43.48) | 3 (42.86) |
| Abdominal pain | 18 (39.3) | 4 (57.14) |
| Weight loss | 16 (34.78) | 2 (28.57) |
| Cholecystectomy | 5 (10.86) | 0 |
| Appendectomy | 5 (10.86) | 2 (28.57) |
| Allergic disease ¹ | 22 (47.82) | 2 (28.57) |
| Autoimmune disease ² | 22 (47.82) | 2 (28.57) |

¹Allergic disease: asthma, allergic rhinitis, allergic urticaria and/or increased IgE type antibody titers against food allergens ²Autoimmune disease: SLE, RA, SS, UCTD, Hashimoto thyroiditis, Crohn's disease and celiac disease.

The most common symptoms were abdominal pain and weight loss, but there was no difference in their incidence. In CC patients, 5 had a history with appendectomy and 5 with cholecystectomy, and 2 LC patients with appendectomy. There were 24 patients with clearly defined autoimmune conditions (GSE and Crohn's disease also included, as shown in Figure 2).

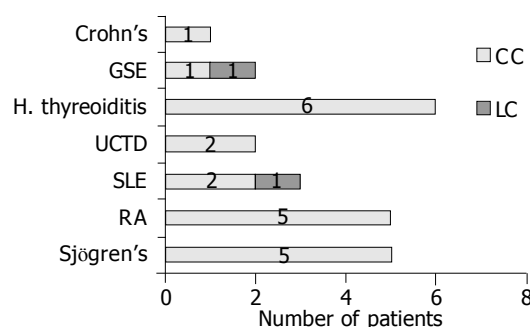


Figure 2 Distribution of autoimmune diseases in MC. Crohn's: Crohn's disease GSE: celiac disease H. thyroiditis: Hashimoto thyroiditis UCTD: undifferentiated connective tissue disease SLE: systemic lupus erythematosus RA: rheumatoid arthritis Sjögren's: Sjögren's syndrome.

Sjögren's disease was associated only with CC and constipation. SLE (2 patients with CC and 1 with LC) and

UCTD (2 patients with MC/CC) were associated only with diarrhea (Figure 3).

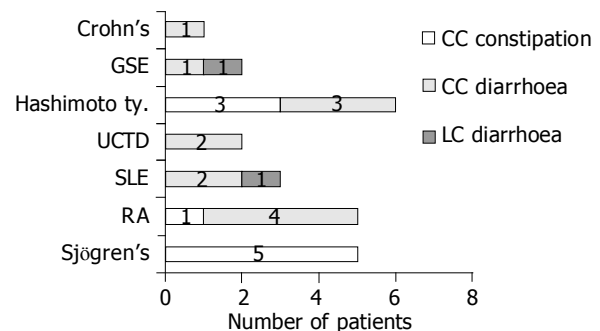


Figure 3 Relation between autoimmune diseases and the type of MC (constipation/diarrhea) Crohn's: Crohn's disease GSE: celiac disease H. thyroiditis: Hashimoto thyroiditis UCTD: undifferentiated connective tissue disease SLE: systemic lupus erythematosus RA: rheumatoid arthritis Sjögren's: Sjögren's syndrome.

The diagnosis of autoimmune disease preceded the diagnosis of MC in all patients and no significant association was found between gender and the time of onset of MC. The average time of onset was 4.12 years in male patients and 6.56 years in females. Common allergic diseases (asthma, allergic rhinitis, and allergic urticaria) and/or increased IgE type antibody titers against food allergens were found in 24 of 53 patients with MC (45.28%), and in 22 (47.82%) CC patients and in 2 (28.57%) LC patients. IgE type antibodies against hazelnut, tomato, soy protein, milk protein, egg protein, and gliadin were found.

Clinical course of the patients was not the same. Most of the patients with MC had chronic watery diarrhea but the other group had constipation. Most of them responded to budesonide (Budenofalk, Dr Falk Pharma, 1×9 mg/d) and entered a long lasting remission period.

DISCUSSION

Symptoms of MC can cease and patients may have not any complaints, but intermittent or continuous diarrhea can remain^[17-20]. CC is characterized by diarrhea, lymphocytic inflammation, and a thickened sub-epithelial collagen layer in the colorectal mucosa^[2]. Frequent watery diarrheas have the clinical picture of CC and LC and intermittent or continuous diarrhea can remain^[21]. On the other hand, numerous cases never suffer from episodes of watery diarrhea but chronic constipation. We had investigated 53 patients with histologically identified MC. We propose that MC is a Janus-faced disease as 23 of them had chronic constipation and 30 had the well-known diarrhea.

There are many reports with several hypotheses on potential pathophysiological mechanisms in MC. Current understanding of MC defines it as an inflammatory disorder of the bowels. Acute inflammation is a beneficial non-specific response of tissues to injury that generally leads to repair and restoration of normal structure and function. MC seems to be a chronic inflammatory process of the bowels. The factors that initiate and perpetuate remodeling are incompletely

understood. It is not clear whether gut remodeling is a normal response to an injury or whether the remodeling/repair response is itself an abnormal response. In addition, while remodeling is generally believed to be disadvantageous, in some ways it may serve as a protective function. The balance between these effects *in vivo* is speculative. The gut wall of patients with MC can be characterized by a number of structural changes and it is not known which one (s) are the most useful and relevant markers.

Allergy (food allergy) can cause both diarrhea and constipation. Diseases or symptoms (i.e., food protein-induced enterocolitis, diarrhea or constipation) involving the gastrointestinal system have been attributed to hypersensitive reactions to food^[22-25]. Albeit the etiology of CC is still unknown but the sub-epithelial band-like collagenous deposit may be produced by fibroblasts after an immune stimulation. In case of CC, the mesenchymal cells' myofibroblastic transformation occurs within the accumulated sub-epithelial extra cellular matrix^[26,27]. According to the recent data the bulk of accumulated sub-epithelial extra cellular matrix is composed of type VI collagen and tenascin^[28,29]. The increased number of mast cells besides the myofibroblasts is remarkable in the "fibrotic" layer, which is characteristic in CC. The presence of a different distribution of mast cells and macrophages in CC and inflammatory bowel disease suggests that mucosal mast cells play a role in the development of Th2 response CC rather than Th1^[30,31].

Our data support the hypothesis that patients with MC may have laboratory and/or clinical evidence of allergic diseases and/or food allergy and these mean a possible connection between MC and food allergy. Remodeling of the gut wall is thought to be a result of chronic inflammation. Since steroids reduce or reverse inflammation, they may also reduce or reverse remodeling. However, there is also *in vitro* evidence for a direct effect of steroids on the cells, growth factors, and cytokines which are thought to be central in the remodeling process. Corticosteroids are the most effective drugs available for the treatment of allergic diseases because they have potent anti-inflammatory effects. Topical corticosteroids work by reducing the effects of histamine and other inflammatory mediators involved in the allergic response and repeated dosing inhibits both the early and late phase allergic reactions. All the patients receiving budesonide had clinical response.

The etiology of MC is still unknown and more research is needed. Up to now, it is not clear whether CC is a distinct entity or only an epiphenomenon of another disease which leads to thickening of the collagen layer^[32, 33]. Whether MC (both CC and LC) is an autoimmune disease has not been conclusively established. Autoimmune diseases occur in patients with MC and an association with various autoimmune diseases has been suggested, but no serological findings support such a theory^[34-36].

Because of the clinical heterogeneity in our study population, the descriptive term MC syndrome may be a more prudent diagnosis than MC. We think that the frequency of MC will increase with better recognition.

REFERENCES

- Read NW, Krejs GJ, Read MG, Santa Ana CA, Morawski SG, Fordtran JS. Chronic diarrhea of unknown origin. *Gastroenterology* 1980; **78**: 264-271
- Lindstrom CG. 'Collagenous colitis' with watery diarrhoea - a new entity? *Pathol Eur* 1976; **11**: 87-89
- Bowling TE, Price AB, al Adnani M, Fairclough PD, Menzies-Gow N, Silk DB. Interchange between collagenous and lymphocytic colitis in severe disease with autoimmune associations requiring colectomy: a case report. *Gut* 1996; **38**: 788-791
- Jawhari A, Talbot IC. Microscopic, lymphocytic and collagenous colitis. *Histopathology* 1996; **29**: 101-110
- Mosnier JF, Larvol L, Barge J, Dubois S, De La Bigne G, Henin D, Cerf M. Lymphocytic and collagenous colitis: an immunohistochemical study. *Am J Gastroenterol* 1996; **91**: 709-713
- Bohr J, Tysk C, Eriksson S, Abrahamsson H, Jarnerot G. Collagenous colitis: a retrospective study of clinical presentation and treatment in 163 patients. *Gut* 1996; **39**: 846-851
- Bohr J, Tysk C, Yang P, Danielsson D, Jarnerot G. Autoantibodies and immunoglobulins in collagenous colitis. *Gut* 1996; **39**: 73-76
- Castanet J, Lacour JP, Ortonne JP. Arthritis, collagenous colitis, and discoid lupus. *Ann Intern Med* 1994; **120**: 89-90
- Leigh C, Elahmady A, Mitros FA, Metcalf A, al Jurf A. Collagenous colitis associated with chronic constipation. *Am J Surg Pathol* 1993; **17**: 81-84
- Burgel N, Bojarski C, Mankertz J, Zeitz M, Fromm M, Schulzke JD. Mechanisms of diarrhea in collagenous colitis. *Gastroenterology* 2002; **123**: 433-443
- Heine RG. Pathophysiology, diagnosis and treatment of food protein-induced gastrointestinal diseases. *Curr Opin Allergy Clin Immunol* 2004; **4**: 221-229
- Nelson RW, Stookey LJ, Kazacos E. Nutritional management of idiopathic chronic colitis in the dog. *J Vet Intern Med* 1988; **2**: 133-137
- Goff JS, Barnett JL, Pelke T, Appelman HD. Collagenous colitis: histopathology and clinical course. *Am J Gastroenterol* 1997; **92**: 57-60
- Fraser AG, Warren BF, Chandrapala R, Jewell DP. Microscopic colitis: a clinical and pathological review. *Scand J Gastroenterol* 2002; **37**: 1241-1245
- Stewart WF, Liberman JN, Sandler RS, Woods MS, Stemhagen A, Chee E, Lipton RB, Farup CE. Epidemiology of constipation (EPOC) study in the United States: relation of clinical subtypes to sociodemographic features. *Am J Gastroenterol* 1999; **94**: 3530-3540
- Thompson WG, Longstreth GF, Drossman DA, Heaton KW, Irvine EJ, Muller-Lissner SA. Functional bowel disorders and functional abdominal pain. *Gut* 1999; **45** Suppl 2: II43-II47
- Bonner GF, Petras RE, Cheong DM, Grewal ID, Breno S, Ruderman WB. Short- and long-term follow-up of treatment for lymphocytic and collagenous colitis. *Inflamm Bowel Dis* 2000; **6**: 85-91
- Ung KA, Gillberg R, Kilander A, Abrahamsson H. Role of bile acids and bile acid binding agents in patients with collagenous colitis. *Gut* 2000; **46**: 170-175
- Ung KA, Kilander A, Nilsson O, Abrahamsson H. Long-term course in collagenous colitis and the impact of bile acid malabsorption and bile acid sequestrants on histopathology and clinical features. *Scand J Gastroenterol* 2001; **36**: 601-609
- Zins BJ, Sandborn WJ, Tremaine WJ. Collagenous and lymphocytic colitis: subject review and therapeutic alternatives. *Am J Gastroenterol* 1995; **90**: 1394-1400
- Cruz-Correa M, Giardiello FM. Lymphocytic and Collagenous Colitis. *Curr Treat Options Gastroenterol* 2000; **3**: 243-248
- Wang N, Dumot JA, Achkar E, Easley KA, Petras RE, Goldblum JR. Colonic epithelial lymphocytosis without a thickened subepithelial collagen table: a clinicopathologic study of 40 cases supporting a heterogeneous entity. *Am J Surg Pathol* 1999; **23**: 1068-1074
- Barbato M, Viola F, Russo LL, Lucarelli S, Frediani T, Cardi E. Microscopic and collagenous colitis in treated celiac dis-

- ease due to food allergy? *Gastroenterology* 1999; **116**: 778
- 24 **Kajino Y**, Kushima R, Koyama S, Fujiyama Y, Okabe H. Collagenous gastritis in a young Japanese woman. *Pathol Int* 2003; **53**: 174-178
- 25 **Barta Z**, Toth L, Szabo GG, Szegedi G. Collagenous colitis: constipation or diarrhoea? *Gut* 2003; **52**: 1230
- 26 **Balazs M**, Egerszegi P, Vadasz G, Kovacs A. Collagenous colitis: an electron microscopic study including comparison with the chronic fibrotic stage of ulcerative colitis. *Histopathology* 1988; **13**: 319-328
- 27 **Hwang WS**, Kelly JK, Shaffer EA, Hershfield NB. Collagenous colitis: a disease of pericryptal fibroblast sheath? *J Pathol* 1986; **149**: 33-40
- 28 **Aigner T**, Neureiter D, Muller S, Kuspert G, Belke J, Kirchner T. Extracellular matrix composition and gene expression in collagenous colitis. *Gastroenterology* 1997; **113**: 136-143
- 29 **Anagnostopoulos I**, Schuppan D, Riecken EO, Gross UM, Stein H. Tenascin labelling in colorectal biopsies: a useful marker in the diagnosis of collagenous colitis. *Histopathology* 1999; **34**: 425-431
- 30 **Nishida Y**, Murase K, Isomoto H, Furusu H, Mizuta Y, Riddell RH, Kohno S. Different distribution of mast cells and macrophages in colonic mucosa of patients with collagenous colitis and inflammatory bowel disease. *Hepatogastroenterology* 2002; **49**: 678-682
- 31 **Flejou JF**, Grimaud JA, Molas G, Baviera E, Potet F. Collagenous colitis. Ultrastructural study and collagen immunotyping of four cases. *Arch Pathol Lab Med* 1984; **108**: 977-982
- 32 **Jarnerot G**, Tysk C, Bohr J, Eriksson S. Collagenous colitis and fecal stream diversion. *Gastroenterology* 1995; **109**: 449-455
- 33 **McCashland TM**, Donovan JP, Strobach RS, Linder J, Quigley EM. Collagenous enterocolitis: a manifestation of gluten-sensitive enteropathy. *J Clin Gastroenterol* 1992; **15**: 45-51
- 34 **Baert F**, Wouters K, D'Haens G, Hoang P, Naegels S, D'Heygere F, Holvoet J, Louis E, Devos M, Geboes K. Lymphocytic colitis: a distinct clinical entity? A clinicopathological confrontation of lymphocytic and collagenous colitis. *Gut* 1999; **45**: 375-381
- 35 **Heckerling P**, Urtubey A, Te J. Collagenous colitis and systemic lupus erythematosus. *Ann Intern Med* 1995; **122**: 71-72
- 36 **Wengrower D**, Pollak A, Okon E, Stalnikowicz R. Collagenous colitis and rheumatoid arthritis with response to sulfasalazine. A case report and review of the literature. *J Clin Gastroenterol* 1987; **9**: 456-460

Assistant Editor Guo SY Edited by Wang XL and Gabbe M