



CASE REPORT

Post-traumatic hepatic artery pseudo-aneurysm combined with subphrenic liver abscess treated with embolization

Long Sun, Yong-Song Guan, Hua Wu, Wei-Min Pan, Xiao Li, Qing He, Yuan Liu

Long Sun, Hua Wu, Wei-Min Pan, Department of Nuclear Medicine and PET Center, the First Hospital of Xiamen, Fujian Medical University, Xiamen 316003, Fujian Province, China.

Yong-Song Guan, Xiao Li, Qing He, Yuan Liu, Department of Interventional Medicine, West China Hospital of Sichuan University, Chengdu 610041, Sichuan Province, China.

Correspondence to: Long Sun, Department of Nuclear Medicine and PET Center, the First Hospital of Xiamen, Fujian Medical University, Xiamen 316003, Fujian Province, China. long.d.sun@163.com

Telephone: +86-592-2139527 Fax: +86-592-2137189

Received: 2005-11-25 Accepted: 2006-01-14

Abstract

A 23-year-old man with post-traumatic hepatic artery pseudo-aneurysm and subphrenic liver abscess was admitted. He underwent coil embolization of hepatic artery pseudo-aneurysm. The pseudo-aneurysm was successfully obstructed and subphrenic liver abscess was controlled. Super-selective trans-catheter coil embolization may represent an effective treatment for hepatic artery pseudo-aneurysm combined with subphrenic liver abscess in the absence of other therapeutic alternatives.

© 2006 The WJG Press. All rights reserved.

Key words: Pseudo-aneurysm; Hepatic trauma; Liver abscess

Sun L, Guan YS, Wu H, Pan WM, Li X, He Q, Liu Y. Post-traumatic hepatic artery pseudo-aneurysm combined with subphrenic liver abscess treated with embolization. *World J Gastroenterol* 2006; 12(17): 2798-2799

<http://www.wjgnet.com/1007-9327/12/2798.asp>

INTRODUCTION

Hepatic artery pseudo-aneurysm is a rare complication of blunt abdominal trauma. Diagnosis is frequently delayed and made by splanchnic angiography. Most of the indications for surgical treatment may disappear after selective catheterization and embolization. We report a case of a 23-year-old man with a history of hepatic trauma. Subphrenic abscess formation after laparotomy and right hepatic artery pseudoaneurysm were diagnosed

by enhanced computer tomography (CT). The lesion was confirmed by arteriography and managed with trans-catheter embolization.

CASE REPORT

We report a case of a 23-year-old man with a severe blunt abdominal trauma caused by a car accident. An immediate laparotomy was performed due to a severe collapse upon admission and a liver fracture was observed. He gradually recovered and a subphrenic abscess occurred on day 10 after operation. Abdominal CT scanning revealed a complex subphrenic abscess and a pseudo-aneurysm of the right hepatic artery (Figure 1). Selective angiography confirmed the diagnosis of right artery pseudo-aneurysm (Figure 2) and the aneurysm was occluded by trans-catheter embolization. This was accomplished uneventfully with placement of two 5mm coils into the aneurysm and right hepatic artery was unblocked (Figure 3). The 14-F drainage catheters containing semi-solid necrotic material were placed into these collections. Eventually, recovery was complete. The classical embolization could avoid surgical treatment with a high morbidity.

DISCUSSION

The liver is the largest solid abdominal organ with a relatively fixed position, which makes it prone to injury. The most common cause of liver injury is blunt abdominal trauma, secondary to motor vehicle accidents in most instances. In the past, most of these injuries were treated surgically. However, surgical literature indicates that as high as 86% of liver injuries have stopped bleeding at the time when surgical exploration is performed, and 67% of operations performed for blunt abdominal trauma are non-therapeutic^[1-2].

As a result of this high mortality rate, emergency surgery is frequently indicated in patients with hepatic injury in the past. However, with better monitoring facilities and imaging techniques, most patients with blunt abdominal trauma are now treated conservatively. Pseudoaneurysms are better depicted by spiral or multi-section CT because of the ability to image during peak contrast enhancement^[3].

Complications of liver trauma occur in approximately 20% of patients, including delayed rupture (very rare), hemobilia, arterio-venous fistula, pseudo-aneurysm, biloma and abscess formation^[4]. There are many potential causes of liver abscesses, such as appendicitis, diverticulitis, or

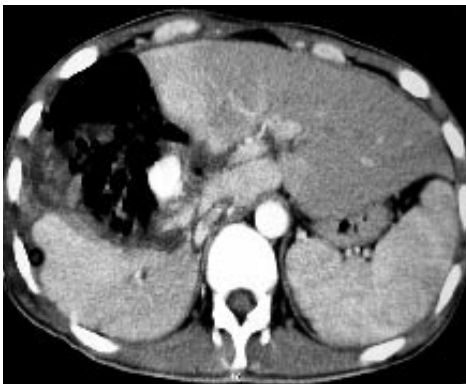

Figure 1 Axial contrast-enhanced CT scan revealing a vascular mass lesion in the right lobe of liver.

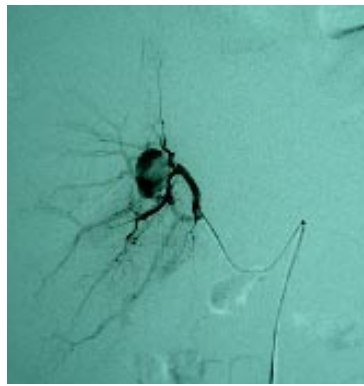


Figure 2 Selective celiac arteriogram showing a hepatic artery pseudo-aneurysm in the right hepatic artery.

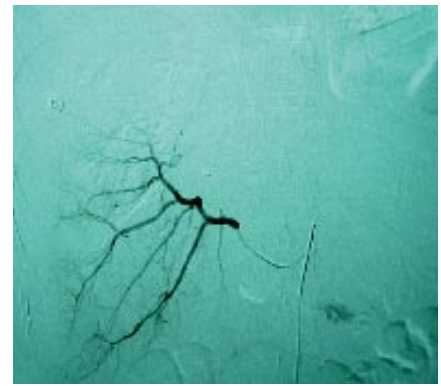


Figure 3 Post embolization selective arteriogram showing disappearance of the right hepatic artery pseudoaneurysm in the right lobe of liver.

a perforated bowel, infection in blood, infection of the biliary (liver secretion) tract, or trauma with bruised liver infection^[5].

The most common bacteria that cause liver abscesses are *escherichia coli*, *klebsiella*, *enterococcus*, and *bacteroides*. The death rate is 10%-30% in treated patients, and higher in those with multiple abscesses. Life-threatening sepsis can develop. The treatment usually consists of surgical or percutaneous (through the skin, with a needle) drainage of the abscess. This is accompanied with a prolonged antibiotic therapy. Sometimes antibiotics alone can cure the infection. Occasionally, patients with blunt abdominal trauma do well initially, but subsequently develop a liver abscess, presumably due to unrecognized liver damage. These patients have signs and symptoms of deep-seated infection^[6-7].

A dynamic angiographic study may demonstrate the site of active bleeding and the sac of pseudoaneurysms. Trans-catheter embolization may be the only treatment required. Superselective catheterization should be performed as far as possible. Both afferent and efferent vessels of pseudo-aneurysms or aneurysms should be occluded to prevent their retrograde filling^[8]. Initially, the surgeon may control the hemorrhage by temporary perihepatic packing. Recurrent liver parenchymal bleeding can be treated successfully with trans-catheter embolization, and placement of an intravenous stent can control bleeding from a major hepatic vein^[9].

Embolization can be performed for the control of persistent arterial hemorrhage which may occur due to stab wounds of the liver, and for the occlusion of pseudo-aneurysm. Trans-catheter arterial embolization may reduce transfusion requirements and allow healing of hepatic injuries without surgery. Because hepatic arteries are not the end arteries, occlusive devices should be deployed distal to the lesion to prevent collateral backdoor filling.

The entire hepatic artery may be occluded if required, as long as the portal vein is patent. If the portal vein is occluded, only selective embolization can be performed to prevent liver infarction due to the presence of intrahepatic collaterals^[10].

REFERENCES

- 1 **Keller MS.** Blunt injury to solid abdominal organs. *Semin Pediatr Surg* 2004; **13**: 106-111
- 2 **Ott R, Schon MR, Seidel S, Schuster E, Josten C, Hauss J.** [Surgical management, prognostic factors, and outcome in hepatic trauma]. *Unfallchirurg* 2005; **108**: 127-134
- 3 **Romano L, Giovine S, Guidi G, Tortora G, Cinque T, Romano S.** Hepatic trauma: CT findings and considerations based on our experience in emergency diagnostic imaging. *Eur J Radiol* 2004; **50**: 59-66
- 4 **Gopanpallikar A, Rathi P, Sawant P, Gupta R, Dhadphale S, Deshmukh HL.** Hepatic artery pseudoaneurysm associated with amebic liver abscess presenting as upper GI hemorrhage. *Am J Gastroenterol* 1997; **92**: 1391-1393
- 5 **Zibari GB, Maguire S, Aultman DF, McMillan RW, McDonald JC.** Pyogenic liver abscess. *Surg Infect (Larchmt)* 2000; **1**: 15-21
- 6 **Hsieh CH.** Comparison of hepatic abscess after operative and nonoperative management of isolated blunt liver trauma. *Int Surg* 2002; **87**: 178-184
- 7 **Szentkereszty Z, Peter M, Erdelyi G, Sapy P.** [Results of surgical treatment of liver abscess, with special emphasis of percutaneous puncture and drainage]. *Magy Seb* 2000; **53**: 259-262
- 8 **Forlee MV, Krige JE, Welman CJ, Beningfield SJ.** Haemobilia after penetrating and blunt liver injury: treatment with selective hepatic artery embolisation. *Injury* 2004; **35**: 23-28
- 9 **Baha B, Meyer PG, Brunelle F, Orliaguet G, Michel JL, Carli P.** A case of hepatic pseudoaneurysm treated with percutaneous embolization in a child with multiple trauma. *Ann Fr Anesth Reanim* 2001; **20**: 786-790
- 10 **Mahi M, Chellaoui M, Chat L, Achabaan F, Alami D, Najid A, el Hassani M, Benamour-Ammar H.** Post-traumatic hepatic artery pseudoaneurysm. A case report. *Arch Pediatr* 2001; **8**: 720-723

S- Editor Wang J L- Editor Wang XL E- Editor Liu WF