



CASE REPORT

Portal venous gas and thrombosis in a Chinese patient with fulminant Crohn's colitis: A case report with literature review

Simon Siu-Man Ng, Raymond Ying-Chang Yiu, Janet Fung-Yee Lee, Jimmy Chak-Man Li, Ka-Lau Leung

Simon Siu-Man Ng, Raymond Ying-Chang Yiu, Janet Fung-Yee Lee, Jimmy Chak-Man Li, Ka-Lau Leung, Department of Surgery, The Chinese University of Hong Kong, Prince of Wales Hospital, Shatin, Hong Kong SAR, China

Correspondence to: Dr. Simon Siu-Man Ng, Department of Surgery, The Chinese University of Hong Kong, Prince of Wales Hospital, Shatin, Hong Kong SAR, China. simonng@surgery.cuhk.edu.hk

Telephone: +852-26321495 Fax: +852-26377974

Received: 2006-04-24 Accepted: 2006-05-22

© 2006 The WJG Press. All rights reserved.

Key words: Portal venous gas; Portal vein thrombosis; Pylephlebitis; Crohn's disease; Chinese

Ng SSM, Yiu RYC, Lee JFY, Li JCM, Leung KL. Portal venous gas and thrombosis in a Chinese patient with fulminant Crohn's colitis: A case report with literature review. *World J Gastroenterol* 2006; 12(34): 5582-5586

<http://www.wjgnet.com/1007-9327/12/5582.asp>

Abstract

Ever since its earliest reports, portal venous gas (PVG) has been associated with numerous intraabdominal catastrophes and has served as an indication for urgent surgical exploration. It is traditionally regarded to be an ominous finding of impending death, with highest mortality reported in patients with underlying bowel ischemia. Today, computed tomography has demonstrated a wider range of clinical conditions associated with PVG, some of which are 'benign' and do not necessarily require surgery, unless when there are signs of intraabdominal catastrophe or systemic toxicity. One of these 'benign' conditions is Crohn's disease. The present report describes a 19-year-old Chinese boy with Crohn's pancolitis who presented with septic shock associated with PVG and portal vein thrombosis, and was successfully managed surgically. To our knowledge, this is the first report of PVG and portal vein thrombosis associated with Crohn's disease in a Chinese patient. In addition, we have also reviewed the reports of another 18 Crohn's patients with PVG previously described in the English literature. Specific predisposing factors for PVG were identified in 8 patients, including barium enema, colonoscopy, blunt abdominal trauma, and enterovenous fistula. The patients who developed PVG following barium enema and blunt trauma were all asymptomatic and no specific treatment was necessary. Eleven patients (58%) who presented with signs of intraabdominal catastrophe or systemic toxicity required either immediate or eventual surgery. The overall mortality rate among the 19 patients was only 11%. The present literature review has shown that the finding of PVG associated with Crohn's disease does not always mandate surgical intervention. It is the clinical features and the related complications that ultimately determine the treatment approaches. The overall outcome of PVG associated with Crohn's disease has been favourable.

INTRODUCTION

Portal venous gas (PVG) is a rare radiological finding that occurs when intraluminal gas from the gastrointestinal tract or gas-forming bacteria enters the portal venous circulation^[1]. Factors predisposing to PVG include bowel mucosal injury, bowel distension, and sepsis^[2]. Ever since its earliest reports^[3,4], PVG has been associated with numerous intraabdominal catastrophes and has served as an indication for urgent surgical exploration. It is traditionally regarded to be an ominous finding of impending death, with highest mortality reported in patients with underlying bowel ischemia^[2]. However, it is becoming apparent that there are conditions in which the finding of PVG is relatively 'benign' and does not always indicate surgery, and these conditions include digestive tract dilatation, ulcerative colitis, Crohn's disease, and complications of iatrogenic and endoscopic procedures^[5]. Remarkably, there are reports of PVG occurring in patients with uncomplicated Crohn's disease after blunt trauma^[6,7] or colonic diagnostic procedures^[8,9], which resolves spontaneously without treatment. On the other hand, when PVG occurs in Crohn's patients with signs of intraabdominal catastrophe or systemic toxicity, urgent surgery is warranted, and the final outcome has mostly been favourable^[10-18]. The present report describes a 19-year-old Chinese boy with Crohn's pancolitis who presented with septic shock associated with PVG and portal vein thrombosis, and was successfully managed surgically. To our knowledge, this is the first report of PVG and portal vein thrombosis associated with Crohn's disease in a Chinese patient. The literature of PVG associated with Crohn's disease is also reviewed, with special emphasis on the clinical features, the various predisposing factors, and the treatment approaches.

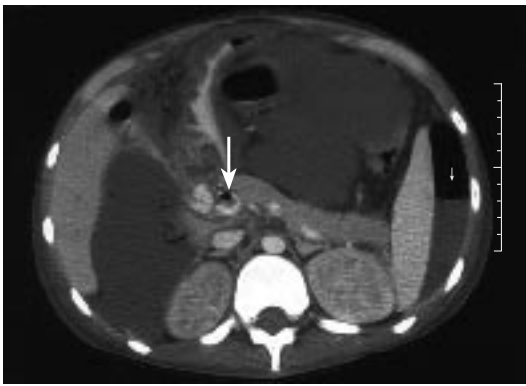


Figure 1 Computed tomography of the abdomen showing evidence of portal venous gas (long arrow), portal vein thrombosis, gross ascites, and pneumoperitoneum (short arrow).

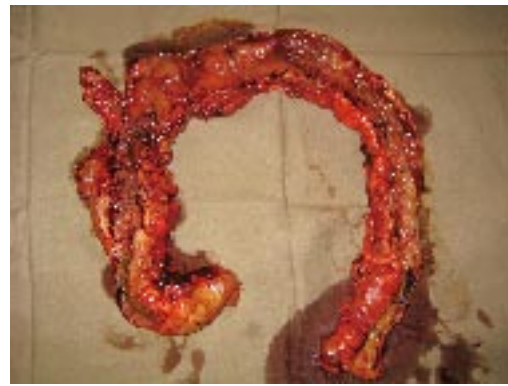

Figure 2 Photograph of the total colectomy specimen showing the classical features of Crohn's colitis: cobblestone mucosa with skipped lesions.

CASE REPORT

A 19-year-old Chinese boy presented to the Accident and Emergency Department of our hospital with fever, hypotension, and abdominal distension. He had been diagnosed with Crohn's pancolitis a year ago and had been treated with mesalazine, but the drug compliance was poor. One month prior to this hospitalization, he had been admitted to another hospital because of fever and bloody diarrhoea. He was treated as a flare-up of Crohn's disease with intravenous steroid and antibiotics. However, his condition remained static despite a week of medical treatment, and he insisted to be discharged against medical advice. He consulted a Chinese herbalist and consumed some Chinese herbal medicines, but his condition continued to deteriorate. He became so ill that his parents finally brought him to our hospital to seek for further medical treatment.

On arrival, his temperature was 38°C, blood pressure 86/40 mmHg and heart rate 153 beats/min respectively. The abdomen was grossly distended and tense, although no frank peritoneal sign could be elicited. Initial blood tests showed leukocytosis, coagulopathy, and metabolic acidosis. He was immediately admitted to the Intensive Care Unit (ICU); aggressive fluid resuscitation and antibiotics were given. After initial stabilization, an urgent computed tomography (CT) of the abdomen and pelvis was performed, which showed evidence of portal venous gas, portal vein thrombosis, gross ascites, and pneumoperitoneum (Figure 1). The small bowel appeared thickened and inflamed, but the large bowels were not clearly demonstrated. The diagnosis was compatible with Crohn's disease with bowel perforation and septic shock, and hence an emergency laparotomy was arranged.

Intraoperatively, generalized peritonitis with 2–3 L of faeculent fluid and pus was noted throughout the peritoneal cavity. The small and large bowels were densely matted together by inflammatory adhesions. The large bowel appeared shrunken and chronically diseased, but no perforated site was identified. No obvious stricture or perforation was noted along the small bowel. The adhesions between the bowels were removed, and this already resulted in a blood loss of 9 L because of severe coagulopathy. Damage control surgery with packing of all the raw areas was done and the patient was sent back to the ICU for

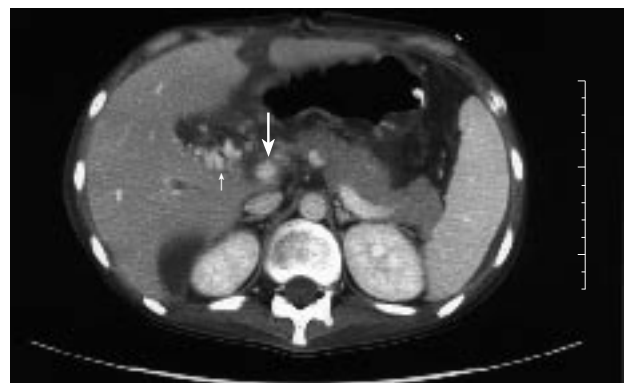

Figure 3 Computed tomography of the abdomen showing evidence of partial recanalization of the portal vein (long arrow) with increasing surrounding collaterals (short arrow).

further stabilization. NovoSeven (recombinant coagulation factor VIIa) and blood products were given to correct the coagulopathy. A second-look laparotomy performed 24 h later showed no more active bleeding from the raw areas. No obvious perforated site was identified along the gastrointestinal tract. The small bowel appeared edematous but viable, while the large bowel appeared shrunken and unhealthy. Thus a total colectomy was performed to remove the diseased large bowel (Figure 2). The abdomen was temporarily closed using a sterile plastic bag to avoid abdominal compartment syndrome. The abdomen was subsequently closed at a 3rd laparotomy 48 h later and an end ileostomy was fashioned. Pathological examination of the resected colon showed severe Crohn's colitis with multiple ulcerations and deep fissures but without perforation.

The postoperative course was very stormy and the patient had prolonged stay in the ICU. Peritoneal swab cultures and blood cultures grew *Enterococcus* and Methicillin-resistant *Staphylococcus aureus* and so vancomycin was added to the treatment regimen. For the portal vein thrombosis, anticoagulation therapy was not started initially because of coagulopathy. Nevertheless, partial recanalization of the portal vein with increasing collaterals was evident on follow-up CT a few weeks later (Figure 3). One month after the 3rd surgery, he developed an episode of massive intraabdominal haemorrhage secondary to erosion of a

Table 1 Clinical features, predisposing factors, treatment, and outcome of 19 Crohn's patients with PVG reported in the English literature

Author (yr)	Sex/age	Clinical features	Predisposing factors	Diagnostic modality	Treatment	Operative findings	Outcome
Reiner <i>et al</i> (1978) ^[10]	F/34	Fever and abdominal pain	Enterovenous fistula	Plain X-ray	Antibiotics and surgery	Ileitis	Survived
Sadhu <i>et al</i> (1979) ^[8]	F/64	No symptom or morbidity	Barium enema	Plain X-ray	No treatment	/	Survived
Gosink (1981) ^[11]	M/45	Fever and abdominal pain	/	US	Surgery	Inflamed colon	Survived
Pappas <i>et al</i> (1984) ^[9]	M/36	No symptom or morbidity	Sigmoidoscopy, barium enema	Plain X-ray	No treatment		Survived
Huycke <i>et al</i> (1985) ^[12]	M/22	Resolution of toxic megacolon; developed abdominal pain and free peritoneal air after colonoscopy	Colonoscopy	Plain X-ray	Antibiotics and surgery	Ileitis and colitis, no perforation	Survived
Katz <i>et al</i> (1986) ^[21]	M/14	No symptom or morbidity	Barium enema	Plain X-ray	Antibiotics		Survived
Ajzen <i>et al</i> (1988) ^[13]	M/64	Severe epigastric pain	Enterovenous fistula	US, CT	Surgery	Ileitis	Died of sepsis and liver failure 1 mo later
Venugopal <i>et al</i> (1990) ^[14]	F/27	Fever	/	CT	Surgery	Ileitis, no perforated or ischaemic bowel	Survived
Kirsch <i>et al</i> (1990) ^[22]	F/26	Epigastric pain and chills	/	Plain X-ray, CT	Antibiotics	/	Survived
Delamarre <i>et al</i> (1991) ^[23]	M/70	Fever	/	CT	Antibiotics	/	Survived
al-Jahdali <i>et al</i> (1994) ^[15]	F/40	Fever	/	CT	Antibiotics (Surgery 2 wk later)	Ileitis	Survived
Hong <i>et al</i> (1997) ^[16]	M/58	Fever, status post-low anterior resection and small bowel resection	/	CT	Antibiotics	/	Survived
Hong <i>et al</i> (1997) ^[16]	F/71	Abdominal pain (Developed free peritoneal air 2 wk later)	/	CT	Antibiotics (Surgery 2 wk later)	Ischaemic and perforated small bowel	Died of disseminated cytomegalovirus infection
Hong <i>et al</i> (1997) ^[16]	M/24	Fever (Developed abdominal pain 4 wk later)	/	CT	Antibiotics (Surgery 4 wk later)	Ileitis	Survived
Brandon <i>et al</i> (2000) ^[17]	F/59	Fever and abdominal pain	/	CT	Surgery	Ileitis and colitis	Survived
Nesher <i>et al</i> (2002) ^[6]		No symptom or morbidity	Blunt trauma	CT	No treatment	/	Survived
Paran <i>et al</i> (2003) ^[7]	F/25	No symptom or morbidity	Blunt trauma	CT	No treatment	/	Survived
Thethy <i>et al</i> (2005) ^[18]	F/58	Fever	/	CT	Surgery	Sigmoid inflammatory mass	Survived
Present case	M/19	Septic shock with free peritoneal air	/	CT	Surgery	Colitis, no perforation	Survived

US: Ultrasonography; CT: Computed tomography.

mesenteric vessel by an infected collection and required a 4th laparotomy for haemostasis. Fortunately, he recovered quite uneventfully thereafter and was subsequently discharged home 2 mo after the first surgery.

The patient was put on maintenance mesalazine and azathioprine and remained well and asymptomatic 14 mo after the surgery. A CT enteroclysis was performed later and showed no evidence of small bowel involvement.

DISCUSSION

Portal venous gas was first described by Wolfe and Evans

in 1955 in 6 neonates with fatal necrotizing enterocolitis^[3]. In 1960, Susman and Senturia reported the similar finding in an adult, critically ill with small bowel infarction^[4]. Since then, PVG has been reported with increasing frequency in the literature. One of the first reviews by Liebman *et al* evaluated 64 patients with PVG on plain X-ray reported in the literature before 1977^[2]. According to that review, although PVG was observed in association with various clinical conditions, it was mostly (72%) found among patients seriously ill with necrotic bowel. The overall mortality was 75%, and this led the authors to recommend urgent surgical exploration for PVG except for patients with stable

ulcerative colitis who had undergone barium enemas, because 5 such patients survived with conservative treatment. Over the last 2 to 3 decades, advances in diagnostic radiology, including the development of ultrasonography and CT, have increased the sensitivity of imaging PVG. Brandon *et al* suggested that early recognition using CT, with appropriate surgical intervention, improves the chance for patient survival when PVG is identified^[17]. Moreover, PVG on CT has been found to be associated with a wider range of clinical conditions, some of which are 'benign' and do not necessarily require surgical intervention, especially when there are no signs of intraabdominal catastrophe or systemic toxicity^[19]. A recent study of 17 patients with PVG detected by CT has actually reported a mortality rate as low as 29%^[20]. Today, PVG is recognized as a mere diagnostic clue in patients with suspected acute abdominal pathology and is not itself a predictor of mortality. The more relevant prognosticator is the clinical condition in which PVG occurs.

One of the relatively 'benign' conditions that are associated with PVG is Crohn's disease. Including the present case, 19 cases of PVG associated with Crohn's disease were reported in the English literature (Table 1)^[6-18,21-23]. In 4 of these patients, PVG was iatrogenic in origin, resulting from barium enema^[8,9,21] or colonoscopy^[12]. Two patients developed PVG after blunt abdominal trauma^[6,7]. It has been postulated that elevated intraluminal pressure (during colonic diagnostic procedures) or intraperitoneal pressure (associated with blunt trauma) can permit bowel gas or gas-forming bacteria to gain access to the portal venous circulation through microscopic mucosal injury. Another factor predisposing to PVG is the development of entero-venous fistula between the bowel lumen and the mesenteric venous system, which is an extremely rare complication reported in 2 patients with Crohn's disease^[10,13]. In the remaining 11 patients, no specific predisposing factors could be identified. PVG in these patients is thought to be the result of mucosal injury and sepsis^[2] associated with bowel inflammation and portal pyaemia. The occurrence of PVG does not seem to be associated with the anatomical location of Crohn's disease involvement. Both ileal and colonic diseases can develop PVG.

The finding of PVG associated with Crohn's disease does not always mandate surgical intervention. It is the clinical features and the related complications that ultimately determine the treatment approaches. The presentation of PVG following blunt trauma^[6,7] and barium enema^[8,9,21] is remarkably innocuous; all the 5 reported patients were asymptomatic and no specific treatment was necessary (except in 1 patient who was given 'prophylactic antibiotics' for 48 h^[21]). Intravenous antibiotics were administered to patients who developed fever, and 3 of them had complete resolution of symptoms with this simple medical treatment^[16,22,23]. Eleven patients (58%) who presented with signs of intraabdominal catastrophe or systemic toxicity required either immediate or eventual surgery. All these patients underwent resection of the inflamed small and large bowels. The overall mortality rate among the 19 patients was only 11%; a patient with entero-venous fistula died of sepsis and liver failure 1 mo after surgery^[13], while another patient who underwent surgery for ischemic and perforated small bowel finally died of disseminated cytomegalovirus infection^[16].

rated small bowel finally died of disseminated cytomegalovirus infection^[16].

The combination of extensive pylephlebitis (or septic thrombosis of the portal vein) and PVG that occurs in our case is an extremely rare complication among patients with Crohn's disease; only 1 similar case was reported in the German literature^[24]. Severe active Crohn's disease and sepsis are the 2 predisposing factors^[25]. Although PVG itself is not a predictor of mortality, the finding of PVG combined with pylephlebitis is generally regarded as an ominous prognostic sign^[26]. Nevertheless, as illustrated in our case, favourable clinical outcome in these patients can still be achieved with early CT diagnosis, maximal organ support in the ICU, aggressive medical treatment, and prompt surgical intervention.

In conclusion, the finding of PVG associated with Crohn's disease does not always mandate surgical intervention. It is the clinical features and the related complications that ultimately determine the treatment approaches. The overall outcome of PVG associated with Crohn's disease has been favourable.

REFERENCES

- Hou SK, Chern CH, How CK, Chen JD, Wang LM, Lee CH. Hepatic portal venous gas: clinical significance of computed tomography findings. *Am J Emerg Med* 2004; **22**: 214-218
- Liebman PR, Patten MT, Manny J, Benfield JR, Hechtman HB. Hepatic-portal venous gas in adults: etiology, pathophysiology and clinical significance. *Ann Surg* 1978; **187**: 281-287
- Wolfe JN, Evans WA. Gas in the portal veins of the liver in infants; a roentgenographic demonstration with postmortem anatomical correlation. *Am J Roentgenol Radium Ther Nucl Med* 1955; **74**: 486-488
- Susman N, Senturia HR. Gas embolization of the portal venous system. *Am J Roentgenol Radium Ther Nucl Med* 1960; **83**: 847-850
- Kinoshita H, Shinozaki M, Tanimura H, Umemoto Y, Sakaguchi S, Takifuji K, Kawasaki S, Hayashi H, Yamaue H. Clinical features and management of hepatic portal venous gas: four case reports and cumulative review of the literature. *Arch Surg* 2001; **136**: 1410-1414
- Nesher E, Aizner A, Kashtan H, Kaplan O, Kluger Y, Greenberg R. Portal vein air embolization after blunt abdominal trauma: a case report and review of the literature. *Eur J Emerg Med* 2002; **9**: 163-165
- Paran H, Epstein T, Gutman M, Shapiro Feinberg M, Zissin R. Mesenteric and portal vein gas: computerized tomography findings and clinical significance. *Dig Surg* 2003; **20**: 127-132
- Sadhu VK, Brennan RE, Madan V. Portal vein gas following air-contrast barium enema in granulomatous colitis: report of a case. *Gastrointest Radiol* 1979; **4**: 163-164
- Pappas D, Romeu J, Tarkin N, Dave PB, Messer J. Portal vein gas in a patient with Crohn's colitis. *Am J Gastroenterol* 1984; **79**: 728-730
- Reiner L, Freed A, Bloom A. Enterovenous fistulization in Crohn's disease. *JAMA* 1978; **239**: 130-132
- Gosink BB. Intrahepatic gas: differential diagnosis. *AJR Am J Roentgenol* 1981; **137**: 763-767
- Huycke A, Moeller DD. Hepatic portal venous gas after colonoscopy in granulomatous colitis. *Am J Gastroenterol* 1985; **80**: 637-638
- Ajzen SA, Gibney RG, Cooperberg PL, Scudamore CH, Miller RR. Enterovenous fistula: unusual complication of Crohn disease. *Radiology* 1988; **166**: 745-746
- Venugopal C, Colley DP. Portal venous gas in a patient with Crohn's disease. *J Clin Gastroenterol* 1990; **12**: 595-597
- al-Jahdali H, Pon C, Thompson WG, Matzinger FR. Non-fatal

- portal pyaemia complicating Crohn's disease of the terminal ileum. *Gut* 1994; **35**: 560-561
- 16 **Hong JJ**, Gadaleta D, Rossi P, Esquivel J, Davis JM. Portal vein gas, a changing clinical entity. Report of 7 patients and review of the literature. *Arch Surg* 1997; **132**: 1071-1075
- 17 **Brandon T**, Bogard B, ReMine S, Urban L. Early recognition of hepatic portal vein gas on CT with appropriate surgical intervention improves patient survival. *Curr Surg* 2000; **57**: 452-455
- 18 **Thethy SS**, Potter MA. An unusual complication of Crohn's colitis. *Gut* 2005; **54**: 768, 796
- 19 **Iannitti DA**, Gregg SC, Mayo-Smith WW, Tomolonis RJ, Cioffi WG, Pricolo VE. Portal venous gas detected by computed tomography: is surgery imperative? *Dig Surg* 2003; **20**: 306-315
- 20 **Faberman RS**, Mayo-Smith WW. Outcome of 17 patients with portal venous gas detected by CT. *AJR Am J Roentgenol* 1997; **169**: 1535-1538
- 21 **Katz BH**, Schwartz SS, Vender RJ. Portal venous gas following a barium enema in a patient with Crohn's colitis. A benign finding. *Dis Colon Rectum* 1986; **29**: 49-51
- 22 **Kirsch M**, Bozdech J, Gardner DA. Hepatic portal venous gas: an unusual presentation of Crohn's disease. *Am J Gastroenterol* 1990; **85**: 1521-1523
- 23 **Delamarre J**, Capron JP, Dupas JL, Deschepper B, Jouet-Gondry C, Rudelli A. Spontaneous portal venous gas in a patient with Crohn's ileocolitis. *Gastrointest Radiol* 1991; **16**: 38-40
- 24 **Kluge S**, Hahn KE, Lund CH, Gocht A, Kreyman G. [Pylephlebitis with air in the portal vein system. An unusual focus in a patient with sepsis]. *Dtsch Med Wochenschr* 2003; **128**: 1391-1394
- 25 **Crowe A**, Taffinder N, Layer GT, Irvine A, Nicholls RJ. Portal vein thrombosis in a complicated case of Crohn's disease. *Postgrad Med J* 1992; **68**: 291-293
- 26 **Häner C**, Inderbitzi R, Badulescu M, Teuscher J. [Septic pylephlebitis with detection of gas in the portal vein: a rare complication of sigmoid diverticulitis]. *Schweiz Med Wochenschr* 1998; **128**: 1339-1344

S- Editor Pan BR L- Editor Zhu LH E- Editor Bai SH