



Clinical application of self-expanding metallic stent in the management of acute left-sided colorectal malignant obstruction

You-Ben Fan, Ying-Sheng Cheng, Ni-Wei Chen, Hui-Min Xu, Zhe Yang, Yue Wang, Yu-Yao Huang, Qi Zheng

You-Ben Fan, Zhe Yang, Yue Wang, Yu-Yao Huang, Qi Zheng, Department of Surgery, Sixth People's Hospital, Shanghai Jiaotong University, Shanghai 200233, China

Ying-Sheng Cheng, Department of Radiology, Sixth People's Hospital, Shanghai Jiaotong University, Shanghai 200233, China

Ni-Wei Chen, Hui-Min Xu, Department of Surgery, Sixth People's Hospital, Shanghai Jiaotong University, Shanghai 200233, China

Correspondence to: Dr. Qi Zheng, Department of Surgery, Sixth People's Hospital, Shanghai Jiaotong University, Shanghai 200233, China. sshosp@public.sta.net.cn

Telephone: +86-21-64368920 Fax: +86-21-64701361

Received: 2005-07-05 Accepted: 2005-09-19

Key words: SEMS; Acute left-sided colorectal malignant obstruction

Fan YB, Cheng YS, Chen NW, Xu HM, Yang Z, Wang Y, Huang YY, Zheng Q. Clinical application of self-expanding metallic stent in the management of acute left-sided colorectal malignant obstruction. *World J Gastroenterol* 2006; 12(5): 755-759

<http://www.wjgnet.com/1007-9327/12/755.asp>

Abstract

AIM: To summarize our experience with the application of self-expanding metallic stent (SEMS) in the management of acute left-sided colorectal malignant obstruction.

METHODS: A retrospective chart review of all patients undergoing placement of SEMS between April 2000 and January 2004 was performed.

RESULTS: Insertion of SEMS was attempted in 26 patients under fluoroscopic guidance with occasional endoscopic assistance. The sites of lesions were located in splenic flexure of two patients, left colon of seven patients, sigmoid colon of eight patients and rectum of nine patients. The intended uses of SEMS were for palliation in 7 patients and as a bridge to elective surgery in 19 patients. In the latter group, placement of SEMS allowed for preoperative systemic and bowel preparation and the following one-stage anastomosis. Successful stent placement was achieved in 22 (85%) of the 26 patients. The clinical bowel obstruction resolved 24 hours after successful stent placement in 21 (95%) patients. Three SEMS-related minor complications occurred, two stents migrated and one caused anal pain.

CONCLUSION: SEMS represents an effective and safe tool in the management of acute malignant colorectal obstruction. As a bridge to surgery, SEMS can provide time for systematic support and bowel preparation and obviate the need for fecal diversion or on-table lavage. As a palliative measure, SEMS can eliminate the need for emergent colostomy.

INTRODUCTION

Acute left-sided colorectal malignant obstruction represents a frequent surgical emergency. It is the first symptom in approximately 15-20% of colorectal cancers^[1-2]. Single-stage surgery (subtotal colectomy with primary anastomosis or partial colectomy with intraoperative lavage) appears to be gaining acceptance as a good therapeutic option in such cases. However, this treatment option is not feasible in all patients, and it is often necessary to use a two-stage procedure (Hartmann's procedure) or to perform permanent colostomy in advanced stages of the disease^[3]. Smothers *et al.*^[4] found that the overall surgical morbidity and mortality are significantly higher in patients with colon cancer undergoing emergency surgery than in those undergoing selective surgery. Some other factors such as advanced age as well as stage and volume of the disease are closely correlated with emergency surgery, and emergency surgery has a strong independent negative influence on immediate surgical morbidity and mortality. If emergency surgery could be transferred to elective surgery after a simple effective therapy, complications would be significantly decreased in patients with acute left-sided colorectal malignant obstruction.

SEMS^[5-7] has been used to relieve obstruction in different situations. Application of metallic stents in the treatment of acute malignant colonic obstruction was first reported by Dohmoto^[8] in 1991 and has become a promising treatment option, though the number of reported cases is only about 600 in the world^[9,10]. Placement of SEMS across the obstructing lesion can relieve obstructive symptoms and avoid emergency surgery. In most cases, a radical colectomy with primary

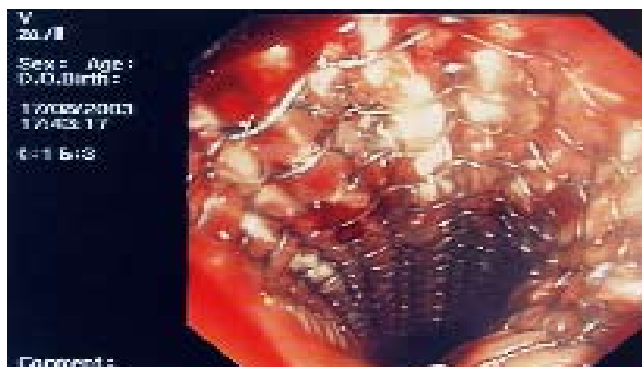


Figure 1 Endoscopic view of partially expanded stent immediately after the stent placement.

anastomosis can be subsequently performed in 6-9 days. Colostomy is the only surgical option, and implantation of stent is the best final palliative treatment in some cases with advanced stages of the disease^[11-23]. This report describes the experience with the application of SEMS in the management of acute malignant left-sided colorectal obstruction.

MATERIALS AND METHODS

Patients

All patients had clinical symptoms and signs of acute bowel obstruction. From April 2000 to January 2004, a total of 26 patients (16 men, 10 women; mean age: 63.23 years; range: 38-85 years) were selected to receive decompressive therapy by implanting SEMS. Patient selection criteria included the site of obstruction from the middle rectum to the descending colon and absence of bowel necrosis and perforation. Patients with more proximal obstructions were excluded on the basis of poor site accessibility and low emergency surgery risk. Age, general condition, and tumor stage were not used as exclusion criteria.

All patients received plain radiography of the abdomen and emergency contrast-enhanced computed tomography. The sites of obstruction were located in rectum of nine patients, sigmoid colon of eight patients, descending colon of seven patients and splenic flexure of two patients. Informed consent was obtained from all patients or from their relatives after the risks and benefits of treatment were fully explained.

Procedure

All procedures were performed at the interventional radiology by endoscopy (Figure 1) and fluoroscopy (Figure 2). Neither analgesia nor sedation was administered during the procedure. There was no routine administration of antibiotics.

Once the guide wire passed through the lesion, the catheter was advanced to the most proximal point, and contrast medium was injected to evaluate tumor length and exclude the possibility of perforation. The superstiff 0.038-inch guide wire was then inserted, and a stent was placed using the delivery system under fluoroscopic control (Figure 2).

Several silver clips were clipped around the lesion during colonoscopy. Then the guide wire inserted through the lesion under direct vision was confirmed to arrive at the splenic flexure under fluoroscopic monitor.

The stent used in all patients was esophageal endoprosthesis (Nanjing Microinvasive Corporation, China), 20 or 25 mm in diameter and 70-100 mm in length. After the placement of the stent, a catheter was inserted over the superstiff guide wire until the tip projected a few centimeters beyond the stent. Contrast medium was injected to ensure that the stent was placed properly across the tumor and to assess the stent patency.

When one stent was not long enough to span the lesion, a second stent was inserted to overlap the first. Balloon dilation was not performed in any of the patients either before or after the implantation of the stent.

Patients were transferred to the surgical ward for observation after the procedure. Abdominal plain radiography was performed to assess the stent expansion and patency as well as possible complications in 24 h. Once symptoms of obstruction remitted, further tumor staging and clinical evaluation were carried out to determine which patients should receive selective surgical therapy and which patients should undergo stent implantation as the definitive palliative treatment.

RESULTS

Successful stent placement was achieved in 22 (85%) of the 26 patients. The procedure could not be completed in four patients. The sites of lesions were located in splenic flexure of one patient, descending colon of two patients and sigmoid colon of one patient. The successful rate was 50% in splenic flexure (1/2), 71% in the descending colon (5/7), 89% in sigmoid colon (7/8), 100% in rectum (9/9), respectively. The obstruction could not be relieved in three patients even though the guide wire and catheter were advanced successfully to the edge of the lesion. Though the guide wire was successfully advanced proximally, the stent could not be implanted in the remaining patient because of the tortuosity of the rectosigmoid region. Emergency laparotomy was performed in these four patients, and colostomy or Hartmann's procedure was completed.

A total of 25 self-expanding metallic stents were implanted. One stent was placed in 19 patients and two stents in 3 patients. The mean fluoroscopy time of the procedure was 46 min (range: 15-120 min).

The clinical bowel obstruction resolved in 21 patients (21/22, 95%) within 24 h after successful stent placement, with expansion and patency observable in all radiographic films. Clinical failure occurred in one patient and symptom of incomplete obstruction persisted for 24 h following the successful placement of SEMS. Emergency laparotomy revealed vegetable residues proximal to the lesion and Hartmann's procedure was performed. Complications of SEMS placement occurred in three patients. Stent migration occurred in two patients after obstruction disappeared but no re-obstruction was found after stent migration. Mild anal pain persisted for one month in the remaining one because the stent was close to the anus. The

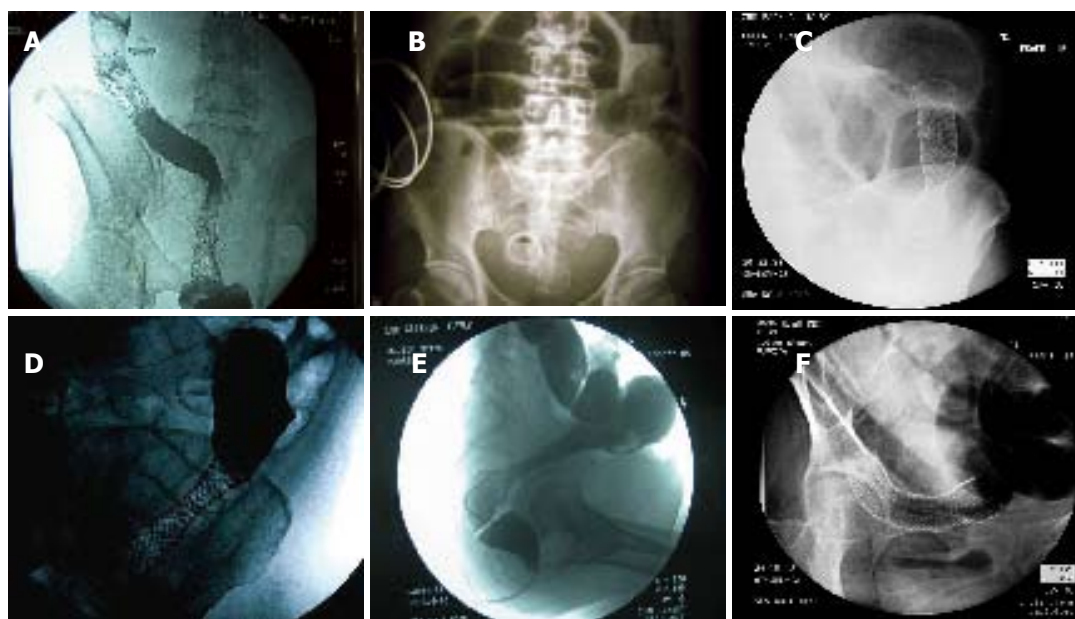


Figure 2 Good patency of the second stent coaxially placed covering the entire malignant stricture (A), a patent and nearly full in the upper rectum (B), SEMS with a waist shape in descending colon cancer (C), SEMS bridging the descending colon (D), a patent stent after SEMS placement in the rectum (E) and a bent stent in sigmoid cancer (F).

pain resolved after analgesic was administered (Table 1).

Surgery

Patients with operable colorectal carcinoma were considered as candidates for selective surgery. The mean time between stent placement and surgery was 8 ± 3 days (range: 5-11 days). These patients underwent adequate bowel preparation and adjuvant systematic therapy. The stent did not interfere with or prolong the surgery in any of these patients. The stents were fully expanded as well as in good position and afforded sufficient tumoral coverage (except for two patients with stent migration) and adequate cleaning of the colon in all patients during surgical exploration. Left colectomy, sigmoidectomy, and (low) anterior resection were performed in five patients, respectively.

Palliation

Stent placement was considered as the definitive palliative treatment of colonic obstruction in seven patients. Lesions were located at the sigmoid of three patients and rectum of four patients. Two patients suffered from gastric carcinoma with sigmoid or rectal seeding and three patients had primary sigmoid or rectal carcinomas with inoperable liver metastases. One patient with sigmoid carcinoma failed in stenting and underwent Hartmann's procedure. The other six patients received adjuvant chemotherapy, or radiation therapy, or both.

DISCUSSION

Usually, it is not difficult to detect acute left-sided colorectal obstruction by abdominal radiography. CT can help find the site and etiology of colon stenosis and the nature of acute colonic occlusion. Barium enema for the diagnosis and treatment of colonic obstruction is not recommended when doctors plan to implant SEMS^[12].

SEMS for colorectal obstruction was performed in the past either under radiological or endoscopic control. We introduced the guide wire under radiological and

endoscopic guidance in most patients. The guide wire could be inserted under direct vision, radiation exposure could be reduced, and biopsies for histology could be taken during the procedure.

Endoscopic placement of SEMS is advantageous over radiological placement because the accessibility to colorectal tumor sites is greater and stents can directly pass through the working channel of the endoscope^[13]. These advantages are especially obvious when the obstruction is proximal to the rectosigmoid. De Gregorio *et al.*^[14] have reported that the guide wire cannot be progressed under fluoroscopic guidance but reaches the neoplastic stricture under endoscopic guidance. Interventional radiologists are much more experienced in passing the guide wires through obstructive lesions and deploying SEMS^[12,13]. In our study, fluoroscopy in combination with endoscopy improved SEMS deployment. Even then, stent was still rather difficult to implant in the descending colon and splenic flexure compared with that in the rectum and sigmoid (6/9, 67%; 16/17, 94%; $P < 0.05$).

We treated 26 patients with acute malignant colorectal obstruction with SEMS placement with a successful rate of 85% (22/26). Only one patient (5%, 1/22) failed to relieve obstruction due to vegetable residues. If we had used colonoscopy to detect and get out the vegetable residues, the patient could have the obstruction relieved and emergency colostomy could not have been performed (Hartmann's procedure). After successful stent placement and proper bowel preparation, 15 patients achieved elective radical colorectal surgery and anastomosis without severe complication. Six patients with inoperable malignancy obviated emergency colostomy after successful stent placement. Although 85% of successful stent placement was a little lower than 90-95% of some foreign reports, we believe that success rate of SEMS placement would be further increased with more refined Chinese instruments and improved manipulation skill.

It was reported that SEMS placement can be used as a palliative treatment for colonic obstruction. In Cristina's study, in 17 (of 43) patients with Dukes D tumor (40%),

Table 1 Details of patients with colorectal obstruction after SEMS placement

Patient No. (gender/ age yr)	Diagnosis	Site of obstruction	Nature of treatment	Stent insertion	Stent number	Subsequent treatment	Complication
1 (F/45)	Primary Ca descending	Splenic flexure	Temporizing	Failed	-	Colostomy	No
2 (F/48)	Primary Ca rectum, ascites, liver metastasis	Middle rectum	Palliative	Successful	2	Chemo- therapy	No
3 (F/73)	Primary Ca rectum	Middle rectum	Temporizing	Successful	1	LAR	No
4 (F/38)	Primary Ca stomach	Sigmoid	Palliative	Successful	2	Chemo-radio therapy	No
5 (M/61)	Primary Ca descending	Descending upper	Temporizing	Successful	2	Left colectomy	No
6 (M/83)	Primary Ca rectum	Rectum	Temporizing	Successful	1	AR	No
7 (M/72)	Primary Ca descending	Descending	Temporizing	Failed	-	Colostomy	No
8 (M/76)	Primary Ca sigmoid, liver metastasis	Sigmoid	Palliative	Successful	1	Chemo- therapy	No
9 (F/44)	Primary Ca rectum	Upper and middle rectum	Temporizing	Successful	1	LAR	No
10 (F/74)	Primary Ca sigmoid	Sigmoid	Palliative	Failed	-	Hartmann	No
11 (M/45)	Primary Ca descending	Descending	Temporizing	Successful	1	Left colectomy	Migration
12 (F/70)	Primary Ca rectum	Upper rectum	Temporizing	Successful	1	AR	No
13 (M/48)	Recurrent Ca rectum	Upper rectum	Palliative	Successful	1	Chemo-radio therapy	Anal pain
14 (M/72)	Primary Ca descending	Splenic flexure	Temporizing	Successful	1	Left colectomy	No
15 (F/63)	Primary Ca sigmoid	Sigmoid	Temporizing	Successful	1	Sigmoidectomy	Migration
16 (M/40)	Primary Ca rectum	Upper rectum	Temporizing	Successful	1	LAR	No
17 (M/72)	Primary Ca descending	Descending	Temporizing	Successful	1	Hartmann	Food residue obstruction
18 (F/79)	Primary Ca rectum Liver metastasis	Middle rectum	Palliative	Successful	1	Chemotherapy	No
19 (M/45)	Primary Ca descending	Descending	Temporizing	Successful	1	Left colectomy	No
20 (M/85)	Primary Ca descending	Descending	Temporizing	Successful	1	Left colectomy	No
21 (M/41)	Gastric Ca rectum seeding	Rectum	Palliative	Successful	1	Chemo- therapy	No
22 (M/69)	Primary Ca descending	Descending	Temporizing	Failed	-	Hartmann	No
23 (M/74)	Primary Ca sigmoid	Sigmoid	Temporizing	Successful	1	Sigmoidectomy	No
24 (M/85)	Primary Ca sigmoid	Sigmoid	Temporizing	Successful	1	Sigmoidectomy	No
25 (M/75)	Primary Ca sigmoid	Sigmoid	Temporizing	Successful	1	Sigmoidectomy	No
26 (F/67)	Primary Ca sigmoid	Sigmoid	Temporizing	Successful	1	Sigmoidectomy	No

the stent was considered as a definitive palliative treatment. In only one case the abdominal computed tomography scan failed to detect peritoneal implants of tumor, and the metastatic disease was identified at the time of laparotomy. As a result, 17 (94%) out of 18 unnecessary operations were avoided^[24].

It was also reported that patients who were not operated have a shorter hospital stay and lower incidence of stoma after SEMS placement^[25].

Binkert *et al.*^[26] showed that SEMS placement can

reduce the cost due to a shorter hospital stay and a lower complication rate. Morino *et al.*^[27] have proposed a new minimally invasive therapeutic strategy for the management of acute malignant colonic obstructions: emergency endoscopic stenting followed by elective laparoscopic one-stage resection. They reported that four patients with malignant colonic obstruction had an immediate restored bowel functions after SEMS deployment within a period that varied from 4 to 5 days, then underwent a one-stage laparoscopic resection and were discharged 5-7 days later

without any complications.

Preoperative stent insertion for obstructive colorectal cancer can result in satisfactory postoperative outcome with good prognoses^[28]. Perforation is the most severe complication of SEMS placement. Neoplastic strictures of the colon are generally soft. Acute neoplastic occlusion may be caused by neoplastic edema or stool residue or both. If the guide wire can be passed through neoplastic strictures, stent placement without balloon dilation should be easy for experienced physicians. The incidence of perforation was 2% (12/493) in the non-balloon dilatation group and 10% (10/105) in the dilatation group, suggesting that balloon dilation should not be recommended^[9].

Some minor SEMS-placement-related complications including stent migration, mild bleeding, pain, and reobstruction may occur. Stent migration occurred in two patients of our group possibly due to abated edema and/or inadequate stent. Because of the limited cases and short survival time, we did not find reobstruction.

In conclusion, colorectal stenting procedure is effective and safe and can be used for acute left-sided colorectal malignant obstruction both as a temporary relief before selective resection and as a definitive treatment in palliative cases.

REFERENCES

- 1 **Umpleby HC**, Williamson RC. Survival in acute obstructing colorectal carcinoma. *Dis Colon Rectum* 1984; **27**: 299-304
- 2 **Kyllönen LE**. Obstruction and perforation complicating colorectal carcinoma. An epidemiologic and clinical study with special reference to incidence and survival. *Acta Chir Scand* 1987; **153**: 607-614
- 3 **Danis J**. Single-stage treatment for malignant left-sided colonic obstruction: a prospective randomized clinical trial comparing subtotal colectomy with segmental resection following intraoperative irrigation. *Br J Surg* 1996; **83**: 1303
- 4 **Smothers L**, Hynan L, Fleming J, Turnage R, Simmang C, Anthony T. Emergency surgery for colon carcinoma. *Dis Colon Rectum* 2003; **46**: 24-30
- 5 **Davids PH**, Groen AK, Rauws EA, Tytgat GN, Huibregtse K. Randomised trial of self-expanding metal stents versus polyethylene stents for distal malignant biliary obstruction. *Lancet* 1992; **340**: 1488-1492
- 6 **Bethge N**, Sommer A, Vakil N. Palliation of malignant esophageal obstruction due to intrinsic and extrinsic lesions with expandable metal stents. *Am J Gastroenterol* 1998; **93**: 1829-1832
- 7 **Cheng YS**, Li MH, Chen WX, Zhuang QX, Chen NW, Shang KZ. Follow-up evaluation for benign stricture of upper gastrointestinal tract with stent insertion. *World J Gastroenterol* 2003; **9**: 2609-2611
- 8 **Dohmoto M**. New method: endoscopic implantation of rectal stent in palliative treatment of malignant stenosis. *Endosc Dig* 1991; **3**: 1507-1512
- 9 **Dauphine CE**, Tan P, Beart RW, Vukasin P, Cohen H, Corman ML. Placement of self-expanding metal stents for acute malignant large-bowel obstruction: a collective review. *Ann Surg Oncol* 2002; **9**: 574-579
- 10 **Keymling M**. Colorectal stenting. *Endoscopy* 2003; **35**: 234-238
- 11 **Mosca S**. How can we improve the implementation of new endoscopic techniques? Concerning colonic stenting. *Endoscopy* 2003; **35**: 709-10; author reply 711-2
- 12 **Baron TH**, Dean PA, Yates MR, Canon C, Koehler RE. Expandable metal stents for the treatment of colonic obstruction: techniques and outcomes. *Gastrointest Endosc* 1998; **47**: 277-286
- 13 **Mainar A**, De Gregorio Ariza MA, Tejero E, Tobío R, Alfonso E, Pinto I, Herrera M, Fernández JA. Acute colorectal obstruction: treatment with self-expandable metallic stents before scheduled surgery--results of a multicenter study. *Radiology* 1999; **210**: 65-69
- 14 **de Gregorio MA**, Mainar A, Tejero E, Tobío R, Alfonso E, Pinto I, Fernández R, Herrera M, Fernández JA. Acute colorectal obstruction: stent placement for palliative treatment--results of a multicenter study. *Radiology* 1998; **209**: 117-120
- 15 **Choo IW**, Do YS, Suh SW, Chun HK, Choo SW, Park HS, Kang SK, Kim SK. Malignant colorectal obstruction: treatment with a flexible covered stent. *Radiology* 1998; **206**: 415-421
- 16 **Spinelli P**, Mancini A. Use of self-expanding metal stents for palliation of rectosigmoid cancer. *Gastrointest Endosc* 2001; **53**: 203-206
- 17 **Saida Y**, Sumiyama Y, Nagao J, Takase M. Stent endoprosthesis for obstructing colorectal cancers. *Dis Colon Rectum* 1996; **39**: 552-555
- 18 **Liberman H**, Adams DR, Blatchford GJ, Ternent CA, Christensen MA, Thorson AG. Clinical use of the self-expanding metallic stent in the management of colorectal cancer. *Am J Surg* 2000; **180**: 407-11; discussion 412
- 19 **Mosca S**, Festa P, Simeoli C, Bottino V, De Sena G. Acute neoplastic obstruction of the splenic flexure: effective presurgical palliation with a biliary metallic stent. *J Gastroenterol Hepatol* 2004; **19**: 235-238
- 20 **Camúñez F**, Echenagusia A, Simó G, Turégano F, Vázquez J, Barreiro-Meiro I. Malignant colorectal obstruction treated by means of self-expanding metallic stents: effectiveness before surgery and in palliation. *Radiology* 2000; **216**: 492-497
- 21 **Law WL**, Chu KW, Ho JW, Tung HM, Law SY, Chu KM. Self-expanding metallic stent in the treatment of colonic obstruction caused by advanced malignancies. *Dis Colon Rectum* 2000; **43**: 1522-1527
- 22 **Khot UP**, Lang AW, Murali K, Parker MC. Systematic review of the efficacy and safety of colorectal stents. *Br J Surg* 2002; **89**: 1096-1102
- 23 **Repici A**, Reggio D, De Angelis C, Barletti C, Marchesa P, Musso A, Carucci P, Debernardi W, Falco M, Rizzetto M, Saracco G. Covered metal stents for management of inoperable malignant colorectal strictures. *Gastrointest Endosc* 2000; **52**: 735-740
- 24 **Martínez-Santos C**, Lobato RF, Fradejas JM, Pinto I, Ortega-Deballón P, Moreno-Azcoita M. Self-expandable stent before elective surgery vs. emergency surgery for the treatment of malignant colorectal obstructions: comparison of primary anastomosis and morbidity rates. *Dis Colon Rectum* 2002; **45**: 401-406
- 25 **Law WL**, Choi HK, Chu KW. Comparison of stenting with emergency surgery as palliative treatment for obstructing primary left-sided colorectal cancer. *Br J Surg* 2003; **90**: 1429-1433
- 26 **Binkert CA**, Ledermann H, Jost R, Saurenmann P, Decurtins M, Zollikofer CL. Acute colonic obstruction: clinical aspects and cost-effectiveness of preoperative and palliative treatment with self-expanding metallic stents--a preliminary report. *Radiology* 1998; **206**: 199-204
- 27 **Morino M**, Bertello A, Garbarini A, Rozzio G, Repici A. Malignant colonic obstruction managed by endoscopic stent decompression followed by laparoscopic resections. *Surg Endosc* 2002; **16**: 1483-1487
- 28 **Saida Y**, Sumiyama Y, Nagao J, Uramatsu M. Long-term prognosis of preoperative "bridge to surgery" expandable metallic stent insertion for obstructive colorectal cancer: comparison with emergency operation. *Dis Colon Rectum* 2003; **46**: S44-S49

S- Editor Wang XL L- Editor Elsevier HK E- Editor Li HY