

RAPID COMMUNICATION

Magnifying colonoscopy as a non-biopsy technique for differential diagnosis of non-neoplastic and neoplastic lesions

Shigeharu Kato, Kuang I Fu, Yasushi Sano, Takahiro Fujii, Yutaka Saito, Takahisa Matsuda, Ikuro Koba, Shigeaki Yoshida, Takahiro Fujimori

Shigeharu Kato, Kuang I Fu, Yasushi Sano, Ikuro Koba, Shigeaki Yoshida, Division of Gastrointestinal Oncology and Digestive Endoscopy, National Cancer Center Hospital East, Kashiwa, Chiba 277-8577, Japan

Kuang-I Fu, Takahiro Fujimori, Department of Surgical and Molecular Pathology, Dokkyo University School of Medicine, 880 Kitakobayashi, Mibu, Shimotuga, Tochigi 321-0293, Japan
Takahiro Fujii, Yutaka Saito, Takahisa Matsuda, Division of Endoscopy, National Cancer Center Hospital, Tsukiji, Tokyo 104-0045, Japan

Correspondence to: Kuangi Fu, MD, Division of Gastrointestinal Oncology and Digestive Endoscopy, National Cancer Center Hospital East, Kashiwa 277-8577, Chiba, Japan. fukuangi@hotmail.com

Telephone: +81-47-1331111

Fax: +81-47-1314724

Received: 2005-09-16

Accepted: 2005-10-26

© 2006 The WJG Press. All rights reserved.

Key words: Non-biopsy technique; Magnifying colonoscopy; Indigo-carmin dye spraying; Pit Pattern

Kato S, Fu KI, Sano Y, Fujii T, Saito Y, Matsuda T, Koba I, Yoshida S, Fujimori T. Magnifying colonoscopy as a non-biopsy technique for differential diagnosis of non-neoplastic and neoplastic lesions. *World J Gastroenterol* 2006; 12(9):1416-1420

<http://www.wjgnet.com/1007-9327/12/1416.asp>

Abstract

AIM: To clarify whether mucosal crypt patterns observed with magnifying colonoscopy are feasible to distinguish non-neoplastic polyps from neoplastic polyps.

METHODS: From June 1999 through March 2000, 180 consecutive patients with 210 lesions diagnosed with a magnifying colonoscope (CF-200Z, Olympus Optical Co., Ltd., Tokyo, Japan) were enrolled. Magnification and chromoendoscopy with 0.2% indigo-carmin dye was applied to each lesion for mucosal crypt observation. Lesions showing types I and II crypt patterns were considered non-neoplastic and examined histologically by biopsy, whereas lesions showing types III to V crypt patterns were removed endoscopically or surgically. The correlation of endoscopic diagnosis and histologic diagnosis was then investigated.

RESULTS: At endoscopy, 24 lesions showed a type I or II pit pattern, and 186 lesions showed type III to V pit patterns. With histologic examination, 26 lesions were diagnosed as non-neoplastic polyps, and 184 lesions were diagnosed as neoplastic polyps. The overall diagnostic accuracy was 99.1% (208/210). The sensitivity and specificity were 92.3% (24/26) and 99.8% (184/186), respectively.

CONCLUSION: Magnifying colonoscopy could be used as a non-biopsy technique for differentiating neoplastic and non-neoplastic polyps.

INTRODUCTION

At colonoscopy, the most frequently encountered lesions are polyps, which are either non-neoplastic (hyperplastic, inflammatory, and hamartomatous) or neoplastic (adenoma and carcinoma). Most polyps detected during colonoscopy are hyperplastic or adenomatous. The adenoma-carcinoma sequence suggests that colorectal cancers develop from benign adenomas, and, thus, removal of adenomas but not hyperplastic polyps, could prevent colorectal cancers^[1, 2]. Therefore, it is important to distinguish hyperplastic polyps from adenomatous polyps at colonoscopy, as removal or biopsy of hyperplastic polyps wastes time and resources and might increase the incidence of complications, such as bleeding and perforation. We routinely use magnifying colonoscopes, which offer both standard and magnifying views^[3]. A magnifying view after chromoendoscopy enables us to observe the lesions' surface structures, the so-called pit patterns, which are reported to be closely related to the histology^[4-6]. To investigate whether magnification with chromoendoscopy using indigo-carmin can be used to reliably differentiate non-neoplastic lesions from neoplastic lesions before histological evaluation, we conducted this prospective study.

MATERIALS AND METHODS

From June 1999 through March 2000, all of the patients with lesions detected on colonoscopy without the following exclusion criteria were enrolled in this study, at the National Cancer Center Hospital East. The study protocol was approved by the institutional review board of our hospital. Informed consent was obtained from all patients before examination. Patients with colorectal

Table 1 Patients characteristics and clinicopathological features of resected lesions

| | |
|---|-------------------|
| Gender (male / female) | 124/56 |
| Mean age (range), years | 63.0 (37-76) |
| Histology | |
| Non-neoplastic (hyperplastic / others) | 24 (20/4) |
| Neoplastic (mild / moderate / severe atypia / mucosal cancer) | 186 (21/133/28/4) |
| Mean size of resected lesions (range), mm | 9.1 (3-18) |
| Location (proximal / distal) | 91/119 |
| Meantime to cecum (range), min | 8.3 (1-23) |
| Mean time for diagnosis and treatment (range), min | 22.5 (5-45) |

Table 2 Correlation of endoscopic diagnosis and histological diagnosis in this study

| Endoscopic diagnosis | Histological diagnosis | | Total | Diagnostic accuracy |
|----------------------|------------------------|------------|-------|---------------------|
| | Non-neoplastic | Neoplastic | | |
| Type I-II | 24 | 0 | 24 | 100% |
| Type III-V | 2 | 184 | 186 | 99.8% |
| Total | 26 | 184 | 210 | |

lesions that had been previously evaluated by histologic examination or colonoscopy were excluded from this study. Patients, without informed consents, with inflammatory bowel disease, hereditary nonpolyposis colorectal cancer and familial adenomatous polyposis were also excluded.

A dose of two liters of preparatory solution of electrolytes and polyethylene glycol was administered orally to each patient for preparation before colonoscopy. If there was no contraindication to its use, an anticholinergic agent (buscopan 20 mg) was administered intramuscularly before each examination to prevent persistent colonic spasms. All colonoscopies were carried out using commercially available videocolonoscopes (CF-200Z; Olympus Optical Co., Ltd., Tokyo, Japan) that provide both conventional and magnifying images. All lesions detected at colonoscopy were diagnosed with magnification and chromoendoscopy using 0.2% indigo-carmin dye. The size of a lesion was estimated using open biopsy forceps or a method of removal (i.e., hot biopsy or snare polypectomy). The classification of mucosal crypt patterns was based on Kudo's classification (types I to V). The type I crypt pattern consists of regular round crypts, type II consists of stellar or papillary crypts, type III consists of tubular crypts or roundish crypts smaller than normal crypts, type IV consists of sulcus, branch, or gyrus-like crypts, and type V consists of irregular or severely distorted crypts^[4-6]. On the basis of mucosal crypt patterns observed with magnification and chromoendoscopy, detected lesions were divided into a non-neoplastic group (types I and II mucosal crypt patterns) or a neoplastic group (types III to V mucosal crypt patterns). All diagnostic and treatment procedures were performed by a colonoscopist (SK) well trained in magnifying colonoscopy.

For histological evaluation, the lesions diagnosed as non-neoplastic were examined at biopsy and lesions diagnosed as neoplastic were removed endoscopically or surgically without exception. Histological diagnosis was made by a pathologist blinded to the colonoscopic diagnosis. The pathological definition of the lesions was established by the Japanese Research Society for Cancer

of the Colon and Rectum^[7]. Histologically, adenoma and carcinoma were defined as neoplastic lesions and other non-neoplastic lesions including hyperplastic polyps, were defined as non-neoplastic lesions. The correlation of magnifying colonoscopic diagnosis and final pathological findings was evaluated to calculate the accuracy rate of endoscopic diagnosis.

Chi-square analysis was performed for comparisons. Differences with a *p*-value less than 0.05 were considered significant. All analyses were performed using Stat View software (Version 5.0 for Windows, SAS Institute Inc., Cary, NC)

RESULTS

The characteristics of the patients and colorectal lesions are shown in Table 1. The 180 patients included 124 males and 56 females, with a mean age of 63.0 years (range, 37 to 76 years). The mean sizes of non-neoplastic lesions and neoplastic lesions were 7.8 mm and 9.2 mm, respectively. Although, neoplastic lesions seemed to be larger than non-neoplastic lesions, they did not differ significantly in size. Two hundred ten colorectal lesions, including 24 non-neoplastic lesions (hyperplastic polyp, 20; others, 4) and 186 neoplastic lesions were detected and evaluated at histologic examination without exception. Ninety-one lesions were located in the proximal colon, and 119 lesions were located in the distal colon. Total colonoscopy and histological evaluation were performed without complications in all cases.

At colonoscopy, 24 lesions showed a type I or II pit pattern, whereas 186 lesions showed types III to V pit patterns. At histologic examination, 26 lesions were diagnosed as non-neoplastic polyps, and 184 lesions were diagnosed as neoplastic polyps. The overall diagnostic accuracy was 99.1% (208/210). The diagnostic accuracy for non-neoplastic pit patterns (negative predictive value) was 100% (24/24). The accuracy of neoplastic pit patterns (positive predictive value) was 99.8% (184/186) (Table 2). The sensitivity and specificity of this endoscopic diagnosis

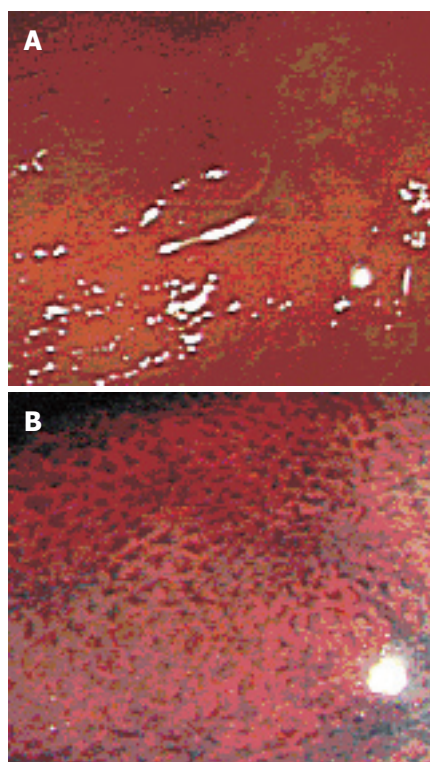


Figure 1 A: Colonoscopy revealed a small reddish polypoid lesion 3 mm in diameter. **B:** Chromoendoscopy with magnification disclosed a type II pit, and the lesion was diagnosed as non-neoplastic and examined at biopsy. The histologic diagnosis was hyperplastic polyp.

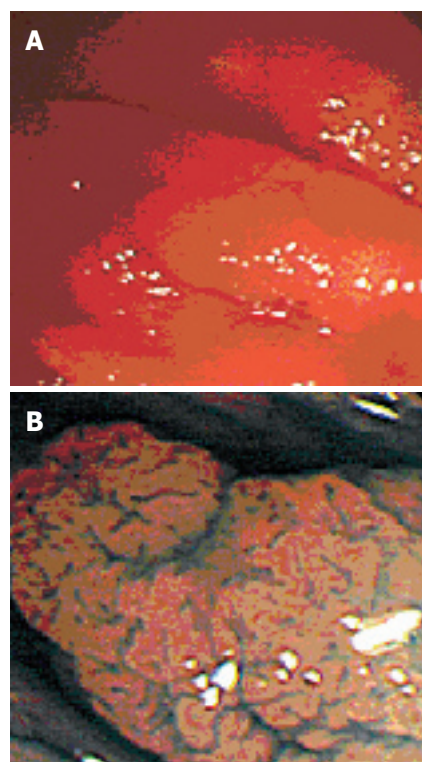


Figure 2 A: Colonoscopy revealed a small flat lesion 5 mm in diameter. **B:** Chromoendoscopy with magnification disclosed a type III pit, and the lesion was diagnosed as neoplastic and resected by snare polypectomy. The histologic diagnosis was adenoma with moderate atypia.

Table 3 Summaries of the previous reports and this study on overall diagnostic accuracy, sensitivity, specificity and predictive values in differentiating non-neoplastic lesions from neoplastic ones

| Author | Method | Number of lesions | Overall accuracy (%) | Sensitivity (%) | Specificity (%) | PPV ¹ (%) | NPV ² (%) |
|------------|-----------------|-------------------|------------------------|-------------------|-------------------|------------------------|------------------------|
| Chapius | Ordinary | 120 | 82.5 | 84.5 | 77.7 | 89.8 | 68.3 |
| Neale | Ordinary | 181 | 80.2 | 69.2 | 85.4 | 69.2 | 85.5 |
| Konishi | Ordinary | 407 | 68 | 90 | 61 | 94.4 | 85.1 |
| Fu | Ordinary | 206 | 84.0 | 88.8 | 67.4 | 93.4 | 63.3 |
| Eisen | Chromoendoscopy | 480 | 82.1 | 82 | 82 | 75 | 88 |
| Kiesslich | Chromoendoscopy | 283 | 92.6 | 92.4 | 93.2 | 97.5 | 81 |
| Fu | Chromoendoscopy | 206 | 89.3 | 93.1 | 76.1 | 93.1 | 76.1 |
| Axelard | Magnifying | 55 | 94.5 | 92.9 | 95.1 | 86.7 | 97.5 |
| Togashi | Magnifying | 923 | 88.4 | 92 | 73.3 | 94.2 | 85.2 |
| Tung | Magnifying | 175 | 80.6 | 93.8 | 64.6 | 76.3 | 89.5 |
| Liu | Magnifying | 954 | 86.1 | 90.8 | 72.7 | 90.4 | 73.6 |
| Konishi | Magnifying | 405 | 92 | 97 | 100 | 96.3 | 86.5 |
| Fu | Magnifying | 206 | 95.6 | 96.3 | 93.5 | 98.1 | 87.8 |
| Hurlstone | Magnifying | 1008 | 95 | 98 | 92 | 95 | 96 |
| This study | Magnifying | 210 | 99.1 | 92 | 100 | 100 | 99.8 |

¹PPV: positive predictive value, ²NPV: negative predictive value

are 92.3% (24/26) and 99.8% (184/186), respectively. (Figures 1 and 2).

DISCUSSION

Previous studies in patients undergoing colonoscopy for various reasons were found that small polyps are identified at more than 50% of examinations^[8]. More than 50% of these small polyps are adenomas^[8-12]. Therefore, a key clinical decision in patients with small polyps may depend on the determination of histology. According to the American Society for Gastrointestinal Endoscopy guidelines issued in 2005, during colonoscopy every effort should be made to obtain a tissue diagnosis when encountering polyps, mass, lesions, or colonic strictures^[13].

However, if lesions could be accurately determined to be non-neoplastic or neoplastic at colonoscopy, biopsies or resections would be unnecessary. Various data on the diagnostic abilities of such differentiation by conventional colonoscopy, chromoendoscopy, and magnifying colonoscopy have been reported and are summarized in Table 3^[14-24].

Among the methods described above, magnifying colonoscopy with chromoendoscopy seems to provide higher diagnostic accuracy than that by conventional colonoscopy or chromoendoscopy. The efficacy of magnifying colonoscopy is often determined in conjunction with intravital staining techniques, of which indigo-carmin staining is generally preferred. Surface analysis of colorectal lesions by magnifying colonoscopy

in addition to chromoendoscopy has been established by Kudo *et al*^[4-6]. They compared the mucosal crypt patterns on stereomicroscopy and colonoscopy with histological sections taken on the horizontal axis and found strong correlations with the histologic features of the lesions. The mucosal crypt patterns were divided into six groups: types I, II, IIIL, IIIs, IV, and V^[4-6]. Furthermore, with regard to treatment decision, we re-categorized these patterns into 3 groups as non-neoplastic (types I and II), no treatment or biopsy, non-invasive (types IIIL, IIIs, IV), endoscopic removal; and invasive (type V), surgical resection^[25]. The present study was conducted prospectively to show the usefulness of pit patterns for distinguishing non-neoplastic lesions from neoplastic lesions with magnifying colonoscopy.

Our data indicate that magnifying colonoscopy with chromoendoscopy can be used to differentiate almost all lesions detected at colonoscopy before histological evaluation. This method requires a magnifying colonoscope and 0.2% indigo-carmin dye to render the pits clearly visible, but this technique may be slightly troublesome.^[26] However, the poor diagnostic reliability of conventional colonoscopy would lead to a significant number of biopsies or resections of non-neoplastic polyps, which would also waste time and resources on unnecessary histopathological examinations. Matsuda *et al* have described the cost-effectiveness of conventional colonoscopy and magnifying colonoscopy^[27]. They reported that the percentage of hyperplastic polyps resected after conventional colonoscopy was significantly higher than that after magnifying colonoscopy (8.6% vs 2.9%) and also concluded that routine use of magnifying colonoscopy would reduce unnecessary resections.

Undoubtedly, colonoscopists require training and experience to correctly judge lesions with magnifying colonoscopy. However, there has been little systematic investigation of this issue. Kobayashi *et al*, have investigated the case with which an inexperienced examiner could learn pit pattern diagnosis^[28]. According to their results, five nurses, without any prior knowledge of mucosal crypt patterns, could achieve a diagnostic accuracy of up to 85.4% in distinguishing non-neoplastic polyps from neoplastic polyps after hearing short lectures on pit pattern diagnosis. Furthermore, a foreign doctor without prior knowledge of pit patterns required 3 mo of training at our hospital to reach a differential diagnostic ability more than 90%, similar to that of well-trained endoscopists at our hospital^[29]. Togashi *et al* have suggested that experience with approximately 200 lesions is needed to learn to correctly diagnose polyps with magnifying colonoscopy^[19]. Endoscopic diagnosis based on a conventional view or chromoendoscopy is subjective and unreliable, as it depends on estimations of the size, shape, overlying mucus, and color of the lesions. However, pit patterns are more objective^[14-15]. A further well-designed prospective study to investigate the learning curve for endoscopic diagnosis with magnifying colonoscopy compared to that with conventional colonoscopy or with chromoendoscopy is necessary to clarify this issue.

In conclusion, magnification with chromoendoscopy is a reliable tool for predicting histology, especially for

differentiation of non-neoplastic and neoplastic lesions. This method could be used as a non-biopsy technique at colonoscopy to limit the need for biopsy or resection, and thus reduce complications, time, and resources required. If possible, an international collaborative prospective study including colonoscopists of eastern and western countries would be desirable for further confirmation of its efficacy.

REFERENCES

- 1 Morson B. President's address. The polyp-cancer sequence in the large bowel. *Proc R Soc Med* 1974; **67**: 451-457
- 2 Winawer SJ, Zauber AG, Ho MN, O'Brien MJ, Gottlieb LS, Sternberg SS, Waye JD, Schapiro M, Bond JH, Panish JF. Prevention of colorectal cancer by colonoscopic polypectomy. The National Polyp Study Workgroup. *N Engl J Med* 1993; **329**: 1977-1981
- 3 Kato S, Fujii T, Koba I, Sano Y, Fu KI, Parra-Blanco A, Tajiri H, Yoshida S, Rembacken B. Assessment of colorectal lesions using magnifying colonoscopy and mucosal dye spraying: can significant lesions be distinguished? *Endoscopy* 2001; **33**: 306-310
- 4 Kudo S, Hirota S, Nakajima T, Hosobe S, Kusaka H, Kobayashi T, Himori M, Yagyuu A. Colorectal tumours and pit pattern. *J Clin Pathol* 1994; **47**: 880-885
- 5 Kudo S, Tamura S, Nakajima T, Yamano H, Kusaka H, Watanabe H. Diagnosis of colorectal tumorous lesions by magnifying endoscopy. *Gastrointest Endosc* 1996; **44**: 8-14
- 6 Kudo S, Rubio CA, Teixeira CR, Kashida H, Kogure E. Pit pattern in colorectal neoplasia: endoscopic magnifying view. *Endoscopy* 2001; **33**: 367-373
- 7 General rules for clinical and pathological studies on cancer of the colon, rectum and anus. Part I. Clinical classification. Japanese Research Society for Cancer of the Colon and Rectum. *Jpn J Surg* 1983; **13**: 557-573
- 8 Weston AP, Campbell DR. Diminutive colonic polyps: histopathology, spatial distribution, concomitant significant lesions, and treatment complications. *Am J Gastroenterol* 1995; **90**: 24-28
- 9 Granqvist S, Gabrielsson N, Sundelin P. Diminutive colonic polyps--clinical significance and management. *Endoscopy* 1979; **11**: 36-42
- 10 Tedesco FJ, Hendrix JC, Pickens CA, Brady PG, Mills LR. Diminutive polyps: histopathology, spatial distribution, and clinical significance. *Gastrointest Endosc* 1982; **28**: 1-5
- 11 Feczko PJ, Bernstein MA, Halpert RD, Ackerman LV. Small colonic polyps: a reappraisal of their significance. *Radiology* 1984; **152**: 301-303
- 12 Waye JD, Lewis BS, Frankel A, Geller SA. Small colon polyps. *Am J Gastroenterol* 1988; **83**: 120-122
- 13 Davila RE, Rajan E, Adler D, Hirota WK, Jacobson BC, Leighton JA, Qureshi W, Zuckerman MJ, Fanelli R, Hambrick D, Baron TH, Faigel DO. ASGE guideline: the role of endoscopy in the diagnosis, staging, and management of colorectal cancer. *Gastrointest Endosc* 2005; **61**: 1-7
- 14 Neale AV, Demers RY, Budev H, Scott RO. Physician accuracy in diagnosing colorectal polyps. *Dis Colon Rectum* 1987; **30**: 247-250
- 15 Chapuis PH, Dent OF, Goulston KJ. Clinical accuracy in the diagnosis of small polyps using the flexible fiberoptic sigmoidoscope. *Dis Colon Rectum* 1982; **25**: 669-672
- 16 Eisen GM, Kim CY, Fleischer DE, Kozarek RA, Carr-Locke DL, Li TC, Gostout CJ, Heller SJ, Montgomery EA, Al-Kawas FH, Lewis JH, Benjamin SB. High-resolution chromoendoscopy for classifying colonic polyps: a multicenter study. *Gastrointest Endosc* 2002; **55**: 687-694
- 17 Kiesslich R, von Bergh M, Hahn M, Hermann G, Jung M. Chromoendoscopy with indigocarmine improves the detection of adenomatous and nonadenomatous lesions in the colon. *Endoscopy* 2001; **33**: 1001-1006
- 18 Axelrad AM, Fleischer DE, Geller AJ, Nguyen CC, Lewis

- JH, Al-Kawas FH, Avigan MI, Montgomery EA, Benjamin SB. High-resolution chromoendoscopy for the diagnosis of diminutive colon polyps: implications for colon cancer screening. *Gastroenterology* 1996; **110**: 1253-1258
- 19 **Togashi K**, Konishi F, Ishizuka T, Sato T, Senba S, Kanazawa K. Efficacy of magnifying endoscopy in the differential diagnosis of neoplastic and non-neoplastic polyps of the large bowel. *Dis Colon Rectum* 1999; **42**: 1602-1608
- 20 **Tung SY**, Wu CS, Su MY. Magnifying colonoscopy in differentiating neoplastic from nonneoplastic colorectal lesions. *Am J Gastroenterol* 2001; **96**: 2628-2632
- 21 **Liu HH**, Kudo SE, Juch JP. Pit pattern analysis by magnifying chromoendoscopy for the diagnosis of colorectal polyps. *J Formos Med Assoc* 2003; **102**: 178-182
- 22 **Konishi K**, Kaneko K, Kurahashi T, Yamamoto T, Kushima M, Kanda A, Tajiri H, Mitamura K. A comparison of magnifying and nonmagnifying colonoscopy for diagnosis of colorectal polyps: A prospective study. *Gastrointest Endosc* 2003; **57**: 48-53
- 23 **Hurlstone DP**, Cross SS, Adam I, Shorthouse AJ, Brown S, Sanders DS, Lobo AJ. Efficacy of high magnification chromoscopic colonoscopy for the diagnosis of neoplasia in flat and depressed lesions of the colorectum: a prospective analysis. *Gut* 2004; **53**: 284-290
- 24 **Fu KI**, **Sano Y**, Kato S, Fujii T, Nagashima F, Yoshino T, Okuno T, Yoshida S, Fujimori T. Chromoendoscopy using indigo carmine dye spraying with magnifying observation is the most reliable method for differential diagnosis between non-neoplastic and neoplastic colorectal lesions: a prospective study. *Endoscopy* 2004; **36**: 1089-1093
- 25 **Fujii T**, Hasegawa RT, Saitoh Y, Fleischer D, Saito Y, Sano Y, Kato S. Chromoscopy during colonoscopy. *Endoscopy* 2001; **33**: 1036-1041
- 26 **Waye JD**, Ganc AJ, Khelifa HB, Kotrilik J, Kumar A, Ogoshi K, Roig GV. Chromoscopy and zoom colonoscopy. *Gastrointest Endosc* 2002; **55**: 765-766
- 27 **Takahisa M**, Saito Y, Kozu T, Saito D. Cost-effectiveness of Magnifying and Conventional Colonoscopy. *Gastrointest Endosc* 2004; **59**: pAB275
- 28 **Kobayashi N**, Matsuda T, Saito Y. Is pit pattern diagnosis possible even for beginners? *Gastrointest. Endosc* 2004; **59**: pAB123
- 29 **Sano Y**, Saito Y, Fu KI, Matsuda T, Uraoka T, Kobayashi N, Ito H, Machida H, Iwasaki J, Emura F, Hanafusa H, Yoshino T, Kato S, Fujii T. Efficacy of Magnifying Chromoendoscopy for the Differential Diagnosis of Colorectal Lesions. *Digestive Endoscopy* 2005; **17**: 105-116

S- Editor Wang J L- Editor Zhang JZ E- Editor Ma WH