

# Clinicopathological study of solid and pseudopapillary tumor of pancreas: Emphasis on magnetic resonance imaging findings

Chi-Chang Yu, Jeng-Hwei Tseng, Chun-Nan Yeh, Tsann-Long Hwang, Yi-Yin Jan

Chi-Chang Yu, Chun-Nan Yeh, Tsann-Long Hwang, Yi-Yin Jan, Department of Surgery, Chang Gung Memorial Hospital, Chang Gung University, Kwei-shan, Taoyuan, Taiwan, China  
Jeng-Hwei Tseng, Department of Radiology, Chang Gung Memorial Hospital, Chang Gung University, Kwei-shan, Taoyuan, Taiwan, China

Correspondence to: Chun-Nan Yeh, MD, Department of Surgery, Chang Gung Memorial Hospital, Chang Gung University, 5, Fu-hsing Street, Kwei-shan, Taoyuan, Taiwan, China. ycn@adm.cgmh.org.tw

Telephone: +886-3-3285818

Received: 2007-01-09

Accepted: 2007-01-25

findings. *World J Gastroenterol* 2007; 13(12): 1811-1815

<http://www.wjgnet.com/1007-9327/13/1811.asp>

## Abstract

**AIM:** To report the clinicopathological features and magnetic resonance imaging (MRI) findings of solid and pseudopapillary tumor (SPT) of pancreas.

**METHODS:** From 1981 to 2005, 26 surgically treated cases of SPT were retrospectively reviewed. MRI findings of the latest 11 consecutive SPT cases were investigated.

**RESULTS:** There were 25 women and one man having SPT (median age: 23 year) with a median tumor size of 7.5 cm. Among them, nine patients developed solid pseudopapillary carcinoma. During the median follow-up period of 66 mo, the 5-year survival rate of the 26 SPT patients was 96.2%. Three MRI features were proposed including Type 1 image, displaying SPT with completely solid part. All SPT patients with type 1 image were detected incidentally. Type 2 image displays of SPT with solid mass hemorrhage and type 3 image with massive hemorrhage. All the eight SPT patients with type 2 and 3 images suffered abdominal pain due to hemorrhage from SPT.

**CONCLUSION:** SPT had a favorable survival rate irrespective of surgical procedures, malignancy, and MRI findings, however, MRI could reliably correlate with its clinicopathological features.

© 2007 The WJG Press. All rights reserved.

**Key words:** Solid and pseudopapillary tumor; Pancreas; Magnetic resonance imaging

Yu CC, Tseng JH, Yeh CN, Hwang TL, Jan YY. Clinicopathological study of solid and pseudopapillary tumor of pancreas: Emphasis on magnetic resonance imaging

## INTRODUCTION

Solid and pseudopapillary tumor (SPT) of pancreas is a rare disease entity, occurring mainly in young women<sup>[1-4]</sup>. The pathologic features of SPT are well characterized<sup>[1,2,5]</sup>. Since 1959, over 500 cases of SPT of the pancreas have been reported in literature<sup>[3,6]</sup>. According to the World Health Organization's (WHO) classification, it is designated as tumors of the exocrine pancreas<sup>[1]</sup>. It is also well known for its indolent biologic behavior. Despite its low malignant potential, proximately 15% of patients with SPT develop metastatic disease, most involving the liver or peritoneum<sup>[2]</sup>. Even in the presence of disseminated disease, the clinical course is usually favorable<sup>[1-3]</sup>.

With recent advances in diagnostic modalities, including ultrasonography (US), computed tomography (CT), magnetic resonance imaging (MRI), and fine-needle aspiration biopsy (FNAB), the tumor was more frequently reported<sup>[1,3,7,8]</sup>. CT may help to differentiate between SPTs and pancreatic cystic neoplasm, whereas MRI may help to differentiate those from islet cell tumors<sup>[7]</sup>.

Here, we reviewed 26 cases of SPT treated at Chang Gung Memorial Hospital from 1981 to 2005 with respect of clinicopathological, radiological, operative findings, and outcomes. With emphasis on MRI findings, we proposed three specific MRI features to correlate this rare disease entity with its clinicopathological features more precisely.

## MATERIALS AND METHODS

### Subject

From 1981 to 2005, 26 consecutive patients with SPT of the pancreas underwent surgical treatment at the Department of Surgery, Chang Gung Memorial Hospital, Taipei, Taiwan. Six of these 26 patients had been reported previously<sup>[9]</sup>. 20 new patients with SPT were included in this study.

### Evaluation

Preoperative evaluation of SPT included history taking physical examinations, routine laboratory examinations, ultrasonography (US), endoscopic ultrasonography (EUS),

**Table 1 Clinicopathological features of 26 SPT patients underwent surgical treatment**

	<i>n</i>	(%)
Gender		
Male	1	3.8
Female	25	96.2
Symptom		
No symptom	5	19.2
Abdominal pain	10	38.5
Abdominal palpable mass	5	19.2
Jaundice	2	7.7
Epigastralgia	4	15.4
Tumor marker		
CEA < 5 (μg/L)	26	100
CA 19-9 < 37 (kU/L)	26	100
Tumor location		
Head	11	42.3
Body	3	11.6
Tail	6	23.1
neck and body	1	3.8
body and tail	5	19.2
Resectability		
Resectable	24	92.3
Unresectable	2	7.7
Operation method		
Whipple's operation	8	30.8
Partial pancreatectomy	3	11.6
Distal pancreatectomy	7	26.9
Enucleation of the pancreatic tumor	6	23.1
Bypass surgery	1	3.8
Biopsy only	1	3.8
Tumor behavior		
Solid-pseudopapillary neoplasm	17	56.4
Solid-pseudopapillary carcinoma	9	34.6

abdominal computed tomography (CT), and magnetic resonance imaging (MRI). The imaging features of the latest 11 consecutive SPT cases underwent MRI study by one of the authors (Tseng JH) (Magnetom Vision; Siemens Erlangen, Germany; projection technique and multislice plus maximum intensity projection) were studied. Of the 26 SPT patients discharged from the hospital after surgical treatment, all of the patients were closely followed up at regular intervals until death or until the time of this manuscript writing.

### Statistical analysis

Survival was calculated and plotted using the Kaplan-Meier method from the time of surgical treatment until the writing of this manuscript. All statistical analyses were performed utilizing the SPSS computer software (Version 12.0, Chicago, IL, USA).

## RESULTS

### Demographic, clinicopathological features, and outcomes

Table 1 summarizes the clinicopathological features of the 26 SPT patients. There were 25 females and 1 male ranging in ages from 13 to 57 (median/mean, 23.0/25.2) yrs. Abdominal pain comprises the most common symptom for SPT (38.5%). Five (19.2%) of the 26 SPT patients were detected incidentally during physical check-up. Two of 26 SPT patients developed jaundice (7.7%). The size of SPT ranged from 3.8 to 15.0 (median, 7.5) cm. All known tumor markers including CEA and CA 19-9 are

within normal limit, irrespective of malignancy. Pancreatic head is the most frequent location of tumor (Table 1). Two of the 26 SPT patients developed into unresectable status due to multiple liver metastasis and carcinomatosis. Among 26 SPT patients, nine patients were classified as solid pseudopapillary carcinoma by the World Health Organization's (WHO) classification (Table 2). Four of nine solid pseudopapillary carcinoma developed duodenal invasions, while the other three developed portal vein invasions. The duration of follow-up ranged from 10.1 to 236.8 mo (median, 66.0) mo. During the follow-up period, 2 patients of 9 malignant SPT (22.2%) had distant metastasis of SPT after surgical treatment. Two of the 26 patients died of causes unrelated to the tumor or surgical procedure. One underwent Whipple's operation and died of hepatic encephalopathy after a grand mal seizure. The other one underwent bypass surgery and died of hepatic failure due to hepatitis exacerbation. All the other cases have survived until now, whether cases were benign or malignancy. The five-year survival rate of the 26 SPT patients was 96.2%.

### MRI imaging features

Table 3 summarized the MRI features. MRI was used in eleven SPT patients with three specific features correlating well with pathological features. MRI had three specific features correlating well with pathological features. Three patients had type 1 image and all the three patients had incidentally found SPT.

Type 1 image means SPT with completely solid part. T1W1 image revealed homogenously hypointense and slightly hyperintense than pancreas parenchyma on T2W1 image. Strong and rapid enhancement and gradually fading pattern could be observed (Figure 1).

Type 2 image means SPT with solid mass with hemorrhage. T1W1 image revealed hypointense with heterogeneously hyperintense area. The hyperintense areas on T1W1 appeared slightly hyperintense on T2W1 image meaning hemorrhage while enhancement of capsule and gradual enhancement of solid part (Figure 2).

Type 3 image means SPT with massive hemorrhage. T1W1 revealed mainly hyperintense with intermediate and hypointense areas. The hyperintense areas on T1W1 image appeared slightly hyperintense on T2W1 image. Only capsular enhancement could be detected (Figure 3). All the eight SPT patients with type 2 and 3 images suffered abdominal pain due to hemorrhage from SPT.

## DISCUSSION

As shown in our results, solid pseudopapillary tumor (SPT) of pancreas predominated in adolescent girls and young women (median/mean: 23.0/25.2 years; rang 13-57 years) and is uncommon in men (1/26; 3.8%). Although SPT of pancreas is uncommon, it has been recognized with increasing frequency in recent years, accounting for approximately 1%-2% of all exocrine pancreatic tumors<sup>[1,3]</sup>. Although literature showed no preferential localization within the pancreas, the head of pancreas is the preferential site of the occurrence of SPT in this study with an incidence rate of 42.3%<sup>[1]</sup>. The etiology

Table 2 Clinicopathological features of 9 solid pseudopapillary carcinoma patients

No.	Age (yr)/ Sex	Tumor location	Extension	Vascular invasion	Operation method	Metastasis	Metastasis (mo)	Status	Follow-up (mo)
1	36/F	Head	Duodenal wall	-	Whipple's operation	-	-	Alive	70
2 <sup>1</sup>	34/F	Tail	-	-	Distal pancreatectomy	-	-	Alive	12
3	39/F	Head	-	-	Whipple's operation	Liver	39	Alive	58
4	22/F	Neck, body	-	PV	Partial pancreatectomy,	-	-	Alive	202
5	18/F	Head	Duodenal wall	-	Whipple's operation	-	-	Alive	145
6	16/F	Head	Duodenal wall	-	Whipple's operation	-	-	Alive	56
7	20/F	Body, tail	Extrapancreatic	-	Biopsy only	Liver, omentum Peritoneum Pelvic wall	0	Alive	75
8	28/F	Head	-	PV	Whipple's operation	-	-	DOC	66
9	19/F	Head	-	PV, SMA	Roux-en-Y cystojejunostomy	-	-	DOC	83

<sup>1</sup>means perineural invasion and angioinvasion; PV: Portal vein; SMA: Superior mesenteric artery; DOC: Die of other cause.

Table 3 MRI features of 11 SPT patients

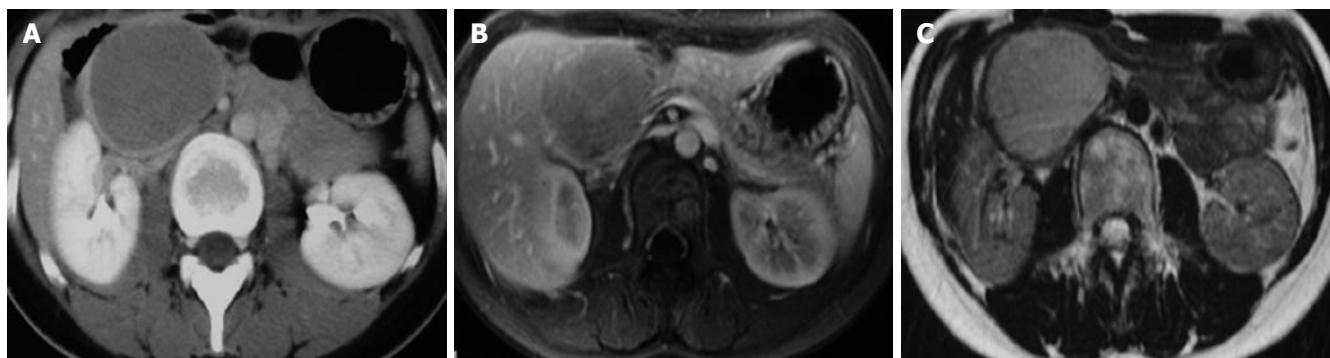
No.	Type of image	Presentation	Age	G	Size (cm)	Location	T1WI	Enhancement	T2WI	H
1	I	RUQ mass, incidentally noted	28	F	3.5	Tail	Hypointense homogenously	Gradual enhancement of solid component	Hypointense homogenously	(-)
2	I	GI upset, incidentally noted	22	F	7.5	Body and tail	Hypointense homogenously	Gradual enhancement of solid component	Hypointense homogenously	(-)
3	I	RUQ mass, incidentally noted	22	F	6	Head	Hypointense homogenously	Gradual enhancement of solid component	Mild hyperintense	(-)
4	II	Abdominal pain	14	F	5	Body	Hyperintense heterogeneously	Heterogenous	Hyperintense (hyperintense areas on T1WI)	(+)
5	II	Abdominal pain	29	F	5	Head	Hyperintense heterogeneously	Heterogenous	Hyperintense (hyperintense areas on T1WI)	(+)
6	II	Abdominal pain	33	F	11	Tail	Hyperintense heterogeneously	Heterogenous	Hyperintense (hyperintense areas on T1WI)	(+)
7	II	Abdominal pain	29	F	7	Head	Hyperintense heterogeneously	Heterogenous	Hyperintense (hyperintense areas on T1WI)	(+)
8	II	Abdominal pain	23	F	7.6	Head	Hyperintense heterogeneously	Heterogenous	Hyperintense (hyperintense areas on T1WI)	(+)
9	III	Abdominal pain	27	F	6	Tail	Hypo and hyperintense homogenously	Capsular enhancement, Gradual enhancement of solid compnent	Hyperintense (hyperintense areas on T1WI)	(+)
10	III	Abdominal pain	36	F	7	Head	Hyperintense heterogeneously	Heterogenous	Hyperintense (hyperintense areas on T1WI)	(+)
11	III	Abdominal pain	16	F	5	Head	Hyperintense heterogeneously	Heterogenous	Hyperintense (hyperintense areas on T1WI)	(+)

I : Completely solid; II : Typical; III : Massive hemorrhage; GI: Gastrointestinal; H: Hemorrhage.

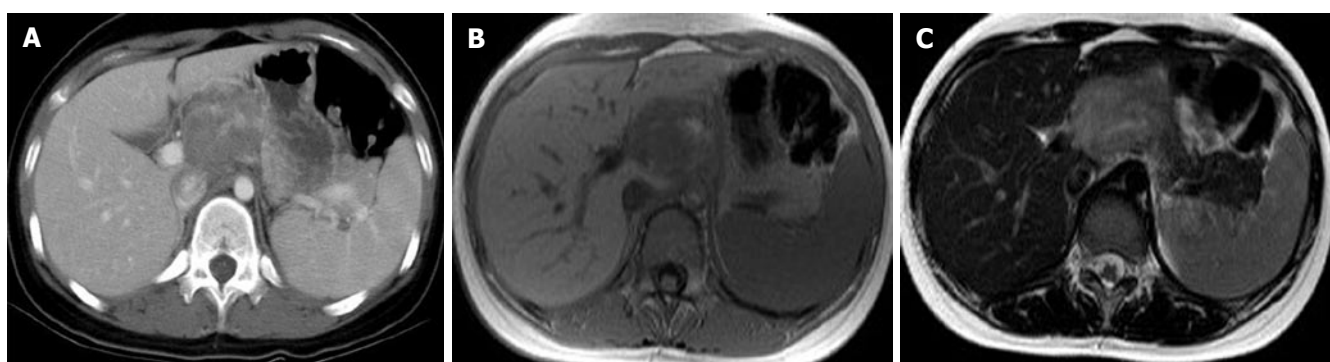
and pathogenesis of SPT is unknown<sup>[1,3,6]</sup>. Very few women developed a SPT after long-term use of hormone contraceptives<sup>[1]</sup>. The striking sex and age distribution point to genetic and hormonal factors and our previous report indicated an association with endocrine disturbances including overproduction of progesterone<sup>[1,6]</sup>. Usually, the neoplasm caused abdominal discomfort and pain (10/26; 38.5%) or they were found incidentally on routine physical examination (5/26; 19.2%). As shown in this

study, jaundice is rare, even in tumor that originated from the head of the pancreas, and there is no association with endocrine function. All known tumor markers including CEA and CA 19-9 are within normal limit, irrespective of malignancy.

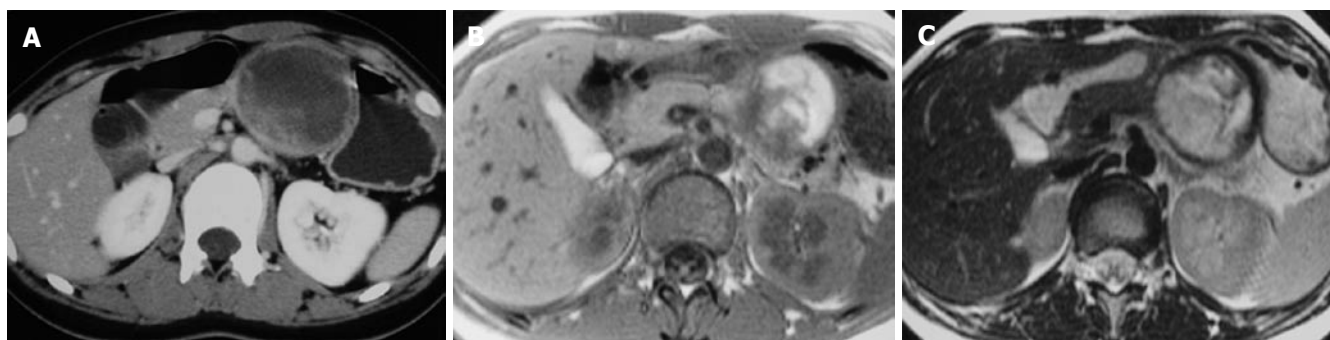
Regarding the role of endoscopic ultrasound (EUS) in evaluation of SPTs, Lee proposed that the characteristic sonographic findings of solid and papillary epithelia neoplasm were well-encapsulated, cystic and solid masses,



**Figure 1** Completely solid pattern. **A:** Abdominal CT with contrast showed a well-defined homogeneous soft tissue mass at the pancreatic head; **B:** T1-weighted MR image with Gd-DTPA enhancement revealed a pancreatic head tumor containing homogenous low-signal-intensity with compression the confluence of splenic vein; **C:** T2-weighted MR image revealed a well-defined pancreatic head tumor containing slightly high-signal-intensity than pancreas parenchyma.



**Figure 2** Typical pattern. **A:** Abdominal CT with contrast showed a well-defined heterogenous mass in the pancreatic head with part of hyperdensity; **B:** T1-weighted MR image demonstrates a pancreatic head mass with low-signal-intensity and heterogeneously high-signal-intensity area; **C:** T2-weighted MR image demonstrates a heterogenous hyperintense mass in the pancreatic head with foci hypointensities, high signal intensity means hemorrhage.



**Figure 3** Massive hemorrhage pattern. **A:** Abdominal CT with contrast revealed a well-defined pancreatic body tumor containing heterogenous attenuation; **B:** T1-weighted MR image revealed a pancreatic body tumor containing revealed mainly high-signal-intensity with intermediate- and low-signal intensity area and irregular septation; **C:** T2-weighted MR image demonstrates a well-defined heterogenous slightly hyperintense mass with foci hypointense part. The high-signal-intensity area on T1W1 image appeared slightly hyperintense on T2 weighted MR image.

but sometimes the mass was seen as a pure solid-looking mass or had internal septations or calcification<sup>[10]</sup>. Fine-needle aspiration (FNA) may have played an important role in preoperative planning by helping distinguish SPTs from other pancreatic lesions with a significantly different prognosis and treatment<sup>[11]</sup>. EUS-FNA represents a diagnostic technique commonly used in adults that may be useful in identifying the rare pediatric patient with pancreatic malignancy<sup>[12]</sup>. Thus, accurate diagnosis of the

special type of pancreatic tumor is obviously important. Fine-needle aspiration biopsy and cytologic analysis or excisional biopsy and histologic analysis are sometimes needed for definitive diagnosis.

Regarding radiological study, CT may help to differentiate SPT from other cystic neoplasm whereas MRI may help to differentiate SPT from islet cell tumors<sup>[7]</sup>. Regarding radiological features of SPT, MRI revealed an encapsulated mass lesion with solid and cystic component



as well as hemorrhage without obvious internal septation should arouse the suspicion of SPT of pancreas, especially in a young female patient. As shown in this study, MRI may be superior to CT in terms of correlation between radiological and clinicopathological findings of SPT. Furthermore, in the setting of renal insufficiency or dye allergy when contrast is contraindicated, MRI had an advantage when compared with CT. We specifically proposed three MRI features to correlate well with clinicopathological features. Type 1 image means SPT with completely solid part. T1W1 image revealed homogeneously hypointense and slightly hyperintense than pancreas parenchyma on T2W1 image. Strong and rapid enhancement and gradually fading pattern could be observed. Type 2 image means SPT with solid mass with hemorrhage. T1W1 image revealed hypointense with heterogeneously hyperintense area. The hyperintense areas on T1W1 appeared slightly hyperintense on T2W1 image, meaning hemorrhage, while enhancement of capsule and gradual enhancement of solid part. Type 3 image means SPT with massive hemorrhage. T1W1 revealed mainly hyperintense with intermediate and hypointense areas. The hyperintense areas on T1W1 image appeared slightly hyperintense on T2W1 image. Only capsular enhancement could be detected.

As shown in this study, a few SPT could be found to be attached to the pancreas or even an extrapancreatic locations. Invasion of the adjacent organs or the portal vein is not uncommon. As shown in this series, few metastasizing SPTs (2/26; 7.6%) developed. Common metastatic sites are regional lymph nodes, the liver, peritoneum, and greater omentum.

Regarding prognosis, Nishihara reported SPT must be classified as lesions of uncertain malignant potential due to varying histological features<sup>[13]</sup>. As shown in this study, enucleation and partial pancreatectomy is as good as distal pancreatectomy, although surgical oncologic principles are not followed in the former. Based on the clinical follow up, there does not appear to be any difference in survival based on resection techniques. So we suggest that SPT is indolent and surgery for SPT should induce minimal functional deficit. Furthermore, the prognosis is good with 96.4% 5-year survival rate for 26 SPTs. After complete removal of SPT, more than 95% of the patients with SPT are cured. Local spread or dissemination to the peritoneal cavity has been reported due to abdominal trauma and rupture of the tumor. Even in patients who had local spread, recurrent or metastases, long disease-free survival

has been recorded after initial diagnosis and resection. Only a few patients have died of metastasizing SPTs.

In conclusion, we present the clinical features and outcomes of 26 SPT patients with emphasis on MRI findings. SPT had a favorable survival irrespective of surgical procedures, malignancy, and MRI pictures. MRI could reliably correlate with its clinicopathological features with specific imaging features.

## REFERENCES

- 1 Klöppel G, Lüttges J, Klimstra DS, Hruban R, Kern S, Adler G. Solid-pseudopapillary neoplasm. In: Hamilton SR, Aaltonen LA, editors. World Health Organization classification of tumours: pathology and genetics of tumours of the digestive system. Lyon: IARC Press, 2000: 246-248
- 2 Tang LH, Aydin H, Brennan MF, Klimstra DS. Clinically aggressive solid pseudopapillary tumors of the pancreas: a report of two cases with components of undifferentiated carcinoma and a comparative clinicopathologic analysis of 34 conventional cases. *Am J Surg Pathol* 2005; **29**: 512-519
- 3 Martin RC, Klimstra DS, Brennan MF, Conlon KC. Solid-pseudopapillary tumor of the pancreas: a surgical enigma? *Ann Surg Oncol* 2002; **9**: 35-40
- 4 Raffel A, Cupisti K, Krausch M, Braunstein S, Tröbs B, Goretzki PE, Willnow U. Therapeutic strategy of papillary cystic and solid neoplasm (PCSN): a rare non-endocrine tumor of the pancreas in children. *Surg Oncol* 2004; **13**: 1-6
- 5 Washington K. Solid-pseudopapillary tumor of the pancreas: challenges presented by an unusual pancreatic neoplasm. *Ann Surg Oncol* 2002; **9**: 3-4
- 6 Lam KY, Lo CY, Fan ST. Pancreatic solid-cystic-papillary tumor: clinicopathologic features in eight patients from Hong Kong and review of the literature. *World J Surg* 1999; **23**: 1045-1050
- 7 Coleman KM, Doherty MC, Bigler SA. Solid-pseudopapillary tumor of the pancreas. *Radiographics* 2003; **23**: 1644-1648
- 8 Lee YR, Kim Y, Koh BH, Cho OK, Rhim H, Park DW, Park HK. Solid and papillary epithelial neoplasm of the pancreas with peritoneal metastasis and its recurrence: a case report. *Abdom Imaging* 2003; **28**: 96-98
- 9 Jeng LB, Chen MF, Tang RP. Solid and papillary neoplasm of the pancreas. Emphasis on surgical treatment. *Arch Surg* 1993; **128**: 433-436
- 10 Lee DH, Yi BH, Lim JW, Ko YT. Sonographic findings of solid and papillary epithelial neoplasm of the pancreas. *J Ultrasound Med* 2001; **20**: 1229-1232
- 11 Buchino JJ. Fine-needle aspiration of solid and papillary cystic tumor of the pancreas. *Pediatr Pathol Lab Med* 1996; **16**: 235-242
- 12 Nadler EP, Novikov A, Landzberg BR, Pochapin MB, Centeno B, Fahey TJ, Spigland N. The use of endoscopic ultrasound in the diagnosis of solid pseudopapillary tumors of the pancreas in children. *J Pediatr Surg* 2002; **37**: 1370-1373
- 13 Nishihara K, Nagoshi M, Tsuneyoshi M, Yamaguchi K, Hayashi I. Papillary cystic tumors of the pancreas. Assessment of their malignant potential. *Cancer* 1993; **71**: 82-92

S- Editor Wang J L- Editor Li M E- Editor Zhou T