

Clinical implications of accessory pancreatic duct

Terumi Kamisawa, Kensuke Takuma, Taku Tabata, Naoto Egawa

Terumi Kamisawa, Kensuke Takuma, Taku Tabata, Naoto Egawa, Department of Internal Medicine, Tokyo Metropolitan Komagome Hospital, 3-18-22 Honkomagome, Bunkyo-ku, Tokyo 113-8677, Japan

Author contributions: Kamisawa T analyzed data and wrote the paper; Takuma K, Tabata T and Egawa N performed research.

Correspondence to: Terumi Kamisawa, MD, PhD, Director of Gastroenterology, Department of Internal Medicine, Tokyo Metropolitan Komagome Hospital, 3-18-22 Honkomagome, Bunkyo-ku, Tokyo 113-8677, Japan. kamisawa@cick.jp

Telephone: +81-3-38232101 Fax: +81-3-38241552

Received: February 25, 2010 Revised: April 1, 2010

Accepted: April 8, 2010

Published online: September 28, 2010

Abstract

The accessory pancreatic duct (APD) is the main drainage duct of the dorsal pancreatic bud in the embryo, entering the duodenum at the minor duodenal papilla (MIP). With the growth, the duct of the dorsal bud undergoes varying degrees of atrophy at the duodenal end. Patency of the APD in 291 control cases was 43% as determined by dye-injection endoscopic retrograde pancreatography. Patency of the APD in 46 patients with acute pancreatitis was only 17%, which was significantly lower than in control cases ($P < 0.01$). The terminal shape of the APD was correlated with APD patency. Based on the data about correlation between the terminal shape of the APD and its patency, the estimated APD patency in 167 patients with acute pancreatitis was 21%, which was significantly lower than in control cases ($P < 0.01$). A patent APD may function as a second drainage system for the main pancreatic duct to reduce the pressure in the main pancreatic duct and prevent acute pancreatitis. Pancreatographic findings of 91 patients with pancreaticobiliary maljunction (PBM) were divided into a normal duct group (80 patients) and a dorsal pancreatic duct (DPD) dominant group (11 patients). While 48 patients (60%) with biliary carcinoma (gallbladder carcinoma, $n = 42$; bile duct carcinoma, $n = 6$) were identified in PBM with a normal pancreatic duct system, only two cases of gallbladder carcinoma

(18%) occurred in DPD-dominant patients ($P < 0.05$). Concentration of amylase in the bile of DPD dominance was significantly lower than that of normal pancreatic duct system (75403.5 ± 82015.4 IU/L vs 278157.0 ± 207395.0 IU/L, $P < 0.05$). In PBM with DPD dominance, most pancreatic juice in the upper DPD is drained into the duodenum *via* the MIP, and reflux of pancreatic juice to the biliary tract might be reduced, resulting in less frequency of associated biliary carcinoma.

© 2010 Baishideng. All rights reserved.

Key words: Accessory pancreatic duct; Minor duodenal papilla; Pancreas divisum; Main pancreatic duct; Acute pancreatitis; Pancreaticobiliary maljunction

Peer reviewers: Oscar Joe Hines, MD, FACS, Professor, Director, Surgery Residency Program, Department of Surgery, UCLA School of Medicine, 10833 Le Conte Ave, Los Angeles, CA 90095-6904, United States; Naoaki Sakata, MD, PhD, Division of Hepato-Biliary Pancreatic Surgery, Tohoku University Graduate School of Medicine, 1-1 Seiryomachi, Aoba-ku, Sendai, Miyagi 980-8574, Japan; Yoshiaki Murakami, MD, Department of Surgery, Division of Clinical Medical Science, Graduate School of Biomedical Science, Hiroshima University, 1-2-3 Kasumi, Minami-ku, Hiroshima 734-8551, Japan

Kamisawa T, Takuma K, Tabata T, Egawa N. Clinical implications of accessory pancreatic duct. *World J Gastroenterol* 2010; 16(36): 4499-4503 Available from: URL: <http://www.wjgnet.com/1007-9327/full/v16/i36/4499.htm> DOI: <http://dx.doi.org/10.3748/wjg.v16.i36.4499>

INTRODUCTION

The human pancreas develops embryologically from fusion of the dorsal and ventral pancreatic buds. The dorsal pancreatic bud gives rise to the anterior part of the head of the pancreas, in addition to the body and tail, while the ventral pancreatic bud develops into the posterior part of the head of the gland. Fusion of the pancreatic buds is accompanied by anastomosis of the

ducts. The main drainage duct of the ventral pancreatic bud communicates with the main duct of the dorsal pancreatic bud, with the point of union lying between the isthmus and head of the pancreas. This becomes the dominant and more constant pancreatic duct [main pancreatic duct (MPD)]. The proximal part of the main dorsal pancreatic duct (DPD) partially regresses to form the accessory pancreatic duct (APD, Santorini's duct), which opens into the minor duodenal papilla (MIP)^[1-5].

Pancreas divisum is a common anatomical variation, in which the dorsal and ventral pancreatic ducts do not unite embryologically. In pancreas divisum, the DPD becomes the main duct and drains most of the pancreas through the MIP. As the MIP is substantially smaller than the major duodenal papilla, a larger secretory capacity might presumably place a significant load on the MIP^[6,7]. Although there are controversies regarding the clinical significance of pancreas divisum, correlation between pancreas divisum and pancreatitis has been reported based on the findings such as increased incidence of pancreas divisum in acute idiopathic pancreatitis in endoscopic retrograde cholangiopancreatography (ERCP)^[8,9], isolated dorsal pancreatitis as shown by irregular dilatation apparent on dorsal pancreatography alone^[10], and improvement after endoscopic or surgical procedures that open the MIP^[11-13]. As less than 5% of the population with pancreas divisum develop pancreatic symptoms^[14], interrelationships between poor function of the MIP and increased flow of pancreatic juice caused by alcohol or diet might increase dorsal duct pressure and lead to development of complications^[6]. On the other hand, as cystic fibrosis transmembrane conductance regulator (CFTR) gene mutations are more frequently found in patients with pancreas divisum associated with idiopathic pancreatitis than in those with pancreas divisum without pancreatitis, it is suggested that predisposing factors such as CFTR gene mutation, are necessary to develop pancreatitis in patients with pancreas divisum^[15-17].

Patency of the APD has been assessed by direct injection of material into the pancreatic duct in resected or autopsy specimens^[18-20]. A great deal of difficulty is encountered in determining the percentage of cases in which the MIP is patent. Accordingly, the reported patency of the APD has ranged widely from 12%^[18] to 82%^[19]. Clinical significance of the APD in the typical pancreatic duct system with fusion between the ventral and DPD remains unclear. We have performed endoscopic studies on patency of the APD using dye-injection endoscopic retrograde pancreatography (ERP)^[6,21-23]. In this editorial, we elucidate clinical implications of the APD.

PATENCY OF APD BY DYE-INJECTION ERP

From 1989 to 2002, during routine ERP, 2-3 mL of contrast medium containing a small amount of indigocarmine was injected into the MPD *via* a selectively cannulated endoscopic catheter at the usual pressure. Egress of dye

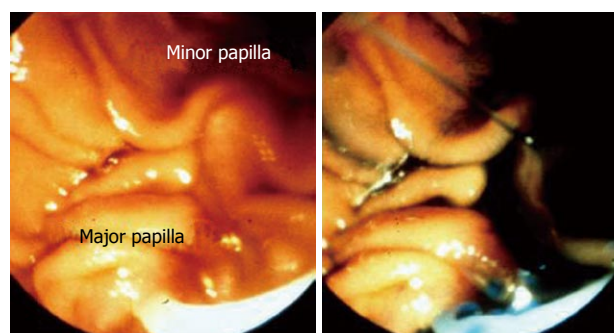


Figure 1 Endoscopic appearance of the major and minor duodenal papilla. In a patient with a patent accessory pancreatic duct, the dye injected into the main pancreatic duct was excreted from the minor duodenal papilla.

Table 1 Relationship between the patency of the accessory pancreatic duct and its terminal shape *n* (%)

Terminal shape of the APD	No. of cases	Patency
Stick	149	71 (48)
Spindle	29	27 (93) ^a
Cudgel	24	21 (88) ^a
Saccular	21	3 (14) ^b
Branch	42	3 (7) ^b

^aSignificantly higher compared with patency of stick-type accessory pancreatic duct (APD); ^bSignificantly lower compared with patency of stick-type APD.

from the MIP observed endoscopically indicates the APD patency. This method can be used endoscopically to determine the patency of the APD (Figure 1)^[6,21-23].

Of the 291 controls with normal pancreatogram in the head of the pancreas who underwent ERCP for suspicion of pancreatobiliary diseases other than acute pancreatitis, 43% had a patent APD. The terminal shape of the APD exhibited several consistent radiological features, which were classified into six types. Stick-type APD showed gradual narrowing of the duct (Figure 2A). In branch-type APD, the duct gradually narrowed and gave off several fine terminal branches (Figure 2B). In spindle-type APD, ampullary termination was seen (Figure 2C), while saccular-type APD displayed saccular termination (Figure 2D). Cudgel-type APD is associated with a duct diameter exceeding 2 mm (Figure 2E). In some cases, APD is halfway or none. The most common is stick type (*n* = 149, 51%), followed by branch type (*n* = 42, 14%), spindle type (*n* = 29, 10%), halfway type or none (*n* = 26, 9%), cudgel type (*n* = 24, 8%), and saccular type (*n* = 21, 7%). The terminal shape of the APD was correlated with APD patency. Stick-type APD was patent in 48% of cases. Patency of the spindle-type APD (93%) and cudgel-type APD (88%) was significantly higher than that of the stick-type APD (*P* < 0.01). Patency of the branch-type APD (7%) and saccular-type APD (14%) was significantly lower than that of the stick-type APD (*P* < 0.01) (Table 1).

In 46 patients with acute pancreatitis, 8 (17%) had a patent APD. Patency of the APD of patients with acute pancreatitis was significantly lower than APD patency

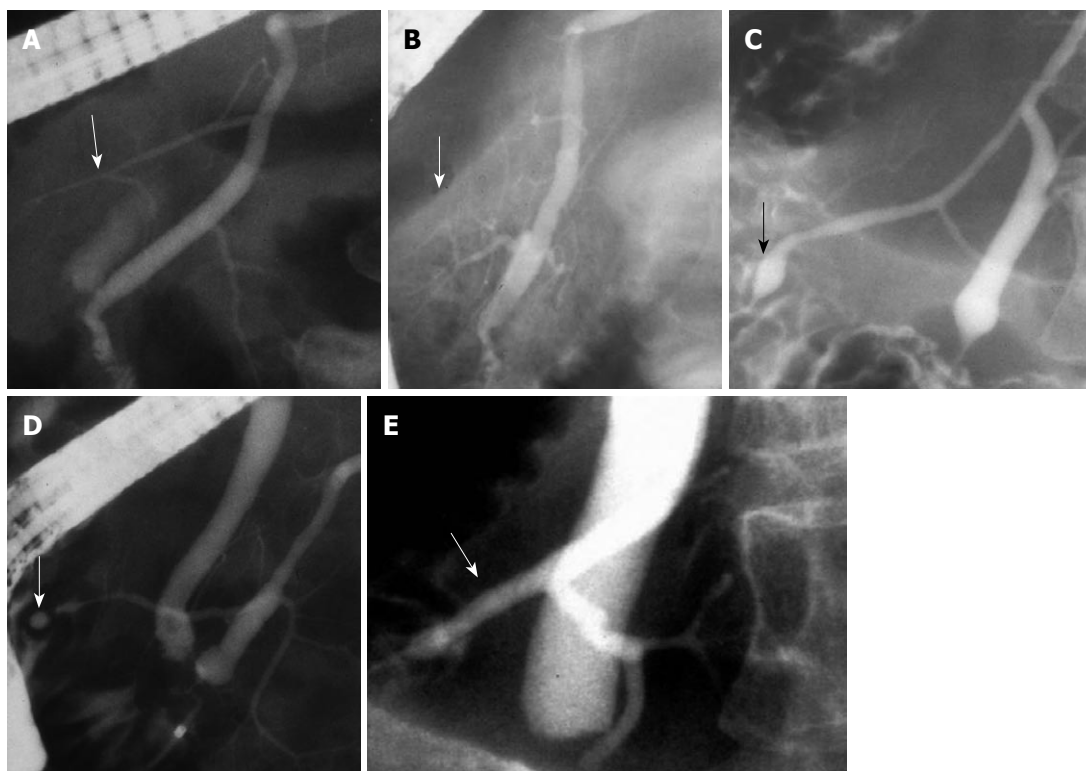


Figure 2 Terminal shape (arrows) of the accessory pancreatic duct. A: Stick type; B: Branch type; C: Spindle type; D: Saccular type; E: Cudgel type.

(43%) of controls ($P < 0.01$). Of the 43 patients with choledocholithiasis, 13 had acute pancreatitis. Patency of the APD in patients with acute biliary pancreatitis was 8%, which was significantly less frequent than in those without acute pancreatitis (43%) ($P < 0.01$).

ANALYSIS OF APD OF PATIENTS WITH ACUTE PANCREATITIS

Pancreatograms of 167 patients with acute pancreatitis, in whom the first side branches in the head were filled, were reviewed. Major etiologies of acute pancreatitis were biliary ($n = 61$), idiopathic ($n = 40$), post-ERCP ($n = 30$), and alcoholic ($n = 24$). The severity of the acute pancreatitis was severe ($n = 13$), moderate ($n = 26$), and mild ($n = 128$).

In respect to the terminal shape of the APD in these 167 patients with acute pancreatitis, stick-type APD ($P < 0.01$), spindle-type APD ($P < 0.01$), and cudgel-type APD ($P < 0.05$) were less frequent, and branch-type APD ($P < 0.01$) and halfway-type or no APD ($P < 0.01$) were more frequent compared with the controls. Based on the underlying data about correlation between the terminal shape of the APD and its patency, the estimated APD patency in 167 patients with acute pancreatitis was 21%, which was significantly lower than that of controls (43%) ($P < 0.01$). APD patency was estimated to be 21% in patients with severe acute pancreatitis, 28% in those with moderate acute pancreatitis, and 20% in those with mild acute pancreatitis.

BILIARY CARCINOMA ASSOCIATED WITH PANCREATICOBILIARY MALJUNCTION SHOWING DORSAL DUCT DOMINANCE

Pancreaticobiliary maljunction (PBM) is a congenital anomaly defined as a union of the pancreatic and biliary ducts that is located outside the duodenal wall. As the action of the sphincter muscle does not functionally affect the union, pancreatic juice frequently refluxes into the bile duct *via* the anomalous junction, resulting in a high incidence of carcinogenesis in the biliary tract^[24-26]. Pancreatographic findings of 91 PBM patients were divided into a normal duct group (80 patients) and a DPD dominant group (11 patients). DPD dominance is defined as cases in which ventral pancreatic duct anastomosis with DPD is narrower than DPD. While 48 patients (60%) with biliary carcinoma (gallbladder carcinoma, $n = 42$; bile duct carcinoma, $n = 6$) were identified in PBM with a normal pancreatic duct system, only two cases of gallbladder carcinoma (18%) occurred in DPD-dominant patients ($P < 0.05$) (Table 2).

Although there was no difference in the diameter of ventral pancreatic duct, the maximum diameter of the Santorini's duct in DPD dominance was significantly larger than that of normal pancreatic duct system (2.5 ± 0.6 mm *vs* 0.9 ± 0.3 mm, $P < 0.01$). The Santorini's duct flew straight from the upstream DPD in DPD dominance. Concentration of amylase in the bile of DPD dominance

Table 2 Relationship between pancreatographic finding and biliary carcinoma in patients with pancreaticobiliary maljunction *n* (%)

Pancreatography	Biliary carcinoma +
Normal (<i>n</i> = 80)	48 (60)
Dorsal pancreatic duct dominant (<i>n</i> = 11)	2 (18)

P < 0.05.

was significantly lower than that of normal pancreatic duct system (75403.5 ± 82015.4 IU/L *vs* 278157.0 ± 207395.0 IU/L, *P* < 0.05).

CLINICAL SIGNIFICANCE OF THE APD

Dye-injection ERP is a simple and definitive method for examining APD patency^[6,21-23]. In the study using dye-injection ERP, the patency of the APD in 46 patients with acute pancreatitis was 17%, which was significantly lower than in controls (43%). Since acute pancreatitis is a reversible disease and ERP was performed after resolution of pancreatitis, it seems less likely that pancreatic inflammation impedes flow of contrast medium through the pancreatic duct. Estimated patency of the APD based on the data by dye-injection ERP was 21% in 167 patients with acute pancreatitis, which was also significantly lower than in controls.

Though the mechanisms that induce acute pancreatitis are different and are not fully clarified, many authors appear to agree that obstruction of the flow of pancreatic juice is of fundamental importance in the occurrence of biliary acute pancreatitis. During impaction of a stone in the major duodenal papilla, pressures of both bile and pancreatic juice flow increase, but if an efficient mechanism for decompressing the pancreatic duct system is available in individuals with a patent APD, it may prevent acute pancreatitis by reducing pressure in the MPD. Nowak *et al.*^[27] reported, in a prospective ERCP study, that APD patency was only found in 17% of 47 patients with acute biliary pancreatitis compared with 69% in a control group. A patent APD may function as a second drainage system for the MPD to reduce the pressure in the MPD and prevent acute pancreatitis. However, as there was no relationship between the severity of acute pancreatitis and patency of the APD, APD patency appears to relate to the trigger of acute pancreatitis, but not to the progression of pancreatitis. During ERCP, in cases with non-patent APD, endoscopists should be more cautious to post-ERCP pancreatitis than usual, and alternatively consider prophylactic pancreatic stenting.

Although DPD dominance was observed in about 4% of pancreases^[19,28], it was detected in 12% of PBM patients. In PBM patients, the incidence of associated biliary carcinoma in DPD-dominant patients with PBM was significantly less frequent than that of a normal pancreatic duct system. Furthermore, a lower amylase level in the bile was more frequently seen in DPD-dominant patients. From these facts, it is suggested that, in PBM patients with DPD dominance,

most pancreatic juice in the upper DPD is drained into the duodenum *via* the MIP, and reflux of pancreatic juice to the biliary tract might be reduced, resulting in less frequency of associated biliary carcinoma.

CONCLUSION

Patency of the APD in patients with acute pancreatitis was significantly lower than in controls. A patent APD may function as a second drainage system to reduce the pressure in the MPD and prevent acute pancreatitis.

REFERENCES

- 1 Adda G, Hannoun L, Loygue J. Development of the human pancreas: variations and pathology. A tentative classification. *Anat Clin* 1984; **5**: 275-283
- 2 Skandalakis LJ, Rowe JS Jr, Gray SW, Skandalakis JE. Surgical embryology and anatomy of the pancreas. *Surg Clin North Am* 1993; **73**: 661-697
- 3 Kamisawa T, Koike M, Okamoto A. Embryology of the pancreatic duct system. *Digestion* 1999; **60**: 161-165
- 4 Kamisawa T, Yuyang T, Egawa N, Ishiwata J, Okamoto A. A new embryologic hypothesis of annular pancreas. *Hepatogastroenterology* 2001; **48**: 277-278
- 5 Kamisawa T, Egawa N, Nakajima H, Tsuruta K, Okamoto A, Matsukawa M. Origin of the long common channel based on pancreatographic findings in pancreaticobiliary maljunction. *Dig Liver Dis* 2005; **37**: 363-367
- 6 Kamisawa T. Clinical significance of the minor duodenal papilla and accessory pancreatic duct. *J Gastroenterol* 2004; **39**: 605-615
- 7 Kamisawa T, Egawa N, Tsuruta K, Okamoto A, Matsukawa M. Pancreatitis associated with congenital abnormalities of the pancreaticobiliary system. *Hepatogastroenterology* 2005; **52**: 223-239
- 8 Cotton PB. Congenital anomaly of pancreas divisum as cause of obstructive pain and pancreatitis. *Gut* 1980; **21**: 105-114
- 9 Bernard JP, Sahel J, Giovannini M, Sarles H. Pancreas divisum is a probable cause of acute pancreatitis: a report of 137 cases. *Pancreas* 1990; **5**: 248-254
- 10 Blair AJ 3rd, Russell CG, Cotton PB. Resection for pancreatitis in patients with pancreas divisum. *Ann Surg* 1984; **200**: 590-594
- 11 Warshaw AL, Simeone JF, Schapiro RH, Flavin-Warshaw B. Evaluation and treatment of the dominant dorsal duct syndrome (pancreas divisum redefined). *Am J Surg* 1990; **159**: 59-64; discussion 64-66
- 12 Lans JJ, Geenen JE, Johanson JF, Hogan WJ. Endoscopic therapy in patients with pancreas divisum and acute pancreatitis: a prospective, randomized, controlled clinical trial. *Gastrointest Endosc* 1992; **38**: 430-434
- 13 Kamisawa T. Endoscopic approach to the minor duodenal papilla: special emphasis on endoscopic management on pancreas divisum. *Dig Endosc* 2006; **18**: 252-255
- 14 Khalid A, Slivka A. Pancreas Divisum. *Curr Treat Options Gastroenterol* 2001; **4**: 389-399
- 15 Choudari CP, Imperiale TF, Sherman S, Fogel E, Lehman GA. Risk of pancreatitis with mutation of the cystic fibrosis gene. *Am J Gastroenterol* 2004; **99**: 1358-1363
- 16 Gelrud A, Sheth S, Banerjee S, Weed D, Shea J, Chuttani R, Howell DA, Telford JJ, Carr-Locke DL, Regan MM, Ellis L, Durie PR, Freedman SD. Analysis of cystic fibrosis gene product (CFTR) function in patients with pancreas divisum and recurrent acute pancreatitis. *Am J Gastroenterol* 2004; **99**: 1557-1562
- 17 Fogel EL, Toth TG, Lehman GA, DiMaggio MJ, DiMaggio EP. Does endoscopic therapy favorably affect the outcome of

- patients who have recurrent acute pancreatitis and pancreas divisum? *Pancreas* 2007; **34**: 21-45
- 18 **Simkins S.** Variations in the pancreatic ducts and the minor duodenal papilla. *Am J Med Sci* 1931; **182**: 626-639
 - 19 **Baldwin WM.** The pancreatic ducts in man, together with a study of the microscopical structure of the minor duodenal papilla. *Anat Rec* 1911; **5**: 197-228
 - 20 **Dawson W, Langman J.** An anatomical-radiological study on the pancreatic duct pattern in man. *Anat Rec* 1961; **139**: 59-68
 - 21 **Kamisawa T, Tabata I, Tajima T, Tsushima K, Yoshida Y.** Patency of the human accessory pancreatic duct as determined by dye-injection endoscopic retrograde pancreatography. *Digestion* 1997; **58**: 78-82
 - 22 **Kamisawa T, Yuyang T, Egawa N, Ishiwata J, Okamoto A.** Patency of the accessory pancreatic duct in relation to its course and shape: a dye-injection endoscopic retrograde pancreatography study. *Am J Gastroenterol* 1998; **93**: 2135-2140
 - 23 **Kamisawa T, Yoshiike M, Egawa N, Nakajima H.** Patency of the accessory pancreatic duct evaluated by dye-injection endoscopic retrograde pancreatography: method and clinical implication. *Dig Endosc* 2004; **16**: 272-276
 - 24 **Kamisawa T, Amemiya K, Tu Y, Egawa N, Sakaki N, Tsuruta K, Okamoto A, Munakata A.** Clinical significance of a long common channel. *Pancreatol* 2002; **2**: 122-128
 - 25 **Kamisawa T, Okamoto A.** Biliopancreatic and pancreatobiliary refluxes in cases with and without pancreaticobiliary maljunction: diagnosis and clinical implications. *Digestion* 2006; **73**: 228-236
 - 26 **Kamisawa T, Takuma K, Anjiki H, Egawa N, Kurata M, Honda G, Tsuruta K, Sasaki T.** Pancreaticobiliary maljunction. *Clin Gastroenterol Hepatol* 2009; **7**: S84-S88
 - 27 **Nowak A, Nowakowska-Dutawa E, Rybicka J.** Patency of the Santorini duct and acute biliary pancreatitis. A prospective ERCP study. *Endoscopy* 1990; **22**: 124-126
 - 28 **Rienhoff WF Jr, Pickrell KL.** Pancreatitis, an anatomic study of the pancreatic and extrahepatic biliary systems. *Arch Surg* 1945; **51**: 205-219

S- Editor Tian L L- Editor Ma JY E- Editor Lin YP