

An aortoduodenal fistula as a complication of immunoglobulin G4-related disease

Momir Sarac, Ivan Marjanovic, Mihailo Bezmarevic, Uros Zoranovic, Stanko Petrovic, Miodrag Mihajlovic

Momir Sarac, Ivan Marjanovic, Uros Zoranovic, Clinic for Vascular and Endovascular Surgery, Military Medical Academy, 11000 Belgrade, Serbia

Mihailo Bezmarevic, Clinic for General Surgery, Military Medical Academy, 11000 Belgrade, Serbia

Stanko Petrovic, Clinic for Gastroenterology, Military Medical Academy, 11000 Belgrade, Serbia

Miodrag Mihajlovic, Institute of Radiology, Military Medical Academy, 11000 Belgrade, Serbia

Author contributions: Sarac M, Marjanovic I and Bezmarevic M operated on the patient; Bezmarevic M took the photos and researched sources for the references; Bezmarevic M, Petrovic S, Sarac M and Marjanovic I were engaged in the postoperative treatment; Sarac M, Bezmarevic M, Zoranovic U and Petrovic S participated in the follow up; Mihajlovic M and Petrovic S helped in the interpretation of photos and helped draft the final version of the manuscript; all authors participated in writing the case report and revising the draft.

Correspondence to: Mihailo Bezmarevic, MD, Clinic for General Surgery, Military Medical Academy, Crnotravska 17, 11000 Belgrade, Serbia. bezmarevicm@gmail.com

Telephone: +381-641-994288 Fax: +381-113-608550

Received: April 16, 2012 Revised: July 2, 2012

Accepted: July 9, 2012

Published online: November 14, 2012

sociated with IgG4-related sclerosing disease as a possible complication of IgG4-related inflammatory aortic aneurysm. Endovascular grafting of a primary aortoduodenal fistula is an effective and minimally invasive alternative to standard surgical repair.

© 2012 Baishideng. All rights reserved.

Key words: Abdominal aortic aneurysm; Aortoduodenal fistula; Endovascular repair; Immunoglobulin G4-related disease

Peer reviewers: Fausto Catena, MD, Department of General, Emergency and Transplant Surgery, St. Orsola-Malpighi University Hospital, Via Massarenti 9, 40139 Bologna, Italy; Dr. Beata Jabońska, Digestive Tract Surgery, Medical University of Silesia, Medyków 14 St., 40-752 Katowice, Poland

Sarac M, Marjanovic I, Bezmarevic M, Zoranovic U, Petrovic S, Mihajlovic M. An aortoduodenal fistula as a complication of immunoglobulin G4-related disease. *World J Gastroenterol* 2012; 18(42): 6164-6167 Available from: URL: <http://www.wjgnet.com/1007-9327/full/v18/i42/6164.htm> DOI: <http://dx.doi.org/10.3748/wjg.v18.i42.6164>

Abstract

Most primary aortoduodenal fistulas occur in the presence of an aortic aneurysm, which can be part of immunoglobulin G4 (IgG4)-related sclerosing disease. We present a case who underwent endovascular grafting of an aortoduodenal fistula associated with a high serum IgG4 level. A 56-year-old male underwent urgent endovascular reconstruction of an aortoduodenal fistula. The patient received antibiotics and other supportive therapy, and the postoperative course was uneventful, however, elevated levels of serum IgG, IgG4 and C-reactive protein were noted, which normalized after the introduction of steroid therapy. Control computed tomography angiography showed no endoleaks. The primary aortoduodenal fistula may have been as-

INTRODUCTION

A primary aortoenteric fistula (AEF) is a communication between the aorta and the intestines, and occurs in a setting without prior aortic surgery. It is a rare but potentially lethal condition with an incidence of 0.04% to 0.07%^[1]. Primary fistulas are in most cases (90%), the result of erosion of the bowel wall, caused by an abdominal aortic aneurysm (AAA)^[2]. The majority occur between the aorta and the duodenum^[3]. Primary aortoduodenal fistulas (ADF) have been reported in the presence of various conditions, including underlying atherosclerotic aortic aneurysm disease, gallstone erosion, foreign body ingestion, and invasive intra-abdominal malignancies^[4]. However, it has been reported that an aortic

WJG | www.wjgnet.com

6165

November 14, 2012 | Volume 18 | Issue 42 |

antibiotics (imipenem in combination with vancomycin) preoperatively, and continued with the same medication for 4 wk after endovascular repair. The patient then continued taking an oral antibiotic for the next two months (ciprofloxacin 1000 mg per day for 4 wk then doxycycline 100 mg per day for another 4 wk). The post-operative course was without complications and without further blood loss. After the patient was introduced to *per os* food intake, control CT angiography showed no endoleaks and a reduction in thrombotic mass volume in the aneurysm with regression of the aneurysm diameter, however, the gas collection persisted (Figure 3A).

On the tenth day after endovascular repair, RBC and HCT values were normal (RBC 4.2 million per μL and HCT 35%). The patient had improved, but the laboratory tests showed a CRP serum level of 56 mg/L and a high serum IgG level of 20.2 g/L and IgG4 of 4.24 g/L, respectively. Autoantibodies against lactoferrin and carbonic anhydrase II were negative, and autoantibodies including anti-nuclear antibodies, antineutrophil cytoplasmic antibodies and rheumatoid factor were not found. Markers for viral hepatitis Bs infection, hepatitis C virus, hepatitis A virus, human immunodeficiency viruses 1 and 2 were negative. Due to lack of histopathological findings, but elevated serum levels of IgG, it could not

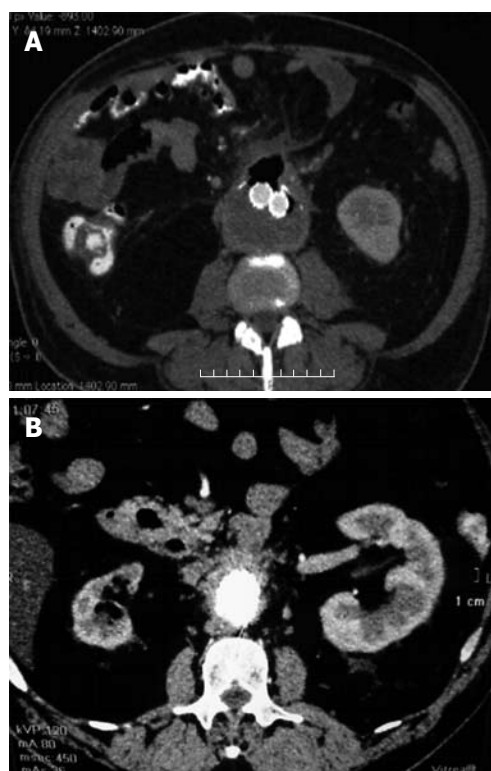


Figure 3 Control computed tomography angiography. A: Control computed tomography (CT) angiography shows no endoleaks and reduction of thrombotic mass volume in the aneurysmatic sac with persistence of gas collection; B: Control CT angiography after 6 mo showed no endoleaks and near total reduction of thrombotic mass in the aneurysmatic sac, without gas collection.

be determined with confidence that this was a systemic disease. It was decided that the patient should start steroid therapy with oral prednisolone at 40 mg per day for 4 wk, and then decrease the dosage by 5 mg every week. Four wk after initiation of steroid therapy, serum levels of IgG (16 g/L) and IgG4 (0.7 g/L) as well as CRP were normal. In the control examination conducted 6 mo after the patient's discharge from hospital (almost 3 mo after the end of steroid therapy), the levels of serum immunoglobulins and CRP were in the normal ranges and control CT angiography showed no endoleaks, near total reduction of the thrombotic mass in the aneurysmatic sac, and no gas collection (Figure 3B).

DISCUSSION

Primary ADF represents a serious condition and is much less frequent than a secondary ADF which occurs as a result of previous aortic aneurysm grafting. The first described case of primary ADF was more than a century ago, and since then about 250 cases have been reported. In the absence of treatment, the mortality rate is almost 100%. With surgical intervention, survival ranges from 18%-93%, but 40% of operated cases develop complications with an overall postoperative mortality rate greater than 30%^[12]. Diagnosis of primary ADF is also difficult. Only 33% to 50% of AEF are diagnosed preoperatively^[3]. Gastrointestinal bleeding and abdominal pain

have been described in all cases, but the classic trio of abdominal pain, palpable mass and gastrointestinal bleeding was found in only 6% to 27.8% of patients^[2,13,14]. Our patient only had gastrointestinal bleeding presenting as melena. Diagnostic procedures include EGDS, CT scan, and arteriography. Endoscopy is considered the modality of choice for initial evaluation of upper gastrointestinal bleeding, but has the potential risk of inducing massive hemorrhage by dislodging fresh thrombus in the fistula^[15,16]. In our case, EGDS findings were without signs of gastrointestinal hemorrhage. CT angiography was reliable in diagnosing AEF but may be somewhat challenging in unstable patients.

The surgical treatment of ADF consists of repairing the duodenal defect and performing a prosthetic repair of the aorta with graft. Where contamination is present, or in the case of mycotic aneurysm, an extraanatomical aortic graft is preferred and extensive debridement is required^[17]. Although the endovascular approach is increasingly utilized in the repair of secondary AEF, only a few primary AEF treated using this method have been reported^[4,11,12,18,19]. In the case of any applied vascular procedure, long-term broad spectrum antibiotic therapy is necessary^[11,12]. We believe that patients with persistent anemia who undergo laparotomy without diagnosis is hazardous.

Primary ADF is the result of inflammatory destruction of an aortic aneurysm arising from an atherosclerotic AAA. This is an etiological factor in 73% of all primary ADFs, while 26% are caused by traumatic or mycotic aneurysms^[2,17,20]. Rarer causes such as radiation, tumors, ulcers and ingestion of foreign bodies account of 1% or less^[4,12]. A very small number of AEF occur in the absence of an aortic aneurysm. In comparison to atherosclerotic AAA, IAAA occurs in only 2% to 10% of all AAA, and has different clinical characteristics, such as younger age of patients, non-specific symptoms, and large aneurysm diameter. Recent reports showed a close relationship between IgG4 and sclerosing lesions of various organs^[21]. IgG4-related sclerosing disease, which are also called IgG4-related sclerosing disease, was first reported with regard to autoimmune pancreatitis^[22]. The clinical characteristics of IgG4-related sclerosing disease are a frequent occurrence in adult male patients, and include elevation of serum IgG4 levels, and steroid sensitivity. In addition to affected organs in IgG4-related disease, elevated IgG4 levels have been described in atopic dermatitis, asthma, some parasitic diseases, pemphigus vulgaris, pemphigus foliaceus and pancreatic cancer^[23]. Our patient had no clinical signs of these diseases. The correct diagnosis of IAAA as part of IgG4-related disease is based on histopathological findings^[21]. According to these recommendations, the diagnosis of IAAA as part of IgG4-related disease in our patient could not be established due to lack of histopathological findings, as endovascular repair of AAA, was successful. If the AAA in our patient was an IAAA, this would be the first case with ADF in IgG4-related sclerosing disease. In addition, the patient had a positive response to steroid therapy. The

question remains as to how it is possible to make a diagnosis of IgG4-related IAAA in such cases where urgent minor surgery is the treatment of choice. In our case, endovascular repair of ADF was successful, and this may be an alternative treatment, especially in patients with high operative risk. Broad spectrum antibiotic therapy is as important as the endovascular treatment in ADF.

In conclusion, primary ADF is a rare complication of aortic aneurysms and is a rare cause of gastrointestinal bleeding. It can be associated with IgG4-related sclerosing disease, whether it occurs as a complication of IAAA or not. CT angiography is a good diagnostic test for an ADF. This case demonstrates that endovascular grafting of primary ADF as an effective, minimally invasive alternative to standard surgical repair. Other supportive therapy such as antibiotics are very important in the treatment of this condition. High serum IgG4 levels and a positive response to steroid therapy suggest the existence of an ADF in IgG4-related IAAA, without histopathological examination.

REFERENCES

- 1 Ferguson MJ, Arden MJ. Gastrointestinal hemorrhage secondary to rupture of aorta. A review of four duodenal and three esophageal cases. *Arch Intern Med* 1966; **117**: 133-140
- 2 Calligaro KD, Bergen WS, Savarese RP, Westcott CJ, Azurin DJ, DeLaurentis DA. Primary aortoduodenal fistula due to septic aortitis. *J Cardiovasc Surg (Torino)* 1992; **33**: 192-198
- 3 Busuttil SJ, Goldstone J. Diagnosis and management of aortoenteric fistulas. *Semin Vasc Surg* 2001; **14**: 302-311
- 4 Eskandari MK, Makaroun MS, Abu-Elmagd KM, Billiar TR. Endovascular repair of an aortoduodenal fistula. *J Endovasc Ther* 2000; **7**: 328-332
- 5 Kasashima S, Zen Y. IgG4-related inflammatory abdominal aortic aneurysm. *Curr Opin Rheumatol* 2011; **23**: 18-23
- 6 Ito H, Kaizaki Y, Noda Y, Fujii S, Yamamoto S. IgG4-related inflammatory abdominal aortic aneurysm associated with autoimmune pancreatitis. *Pathol Int* 2008; **58**: 421-426
- 7 Tseng CW, Tsai JJ, Chen CC. Abdominal aortitis associated with autoimmune pancreatitis. *Clin Gastroenterol Hepatol* 2009; **7**: e3-e4
- 8 Matsuki Y, Sato K, Fujikawa A, Kyoto Y, Hashimoto H, Hakozaiki Y. A case of incidentally detected IgG4-related sclerosing disease involving inflammatory abdominal aortic aneurysm and autoimmune pancreatitis. *Mod Rheumatol* 2010; **20**: 306-310
- 9 Finkelberg DL, Sahani D, Deshpande V, Brugge WR. Autoimmune pancreatitis. *N Engl J Med* 2006; **355**: 2670-2676
- 10 Kim KP, Kim MH, Song MH, Lee SS, Seo DW, Lee SK. Autoimmune chronic pancreatitis. *Am J Gastroenterol* 2004; **99**: 1605-1616
- 11 Jayarajan S, Napolitano LM, Rectenwald JE, Upchurch GR. Primary aortoenteric fistula and endovascular repair. *Vasc Endovascular Surg* 2009; **43**: 592-596
- 12 Shehzad KN, Riaz A, Meyrick-Thomas J. Primary aortoduodenal fistula - a rare clinical entity. *JRSM Short Rep* 2010; **1**: 7
- 13 Song Y, Liu Q, Shen H, Jia X, Zhang H, Qiao L. Diagnosis and management of primary aortoenteric fistulas--experience learned from eighteen patients. *Surgery* 2008; **143**: 43-50
- 14 Voorhoeve R, Moll FL, de Letter JA, Bast TJ, Wester JP, Slee PH. Primary aortoenteric fistula: report of eight new cases and review of the literature. *Ann Vasc Surg* 1996; **10**: 40-48
- 15 Frizelle FA, Hung NA, Heslop JH, Parry BR. Obscure gastrointestinal bleeding: idiopathic aortoduodenal fistula. *J R Coll Surg Edinb* 1991; **36**: 331-333
- 16 Goenka MK, Mehta SK, Kochhar R, Nagi B, Sachdev A, Bhardwaj A, Gupta NM. Primary aortoduodenal fistula in a 23 year old man without an associated aortic aneurysm. *Eur J Surg* 1993; **159**: 371-372
- 17 Pagni S, Denatale RW, Sweeney T, McLaughlin C, Ferneini AM. Primary aorto-duodenal fistula secondary to infected abdominal aortic aneurysms: the role of local debridement and extra-anatomic bypass. *J Cardiovasc Surg (Torino)* 1999; **40**: 31-35
- 18 Papacharalambous G, Skourtis G, Saliveros A, Karagannidis D, Makris S, Panousis P, Ktenidis K. Endovascular treatment of a primary aortoduodenal fistula: 2-year follow-up of a case report. *Vasc Endovascular Surg* 2007; **41**: 265-270
- 19 Burks JA, Faries PL, Gravereaux EC, Hollier LH, Marin ML. Endovascular repair of bleeding aortoenteric fistulas: a 5-year experience. *J Vasc Surg* 2001; **34**: 1055-1059
- 20 Farber A, Grigoryants V, Palac DM, Chapman T, Cronenwett JL, Powell RJ. Primary aortoduodenal fistula in a patient with a history of intravesical therapy for bladder cancer with bacillus Calmette-Guérin: review of primary aortoduodenal fistula without abdominal aortic aneurysm. *J Vasc Surg* 2001; **33**: 868-873
- 21 Kasashima S, Zen Y, Kawashima A, Endo M, Matsumoto Y, Kasashima F. A new clinicopathological entity of IgG4-related inflammatory abdominal aortic aneurysm. *J Vasc Surg* 2009; **49**: 1264-1271; discussion 1271
- 22 Hamano H, Kawa S, Horiuchi A, Unno H, Furuya N, Akamatsu T, Fukushima M, Nikaido T, Nakayama K, Usuda N, Kiyosawa K. High serum IgG4 concentrations in patients with sclerosing pancreatitis. *N Engl J Med* 2001; **344**: 732-738
- 23 Zhang L, Notohara K, Levy MJ, Chari ST, Smyrk TC. IgG4-positive plasma cell infiltration in the diagnosis of autoimmune pancreatitis. *Mod Pathol* 2007; **20**: 23-28

S- Editor Gou SX L- Editor Webster JR E- Editor Li JY