

Influence of endoscopic submucosal dissection on esophageal motility

Bao-Guo Bu, En-Qiang Linghu, Hui-Kai Li, Xiao-Xiao Wang, Rong-Bin Guo, Li-Hua Peng

Bao-Guo Bu, En-Qiang Linghu, Hui-Kai Li, Xiao-Xiao Wang, Rong-Bin Guo, Li-Hua Peng, Department of Gastroenterology and Hepatology, PLA General Hospital, Beijing 100853, China

Author contributions: Linghu EQ designed the research; Bu BG performed the research and contributed to acquisition, analysis and interpretation of data, and wrote the article; Li HK, Wang XX, Guo RB and Peng LH contributed to acquisition of data.

Correspondence to: En-Qiang Linghu, Professor, Department of Gastroenterology and Hepatology, PLA General Hospital, 28 Fuxing Road, Haidian District, Beijing 100853, China. linghuenqiang@vip.sina.com

Telephone: +86-10-66936998 Fax: +86-10-68154653

Received: May 1, 2013 Revised: June 22, 2013

Accepted: June 28, 2013

Published online: August 7, 2013

Abstract

AIM: To assess esophageal motility after esophageal endoscopic submucosal dissection (ESD).

METHODS: Twelve patients (6 men and 6 women) aged 53-64 years (mean age, 58 years) who underwent regular examination 3-12 mo after esophageal ESD for neoplasms of the esophageal body were included in this study. The ESD procedure was performed under deep sedation using a combination of propofol and fentanyl, and involved a submucosal injection to lift the lesion and use of a dual-knife and an insulated-tip knife to create a circumferential incision around the lesion extending into the submucosa. Esophageal motility was examined using a high-resolution manometry system. Dysphagia was graded using a five-point scale according to the Mellow and Pinkas scoring system. Patient symptoms and the results of esophageal manometry were then analyzed.

RESULTS: Of the 12 patients enrolled, 1 patient had

grade 2 dysphagia, 1 patient had grade 1 dysphagia, and 3 patients complained of sporadic dysphagia. Ineffective esophageal motility was observed in 5 of 6 patients with above semi-circumference of resection extension. Of these 5 patients, 1 patient complained of grade 2 dysphagia (with esophageal stricture), one patient complained of grade 1 dysphagia, and 3 patients complained of sporadic dysphagia. Normal esophageal body manometry was observed in all 6 patients with below semi-circumference of resection extension. The 6 patients with normal esophageal motility did not complain of dysphagia.

CONCLUSION: Extensive esophageal ESD may cause esophageal dysmotility in some patients, and might also have an influence on dysphagia although without esophageal stricture.

© 2013 Baishideng. All rights reserved.

Key words: Esophageal neoplasm; Endoscopic submucosal dissection; Dysphagia; Ineffective esophageal motility; Esophageal manometry

Core tip: Endoscopic submucosal dissection (ESD) is widely used to treat esophageal epithelial neoplasms. ESD has the advantage over esophagectomy of being less invasive and having lower postoperative morbidity. ESD also has the advantage over endoscopic mucosal resection of enabling the removal of larger epithelial neoplasms in an *en bloc* manner for complete resection. It is not known whether esophageal ESD affects esophageal motility. Therefore, the present study aimed to evaluate the effects of ESD on esophageal motility.

Bu BG, Linghu EQ, Li HK, Wang XX, Guo RB, Peng LH. Influence of endoscopic submucosal dissection on esophageal motility. *World J Gastroenterol* 2013; 19(29): 4781-4785 Available from: URL: <http://www.wjgnet.com/1007-9327/full/v19/i29/4781.htm> DOI: <http://dx.doi.org/10.3748/wjg.v19.i29.4781>

INTRODUCTION

Endoscopic submucosal dissection (ESD) is widely used to treat esophageal epithelial neoplasms^[1-3]. ESD has the advantage over esophagectomy of being less invasive and having lower postoperative morbidity^[4-6]. ESD also has the advantage over endoscopic mucosal resection (EMR) of enabling the removal of larger epithelial neoplasms in an *en bloc* manner for complete resection^[7-9]. Some postoperative complications such as bleeding and perforation may occur, but can be minimized by the development of the endoscopist's skill and the use of advanced equipment^[10,11]. Postoperative stricture is a major complication of ESD due to the increase in the scope of ESD resection, which can result in dysphagia and thus affect patients' quality of life. Some studies have found that more than 3/4 of the circumference of esophageal ESD has a high risk of esophageal stricture^[12,13]. Post-ESD stricture can be prevented with repeated endoscopic balloon dilation and oral prednisolone^[14,15].

In addition, dysphagia is not always related to esophageal stricture and motility abnormalities also play an important role^[16-19]. Some patients undergoing esophageal ESD at our center complained of sporadic dysphagia without postoperative esophageal stricture, especially when swallowing a large mass of food. This observation has raised concerns that sporadic dysphagia in these patients may be due to postoperative esophageal dysmotility. Moreover, the healing of an ESD-induced iatrogenic esophageal ulcer is also involved in destruction and fibrosis of the muscularis propria^[20]. It is not known whether esophageal ESD affects esophageal motility. Therefore, the present study aimed to evaluate the effects of ESD on esophageal motility.

MATERIALS AND METHOD

Patients

Twelve patients (6 men, 6 women; mean age, 58 years; range, 53-64 years) examined between 3 and 12 mo after ESD for neoplasms of the esophageal body at the Chinese PLA General Hospital were included in this study. Clinicopathological data of the patients are shown in Table 1. After written informed consent was obtained, data on dysphagia were collected by questionnaire and all patients underwent esophageal manometry.

ESD procedure

The ESD procedure was performed in a standardized way under deep sedation using a combination of propofol and fentanyl. Patients were continuously monitored by electrocardiography. The margins of the lesion were marked by electrocautery (30 W soft coagulation) to determine the resection border. A submucosal injection was then performed to lift the lesion. When the lesion was lifted sufficiently, a dual-knife and insulated-tip knife were used to create a circumferential incision around the lesion extending into the submucosa and a submucosal

dissection was performed to remove the lesion in an *en bloc* fashion.

Grading of dysphagia

Dysphagia was graded on a five-point scale according to Mellow and Pinkas^[21]: 0 = no dysphagia, 1 = dysphagia to normal solids, 2 = dysphagia to soft solids, 3 = dysphagia to solids and liquids, 4 = complete dysphagia, even to saliva.

Esophageal manometry

Assessment of esophageal motility was performed using a high-resolution manometry system with 36 channels spaced at 1 cm intervals (outer diameter 4.2 mm) (Sierra Scientific Instruments, Los Angeles, CA, United States). This system can automatically capture esophageal motor function from the pharynx to the stomach with a single placement of the catheter.

Esophageal manometry was performed after fasting for at least 6 h, and the high-resolution catheter was passed transnasally, positioned 2 cm below the lower esophageal sphincter (LES) and then fixed in place by taping it to the nose. The upper esophageal sphincter and LES were located using a real-time pressure monitor. The protocol included a 5-min period to assess basal sphincter pressure and then ten swallows of water (5 mL each swallow) in the supine position^[22]. All swallows and pressure measurements were analyzed by Manoview Analysis Software (Sierra Scientific Instruments, United States).

RESULTS

Grading of dysphagia

Of the 12 patients, one patient complained of grade 2 dysphagia, one complained of grade 1 dysphagia and three patients complained of sporadic dysphagia (especially when swallowing a large mass of food) (Table 1).

Esophageal manometry

Esophageal manometry showed that of the 6 patients with above semi-circumference of resection extension, 5 patients had low esophageal body pressure, including four patients with low mean esophageal body pressure and one with low pressure at an interval of 3 cm below the LES (Table 1). Of these 5 patients, 1 patient (with post-ESD esophageal stricture) complained of grade 2 dysphagia, 1 patient (without post-ESD esophageal stricture) complained of grade 1 dysphagia and 3 patients complained of sporadic dysphagia. Segmental simultaneous wave was observed in ESD scar site in 4 of these 5 patients, and wave amplitude was significantly decreased (Figure 1).

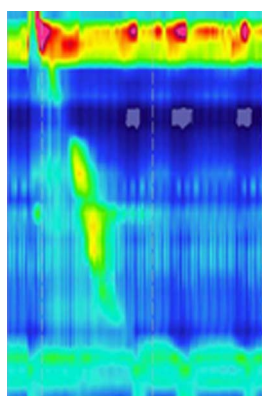
DISCUSSION

ESD is a feasible method for treating early esophageal epithelial neoplasms, and was developed for *en bloc* and

Table 1 Clinicopathological features and esophageal manometry of 12 patients with esophageal epithelial neoplasms treated by endoscopic submucosal dissection

Number of patient	Sex	Age (yr)	Post-ESD pathology	Circumferential extension	Grade of dysphagia	Pressure of esophageal body (mmHg)			Non-peristaltic contractions of esophageal body in ten water swallows
						7.0 cm above LES	3.0 cm above LES	mean	
1	F	64	T1 cancer	2/4-3/4	0	129.8	108.7	119.2	0%
2	M	64	LGIN	1/4-2/4	0	99.9	75.3	87.6	0%
3	M	53	HGIN	2/4-3/4	2	26.1	45.2	35.6	40%
4	F	55	HGIN	2/4-3/4	Sporadic	31.8	41.2	36.5	50%
5	M	55	HGIN/Tis	1/4-2/4	0	139.1	125.9	132.5	0%
6	M	55	LGIN	2/4-3/4	Sporadic	90.1	31.9	61.0	20%
7	M	58	T1 cancer	> 3/4	Sporadic	34.1	21.7	27.9	20%
8	F	64	HGIN/Tis	1/4-2/4	0	58.6	76.6	67.6	0%
9	F	55	LGIN	1/4-2/4	0	99.0	109.2	104.1	0%
10	F	57	HGIN	> 3/4	1	34.3	52.5	43.4	50%
11	F	58	HGIN	1/4-2/4	0	96.2	109.2	102.7	0%
12	M	57	LGIN	1/4-2/4	0	90.6	76.2	83.4	0%

HGIN: High grade intraepithelial neoplasia; LGIN: Low grade intraepithelial neoplasia; LES: Lower esophageal sphincter; ESD: Endoscopic submucosal dissection; Tis: Cancer *in situ*; M: Male; F: Female.

**Figure 1** Segmental simultaneous wave and decreased amplitude in endoscopic submucosal dissection scar site.

complete resection of large esophageal epithelial neoplasms, to allow precise histological assessment of specimens excised in one piece with tumor-free lateral/basal margins and to reduce residual disease and local recurrence^[1-3]. With the increase in the scope of esophageal ESD resection, postoperative esophageal stricture and dysphagia are major complications during long-term follow-up, and require repetitive endoscopic balloon dilatation which severely affects patient quality of life. More than 3/4 of the circumference of esophageal ESD is a significant cause of postoperative esophageal stricture^[12,13]. Ono *et al.*^[10] reported that post-ESD stricture with dysphagia was successfully managed with repeated endoscopic balloon dilation in a median of 2 sessions.

Honda *et al.*^[23] found that in a dog model, mucosal defects after EMR were associated with inflammation and although the muscularis propria appeared not to have been damaged by the EMR procedure, myofiber atrophy was found to develop after the first postoperative week, eventually leading to fibrosis. Ota *et al.*^[20] found that an artificial ulcer after esophageal EMR/ESD in humans had a similar healing time to that in dogs. Kahrilas *et al.*^[24] reported an increased proportion of failed primary peristalsis and

a reduction in peristalsis amplitude in peptic esophagitis. Singh *et al.*^[25] found a reduction in peristaltic amplitude after healing of esophagitis. Malhi-Chowla *et al.*^[19] found that photodynamic therapy may worsen esophageal motility in some patients with esophageal adenocarcinoma and Barrett's esophagus or Barrett's esophagus with high-grade dysplasia. Esophageal dysmotility resulting from photodynamic therapy or caustic esophageal burns is due to muscularis propria destruction. Bautista *et al.*^[16] found that caustic esophageal burns can also result in esophageal dysmotility without stricture. McDougall *et al.*^[26] found that there was no improvement in esophageal motility after healing of esophagitis, and they suggested that there was either a primary motility problem, or that reflux damage caused irreversible impairment of motility which failed to recover when the mucosa healed. Healing of post-ESD esophageal ulcer is a similar process to that in caustic esophageal burns and photodynamic therapy. It is not known whether esophageal ESD affects esophageal motility.

In the present study, ineffective esophageal body motility was observed in 5 of 6 patients with above semi-circumference of resection extension. Segmental simultaneous wave was observed in ESD scar site in 4 of these 5 patients, and wave amplitude was significant decreased. These results showed that extensive esophageal ESD might have an effect on esophageal motility. These were some observed phenomenon, and further research was needed to confirm.

Malhi-Chowla *et al.*^[19] found that some patients complained of dysphagia after photodynamic therapy without esophageal stricture, while esophageal dysmotility was observed in these patients. Therefore, they considered that dysphagia may be related to underlying esophageal dysmotility and may not always be caused by stricture or underlying carcinoma.

In the present study, 2 patients complained of dysphagia, and 3 patients complained of sporadic dysphagia. Of these 5 patients, only one had esophageal stricture.

However, ineffective esophageal motility was observed in all five patients. These results showed that besides esophageal stricture, ineffective esophageal motility might play an important role in dysphagia after esophageal ESD.

In summary, extensive esophageal ESD may cause ineffective esophageal motility, and ineffective esophageal motility may be a cause of dysphagia after esophageal ESD. Further studies should be encouraged to compare esophageal motility in patients before and after they undergo esophageal ESD.

COMMENTS

Background

Endoscopic submucosal dissection (ESD) is used to resect the esophageal epithelial neoplasms and has the advantage over endoscopic mucosal resection of enabling the removal of the larger epithelial neoplasms in an *en bloc* manner for complete resection. The previous study showed that esophageal dysmotility after caustic burn may cause dysphagia. However, esophageal dysmotility after esophageal ESD has not been studied. The present study therefore aimed to assess esophageal motility after esophageal ESD.

Research frontiers

The study involved testing the esophageal motility after esophageal ESD and analyzing the relation of esophageal dysmotility and extension of ESD.

Innovations and breakthroughs

Esophageal dysmotility after esophageal ESD has not been reported. In this study, the authors found that low esophageal body pressure was observed in 5 patients of 6 patients with above semi-circumference of resection extension, whereas normal esophageal body manometry was observed in all 6 patients with below semi-circumference of resection extension. The 5 patients with low esophageal body pressure complained of various degree of dysphagia.

Applications

The results suggest that extensive esophageal ESD may cause ineffective esophageal motility, and ineffective esophageal motility may be a cause of dysphagia after esophageal ESD.

Peer review

ESD is widely used to treat esophageal epithelial neoplasms. The authors evaluated the effects of ESD on esophageal motility. The authors suggest that extensive esophageal ESD may cause ineffective esophageal motility, and ineffective esophageal motility may be a cause of dysphagia after esophageal ESD. The data in this study is very important and informative.

REFERENCES

- Oyama T, Tomori A, Hotta K, Morita S, Kominato K, Tanaka M, Miyata Y. Endoscopic submucosal dissection of early esophageal cancer. *Clin Gastroenterol Hepatol* 2005; **3**: S67-S70 [PMID: 16013002]
- Fujishiro M, Yahagi N, Kakushima N, Kodashima S, Muraki Y, Ono S, Yamamichi N, Tateishi A, Shimizu Y, Oka M, Ogura K, Kawabe T, Ichinose M, Omata M. Endoscopic submucosal dissection of esophageal squamous cell neoplasms. *Clin Gastroenterol Hepatol* 2006; **4**: 688-694 [PMID: 16713746]
- Honda K, Akiho H. Endoscopic submucosal dissection for superficial esophageal squamous cell neoplasms. *World J Gastrointest Pathophysiol* 2012; **3**: 44-50 [PMID: 22532931 DOI: 10.4291/wjgp.v3.i2.44]
- Kato H, Tachimori Y, Watanabe H, Yamaguchi H, Ishikawa T, Itabashi M. Superficial esophageal carcinoma. Surgical treatment and the results. *Cancer* 1990; **66**: 2319-2323 [PMID: 2245387]
- Roth JA, Putnam JB Jr. Surgery for cancer of the esophagus. *Semin Oncol* 1994; **21**: 453-461 [PMID: 7518967]
- Fujita H, Sueyoshi S, Yamana H, Shinozaki K, Toh U, Tanaka Y, Mine T, Kubota M, Shirouzu K, Toyonaga A, Harada H, Ban S, Watanabe M, Toda Y, Tabuchi E, Hayabuchi N, Inutsuka H. Optimum treatment strategy for superficial esophageal cancer: endoscopic mucosal resection versus radical esophagectomy. *World J Surg* 2001; **25**: 424-431 [PMID: 11344392]
- Shimura T, Sasaki M, Kataoka H, Tanida S, Oshima T, Ogasawara N, Wada T, Kubota E, Yamada T, Mori Y, Fujita F, Nakao H, Ohara H, Inukai M, Kasugai K, Joh T. Advantages of endoscopic submucosal dissection over conventional endoscopic mucosal resection. *J Gastroenterol Hepatol* 2007; **22**: 821-826 [PMID: 17565635]
- Ishihara R, Iishi H, Uedo N, Takeuchi Y, Yamamoto S, Yamada T, Masuda E, Higashino K, Kato M, Narahara H, Tatsuta M. Comparison of EMR and endoscopic submucosal dissection for en bloc resection of early esophageal cancers in Japan. *Gastrointest Endosc* 2008; **68**: 1066-1072 [PMID: 18620345 DOI: 10.1016/j.gie.2008.03.1114]
- Takahashi H, Arimura Y, Masao H, Okahara S, Tanuma T, Kodaira J, Kagaya H, Shimizu Y, Hokari K, Tsukagoshi H, Shinomura Y, Fujita M. Endoscopic submucosal dissection is superior to conventional endoscopic resection as a curative treatment for early squamous cell carcinoma of the esophagus (with video). *Gastrointest Endosc* 2010; **72**: 255-264, 264.e1-2 [PMID: 20541198 DOI: 10.1016/j.gie.2010.02.040]
- Ono S, Fujishiro M, Niimi K, Goto O, Kodashima S, Yamamichi N, Omata M. Long-term outcomes of endoscopic submucosal dissection for superficial esophageal squamous cell neoplasms. *Gastrointest Endosc* 2009; **70**: 860-866 [PMID: 19577748 DOI: 10.1016/j.gie.2009.04.044]
- Nonaka K, Arai S, Ishikawa K, Nakao M, Nakai Y, Togawa O, Nagata K, Shimizu M, Sasaki Y, Kita H. Short term results of endoscopic submucosal dissection in superficial esophageal squamous cell neoplasms. *World J Gastrointest Endosc* 2010; **16**: 2:69-74 [PMID: 21160693 DOI: 10.4253/wjge.v2.i2.69]
- Ono S, Fujishiro M, Niimi K, Goto O, Kodashima S, Yamamichi N, Omata M. Predictors of postoperative stricture after esophageal endoscopic submucosal dissection for superficial squamous cell neoplasms. *Endoscopy* 2009; **41**: 661-665 [PMID: 19565442 DOI: 10.1055/s-0029-1214867]
- Mizuta H, Nishimori I, Kuratani Y, Higashidani Y, Kohsaki T, Onishi S. Predictive factors for esophageal stenosis after endoscopic submucosal dissection for superficial esophageal cancer. *Dis Esophagus* 2009; **22**: 626-631 [PMID: 19302207 DOI: 10.1111/j.1442-2050]
- Ezoe Y, Muto M, Ezoe Y, Muto M, Horimatsu T, Morita S, Miyamoto S, Mochizuki S, Minashi K, Yano T, Ohtsu A, Chiba T. Efficacy of preventive endoscopic balloon dilation for esophageal stricture after endoscopic resection. *J Clin Gastroenterol* 2011; **45**: 222-227 [PMID: 20861798 DOI: 10.1097/MCG.0b013e3181f39f4e]
- Yamaguchi N, Isomoto H, Nakayama T, Hayashi T, Nishiyama H, Ohnita K, Takeshima F, Shikuwa S, Kohno S, Nakao K. Usefulness of oral prednisolone in the treatment of esophageal stricture after endoscopic submucosal dissection for superficial esophageal squamous cell carcinoma. *Gastrointest Endosc* 2011; **73**: 1115-1121 [PMID: 21492854]
- Bautista A, Varela R, Villanueva A, Estevez E, Tojo R, Cadranel S. Motor function of the esophagus after caustic burn. *Eur J Pediatr Surg* 1996; **6**: 204-207 [PMID: 8877350]
- Genç A, Mutaf O. Esophageal motility changes in acute and late periods of caustic esophageal burns and their relation to prognosis in children. *J Pediatr Surg* 2002; **37**: 1526-1528. [PMID: 12407532]
- Tugay M, Utkan T, Utkan Z. Effects of caustic lye injury to the esophageal smooth muscle reactivity: in vitro study. *J Surg Res* 2003; **113**: 128-132 [PMID: 12943821]
- Malhi-Chowla N, Wolfsen HC, DeVault KR. Esophageal dysmotility in patients undergoing photodynamic therapy. *Mayo Clin Proc* 2001; **76**: 987-989 [PMID: 11605700]
- Ota M, Ohki T, Nakamura T, Hayashi K, Yamamoto M. Investigation of ulcer healing after esophageal EMR/ESD.

- 21 **Mellow MH**, Pinkas H. Endoscopic therapy for esophageal carcinoma with Nd: YAG laser: prospective evaluation of efficacy, complications, and survival. *Gastrointest Endosc* 1984; **30**: 334-339 [PMID: 6210226]
- 22 **Pandolfino JE**, Ghosh SK, Zhang Q, Jarosz A, Shah N, Kahrilas PJ. Quantifying EGJ morphology and relaxation with high-resolution manometry: a study of 75 asymptomatic volunteers. *Am J Physiol Gastrointest Liver Physiol* 2006; **290**: G1033-1040 [PMID: 16455788]
- 23 **Honda M**, Nakamura T, Hori Y, Shionoya Y, Nakada A, Sato T, Yamamoto K, Kobayashi T, Shimada H, Kida N, Hashimoto A, Hashimoto Y. Process of healing of mucosal defects in the esophagus after endoscopic mucosal resection: histological evaluation in a dog model. *Endoscopy* 2010; **42**: 1092-1095 [PMID: 21038294 DOI: 10.1055/s-0030-1255741]
- 24 **Kahrilas PJ**, Dodds WJ, Hogan WJ, Kern M, Arndorfer RC, Reece A. Esophageal peristaltic dysfunction in peptic esophagitis. *Gastroenterology* 1986; **91**: 897-904 [PMID: 3743966]
- 25 **Singh P**, Adamopoulos A, Taylor RH, Colin-Jones DG. Oesophageal motor function before and after healing of esophagitis. *Gut* 1992; **33**: 1590-1596 [PMID: 1487159]
- 26 **McDougall NI**, Mooney RB, Ferguson WR, Collins JS, McFarland RJ, Love AH. The effect of healing oesophagitis on oesophageal motor function as determined by oesophageal scintigraphy and ambulatory oesophageal motility/pH monitoring. *Aliment Pharmacol Ther* 1998; **12**: 899-907 [PMID: 9768534]

P- Reviewers Blonski W, Kahrilas PJ **S- Editor** Song XX

L- Editor A **E- Editor** Zhang DN





Published by **Baishideng Publishing Group Co., Limited**

Flat C, 23/F., Lucky Plaza,

315-321 Lockhart Road, Wan Chai, Hong Kong, China

Fax: +852-65557188

Telephone: +852-31779906

E-mail: bpgoffice@wjgnet.com

<http://www.wjgnet.com>



ISSN 1007-9327

