

Consecutive laparoscopic gallbladder and spleen resections in cirrhotic patients

Ming-Jun Wang, Jun-Li Li, Jin Zhou, Zhong Wu, Bing Peng

Ming-Jun Wang, Zhong Wu, Bing Peng, Department of Hepato-Biliary-Pancreatic Surgery, West China Hospital, Sichuan University, Chengdu 610041, Sichuan Province, China
Jun-Li Li, Laboratory of Cardiovascular Diseases, Research Centre of Regeneration Medicine, West China Hospital, Sichuan University, Chengdu 610041, Sichuan Province, China
Jin Zhou, Department of Gastrointestinal Surgery, West China Hospital, Sichuan University, Chengdu 610041, Sichuan Province, China

Author contributions: Wang MJ made substantial contribution to the study conception and design, data acquisition and analysis; Wang MJ, Li JL, Zhou J and Wu Z drafted the article and provided critical revision for important intellectual content; Peng B provided the final approval of the version to be published.

Supported by Grant from the West China Hospital at Sichuan University

Correspondence to: Bing Peng, MD, PhD, Department of Hepato-Biliary-Pancreatic Surgery, West China Hospital, Sichuan University, No. 37, Guoxue Alley, Chengdu 610041, Sichuan Province, China. pengbing84@hotmail.com

Telephone: +86-28-85433477 Fax: +86-28-85433474

Received: September 9, 2013 Revised: November 8, 2013

Accepted: November 28, 2013

Published online: January 14, 2014

Abstract

AIM: To evaluate the feasibility, safety, and effectiveness of consecutive laparoscopic cholecystectomy (LC) plus splenectomy (LS) in liver cirrhosis patients.

METHODS: From 2003 to 2013, 17 (group 1) patients with liver cirrhosis complicated by hypersplenism and symptomatic gallstones were treated with combined LC and LS, while 58 (group 2) patients with liver cirrhosis and hypersplenism received LS alone. An additional 14 (group 3) patients who received traditional open procedures during the same period were included as controls. Data were retrospectively collected and reviewed in regard to demographic characteristics and preoperative, intraoperative and postoperative features. Differences between the three groups were assessed by

statistical analysis.

RESULTS: The three groups showed no significant differences in the demographic characteristics or preoperative status. However, the patients treated with LC and LS required significantly longer operative time, shorter postoperative stay as well as shorter time of return to the first oral intake, and suffered less intraoperative blood loss as well as fewer postoperative surgical infections than the patients treated with traditional open procedures (group 1 vs group 3, $P < 0.05$ for all). The patients treated with LC and LS showed no significant differences in the intraoperative and postoperative variables from those treated with LS alone (group 1 vs group 2). All patients showed significant improvements in the haematological responses (preoperative period vs postoperative period, $P < 0.05$ for all). None of the patients treated with LC and LS presented with any gallstone-associated symptoms following discharge, while the patients treated with the traditional open procedures expressed complaints of discomfort related to their surgical incisions.

CONCLUSION: Consecutive LC and LS is an appropriate treatment option for liver cirrhosis patients with gallstones and hypersplenism, especially for those with Child-Pugh A and B.

© 2014 Baishideng Publishing Group Co., Limited. All rights reserved.

Key words: Laparoscopic cholecystectomy; Laparoscopic splenectomy; Liver cirrhosis; Hypersplenism; Open surgery

Core tip: Cholelithiasis occurs more frequently in liver cirrhosis patients with hypersplenism than in the general population. The recent significant advances in minimally invasive surgery have aroused surgeons' interest in performing combined laparoscopic procedures. Here, we report our experience with concomitant laparoscopic

ic cholecystectomy and splenectomy in liver cirrhosis patients. This is the first reported case series of its kind and will provide useful clinical information to physicians facing the challenge of treating cirrhotic patients who are in need of surgical attention to address coexisting abdominal diseases.

Wang MJ, Li JL, Zhou J, Wu Z, Peng B. Consecutive laparoscopic gallbladder and spleen resections in cirrhotic patients. *World J Gastroenterol* 2014; 20(2): 546-554 Available from: URL: <http://www.wjgnet.com/1007-9327/full/v20/i2/546.htm> DOI: <http://dx.doi.org/10.3748/wjg.v20.i2.546>

INTRODUCTION

The incidence of gallbladder stones in liver cirrhosis patients is two-fold higher than the estimates for the general population^[1,2]. Underlying risk factors for this co-morbidity are associated with dysfunction of gallbladder motility and emptying, hypersplenism, increased haemolysis, and enhanced circulating oestrogen levels^[1,3]. Considering the significant intraoperative blood loss that accompanies portal hypertension, liver cirrhosis was classified as a contraindication to laparoscopic cholecystectomy (LC) in the early 1990s^[4].

Since the first study of LC in patients with liver cirrhosis was reported in 1993^[5], extensive clinical data pertaining to this topic have been included in the publicly available literature; in general, these data have demonstrated that LC can be performed safely in liver cirrhosis patients^[6-9]. On the other hand, hypersplenism resulting in thrombocytopenia and leukopenia is a common complication observed in patients with liver cirrhosis complicated by portal hypertension^[10]. Splenectomy should be considered for these patients, to avoid fatal bleeding. Several recent studies have demonstrated the feasibility, safety, and effectiveness of laparoscopic splenectomy (LS) in patients with hypersplenism secondary to liver cirrhosis, and the results of short- and long-term outcomes attained with this procedure are encouraging^[11-13].

To help maximize the safety of consecutive gallbladder and spleen resections using the conventional open procedures, a wide upper abdominal incision is required. Technical advances in laparoscopic surgery have prompted surgeons to develop combination approaches for simultaneous treatment of coexisting abdominal diseases^[14-17]. However, few studies have systematically assessed the risks and benefits of LC plus LS in treating liver cirrhosis patients, which aroused our interest in performing the study described herein.

MATERIALS AND METHODS

Patients

Between 2003 and 2013, the procedure of concomitant cholecystectomy and splenectomy was performed on 51

liver cirrhosis patients with hypersplenism and/or portal hypertension as well as gallbladder stones at the Department of Hepato-Biliary-Pancreatic Surgery of the West China Hospital of Sichuan University. Among them, 19 patients received the laparoscopic procedures while the remaining 32 were treated with the open procedures. Twenty of the total patients who underwent other surgeries (radiofrequency ablation for hepatocarcinoma, herniorrhaphy for hernia, liver resection for hepatocarcinoma, or biliary duct exploration) were excluded from analysis. Therefore, 17 of the patients who received LC and LS were included as group 1, while 14 of the patients who received open cholecystectomy and splenectomy were included as group 3. An additional 58 liver cirrhosis patients with hypersplenism and/or portal hypertension who had received LS only between 2003 and 2013 were included as group 2. The inclusion and exclusion criteria are detailed in Figure 1. Written informed consent was obtained from all study participants, and the study was approved by the Ethics Committee of Sichuan University.

Diagnosis and indications

Diagnosis was made according to the patient's clinical history (hepatitis B or C, schistosome infection, and alcohol abuse), results from blood tests (thrombocytopenia, leukopenia or/and anaemia), computed tomography (CT) scans, B-ultrasound examinations (enlarged spleen, abnormal hepatic shape, size and edges with/without gastroesophageal varices, and gallstones) and postoperative pathological examinations (stages on a four-point Metavir scoring scale^[18]: F0, no fibrosis; F1, portal fibrosis without septa; F2, portal fibrosis and few septa; F3, numerous septa without cirrhosis; F4, cirrhosis). Indications for splenectomy were as follows: (1) severe thrombocytopenia due to hypersplenism with a platelet count $< 30 \times 10^9/L$ and/or a white blood cell count $< 3 \times 10^9/L$; and (2) being prone to oesophageal variceal haemorrhage as a result of severe portal hypertension. Cholecystectomy was taken into consideration when the diagnosis of symptomatic cholelithiasis was established on the basis of clinical presentations and confirmed by CT scans or B-ultrasound examinations.

Perioperative surveillance

Craniocaudal splenic length was measured preoperatively using CT scanning. B-ultrasound examinations were selectively applied in addition to the CT scan to detect gallbladder stones. The Child-Pugh class and the American Society of Anaesthesiologists (ASA) classification systems were applied respectively for evaluating the liver reserve function and the anaesthetic risk preoperatively. Laboratory data, including peripheral blood counts (haemoglobin, leukocytes, platelets, and prothrombin time), total bilirubin (TBil), aspartate aminotransferase (AST), alanine aminotransferase (ALT), and albumin (ALB) concentrations were obtained before surgery and on postoperative days (POD) 1, 3, and 5. Seven days of postopera-

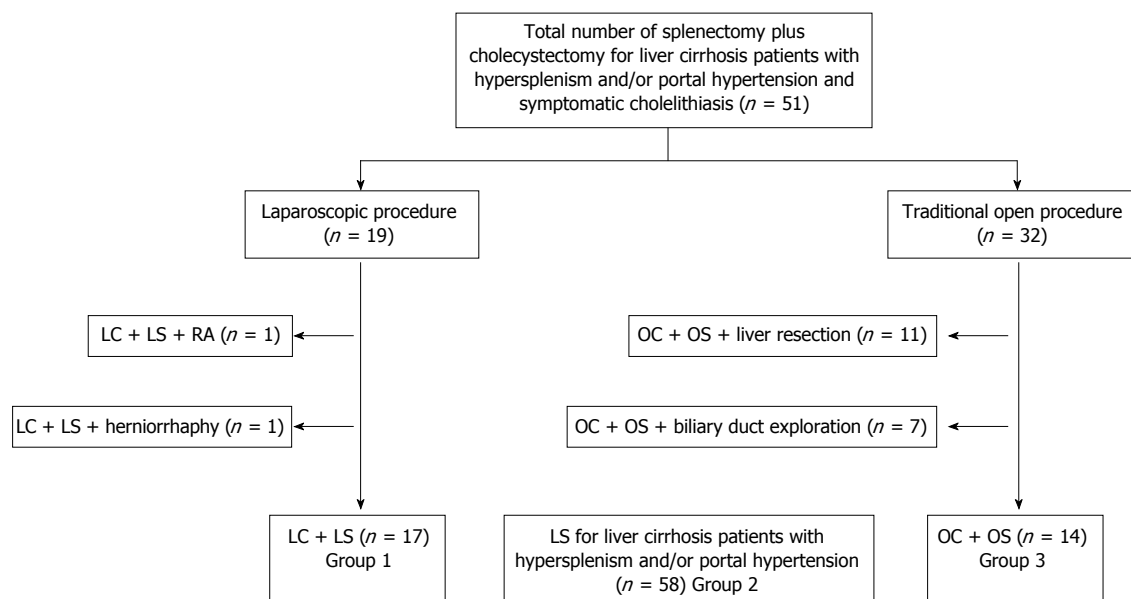


Figure 1 Inclusion and exclusion criteria for study participation. LC: Laparoscopic cholecystectomy; LS: Laparoscopic splenectomy; OC: Open cholecystectomy; OS: Open splenectomy; RA: Radiofrequency ablation.

tive surveillance were performed for portal or splenic vein thrombosis (PSVT), biliary and pancreatic leakage (all by B-ultrasound; following detection of PSVT with B-ultrasound, CT scanning was performed to make a definite diagnosis), and fluid drainage. After discharge, patients were recommended to undergo B-ultrasound or CT scanning once a month for the following 3 mo to monitor PSVT.

Surgical techniques

All of the operations were performed by a single team with a chief physician who is expert at LS^[19]. First, the LC procedure was carried out in a three-trocar manner with the patient in the supine position and with the operation table tilted to the left. After establishment of pneumoperitoneum with a pressure of 14 mmHg CO₂, the first 10 mm trocar for laparoscopy was inserted in the lower umbilicus. A 12 mm subxiphoid trocar and a 5 mm right subcostal margin trocar were then added for resections of the gallbladder and a 1 cm × 1 cm piece of hepatic tissue. Subsequently, the patients were placed in a right semi-decubitus position with the left side elevated 45–60 ° and with the operating table slightly tilted to the reverse Trendelenburg position. Two other trocars were then placed at the left mid-clavicular line below the inferior margin of the spleen (12 mm), and at the left axillary line below the inferior pole of the spleen (5 mm). Splenic attachments and ligaments were dissected using an ultrasonic dissector or the LigaSureTM Vessel Sealing System (Covidien, Mansfield, MS, United States) in the order of splenogastric ligament, splenic flexure attachment, splenorenal ligament, and splenophrenic ligament. After the spleen was released from the attachments and ligaments, an endoscopic linear vascular stapler was applied to transect the splenic hilar pedicles. The mobilized spleen was

placed into a retrieval bag, mechanically morcellated with forceps, and retracted from the 12 mm trocar site. A suction drain was placed in the splenic fossa, while another one was placed at the site of Calot's triangle.

For the traditional open procedure, left and right subcostal incisions were required. The details of the open splenectomy and the single LS were described previously^[11]; the open cholecystectomy was performed in the antegrade or retrograde manner.

Statistical analysis

Patients' complete medical records were retrospectively collected and reviewed, including demographic characteristics and information related to the preoperative (ASA classification, Child-Pugh class, splenic size, complete blood count, liver function index, and aetiology of cirrhosis), intraoperative (conversion rate, operative time, transfusion rate, estimated blood loss, and additional operations) and postoperative (postoperative stay, time to the first oral intake, histologic fibrosis stage, complete blood count, liver function index, and short-term complications) periods.

Continuous numerical variables are expressed as mean ± SD or median and interquartile, while categorical data are presented as number of cases and percentage. All statistical analyses were carried out using the SPSS statistical software package (version 16.0; SPSS Inc., Chicago, IL, United States) and included the Student's *t*, nonparametric Mann-Whitney *U*, χ^2 , and Fisher's exact tests, with rejection level for the null hypothesis set at a *P*-value of < 0.05.

RESULTS

As presented in Table 1, comparisons of group 1 with

Table 1 Demographic characteristics and preoperative information

| Variable | Group 1 | Group 2 ¹ | Group 3 ² |
|---------------------------------|----------------------|-----------------------|-----------------------|
| Cases | 17 | 58 | 14 |
| Sex (M/F) | 10/7 | 26/32 | 8/6 |
| Age (yr) | 55.9 ± 12.9 | 49.7 ± 14.5 | 50.8 ± 7.6 |
| ASA classification | | | |
| II | 1 | 13 | 0 |
| III | 15 | 42 | 13 |
| IV | 1 | 3 | 1 |
| Child-Pugh class | | | |
| A | 7 | 37 | 10 |
| B | 10 | 19 | 4 |
| C | 0 | 2 | 0 |
| Splenic size (cm) | 24.8 ± 6.8 | 22.1 ± 4.9 | 24.6 ± 3.3 |
| Laboratory data | | | |
| HGB (g/L) | 96.0 (86.0-128.0) | 111.5 (91.5-125.0) | 116.0 (93.0-133.5) |
| Platelet (× 10 ⁹ /L) | 34.0 (27.0-38.5) | 37.0 (27.0-44.5) | 37.5 (32.0-51.0) |
| WBC (× 10 ⁹ /L) | 2.0 (1.7-3.2) | 2.2 (1.7-3.0) | 2.6 (1.7-3.5) |
| Total bilirubin (mmol/L) | 24.2 (14.3-39.6) | 21.0 (16.0-25.3) | 16.3 (15.5-19.1) |
| AST (IU/L) | 50.0 (24.5-83.0) | 31.5 (22.0-45.8) | 38.5 (30.3-47.0) |
| ALT (IU/L) | 34.0 (25.0-74.0) | 33.5 (25.8-50.3) | 33.0 (25.0-42.5) |
| ALB (g/L) | 37.5 (34.2-39.5) | 38.3 (34.8-40.8) | 39.6 (36.6-42.2) |
| Prothrombin time (s) | 13.2 (12.5-15.1) | 12.9 (11.2-14.9) | 13.8 (12.3-14.7) |
| Diagnoses | | | |
| Posthepatic cirrhosis | 17 | 51 | 11 |
| Alcoholic cirrhosis | 0 | 4 | 1 |
| Schistosomiasis cirrhosis | 0 | 3 | 2 |

Data are expressed as absolute median (range) or mean ± SD. No significant differences were detected for ¹group 1 *vs* group 2 or ²group 1 *vs* group 3. ASA: American Society of Anaesthesiologists; HGB: Haemoglobin; WBC: White blood cell; AST: Aspartate aminotransferase; ALT: Alanine aminotransferase; ALB: Albumin.

groups 2 and 3 revealed no significant differences in terms of demographic characteristics (sex and age), distributions of ASA classification and Child-Pugh class, as well as diagnoses, splenic size, and preoperative laboratory data. The entire study population consisted of 89 patients (44 males and 45 females; mean age: 52.7 ± 13.8 years), 17 of whom were intended to receive LC plus LS. Preoperative evaluations of anaesthetic risk and liver reserve function showed that there were 14 (15.7%), 70 (78.7%) and 5 (5.6%) patients classified as ASA II, III and IV, while 54 (60.7%), 33 (37.1%) and 2 (2.2%) patients fell into to Child-Pugh A, B and C categories. Chronic hepatitis B or C (79 patients, 88.8%) was the leading cause of liver cirrhosis, while excessive alcohol consumption (5 patients, 5.6%) and schistosomiasis (5 patients, 5.6%) also contributed to liver damage in the study population.

Table 2 details the intraoperative information. The concomitant LC and LS procedure was successfully performed in 16 patients in group 1, with a conversion rate of 5.9%. The single case in group 1 that had to be con-

Table 2 Intraoperative information

| Variable | Group 1 | Group 2 | Group 3 | P ¹ |
|----------------------|---------------|---------------|---------------|----------------|
| Conversion rate | 1 (5.9) | 3 (5.2) | ND | ND |
| Operative time (min) | 221.2 ± 44.8 | 218.0 ± 58.4 | 166.4 ± 64.5 | 0.009 |
| Transfusion rate | 3 (17.6%) | 8 (13.8%) | 5 (35.7%) | NS |
| EBL (mL) | 225.9 ± 195.7 | 170.2 ± 130.2 | 421.4 ± 234.3 | 0.017 |
| Additional operation | | | | |
| Liver biopsy | 17 | 58 | 14 | ND |

Data are expressed as *n* (%) or mean ± SD. ¹Group 1 *vs* group 3. EBL: Estimated blood loss; NS: No significance; ND: Analysis not done.

Table 3 Postoperative information

| Variable | Group 1 | Group 2 | Group 3 | P ¹ |
|-----------------------------------|-----------|-----------|------------|----------------|
| Postoperative stay (d, mean ± SD) | 8.7 ± 2.6 | 7.8 ± 1.8 | 11.3 ± 2.9 | 0.013 |
| Oral intake (d, mean ± SD) | 2.8 ± 1.4 | 2.2 ± 0.9 | 4.3 ± 1.1 | 0.004 |
| Histologic fibrosis stage | | | | NS |
| F3 | 5 | 11 | 4 | ND |
| F4 | 12 | 45 | 9 | ND |
| Short-term complications | | | | |
| CBD injury | 0 | ND | 0 | ND |
| Bile leakage | 0 | ND | 0 | ND |
| Splenic fossa collection | 1 | 1 | 0 | ND |
| Pleural effusion | 1 | 4 | 2 | ND |
| Pulmonary infection | 1 | 3 | 3 | ND |
| Incision infection | 0 | 0 | 2 | ND |
| Pancreatic leakage | 2 | 8 | 1 | ND |
| Portal or splenic vein thrombosis | 2 | 4 | 1 | ND |
| Postoperative bleeding | 1 | 2 | 0 | ND |
| Total | 8 | 22 | 9 | ND |

¹Group 1 *vs* group 3. CBD: Common bile duct; NS: No significance; ND: analysis not done.

verted to the open procedure was mainly due to bleeding from the splenic hilar vessels when transecting the splenic pedicle with the endoscopic linear vascular stapler in the narrow intra-abdominal space. For the same reason, the conversion rate in group 2, comparable to that in group 1, was 5.2%, suggesting that LC did not increase the rate when performing the laparoscopic combined surgery. The operative time, transfusion rate, and estimated blood loss were similar between groups 1 and 2. Compared with group 3, patients in group 1 required longer operative time (221.2 ± 44.8 min *vs* 166.4 ± 64.5 min, *P* = 0.009) and suffered less intraoperative blood loss (225.9 ± 195.7 mL *vs* 421.4 ± 234.3 mL, *P* = 0.017), while the transfusion rate was comparable between these two groups. Liver biopsy was performed in all patients for postoperative pathological examinations.

The postoperative information is presented in Table 3. Comparisons of groups 1 and 2 showed no differences in terms of postoperative stay, and time to the first oral intake. Comparing group 1 with group 3, the length of postoperative stay was shorter (8.7 ± 2.6 d *vs* 11.3 ± 2.9 d, *P* = 0.013) as was the time of return to the first oral intake (2.8 ± 1.4 d *vs* 4.3 ± 1.1 d, *P* = 0.004). Pathological results of liver biopsies taken during splenectomy indicated that most of the histological fibrosis stages belonged

Table 4 Dynamic changes of haematological and liver function parameters perioperatively

| Parameter | Preoperative | POD 1 | POD 3 | POD 5 |
|------------------------------|--------------------|-------------------------------|---------------------------------|----------------------------------|
| HGB (g/L) | | | | |
| Group 1 | 96.0 (86.0-128.0) | 102.0 (86.0-119.5) | 108.0 (89.5-118) | 105.0 (88.5-115.5) |
| Group 2 | 111.5 (91.5-125.0) | 107.0 (92.8-119.0) | 102.0 (90.8-118.0) | 105.5 (93.8-120.3) |
| Group 3 | 116.0 (93.0-133.5) | 101.0 (91.3-126.3) | 105.5 (88.3-127.3) | 111.5 (89.8-123.5) |
| Platelet ($\times 10^9/L$) | | | | |
| Group 1 | 34.0 (27.0-38.5) | 63.0 (39.5-81.0) ^a | 105.0 (50.0-175.5) ^a | 184.0 (127.5-303.0) ^a |
| Group 2 | 37.0 (27.0-44.5) | 63.0 (42.0-79.0) ^a | 115.0 (74.3-160.5) ^a | 192.0 (130.8-307.3) ^a |
| Group 3 | 37.5 (32.0-51.0) | 54.0 (41.8-78.8) ^a | 118.0 (59.8-138.5) ^a | 242.5 (110.0-285.3) ^a |
| WBC ($\times 10^9/L$) | | | | |
| Group 1 | 2.0 (1.7-3.2) | 11.1 (8.1-14.9) ^a | 10.5 (8.1-12.5) ^a | 9.1 (7.3-10.6) ^a |
| Group 2 | 2.2 (1.7-2.9) | 11.1 (8.9-13.3) ^a | 10.4 (8.4-13.8) ^a | 8.6 (6.7-10.4) ^a |
| Group 3 | 2.6 (1.7-3.5) | 13.3 (10.2-14.9) ^a | 12.1 (8.9-15.3) ^a | 9.2 (7.6-11.1) ^a |
| TBil (mmol/L) | | | | |
| Group 1 | 24.2 (14.3-39.6) | 27.8 (14.5-34.6) | 21.3 (17.3-35.5) | 24.0 (17.3-30.3) |
| Group 2 | 21.0 (16.0-25.3) | 21.8 (14.5-31.0) | 20.1 (13.5-26.7) | 19.5 (12.8-28.0) |
| Group 3 | 16.3 (15.5-19.1) | 15.1 (12.0-20.0) | 24.3 (15.0-31.7) | 19.4 (13.5-26.7) |
| ALT (IU/L) | | | | |
| Group 1 | 34.0 (25.0-74.0) | 43.0 (28.5-99.0) | 40.0 (31.5-57.5) | 42.0 (26.0-58.0) |
| Group 2 | 33.5 (25.8-50.3) | 32.5 (27.8-53.3) | 33.5 (24.8-54.0) | 31.5 (21.8-43.0) |
| Group 3 | 33.0 (25.0-42.5) | 37.5 (26.8-75.8) | 34.0 (27.5-57.0) | 32.0 (20.2-54.5) |
| AST (IU/L) | | | | |
| Group 1 | 50.0 (24.5-83.0) | 52.0 (42.5-91.0) | 43.0 (26.5-54.0) | 34.0 (28.0-58.5) |
| Group 2 | 31.5 (22.0-45.8) | 44.5 (34.8-64.0) | 38.5 (28.0-53.0) | 33.5 (26.0-49.0) |
| Group 3 | 38.5 (30.3-47.0) | 47.0 (41.8-83.0) | 40.5 (33.5-71.5) | 38.5 (24.5-55.0) |
| ALB (g/L) | | | | |
| Group 1 | 37.5 (34.2-39.5) | 29.0 (26.8-32.5) ^a | 31.6 (28.9-32.9) ^a | 32.4 (30.5-35.5) ^a |
| Group 2 | 38.3 (34.8-40.8) | 31.5 (28.0-34.7) ^a | 32.3 (29.5-35.1) ^a | 34.2 (31.9-38.0) ^a |
| Group 3 | 39.6 (36.6-42.2) | 27.8 (25.9-33.2) ^a | 35.3 (31.9-36.5) ^a | 34.5 (30.0-38.1) ^a |

^a $P < 0.05$ vs preoperative status within the group. HGB: Haemoglobin; WBC: White blood cell; TBil: Total bilirubin; ALT: Alanine aminotransferase; AST: Aspartate aminotransferase; ALB: Albumin; POD: Postoperative days.

to F3 (numerous septa without cirrhosis) or F4 (cirrhosis), and no significant differences regarding the stage distribution among the three groups were detected.

In regard to short-term surgical complications, given that one patient may suffer more than one complication, the events were recorded numerically instead of as a complication rate. Fortunately, no one suffered common bile duct injury or bile leakage. The detailed data of other complications are presented in Table 3. Although the complication rate was not calculated, a trend was observed towards more pulmonary and incision infections occurring in the patients who received open surgery. All of the complications were resolved by conservative treatments, except the two cases of splenic fossa collections and the five cases (one in group 1, three in group 2, and one in group 3) of the seven pleural effusions which required punctured drainage guided by B-ultrasound, and the two patients in group 2 who suffered postoperative bleeding that required emergency laparotomy and blood transfusions.

Table 4 shows the dynamic changes of haematological and liver function parameters from the perioperative period. No obvious perioperative changes were observed for haemoglobin, AST, ALT and TBil levels. The platelet counts, however, gradually ascended to the normal range on POD 5 for all groups. The changes of the leukocyte counts rapidly ascended at first and then gradually descended to the normal range. A similar trend was ob-

served for ALB, but the levels reached on POD 5 were slightly lower than the normal range for all groups.

None of the patients in group 1 presented any gallstone-associated symptoms following discharge, while the patients in group 3 expressed complaints of discomfort related to their surgical incisions.

DISCUSSION

LC application was restricted by several contraindications, including liver cirrhosis, according to the consensus statement issued by the National Institutes of Health (NIH) in 1993^[20]. Since the first report of LC was published by Yerdel *et al*^[5] in 1993, the literature pertaining to this procedure as a treatment in liver cirrhosis patients has grown substantially. In general, the studies have indicated that early liver cirrhosis patients with symptomatic gallstones could undergo LC safely, without any significant increase in morbidity and mortality; moreover, performing LC in patients with advanced cirrhosis should be seriously considered^[3,7,21-24]. Additionally, the past decade has seen substantial progress in the understanding of the risks and benefits of LS in patients with hypersplenism secondary to liver cirrhosis, with studies providing encouraging surgical outcomes of this mini-invasive procedure^[11,25]. As surgeons' experience in applying LS increased, so did the interest in using this procedure in a consecutive approach to cope with the challenging conditions of coexisting ab-

Table 5 Reports in the literature of laparoscopic cholecystectomy plus laparoscopic splenectomy

| Ref. | Year | n | Main diagnosis | Surgical sequence | Conversion rate | Morbidity |
|---------------------------------------|------|----|---|-------------------|-----------------|----------------|
| Trias <i>et al</i> ^[26] | 1994 | 1 | Hereditary spherocytosis | LC → LS | NR | NR |
| Patton <i>et al</i> ^[15] | 1997 | 1 | Hereditary spherocytosis | LC → LS | NR | Atelectasis |
| Caprotti <i>et al</i> ^[31] | 1999 | 7 | Hereditary spherocytosis | LC → LS | NR | NR |
| Brink <i>et al</i> ^[32] | 2003 | 1 | Autoimmune haemolytic anaemia | LC → LS | NR | PSVT |
| Rossi <i>et al</i> ^[34] | 2007 | 1 | Congenital haemolytic anaemia | NR | NR | PSVT |
| Choi <i>et al</i> ^[33] | 2007 | 2 | Hereditary spherocytosis | LC → LS | NR | NR |
| Sasaki <i>et al</i> ^[14] | 2010 | 9 | Hereditary spherocytosis (n = 4) Splenic artery aneurysm (n = 2) Hypersplenism with liver cirrhosis (n = 2) Evans syndrome (n = 1) | LS → LC | NR | PSVT |
| Nobili <i>et al</i> ^[16] | 2011 | 30 | Hereditary spherocytosis (n = 22) Thalassemia (n = 4) Idiopathic thrombocytopenic purpura (n = 3) Sickle cell disease (n = 1) | LC → LS | 1 (3.3%) | Hemoperitoneum |

PSVT: Portal or splenic vein thrombosis; NR: Not reported; LC: Laparoscopic cholecystectomy; LS: Laparoscopic splenectomy.

dominal diseases.

The first study regarding concomitant LC and LS was reported in 1994^[26]. Since then only a few additional studies have been reported in the literature (Table 5), and almost all have enrolled only a few patients with benign haematological disorders. The current study analysed 17 liver cirrhosis patients with gallstones who received LC plus LS and compared the surgical outcomes between laparoscopic and open procedures. Similar to the other studies that have compared these two procedures, the conclusion was drawn that patients benefited from the mini-invasive surgery in terms of shorter postoperative stay, less intraoperative blood loss, faster return to oral intake, better cosmetic outcome, and fewer surgical infections.

Cirrhotic patients are often treated with operative interventions when they suffer from concomitant late stage gallbladder disease, which had led to severe chronic cholecystitis. Consequently, in addition to the risks associated with liver cirrhosis itself, the woody and friable gallbladder tissue has represented a challenge to surgeons during LC. Bearing in mind that the periumbilical colaterals and the falciform ligament might be sources of bleeding in these patients^[27-29], the trocar for laparoscopy is recommended to be placed in the lower umbilicus. Furthermore, according to our clinical experience, ultrasonic shears are recommended for division to avoid bleeding from dilated tortuous veins around the gallbladder. Nonetheless, it is dangerous and difficult to resect the gallbladder from the cirrhotic liver bed, which is easily injured and bleeds profusely. In this case, laparoscopic subtotal cholecystectomy (LSC), with the posterior wall of the gallbladder left on the cirrhotic liver bed, may be a better treatment choice^[9,27,28,30]. The major disadvantage of LSC is the high rate (38.1%-94.1%) of bile leakage from the closed stump^[27]. None of the patients in the current study received LSC or suffered bile leakage, which may be attributed to appropriate patient selection and sufficient preoperative assessment.

In the current study, the LS procedure was performed

consecutively to the LC procedure during the same operative period. While some studies support performing the procedures in this order, others do not^[14-16,26,31-34]; the main advantage of performing the LC procedure first is that it has a relatively low conversion rate. Indeed, in our case series one patient required conversion during the LS procedure and a left subcostal incision was required. In addition, four patients (one in group 1 and three in group 2) had to be converted to the open procedures, due to bleeding from the splenic pedicle during LS. The overall conversion rate of 5.3% is in line with that reported previously^[35]. It has also been reported that preoperative splenic artery embolization (SAE) could reduce operative time, intraoperative blood loss, and the need for transfusion during LS^[36,37]; however, because of serious complications, such as severe pain, pancreatitis, atelectasis and microcoil migration, the application of this approach before LS remains controversial^[38,39]. None of the patients in the current study received preoperative SAE.

A variety of studies have focused on the development of PSVT after splenectomy, but the true incidence remains uncertain^[40]. This complication is described as an uncommon but fatal occurrence and has been reported to result from some combination of hypercoagulability, platelet activation, disturbance and activation of the endothelium, and altered lipid profiles^[41]. It is difficult to make early clinical diagnoses of PSVT because of the non-specific symptom profile, which includes fever, abdominal pain and vomiting^[42-44], and potential asymptomatic profile^[45]. Encouragingly, hidden PSVT may be detected by Doppler ultrasound or CT scans. The first report of PSVT after LC plus LS was published in 2003^[32], and in the current study seven patients (7.9%) suffered postoperative PSVT. The rate of PSVT was higher in group 1 (11.8%) than in group 2 (6.9%) and group 3 (7.1%), but the small sample size precluded our ability to determine whether concomitant LC and LS was a significant risk factor for this complication. In view of the potentially deadly outcome of PSVT, B-ultrasound was performed to monitor the development of throm-

bosis until POD 7, and B-ultrasound or CT scanning was performed once a month for 3 mo after discharge. Once a PSVT diagnosis was established, early anticoagulation therapy was initiated.

During laparoscopic procedures, a 12-14 mmHg CO₂ pneumoperitoneum is required for the establishment of a sufficient operative field^[46]. This method has been reported to lead to ischemia-reperfusion injury to the liver^[47], which may further damage the already impaired liver function. Some studies have demonstrated that pneumoperitoneum can cause postoperative increases in AST, ALT, bilirubin and prothrombin time^[48-50], but these results have not been consistent^[11,51]. In the current study, a 14 mmHg CO₂ pneumoperitoneum did not appear to result in significant postoperative changes in AST, ALT, or bilirubin; the reasons for this phenomenon are unknown. Therefore, different pressures of pneumoperitoneum should be used when performing laparoscopic surgeries to assess their impacts on liver function in the future studies.

Admittedly, our results could be affected by several potential biases, because this study was neither blinded nor randomized and the sample size was small. However, the preoperative information among the three groups was comparable (Table 1), which could balance the potential biases to some extent. A large-volume, prospective, and randomized study is necessary to confirm our findings.

In summary, based on this comparative study, consecutive LC and LS is not only feasible, safe and effective, but also a superior choice for liver cirrhosis patients with gallstones and hypersplenism, especially for those patients with Child-Pugh A and B.

COMMENTS

Background

Laparoscopic cholecystectomy (LC) was once contraindicated for liver cirrhosis patients due to well-developed collateral vessels and increased risk of bleeding, and the same was true for laparoscopic splenectomy (LS). However, the technical improvements in laparoscopic technique and accumulation of surgeons' experience have led clinicians to question this concept. An increasing number of studies have demonstrated the efficacy and safety of laparoscopic surgery for treating gallstones or hypersplenism in the patient population with liver cirrhosis. On the other hand, the incidence of gallbladder stones in liver cirrhosis patients has been estimated as two-fold higher than that in the general population. It is necessary to determine the efficacy and safety of consecutive resections of the gallbladder and spleen by laparoscopy in liver cirrhosis patients.

Research frontiers

To date, few comparable studies of LS plus LC in treating liver cirrhosis patients with gallstones and hypersplenism/portal hypertension have been reported. In the era of minimally invasive surgery, patients prefer to receive laparoscopic operations if possible. In the current study, the authors demonstrated the feasibility, safety, and effectiveness of consecutive LC and LS in treating liver cirrhosis patients with gallstones and hypersplenism.

Innovations and breakthroughs

This is the first report of laparoscopic treatment of hypersplenism/portal hypertension combined with gallstones in liver cirrhotic patients. The results represent good news to liver cirrhosis patients who are in need of surgical attention to address coexisting abdominal diseases.

Applications

This is the first case series of LC plus LS treatment in liver cirrhosis patients and will add value to the surgical literature. This study revealed that LC plus LS

may be a better treatment option for liver cirrhosis patients; however, long-term results need to be confirmed in a future study.

Terminology

Hypersplenism is a related hematologic syndrome leading to thrombocytopenia, neutropenia, or both, and frequently occurs in patients with liver cirrhosis due to portal hypertension. Higher incidence of gallstones have been reported in the population of patients with liver cirrhosis, and their development is associated with dysfunction of gallbladder motility and emptying, hypersplenism, increased haemolysis, and enhanced circulating oestrogen levels.

Peer review

This is an interesting novel comparative analysis of the perioperative outcomes of consecutive laparoscopic and open surgeries in treating liver cirrhosis patients with gallstones and hypersplenism.

REFERENCES

- Schwesinger WH, Kurtin WE, Levine BA, Page CP. Cirrhosis and alcoholism as pathogenetic factors in pigment gallstone formation. *Ann Surg* 1985; **201**: 319-322 [PMID: 3977433 DOI: 10.1097/0000658-198503000-00011]
- Silva MA, Wong T. Gallstones in chronic liver disease. *J Gastrointest Surg* 2005; **9**: 739-746 [PMID: 15862273 DOI: 10.1016/j.gassur.2004.09.041]
- Delis S, Bakoyiannis A, Madariaga J, Bramis J, Tassopoulos N, Dervenis C. Laparoscopic cholecystectomy in cirrhotic patients: the value of MELD score and Child-Pugh classification in predicting outcome. *Surg Endosc* 2010; **24**: 407-412 [PMID: 19551433 DOI: 10.1007/s00464-009-0588-y]
- Soper NJ. Effect of nonbiliary problems on laparoscopic cholecystectomy. *Am J Surg* 1993; **165**: 522-526 [PMID: 8480895 DOI: 10.1016/S0002-9610(05)80954-7]
- Yerdel MA, Tsuge H, Mimura H, Sakagami K, Mori M, Orita K. Laparoscopic cholecystectomy in cirrhotic patients: expanding indications. *Surg Laparosc Endosc* 1993; **3**: 180-183 [PMID: 8111553]
- Friel CM, Stack J, Forse A, Babineau TJ. Laparoscopic cholecystectomy in patients with hepatic cirrhosis: a five-year experience. *J Gastrointest Surg* 1999; **3**: 286-291 [PMID: 10481121 DOI: 10.1016/S1091-255X(99)80070-5]
- Quillin RC, Burns JM, Pineda JA, Hanseman D, Rudich SM, Edwards MJ, Tevar AD. Laparoscopic cholecystectomy in the cirrhotic patient: predictors of outcome. *Surgery* 2013; **153**: 634-640 [PMID: 23305593 DOI: 10.1016/j.surg.2012.11.012]
- Lledó JB, Ibañez JC, Mayor LG, Juan MB. Laparoscopic cholecystectomy and liver cirrhosis. *Surg Laparosc Endosc Percutan Tech* 2011; **21**: 391-395 [PMID: 22146159 DOI: 10.1097/SLE.0b013e31823b5096]
- Hamad MA, Thabet M, Badawy A, Mourad F, Abdel-Salam M, Abdel-Rahman Mel-T, Hafez MZ, Sherif T. Laparoscopic versus open cholecystectomy in patients with liver cirrhosis: a prospective, randomized study. *J Laparoendosc Adv Surg Tech A* 2010; **20**: 405-409 [PMID: 20518688 DOI: 10.1089/lap.2009.0476]
- Peck-Radosavljevic M. Hypersplenism. *Eur J Gastroenterol Hepatol* 2001; **13**: 317-323 [PMID: 11338057 DOI: 10.1097/00042737-200104000-00004]
- Cai YQ, Zhou J, Chen XD, Wang YC, Wu Z, Peng B. Laparoscopic splenectomy is an effective and safe intervention for hypersplenism secondary to liver cirrhosis. *Surg Endosc* 2011; **25**: 3791-3797 [PMID: 21681623 DOI: 10.1007/s00464-011-1790-2]
- Tomikawa M, Akahoshi T, Sugimachi K, Ikeda Y, Yoshida K, Tanabe Y, Kawanaka H, Takenaka K, Hashizume M, Maehara Y. Laparoscopic splenectomy may be a superior supportive intervention for cirrhotic patients with hypersplenism. *J Gastroenterol Hepatol* 2010; **25**: 397-402 [PMID: 19929930 DOI: 10.1111/j.1440-1746.2009.06031.x]
- Cobb WS, Heniford BT, Burns JM, Carbonell AM, Matthews BD, Kercher KW. Cirrhosis is not a contraindication to

- laparoscopic surgery. *Surg Endosc* 2005; **19**: 418-423 [PMID: 15624057 DOI: 10.1007/s00464-004-8722-3]
- 14 **Sasaki A**, Nitta H, Otuska K, Kimura Y, Obuchi T, Wakabayashi G. Concomitant laparoscopic splenectomy and cholecystectomy. *Surg Laparosc Endosc Percutan Tech* 2010; **20**: 66-68 [PMID: 20393329 DOI: 10.1097/SLE.0b013e3181d8493e]
 - 15 **Patton ML**, Moss BE, Haith LR, Shotwell BA, Milliner DH, Simeone MR, Kraut JD, Patton JN. Concomitant laparoscopic cholecystectomy and splenectomy for surgical management of hereditary spherocytosis. *Am Surg* 1997; **63**: 536-539 [PMID: 9168768]
 - 16 **Nobili C**, Romano F, Ciravegna AL, Garancini M, Degrate L, Uggeri F, Uggeri F. Consecutive concomitant laparoscopic splenectomy and cholecystectomy: an Italian experience of 30 patients and proposition of a technique. *J Laparoendosc Adv Surg Tech A* 2011; **21**: 313-317 [PMID: 21366441 DOI: 10.1089/lap.2010.0442]
 - 17 **Wadhwa A**, Chowbey PK, Sharma A, Khullar R, Soni V, Baijal M. Combined procedures in laparoscopic surgery. *Surg Laparosc Endosc Percutan Tech* 2003; **13**: 382-386 [PMID: 14712100 DOI: 10.1097/00129689-200312000-00007]
 - 18 Intraobserver and interobserver variations in liver biopsy interpretation in patients with chronic hepatitis C. The French METAVIR Cooperative Study Group. *Hepatology* 1994; **20**: 15-20 [PMID: 8020885]
 - 19 **Wu Z**, Zhou J, Cai YQ, Liu SA, Peng B. The learning curve for laparoscopic splenectomy for massive splenomegaly: a single surgeon's experience. *Chin Med J (Engl)* 2013; **126**: 2103-2108 [PMID: 23769566]
 - 20 National Institutes of Health Consensus Development Conference Statement on Gallstones and Laparoscopic Cholecystectomy. *Am J Surg* 1993; **165**: 390-398 [PMID: 8480870 DOI: 10.1016/S0002-9610(05)80929-8]
 - 21 **D'Albuquerque LA**, de Miranda MP, Genzini T, Copstein JL, de Oliveira e Silva A. Laparoscopic cholecystectomy in cirrhotic patients. *Surg Laparosc Endosc* 1995; **5**: 272-276 [PMID: 7551278]
 - 22 **Poggio JL**, Rowland CM, Gores GJ, Nagorney DM, Donohue JH. A comparison of laparoscopic and open cholecystectomy in patients with compensated cirrhosis and symptomatic gallstone disease. *Surgery* 2000; **127**: 405-411 [PMID: 10776431 DOI: 10.1067/msy.2000.104114]
 - 23 **Puggioni A**, Wong LL. A metaanalysis of laparoscopic cholecystectomy in patients with cirrhosis. *J Am Coll Surg* 2003; **197**: 921-926 [PMID: 14644279 DOI: 10.1016/j.jamcollsurg.2003.08.011]
 - 24 **Curro G**, Iapichino G, Melita G, Lorenzini C, Cucinotta E. Laparoscopic cholecystectomy in Child-Pugh class C cirrhotic patients. *JSLs* 2005; **9**: 311-315 [PMID: 16121878]
 - 25 **Watanabe Y**, Horiuchi A, Yoshida M, Yamamoto Y, Sugishita H, Kumagi T, Hiasa Y, Kawachi K. Significance of laparoscopic splenectomy in patients with hypersplenism. *World J Surg* 2007; **31**: 549-555 [PMID: 17308852 DOI: 10.1007/s00268-006-0504-8]
 - 26 **Trías M**, Targarona EM. Laparoscopic treatment of hereditary spherocytosis (splenectomy plus cholecystectomy). *J Laparoendosc Surg* 1994; **4**: 71-73 [PMID: 8173117 DOI: 10.1089/lps.1994.4.71]
 - 27 **Palanivelu C**, Rajan PS, Jani K, Shetty AR, Senthilkumar K, Senthilnathan P, Parthasarathi R. Laparoscopic cholecystectomy in cirrhotic patients: the role of subtotal cholecystectomy and its variants. *J Am Coll Surg* 2006; **203**: 145-151 [PMID: 16864026 DOI: 10.1016/j.jamcollsurg.2006.04.019]
 - 28 **Bessa SS**, Abdel-Razek AH, Sharaan MA, Bassiouni AE, El-Khishen MA, El-Kayal el-SA. Laparoscopic cholecystectomy in cirrhotics: a prospective randomized study comparing the conventional diathermy and the harmonic scalpel for gallbladder dissection. *J Laparoendosc Adv Surg Tech A* 2011; **21**: 1-5 [PMID: 21166564 DOI: 10.1089/lap.2010.0255]
 - 29 **Machado NO**. Laparoscopic cholecystectomy in cirrhotics. *JSLs* 2012; **16**: 392-400 [PMID: 23318064 DOI: 10.4293/108680812x13462882736493]
 - 30 **Cucinotta E**, Lazzara S, Melita G. Laparoscopic cholecystectomy in cirrhotic patients. *Surg Endosc* 2003; **17**: 1958-1960 [PMID: 14577023 DOI: 10.1007/s00464-002-8852-4]
 - 31 **Caprotti R**, Franciosi C, Romano F, Codecasa G, Musco F, Motta M, Uggeri F. Combined laparoscopic splenectomy and cholecystectomy for the treatment of hereditary spherocytosis: is it safe and effective? *Surg Laparosc Endosc Percutan Tech* 1999; **9**: 203-206 [PMID: 10804001 DOI: 10.1097/00129689-199906000-00010]
 - 32 **Brink JS**, Brown AK, Palmer BA, Moir C, Rodeberg DR. Portal vein thrombosis after laparoscopy-assisted splenectomy and cholecystectomy. *J Pediatr Surg* 2003; **38**: 644-647 [PMID: 12677588 DOI: 10.1053/jpsu.2003.50144]
 - 33 **Choi YS**, Han HS, Yoon YS, Jang JY, Kim SW, Park YH. Laparoscopic splenectomy plus cholecystectomy for treating hereditary spherocytosis combined with cholelithiasis in siblings. *Minim Invasive Ther Allied Technol* 2007; **16**: 317-318 [PMID: 17917996 DOI: 10.1080/13645700701384108]
 - 34 **Rossi E**, Michelini ME, Pignatti CB, Zanotti F, Franchella A. A case of portal vein thrombosis after laparoscopy-assisted splenectomy and cholecystectomy in a child. *J Pediatr Surg* 2007; **42**: 1449-1451 [PMID: 17706514 DOI: 10.1016/j.jpedsurg.2007.03.052]
 - 35 **Casaccia M**, Torelli P, Pasa A, Sormani MP, Rossi E. Putative predictive parameters for the outcome of laparoscopic splenectomy: a multicenter analysis performed on the Italian Registry of Laparoscopic Surgery of the Spleen. *Ann Surg* 2010; **251**: 287-291 [PMID: 20010087 DOI: 10.1097/SLA.0b013e3181bfda59]
 - 36 **Fujitani RM**, Johs SM, Cobb SR, Mehringer CM, White RA, Klein SR. Preoperative splenic artery occlusion as an adjunct for high risk splenectomy. *Am Surg* 1988; **54**: 602-608 [PMID: 3178046]
 - 37 **Hiatt JR**, Gomes AS, Machleder HI. Massive splenomegaly. Superior results with a combined endovascular and operative approach. *Arch Surg* 1990; **125**: 1363-1367 [PMID: 2222177 DOI: 10.1001/archsurg.1990.01410220147021]
 - 38 **Poulin E**, Thibault C, Mamazza J, Girotti M, Côté G, Renaud A. Laparoscopic splenectomy: clinical experience and the role of preoperative splenic artery embolization. *Surg Laparosc Endosc* 1993; **3**: 445-450 [PMID: 8269261]
 - 39 **Poulin EC**, Mamazza J, Schlachta CM. Splenic artery embolization before laparoscopic splenectomy. An update. *Surg Endosc* 1998; **12**: 870-875 [PMID: 9602009 DOI: 10.1007/s004649900732]
 - 40 **Romano F**, Caprotti R, Conti M, Piacentini MG, Uggeri F, Motta V, Pogliani EM, Uggeri F. Thrombosis of the splenoportal axis after splenectomy. *Langenbecks Arch Surg* 2006; **391**: 483-488 [PMID: 16909290 DOI: 10.1007/s00423-006-0075-z]
 - 41 **Crary SE**, Buchanan GR. Vascular complications after splenectomy for hematologic disorders. *Blood* 2009; **114**: 2861-2868 [PMID: 19636061 DOI: 10.1182/blood-2009-04-210112]
 - 42 **Plessier A**, Darwish-Murad S, Hernandez-Guerra M, Consigny Y, Fabris F, Trebicka J, Heller J, Morard I, Lasser L, Langlet P, Denninger MH, Vidaud D, Condat B, Hadengue A, Primignani M, Garcia-Pagan JC, Janssen HL, Valla D. Acute portal vein thrombosis unrelated to cirrhosis: a prospective multicenter follow-up study. *Hepatology* 2010; **51**: 210-218 [PMID: 19821530 DOI: 10.1002/hep.23259]
 - 43 **Rattner DW**, Ellman L, Warshaw AL. Portal vein thrombosis after elective splenectomy. An underappreciated, potentially lethal syndrome. *Arch Surg* 1993; **128**: 565-59; discussion 565-59; [PMID: 8489390 DOI: 10.1001/archsurg.1993.01420170101015]
 - 44 **Nagasue N**, Inokuchi K, Kobayashi M, Saku M. Mesenteric venous thrombosis occurring late after splenectomy. *Br J*

- Surg* 1977; **64**: 781-783 [PMID: 588970]
- 45 **Krauth MT**, Lechner K, Neugebauer EA, Pabinger I. The postoperative splenic/portal vein thrombosis after splenectomy and its prevention--an unresolved issue. *Haematologica* 2008; **93**: 1227-1232 [PMID: 18556406 DOI: 10.3324/haematol.12682]
 - 46 **Yoon HM**, Yang HK, Lee HJ, Park do J, Kim HH, Lee KU, Ahn HS, Jo JJ. Comparison of liver function after laparoscopically assisted and open distal gastrectomies for patients with liver disease. *Surg Endosc* 2011; **25**: 1761-1765 [PMID: 21424207 DOI: 10.1007/s00464-010-1449-4]
 - 47 **Leandros E**, Albanopoulos K, Tsigris C, Archontovasilis F, Panoussopoulos SG, Skalistira M, Bramis C, Konstandoulakis MM, Giannopoulos A. Laparoscopic cholecystectomy in cirrhotic patients with symptomatic gallstone disease. *ANZ J Surg* 2008; **78**: 363-365 [PMID: 18380734 DOI: 10.1111/j.1445-2197.2008.04478.x]
 - 48 **Tan M**, Xu FF, Peng JS, Li DM, Chen LH, Lv BJ, Zhao ZX, Huang C, Zheng CX. Changes in the level of serum liver enzymes after laparoscopic surgery. *World J Gastroenterol* 2003; **9**: 364-367 [PMID: 12532468]
 - 49 **Morino M**, Giraudo G, Festa V. Alterations in hepatic function during laparoscopic surgery. An experimental clinical study. *Surg Endosc* 1998; **12**: 968-972 [PMID: 9632872 DOI: 10.1007/s004649900758]
 - 50 **Andrei VE**, Schein M, Margolis M, Rucinski JC, Wise L. Liver enzymes are commonly elevated following laparoscopic cholecystectomy: is elevated intra-abdominal pressure the cause? *Dig Surg* 1998; **15**: 256-259 [PMID: 9845595 DOI: 10.1159/000018624]
 - 51 **Bickel A**, Weiar A, Eitan A. Evaluation of liver enzymes following elective laparoscopic cholecystectomy: are they really elevated? *J Gastrointest Surg* 2008; **12**: 1418-1421 [PMID: 18516716 DOI: 10.1007/s11605-008-0557-0]

P- Reviewers: Benarroch-Gampel J, Neuberger J

S- Editor: Ma YJ **L- Editor:** Wang TQ **E- Editor:** Zhang DN





Published by **Baishideng Publishing Group Co., Limited**

Flat C, 23/F., Lucky Plaza,

315-321 Lockhart Road, Wan Chai, Hong Kong, China

Fax: +852-65557188

Telephone: +852-31779906

E-mail: bpgoffice@wjgnet.com

<http://www.wjgnet.com>



ISSN 1007-9327

