

Endoscopic removal of a tablespoon lodged within the duodenum

Takashi Watanabe, Kunihiko Aoyagi, Yoshitaka Tomioka, Hideki Ishibashi, Shotaro Sakisaka

Takashi Watanabe, Kunihiko Aoyagi, Yoshitaka Tomioka, Hideki Ishibashi, Shotaro Sakisaka, Department of Gastroenterology and Medicine, Fukuoka University School of Medicine, Fukuoka 814-0180, Japan

Author contributions: Watanabe T and Aoyagi K designed the report; Watanabe T, Tomioka Y and Ishibashi H collected the patient's clinical data; Watanabe T, Aoyagi K and Sakisaka S wrote the paper.

Supported by Department of Gastroenterology and Medicine, Fukuoka University School of Medicine, Fukuoka, Japan.

Open-Access: This article is an open-access article which was selected by an in-house editor and fully peer-reviewed by external reviewers. It is distributed in accordance with the Creative Commons Attribution Non Commercial (CC BY-NC 4.0) license, which permits others to distribute, remix, adapt, build upon this work non-commercially, and license their derivative works on different terms, provided the original work is properly cited and the use is non-commercial. See: <http://creativecommons.org/licenses/by-nc/4.0/>

Correspondence to: Takashi Watanabe, MD, Department of Gastroenterology and Medicine, Fukuoka University School of Medicine, 7-45-1 Nanakuma, Jonan-ku, Fukuoka 814-0180, Japan. takashii@minf.med.fukuoka-u.ac.jp

Telephone: +81-92-8011011-3355

Fax: +81-92-8742663

Received: August 22, 2014

Peer-review started: August 23, 2014

First decision: September 15, 2014

Revised: September 30, 2014

Accepted: December 14, 2014

Article in press: December 16, 2014

Published online: April 28, 2015

proximal and distal parts of the handle. The double-snare was first pulled unsuccessfully and then pulled with simultaneous manual abdominal compression of the bulbus from the body surface. Compression was gently applied towards the stomach. As a result, the head of the spoon prolapsed from the bulbus, and was easily retracted from the stomach without any complications. In cases of foreign body lodging within the duodenum, the manual abdominal compression technique may help clinicians pull out the object and avoid surgery. The usefulness of manual compression is dependent on the foreign body's sharpness and the location.

Key words: Endoscopic removal; Tablespoon; Duodenum; Lodged

© **The Author(s) 2015.** Published by Baishideng Publishing Group Inc. All rights reserved.

Core tip: Here we report the case of endoscopic removal of a tablespoon from the stomach that was lodged within the duodenum. Only the double-snare technique was first performed unsuccessfully and then pulled with simultaneous manual abdominal compression of the bulbus from the body surface. Compression was gently applied toward the stomach. As a result, the head of the spoon prolapsed from the bulbus and was easily retracted from the stomach without any complications. The usefulness of manual compression is dependent on the foreign body's sharpness and location.

Abstract

Here we report the case of a 34-year-old man who underwent endoscopic removal of a tablespoon from the stomach that was lodged within the duodenum. Removal required the use of a two-channel upper endoscope and polypectomy snares. Using the double-snare technique, the spoon was grasped at the

Watanabe T, Aoyagi K, Tomioka Y, Ishibashi H, Sakisaka S. Endoscopic removal of a tablespoon lodged within the duodenum. *World J Gastroenterol* 2015; 21(16): 5096-5098 Available from: URL: <http://www.wjgnet.com/1007-9327/full/v21/i16/5096.htm> DOI: <http://dx.doi.org/10.3748/wjg.v21.i16.5096>

INTRODUCTION

Endoscopist has often encountered cases of foreign bodies in the gastrointestinal tract. Most foreign bodies pass spontaneously through the body, but 10%-20% require endoscopic removal and $\leq 1\%$ require surgery^[1,2]. Surgical removal can be avoided with correct endoscopic removal.

Here we present a successful case of endoscopic removal of a tablespoon from the stomach that had lodged within the duodenum. This report is the first to detail the removal of a foreign body lodged within the duodenum using the manual abdominal compression technique.

CASE REPORT

A 34-year-old man was admitted to our hospital for the removal of a metal spoon from the stomach. Five days previously, he was hospitalized with schizophrenia in another hospital and deliberately swallowed the spoon. Plain radiography of the abdomen revealed a large spoon within the stomach (Figure 1). Surprisingly, only the handle of the spoon was actually in the stomach (Figure 2), while the head of the spoon was lodged within the bulb of the duodenum. The entire spoon could not pass through the duodenum, so its handle extended to the wall of the lower part of the greater curvature of the stomach.

Using the double-snare technique, the spoon was grasped at the proximal and distal parts of the handle as described previously^[3]. The double-snare was first pulled unsuccessfully, followed by simultaneous pulling with manual abdominal compression of the bulbus from the body surface (Figure 3). The compression technique was gently performed toward the stomach. As a result, the head of spoon prolapsed from the bulbus. Furthermore, this patient had severe hiatal hernia, which allowed the distal portion of the handle to be easily retracted through the esophagocardial junction. The spoon was 18 cm long and 4.0 cm at its widest point (Figure 4). No complications such as hemorrhage or perforation were encountered.

DISCUSSION

In cases of foreign bodies in the gastrointestinal tract, treatments are chosen according to object type and location as well as the patient's general condition^[4]. It is especially necessary to confirm the foreign body's size, shape, and material^[5]. For example, long objects are generally difficult to extract from the stomach, while sharp foreign bodies present a high risk of mucosal injury including hemorrhage or perforation.

In the present case, the tablespoon was a long metallic object, prone to slipping and difficult to grasp^[6]. The polypectomy snare is considered useful for retrieving sharp objects^[7,8]. Spoon removal from the stomach utilizing the double-snare technique has

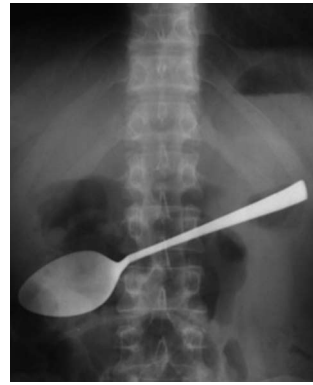

Figure 1 A plain radiograph of the abdomen revealing a tablespoon within the stomach.

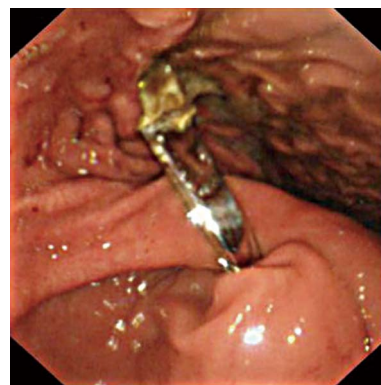


Figure 2 Endoscopic findings showing only the handle of the spoon in the stomach. The head of the spoon is incarcerated in the bulb of the duodenum.

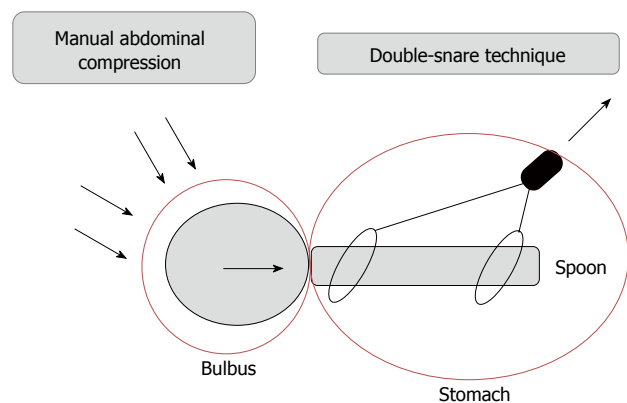


Figure 3 Image of the removal technique. The spoon was successfully removed by the combination of the double-snare technique as a pulling power and the manual abdominal compression as a pushing power.

been reported and its usefulness has been proven^[3].

However, since the head of the spoon was lodged in the bulbus of the duodenum, the extraction technique failed. Five days passed from the appearance of the condition, and the possibility of it spontaneously passing through the intestinal tract was low. If endoscopic extraction was not possible, the presence of the foreign body could cause pressure necrosis



Figure 4 The retrieved spoon.

of the bowel mucosa as well as hemorrhage and perforation^[9]. When a foreign body cannot be removed, surgery becomes the only option^[10]. In this case, it was possible to extract the spoon from the duodenum using the manual abdominal compression technique on the body surface. However, manual compression may be dangerous if a sharp foreign body perforates the duodenal wall. Therefore, the usefulness of manual compression is dependent on the foreign body's sharpness and location.

COMMENTS

Case characteristics

A 34-year-old man with a tablespoon which lodged within the duodenum.

Clinical diagnosis

Foreign body as a tablespoon which lodged within at the duodenum.

Imaging diagnosis

The head of the spoon is incarcerated in the bulbous of the duodenum.

Treatment

The foreign body was removed by the double-snare technique and manual abdominal compression technique.

Related reports

There are a lot of cases of the large foreign bodies removed in the gastrointestinal by endoscopy.

Experiences and lessons

The authors report the case of endoscopic removal of a tablespoon from the stomach that was lodged within the duodenum. The usefulness of manual compression is dependent on the foreign body's sharpness and the location.

Peer-review

This is a interesting case which performed endoscopic removal of a tablespoon from the stomach that was lodged within the duodenum.

REFERENCES

- 1 **Schwartz GF**, Polsky HS. Ingested foreign bodies of the gastrointestinal tract. *Am Surg* 1976; **42**: 236-238 [PMID: 1267274]
- 2 **Webb WA**. Management of foreign bodies of the upper gastrointestinal tract. *Gastroenterology* 1988; **94**: 204-216 [PMID: 3275566]
- 3 **Aoyagi K**, Maeda K, Morita I, Eguchi K, Nishimura H, Sakisaka S. Endoscopic removal of a spoon from the stomach with a double-snare and balloon. *Gastrointest Endosc* 2003; **57**: 990-991 [PMID: 12776067 DOI: 10.1016/S0016-5107(03)70044-3]
- 4 **Eisen GM**, Baron TH, Dominitz JA, Faigel DO, Goldstein JL, Johanson JF, Mallery JS, Raddawi HM, Vargo JJ, Waring JP, Fanelli RD, Wheeler-Harbaugh J. Guideline for the management of ingested foreign bodies. *Gastrointest Endosc* 2002; **55**: 802-806 [PMID: 12024131 DOI: 10.1016/S0016-5107(02)70407-0]
- 5 **Chaves DM**, Ishioka S, Félix VN, Sakai P, Gama-Rodrigues JJ. Removal of a foreign body from the upper gastrointestinal tract with a flexible endoscope: a prospective study. *Endoscopy* 2004; **36**: 887-892 [PMID: 15452785 DOI: 10.1055/s-2004-825856]
- 6 **Kethu SR**, Johnson C, Agrawal D. Rubber-sleeving a forceps for endoscopic removal of a flat, metallic foreign body. *Gastrointest Endosc* 2007; **66**: 393-394; discussion 394 [PMID: 17521638 DOI: 10.1016/j.gie.2006.12.029]
- 7 **Faigel DO**, Stotland BR, Kochman ML, Hoops T, Judge T, Kroser J, Lewis J, Long WB, Metz DC, O'Brien C, Smith DB, Ginsberg GG. Device choice and experience level in endoscopic foreign object retrieval: an in vivo study. *Gastrointest Endosc* 1997; **45**: 490-492 [PMID: 9199906 DOI: 10.1016/S0016-5107(97)70179-2]
- 8 **Chen SC**, Yu SC, Yuan RH, Chang KJ. Endoscopic removal of a large gastric metallic watch with a polypectomy snare loop. *Endoscopy* 1997; **29**: S55-S56 [PMID: 9476781 DOI: 10.1055/s-2007-1004333]
- 9 **James AH**, Allen-Mersh TG. Recognition and management of patients who repeatedly swallow foreign bodies. *J R Soc Med* 1982; **75**: 107-110 [PMID: 7069668]
- 10 **Wishner JD**, Rogers AM. Laparoscopic removal of a swallowed toothbrush. *Surg Endosc* 1997; **11**: 472-473 [PMID: 9153178 DOI: 10.1007/s004649900393]

P- Reviewer: Gomes CAR, Goncalves BM **S- Editor:** Yu J
L- Editor: A **E- Editor:** Zhang DN





Published by **Baishideng Publishing Group Inc**

8226 Regency Drive, Pleasanton, CA 94588, USA

Telephone: +1-925-223-8242

Fax: +1-925-223-8243

E-mail: bpgoffice@wjgnet.com

Help Desk: <http://www.wjgnet.com/esps/helpdesk.aspx>

<http://www.wjgnet.com>



ISSN 1007-9327



9 771007 932045