

Adenocarcinoma of the third and fourth portions of the duodenum: The capsule endoscopy value

Feliciano Chanana Paquissi, Ana Henriqueta Filipe Bunga Pimentel Lima,
Maria de Fátima do Nascimento Vieira Lopes, Francisco Viamontes Diaz

Feliciano Chanana Paquissi, Department of Medicine, Clínica Girassol, Luanda 1215, Angola

Ana Henriqueta Filipe Bunga Pimentel Lima, Service of Clinical Pathology, Clínica Girassol, Luanda 1215, Angola

Maria de Fátima do Nascimento Vieira Lopes, Service of Gastroenterology, Clínica Girassol, Luanda 1215, Angola

Francisco Viamontes Diaz, Department of General Surgery, Clínica Girassol, Luanda 1215, Angola

Author contributions: Paquissi FC and Lima AHFBP designed the report; Lopes MFNV performed the analyses of endoscopic aspects of the report; Paquissi FC collected the patient's clinical data; Lima AHFBP performed the analyses of pathological aspects of the report; Diaz FV performed the analyses of surgical aspects of the report; Paquissi FC and Lima AHFBP compiled the data and wrote the paper; all authors read and approved the final manuscript.

Open-Access: This article is an open-access article which was selected by an in-house editor and fully peer-reviewed by external reviewers. It is distributed in accordance with the Creative Commons Attribution Non Commercial (CC BY-NC 4.0) license, which permits others to distribute, remix, adapt, build upon this work non-commercially, and license their derivative works on different terms, provided the original work is properly cited and the use is non-commercial. See: <http://creativecommons.org/licenses/by-nc/4.0/>

Correspondence to: Feliciano Chanana Paquissi, MD, Resident of Department of Medicine, Clínica Girassol, Street Comandante Gika number 225, Luanda 1215, Angola. fepaquissi@gmail.com
Telephone: +55-11-949975972

Received: May 11, 2014

Peer-review started: May 12, 2014

First decision: June 10, 2014

Revised: July 8, 2014

Accepted: August 28, 2014

Article in press: August 28, 2014

Published online: August 21, 2015

Abstract

Primary adenocarcinoma of the small intestine occurs in over 50% of cases in the duodenum. However, its location in the third and fourth duodenal portions occurs rarely and is a diagnostic challenge. The aim of this work is to report an adenocarcinoma of the third and fourth duodenal portions, emphasizing its diagnostic difficulty and the value of video capsule endoscopy. A man, 40 years old, with no medical history, with abdominal discomfort and progressive fatigue, presented four months ago with one episode of moderate melena. The physical examination was normal, except for mucosal pallor. Blood tests were consistent with microcytic, hypochromic iron deficiency anemia with 7.8 g/dL hemoglobin. The upper and lower endoscopy were normal. Additional work-up with video capsule endoscopy showed a polypoid lesion involving the third and fourth portions of the duodenum. Biopsy showed a moderately differentiated adenocarcinoma. Abdominal computed tomography showed a wall thickening from the third duodenal portion to the proximal jejunum, without distant metastasis. The patient underwent segmental resection (distal duodenum and proximal jejunum) with duodenojejunostomy. The surgical specimen histology confirmed the biopsy diagnosis, with transmural infiltration, without nodal involvement. Conclusion: Adenocarcinoma of the third and fourth portions of the duodenum is difficult to diagnose and capsule endoscopy is of great value.

Key words: Duodenum; Duodenal cancer; Adenocarcinoma; Endoscopy; Video capsule endoscopy

© The Author(s) 2015. Published by Baishideng Publishing

Group Inc. All rights reserved.

Core tip: Third and/or fourth duodenal portion adenocarcinoma is a rare disease, associated with a vague clinical picture and a diagnostic challenge. Capsule endoscopy has shown a higher accuracy compared to conventional endoscopic methods. This case reports the occurrence of adenocarcinoma of the third and fourth duodenal portions and the value of capsule endoscopy to minimize the diagnostic difficulty.

Paquissi FC, Lima AHFBP, Lopes MFNV, Diaz FV. Adenocarcinoma of the third and fourth portions of the duodenum: The capsule endoscopy value. *World J Gastroenterol* 2015; 21(31): 9437-9441 Available from: URL: <http://www.wjgnet.com/1007-9327/full/v21/i31/9437.htm> DOI: <http://dx.doi.org/10.3748/wjg.v21.i31.9437>

INTRODUCTION

The small intestine is approximately 75% of the length and 90% of the mucosal surface of the gastrointestinal tract but represents only 2% to 5% of all primary malignant gastrointestinal tumors. Tumors in the small intestine are about 13 to 18 times less common than colon cancer, despite its exposure to a variety of endogenous and exogenous harmful substances^[1,2]. Histologically, there are four subtypes of malignant tumors of the small intestine: adenocarcinomas (around 40%); neuroendocrine tumors (35% to 40%); lymphomas (15%) and sarcomas (11% to 13%)^[3,4]. When distributed by segments, adenocarcinomas are more common in the duodenum and proximal jejunum, neuroendocrine tumors and lymphomas are more common in the distal portions, while sarcomas have diffuse distribution^[3,5].

Duodenal adenocarcinoma represents approximately 0.5% of all malignant gastrointestinal tumors and the most studied of them are those located in the first and second (most periampullary) portions^[6,7]. The location of this tumor in the third and/or fourth duodenal portion is rare, presents with non-specific symptoms and is of difficult diagnosis using conventional endoscopic methods^[8]. In this paper is presented an adenocarcinoma of the third and fourth portions of the duodenum, with review of the literature, emphasizing the difficulties and the value of video capsule endoscopy for diagnosis.

CASE REPORT

A man, 40 years old, with no medical history, presented with epigastric and mesogastric discomfort and progressive fatigue, with four months of evolution; and reported an episode of melena in moderate quantity. Physical examination was normal except for mucosal pallor. The laboratory findings were consistent with

microcytic, hypochromic iron deficiency anemia with $3.49 \times 10^6/\text{mm}^3$ RBC, 7.8 g/dL hemoglobin, 27.5% hematocrit, 79 fL MCV, 22.5 pg MCH, 28.4 g/dL MCHC, 22.6% RDW, $915000/\text{mm}^3$ platelets, and 13 ng/mL serum ferritin. Urine analysis, serum liver function test (LFT), hemolysis markers, and serum electrolytes were unremarkable. Upper gastrointestinal endoscopy (until the 2nd duodenal portion) and colonoscopy were normal. Further investigation, using video capsule endoscopy, in the outpatient setting, showed polypoid lesions involving the third and fourth portions of the duodenum (Figure 1). The biopsy showed a moderately differentiated adenocarcinoma. Abdominal CT showed a wall thickening involving the third and fourth portions of the duodenum and proximal jejunum, with no clear cleavage lines with adjacent structures without evidence of nodal and distant metastasis (Figure 2). The patient underwent a segmental resection of the duodenum (third and fourth portions) and proximal jejunum, with duodenojejunostomy. The pathological examination of the surgical specimen confirmed a moderately differentiated adenocarcinoma infiltrating the wall of the organ without lymph node metastasis (Figure 3). The patient underwent a follow-up by oncology.

DISCUSSION

This case represents a rare location of primary duodenal adenocarcinoma^[8] in a younger patient compared to the average peak incidence of duodenal adenocarcinoma shown in literature (seventh decade of life), with a slight predominance for males^[9]. The patient was younger, and there was no known condition associated with early occurrence, such as inflammatory bowel disease^[10], familial adenomatous polyposis, or hereditary nonpolyposis colorectal cancer, in which cancer presents earlier (median 39 years)^[11] in his personal and/or family medical history.

The clinical picture of adenocarcinoma in the third and fourth portions occurs with rather non-specific symptoms. Unlike periampullary tumors, whose main clinical picture is jaundice and other clinical aspects from the obstruction of the hepatobiliary-pancreatic system^[7], in third and fourth portion tumors there are non-specific symptoms such as vague abdominal pain, weight loss, anemia symptoms, but no frank bleeding, and more rarely, bowel obstruction dominates the clinical picture^[12,13]. In this case, the duration of symptoms before diagnosis was 4 mo, that is within the average literature range (from 1.4 to 8 mo)^[7]. One study showed worse 2-year survival rate associated with 4 mo or longer duration^[14].

In routine work-up, both upper and lower endoscopy were normal. This situation is a substratum for missing tumors in the third and/or fourth portions, and is often worsened by the low index of clinical suspicion, which usually delays the diagnosis, resulting in advanced disease at diagnosis and decreasing

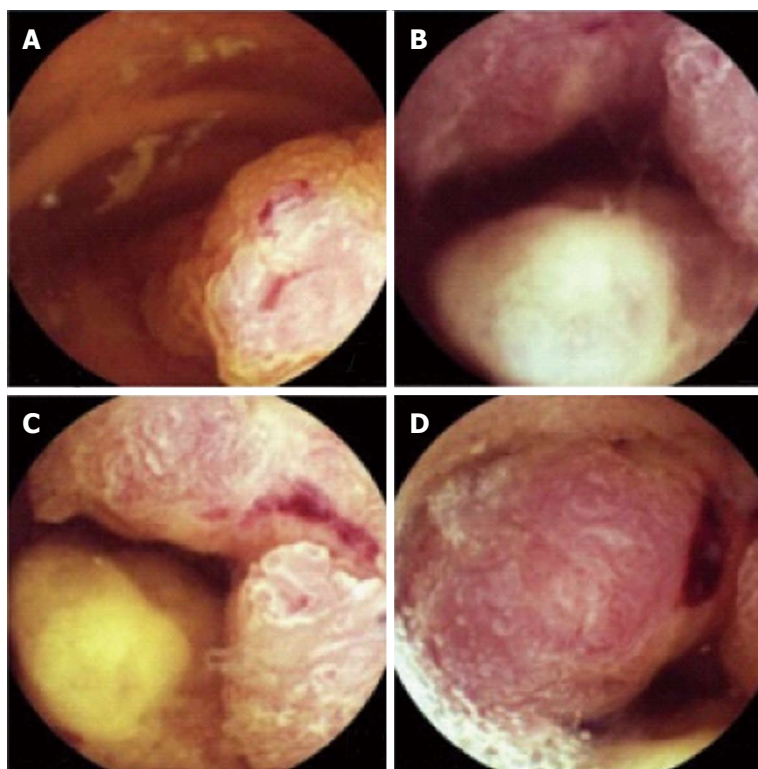


Figure 1 Capsule endoscopy findings in the 3rd and 4th portions of the duodenum. A: Polypoid and multilobular lesion; B, C: Partially obstructing the lumen; C, D: Ulcerated with low-flow bleeding.

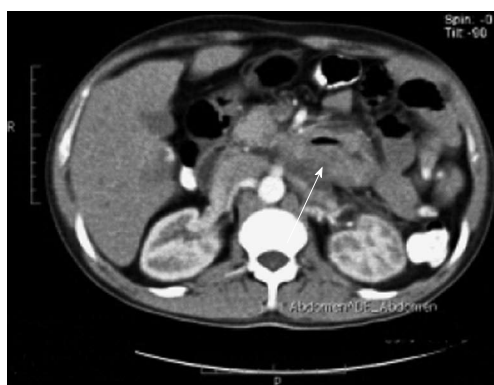

Figure 2 Abdominal computed tomography scan demonstrating a thickening of the wall involving the 3rd and 4th portions of duodenum, narrowing its lumen (arrows), without clear lines of cleavage with adjacent structures and with no evidence of nodal and distant metastasis.

the rate of potentially curative resections^[7,15]. After nondiagnostic conventional endoscopic tests, in the setting of iron deficiency anemia, it is worth having a high index of suspicion for tumors beyond the second portion and to carry on the work-up using a method of greater accuracy for these tumors, the endoscopic capsule^[8,16].

Capsule endoscopy is a non-invasive procedure that uses a wireless endoscopic device that allows imaging of the gastrointestinal tract. In this case, it was a valuable tool that allowed complete small bowel exploration in the ambulatory setting. The main

indications for its use are the evaluation of obscure gastrointestinal bleeding, and Crohn's disease^[17,18]. Its sensitivity and specificity for diagnosing a small bowel tumor is 88.9% to 95% and 75% to 95% respectively, in the setting of obscure gastrointestinal bleeding^[16,19]. Tumors are found in about 3% to 9% of patients undergoing this procedure for evaluation of obscure gastrointestinal bleeding, and 50% to 60% were malignant^[18]. Video capsule endoscopy has also been used for the evaluation of patients with certain disorders that increase the risk of tumors of the small intestine, such as familial adenomatous polyposis^[18].

Treatment of primary duodenal adenocarcinoma depends on the location and staging. In this case, a segmental resection of the duodenum (3rd and 4th portions) and the proximal jejunum (20 cm from duodenojejunal flexure), with primary duodenojejuno-stomy was performed. This approach was preferred to more extensive resection, because it provides equivalent survival rates to extensive resections (since it is possible to achieve negative margins), with the benefit of lower morbidity than that associated with pancreaticoduodenectomy^[20] and even better survival, as was shown in one study^[21]. Currently, extensive pancreaticoduodenectomy applies more to tumors of the proximal duodenum (1st and 2nd portions)^[22].

The pathological examination of the surgical specimen confirmed a moderately differentiated adenocarcinoma, which is the most common histological grade^[3,23], that infiltrates the three layers of the wall, without invasion of adjacent organs or metastasis

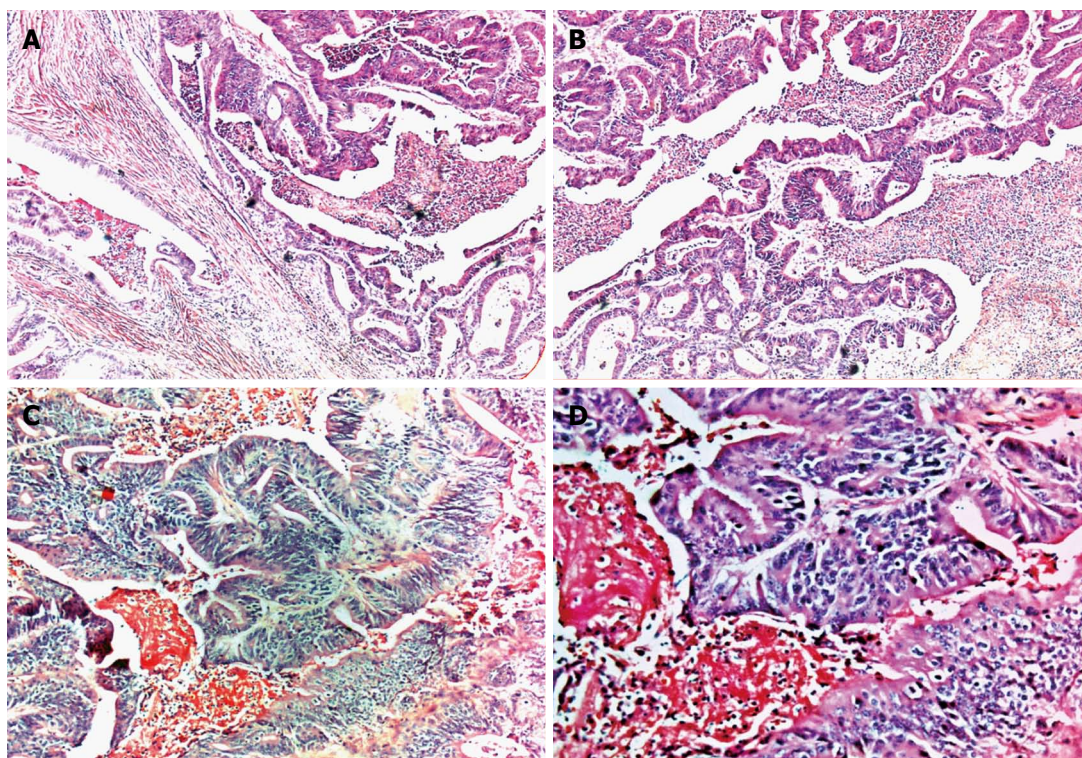


Figure 3 Histological findings of surgical specimen demonstrating moderately differentiated adenocarcinoma, infiltrating the wall thickness (A) (HE, magnification $\times 5$), with areas of cribriform appearance due to fusion of glands and areas of necrosis (B) (HE, magnification $\times 10$); A higher magnification, demonstrating dysplastic aspect of epithelium, loss of polarity and cell dysplasia (C) (HE, magnification $\times 100$) and (D) (HE, magnification $\times 200$). HE: Hematoxylin and eosin.

to the lymph nodes, and surgical margins were negative for tumor cells. Therefore, it was a stadium II tumor (T3 N0 M0), that is the most frequent stage for adenocarcinoma in this site^[12,24]. Despite negative margins and no lymph node involvement, the combination of 3 variables present in this case - tumor extension, histological grade and transmural invasion - are associated with poor prognosis^[6].

With regard to the adjuvant treatment, there is no established protocol for small bowel adenocarcinomas, due to the lack of randomized trials^[25]; and the few available data from retrospective studies have shown no statistically significant overall survival benefit^[26]. As with treatment, there is no established follow-up protocol for patients with resected adenocarcinoma of the small intestine. In this case, the patient continued follow-up by oncologist.

Malignant tumors of the small intestine, although rare, should be part of the differential diagnosis in the investigation of obscure gastrointestinal bleeding and the high index of suspicion and appropriate use of endoscopic capsule are of great value.

COMMENTS

Case characteristics

A 40-year-old male presenting with abdominal discomfort and progressive fatigue due to severe anemia by continuous bleeding from third and fourth

portions duodenal cancer.

Clinical diagnosis

Small intestine examination with video capsule endoscopy revealed a multilobular tumor, ulcerated with low-flow bleeding lesion in the third and fourth duodenal portions.

Differential diagnosis

Upper gastrointestinal endoscopy (until the 2nd duodenal portion) and colonoscopy were performed to rule out stomach and colon bleeding respectively.

Laboratory diagnosis

Blood tests demonstrated RBC $3.49 \times 10^6/\text{mm}^3$; hemoglobin 7.8 g/dL; MCH 79 fL and serum ferritin 13 ng/mL. Metabolic panel and liver function tests were within normal limits.

Imaging diagnosis

Abdominal computed tomography demonstrated a wall thickening involving third and fourth duodenal portions and proximal jejunum, without evidence of nodal and distant metastasis.

Pathological diagnosis

The histopathological examination of the surgical specimen demonstrated a three layer infiltrating adenocarcinoma, without lymph node invasion, with free surgical margins.

Treatment

Segmental resection of the duodenum (3rd and 4th portions) and proximal jejunum (20 cm from duodenojejunal flexure) was performed, with primary duodenojejunostomy.

Experiences and lessons

Malignant tumors of the third and fourth duodenal portions are a diagnostic challenge using conventional endoscopic tests; a high index of suspicion and appropriate use of the endoscopic capsule is of great value for early diagnosis.

Peer-review

The authors reported primary adenocarcinoma of the 3rd/4th portions of the duodenum in a 40-year-old man. Blood tests revealed microcytic, hypochromic iron deficiency anemia. Upper gastrointestinal endoscopy and colonoscopy were normal, but the polypoid lesions with low-flow bleeding were observed by video capsule endoscopy.

REFERENCES

- 1 **Aparicio T**, Zaanen A, Svrcek M, Laurent-Puig P, Carrere N, Manfredi S, Locher C, Afchain P. Small bowel adenocarcinoma: epidemiology, risk factors, diagnosis and treatment. *Dig Liver Dis* 2014; **46**: 97-104 [PMID: 23796552 DOI: 10.1016/j.dld.2013.04.013]
- 2 **Siegel R**, Naishadham D, Jemal A. Cancer statistics, 2012. *CA Cancer J Clin* 2012; **62**: 10-29 [PMID: 22237781 DOI: 10.3322/caac.20138]
- 3 **Dabaja BS**, Suki D, Pro B, Bonnen M, Ajani J. Adenocarcinoma of the small bowel: presentation, prognostic factors, and outcome of 217 patients. *Cancer* 2004; **101**: 518-526 [PMID: 15274064 DOI: 10.1002/cncr.20404]
- 4 **Bilimoria KY**, Bentrem DJ, Wayne JD, Ko CY, Bennett CL, Talamonti MS. Small bowel cancer in the United States: changes in epidemiology, treatment, and survival over the last 20 years. *Ann Surg* 2009; **249**: 63-71 [PMID: 19106677 DOI: 10.1097/SLA.0b013e31818e4641]
- 5 **Pan SY**, Morrison H. Epidemiology of cancer of the small intestine. *World J Gastrointest Oncol* 2011; **3**: 33-42 [PMID: 21461167 DOI: 10.4251/wjgo.v3.i3.33]
- 6 **Ryder NM**, Ko CY, Hines OJ, Gloor B, Reber HA. Primary duodenal adenocarcinoma: a 40-year experience. *Arch Surg* 2000; **135**: 1070-1074; discussion 1074-1075 [PMID: 10982512 DOI: 10.1001/archsurg.135.9.1070]
- 7 **Solej M**, D'Amico S, Brondino G, Ferronato M, Nano M. Primary duodenal adenocarcinoma. *Tumori* 2008; **94**: 779-786 [PMID: 19267092 DOI: 10.1700/396.4655]
- 8 **Eliakim R**, Fischer D, Suissa A, Yassin K, Katz D, Guttman N, Migdal M. Wireless capsule video endoscopy is a superior diagnostic tool in comparison to barium follow-through and computerized tomography in patients with suspected Crohn's disease. *Eur J Gastroenterol Hepatol* 2003; **15**: 363-367 [PMID: 12655255 DOI: 10.1097/01.meg.0000050000.68425.7e]
- 9 **Kim MJ**, Choi SB, Han HJ, Park PJ, Kim WB, Song TJ, Suh SO, Choi SY. Clinicopathological analysis and survival outcome of duodenal adenocarcinoma. *Kaohsiung J Med Sci* 2014; **30**: 254-259 [PMID: 24751389 DOI: 10.1016/j.kjms.2013.12.006]
- 10 **Xie J**, Itzkowitz SH. Cancer in inflammatory bowel disease. *World J Gastroenterol* 2008; **14**: 378-389 [PMID: 18200660 DOI: 10.3748/wjg.14.378]
- 11 **Björk J**, Akerbrant H, Iselius L, Bergman A, Engwall Y, Wahlström J, Martinsson T, Nordling M, Hultcrantz R. Periapillary adenomas and adenocarcinomas in familial adenomatous polyposis: cumulative risks and APC gene mutations. *Gastroenterology* 2001; **121**: 1127-1135 [PMID: 11677205 DOI: 10.1053/gast.2001.28707]
- 12 **Tocchi A**, Mazzoni G, Puma F, Miccini M, Cassini D, Bettelli E, Tagliacozzo S. Adenocarcinoma of the third and fourth portions of the duodenum: results of surgical treatment. *Arch Surg* 2003; **138**: 80-85 [PMID: 12511157 DOI: 10.1001/archsurg.138.1.80]
- 13 **Bang CS**, Yoon JH, Choi SH, Eom JH, Lee YS, Lee YH, Han SH. Primary Adenocarcinoma of Duodenum Located in Third Portion Cured by Wedge Resection. *Korean J Helicobacter Up Gastrointest Res* 2013; **13**: 263-266 [DOI: 10.7704/kjhugr.2013.13.4.263]
- 14 **Delcore R**, Thomas JH, Forster J, Hermreck AS. Improving resectability and survival in patients with primary duodenal carcinoma. *Am J Surg* 1993; **166**: 626-630; discussion 630-631 [PMID: 7903846 DOI: 10.1016/S0002-9610(05)80668-3]
- 15 **Stell D**, Mayer D, Mirza D, Buckels J. Delayed diagnosis and lower resection rate of adenocarcinoma of the distal duodenum. *Dig Surg* 2004; **21**: 434-438; discussion 438-439 [PMID: 15665538 DOI: 10.1159/000083470]
- 16 **Hartmann D**, Schmidt H, Bolz G, Schilling D, Kinzel F, Eickhoff A, Huschner W, Möller K, Jakobs R, Reitzig P, Weickert U, Gellert K, Schultz H, Guenther K, Hollerbuhl H, Schoenleben K, Schulz HJ, Riemann JF. A prospective two-center study comparing wireless capsule endoscopy with intraoperative enteroscopy in patients with obscure GI bleeding. *Gastrointest Endosc* 2005; **61**: 826-832 [PMID: 15933683 DOI: 10.1016/S0016-5107(05)00372-X]
- 17 **Ladas SD**, Triantafyllou K, Spada C, Riccioni ME, Rey JF, Niv Y, Delvaux M, de Franchis R, Costamagna G. European Society of Gastrointestinal Endoscopy (ESGE): recommendations (2009) on clinical use of video capsule endoscopy to investigate small-bowel, esophageal and colonic diseases. *Endoscopy* 2010; **42**: 220-227 [PMID: 20195992 DOI: 10.1055/s-0029-1243968]
- 18 **Eliakim R**. Video capsule endoscopy of the small bowel. *Curr Opin Gastroenterol* 2010; **26**: 129-133 [PMID: 20145540 DOI: 10.1097/MOG.0b013e328334df17]
- 19 **Pennazio M**, Santucci R, Rondonotti E, Abbiati C, Beccari G, Rossini FP, De Franchis R. Outcome of patients with obscure gastrointestinal bleeding after capsule endoscopy: report of 100 consecutive cases. *Gastroenterology* 2004; **126**: 643-653 [PMID: 14988816 DOI: 10.1053/j.gastro.2003.11.057]
- 20 **Bakaeen FG**, Murr MM, Sarr MG, Thompson GB, Farnell MB, Nagorney DM, Farley DR, van Heerden JA, Wiersma LM, Schleck CD, Donohue JH. What prognostic factors are important in duodenal adenocarcinoma? *Arch Surg* 2000; **135**: 635-641; discussion 641-642 [PMID: 10843358 DOI: 10.1001/archsurg.135.6.635]
- 21 **Kaklamanos IG**, Bathe OF, Franceschi D, Camarda C, Levi J, Livingstone AS. Extent of resection in the management of duodenal adenocarcinoma. *Am J Surg* 2000; **179**: 37-41 [PMID: 10737576 DOI: 10.1016/S0002-9610(99)00269-X]
- 22 **Halfdanarson TR**, McWilliams RR, Donohue JH, Quevedo JF. A single-institution experience with 491 cases of small bowel adenocarcinoma. *Am J Surg* 2010; **199**: 797-803 [PMID: 20609724 DOI: 10.1016/j.amjsurg.2009.05.037]
- 23 **Hung FC**, Kuo CM, Chuah SK, Kuo CH, Chen YS, Lu SN, Chang Chien CS. Clinical analysis of primary duodenal adenocarcinoma: an 11-year experience. *J Gastroenterol Hepatol* 2007; **22**: 724-728 [PMID: 17444863 DOI: 10.1111/j.1440-1746.2007.04935.x]
- 24 **Edge SB**, Byrd DR, Compton CC, Fritz AG, Greene FL, Trotti A. American Joint Committee on Cancer (AJCC) Cancer staging manual. 7th ed. New York: Springer-Verlag, 2010: 718
- 25 **Singhal N**, Singhal D. Adjuvant chemotherapy for small intestine adenocarcinoma. *Cochrane Database Syst Rev* 2007; **(3)**: CD005202 [PMID: 17636789 DOI: 10.1002/14651858.CD005202.pub2]
- 26 **Overman MJ**, Kopetz S, Lin E, Abbruzzese JL, Wolff RA. Is there a role for adjuvant therapy in resected adenocarcinoma of the small intestine. *Acta Oncol* 2010; **49**: 474-479 [PMID: 20397775 DOI: 10.3109/02841860903490051]

P- Reviewer: Charoenphandhu N S- Editor: Ma YJ

L- Editor: O'Neill M E- Editor: Liu XM





Published by **Baishideng Publishing Group Inc**

8226 Regency Drive, Pleasanton, CA 94588, USA

Telephone: +1-925-223-8242

Fax: +1-925-223-8243

E-mail: bpgoffice@wjgnet.com

Help Desk: <http://www.wjgnet.com/esps/helpdesk.aspx>

<http://www.wjgnet.com>



ISSN 1007-9327

