

Basic Study

Mucosal healing effect of nilotinib in indomethacin-induced enterocolitis: A rat model

Gozde Dervis Hakim, Mujde Soyuturk, Mehtat Unlu, Pinar Ataca, Meral Karaman, Ozgul Sagol, Elif Borekci, Osman Yilmaz

Gozde Dervis Hakim, Mujde Soyuturk, Department of Gastroenterology, School of Medicine, Dokuz Eylul University, Inciralti, Izmir 35340, Turkey

Mehtat Unlu, Ozgul Sagol, Department of Pathology, School of Medicine, Dokuz Eylul University, Inciralti, Izmir 35340, Turkey

Pinar Ataca, Elif Borekci, Department of Internal Medicine, School of Medicine, Dokuz Eylul University, Inciralti, Izmir 35340, Turkey

Meral Karaman, Osman Yilmaz, Department of Laboratory Animal Science, School of Medicine, Dokuz Eylul University, Inciralti, Izmir 35340, Turkey

Author contributions: Dervis Hakim G and Soyuturk M designed the research; Dervis Hakim G and Ataca P performed the research; Sagol O and Karaman M contributed new reagents or analytic tools; Borekci E provided technical support; Unlu M And Sagol O contributed to the evaluations of the pathological data; Karaman M and Yilmaz O designed the rat conditions; Soyuturk M analyzed the data; Dervis Hakim G wrote the paper; all authors read and approved the final manuscript.

Supported by Dokuz Eylul University Research Committee.

Institutional review board statement: The study was reviewed and approved by the Dokuz Eylul University Institutional Review Board.

Institutional animal care and use committee statement: All procedures involving animals were reviewed and approved by the Institutional Animal Care and Use Committee of the Dokuz Eylul University [protocol number: B.30.2.DEÜ.0.01.00.00/15387].

Conflict-of-interest statement: The authors declare no conflict of interest.

Open-Access: This article is an open-access article which was selected by an in-house editor and fully peer-reviewed by external reviewers. It is distributed in accordance with the Creative Commons Attribution Non Commercial (CC BY-NC 4.0) license, which permits others to distribute, remix, adapt, build upon this

work non-commercially, and license their derivative works on different terms, provided the original work is properly cited and the use is non-commercial. See: <http://creativecommons.org/licenses/by-nc/4.0/>

Correspondence to: Gozde Dervis Hakim, MD, Department of Gastroenterology, School of Medicine, Dokuz Eylul University, Inciralti, Mh., Mithatpaşa cad. No. 1606, Inciraltı yerleşkesi, Izmir 35340, Turkey. gozdedervis@gmail.com
Telephone: +90-505-2663138

Received: March 26, 2015

Peer-review started: March 28, 2015

First decision: May 18, 2015

Revised: June 15, 2015

Accepted: September 13, 2015

Article in press: September 14, 2015

Published online: November 28, 2015

Abstract

AIM: To investigate the effects of nilotinib in a rat model of indomethacin-induced enterocolitis.

METHODS: Twenty-one Wistar albino female rats obtained from Dokuz Eylul University Department of Laboratory Animal Science were divided into the following three groups: control ($n = 7$), indomethacin ($n = 7$) and nilotinib ($n = 7$). A volume of 0.25 mL of physiological serum placebo was administered to the control and indomethacin groups through an orogastric tube for 13 d. To induce enterocolitis, the indomethacin and nilotinib groups received 7.5 mL/kg indomethacin dissolved in 5% sodium bicarbonate and administered subcutaneously in a volume of 0.5 mL twice daily for three days. Nilotinib was administered 20 mg/kg/d in two divided doses to the nilotinib group of rats for 13 d through an orogastric tube, beginning on the same day as indomethacin administration. For 13 d, the rats were

fed a standard diet, and their weights were monitored daily. After the rats were sacrificed, the intestinal and colonic tissue samples were examined. The macroscopic and microscopic pathology scores were evaluated. The pathologist stained all tissue samples using terminal deoxynucleotidyl transferase-mediated dUTP-biotin nick-end labeling method. Mucosal crypts and apoptotic cells were quantified. The platelet-derived growth factor receptor (PDGFR) α and β scores assessed by immunohistochemical staining method and tissue and serum tumor necrosis factor (TNF) α levels were determined by enzyme-linked immunosorbent assay.

RESULTS: Between days 1 and 13, the rats in the nilotinib and indomethacin groups lost significantly more weight than the controls (-11 g *vs* $+14.14$ g, $P = 0.013$; -30 g *vs* $+14.14$ g, $P = 0.003$). In the small intestinal and colonic tissues, the macroscopic scores were significantly lower in the nilotinib group than in the indomethacin group (1.14 ± 0.38 and 7.29 ± 2.98 , $P = 0.005$; 1.14 ± 0.38 and 7.43 ± 2.64 , $P = 0.001$, respectively), but the values of the nilotinib and indomethacin groups were similar to the control group. In the small intestinal and colonic tissues, the microscopic scores were significantly lower in the nilotinib group than in the indomethacin group (3.43 ± 2.99 and 7.67 ± 3.67 , $P = 0.043$; 2.29 ± 0.76 and 8.80 ± 2.68 , $P = 0.003$, respectively), but the values were similar to the control group. The PDGFR β scores in the small intestine and colon were significantly lower in the nilotinib group than in the indomethacin group (1.43 ± 0.79 and 2.43 ± 0.54 , $P = 0.021$; 1.57 ± 0.54 and 3 ± 0 , $P = 0.001$), and the values were similar to controls. The colonic PDGFR α scores were significantly lower in the nilotinib group than in the indomethacin group (1.71 ± 0.49 and 3 ± 0 , $P = 0.001$). The colonic apoptosis scores were significantly lower in the controls than in the nilotinib group (1.57 ± 1.13 and 4 ± 1.29 , $P = 0.007$). Furthermore, the serum and tissue TNF- α levels were similar between the nilotinib and indomethacin groups.

CONCLUSION: In the indomethacin-induced enterocolitis rat model, nilotinib has a positive effect on the macroscopic and microscopic pathologic scores, ensuring considerable mucosal healing. Nilotinib decreases PDGFR α and β levels and increases the colonic apoptotic scores, but it has no significant effects on weight loss and the TNF- α levels.

Key words: Inflammatory bowel disease; Enterocolitis; Platelet-derived growth factor receptor; Tumor necrosis factor α ; Tyrosine kinase inhibitor; Rats; Mucosal healing

© **The Author(s) 2015.** Published by Baishideng Publishing Group Inc. All rights reserved.

Core tip: The etiopathogenesis of inflammatory bowel diseases (IBDs) has not been clearly elucidated.

Many management strategies that include targeting particular pathways involved in the development of IBD have been developed. In the present study, we aimed to investigate the effects of nilotinib in a rat model of indomethacin-induced enterocolitis. From our study, it appears that nilotinib had considerable effects on pathological scores, which indicated positive effects in mucosal healing. Nilotinib decreased platelet-derived growth factor receptor α and β and increased the colonic apoptotic scores, but it had no significant effects on weight loss or serum-tissue tumor necrosis factor α levels.

Dervis Hakim G, Soyuturk M, Unlu M, Ataca P, Karaman M, Sagol O, Borekci E, Yilmaz O. Mucosal healing effect of nilotinib in indomethacin-induced enterocolitis: A rat model. *World J Gastroenterol* 2015; 21(44): 12576-12585 Available from: URL: <http://www.wjgnet.com/1007-9327/full/v21/i44/12576.htm> DOI: <http://dx.doi.org/10.3748/wjg.v21.i44.12576>

INTRODUCTION

Inflammatory bowel diseases (IBDs) are a group of idiopathic, chronic and relapsing inflammatory conditions of the gastrointestinal tract. The pathogenesis of IBD is only partially understood; complex interactions between the immune system, enteric commensal bacteria and host genotype are thought to underlie the development of IBD^[1]. The current guidelines for conventional IBD therapy recommend the use of aminosalicylates [sulphasalazine, 5-aminosalicylic acid (5-ASA)], corticosteroids, or immunosuppressive drugs (azathioprine, 6-mercaptopurine, methotrexate, and cyclosporine A) according to the extent and severity of disease, the response to current or prior treatment, and the presence of complications^[2]. The use of these drugs is limited by side effects, unresponsiveness or high relapse rates^[3-8]. The introduction of anti-TNF- α drugs has changed the mode of therapy in patients with Crohn's disease (CD). Anti-TNF- α drugs induce clinical remission and significant endoscopic improvement. However, both immune-mediated adverse reactions and loss of efficacy with time have limited their use^[9,10].

Currently, mucosal healing, which is referred to as "endoscopic remission", has emerged as an increasingly important therapeutic goal. In CD, mucosal healing is associated with a decreased need for hospitalization and surgery, lower costs, decreased side effects, increased rates of clinical remission, and improved quality of life. However, there are no published data on the ability of 5-ASA to induce mucosal healing in CD^[11]. Among the 92% of CD patients who achieved clinical remission, 29% achieved endoscopic remission, and 13% achieved complete mucosal healing with oral prednisolone^[12,13]. In

several studies with immunomodulators (azathioprine and methotrexate), the mucosal healing rates were between 11% and 62.5%^[14-20]. In contrast, mucosal healing is achieved in approximately 30% of CD patients who receive anti-TNF therapies^[21-25]. Briefly, 20%-30% of patients do not respond to biological therapy, and up to 70% of CD patients will undergo intestinal resection during the course of their disease. Hence, the available medical treatment options are still far from resulting in complete long-term remission and mucosal healing^[26,27]. Therefore, it is critically important to identify new medical treatment options for IBD.

The protein tyrosine kinases (TKs) constitute a large family of homologous proteins that have an important role in regulating intracellular signal transduction pathways and control a range of fundamental cellular process, including growth, metabolism, differentiation, adhesion and apoptosis^[28]. Imatinib, the best-known member of this class of drugs, is specific for TK receptor sites and suppresses the Abelson proto-oncogene (ABL), c-kit proto-oncogene, platelet-derived growth factor receptor (PDGFR), macrophage colony-stimulating factor receptor (c-fms), TNF- α , and inducible nitric oxide synthase^[29]. Nilotinib is a highly potent and selective inhibitor of the wild-type BCR-ABL1, and it was developed for imatinib-resistant mutants^[30-32]. Nilotinib reduces the levels of interleukin (IL)-6, IL-1 β , TNF- α , tumor growth factor (TGF) β 1, and PDGFR β more significantly than imatinib, and it has a potent antifibrotic effect^[33]. More recently, in our previous study, we demonstrated that nilotinib has a significant effect on weight loss and macroscopic and microscopic pathological scores and causes significant mucosal healing in a rat trinitrobenzene sulfonic acid (TNBS)-induced colitis model^[34].

The present study was planned based on the success of nilotinib demonstrated in our previous study, and we aimed to investigate the effect of nilotinib in a chronic enterocolitis rat model that was induced with indomethacin. For this purpose, we evaluated the efficacy of nilotinib on weight, macroscopic and microscopic pathological scores, TNF- α levels, PDGFR levels, and apoptotic index in rats with indomethacin-induced enterocolitis.

MATERIALS AND METHODS

Animals

Approval was obtained from the animal ethics council of Dokuz Eylul University Faculty of Medicine (DEUTF). The DEUTF Hospital Experimental Research Laboratory provided 21 female Wistar albino rats, weighing 226-243 g (mean weight, 241.09 g), for use in this study. The rats were divided into three groups, each consisting of seven rats (Table 1).

The rats were maintained at room at a temperature of $23 \pm 2^\circ\text{C}$ under a 12-h light/dark cycle at the DEUTF Experimental Animal Laboratory. Before and

Table 1 Study groups and experimental design

Group	n	1-3 d	4-13 d
1	7	Physiological serum	Physiological serum
2	7	Indomethacin	Physiological serum
3	7	Indomethacin	Nilotinib

during the study, the animals were fed a standard diet, and their weights were monitored daily. The animals were also allowed water *ad libitum*.

Experimental design

After 24 h of fasting, 0.25 mL of physiological serum was administered to the control group of rats through an orogastric tube. To induce chronic enterocolitis, the rats in the other two groups received 7.5 mg/kg indomethacin dissolved in 5% sodium bicarbonate and administered in a 0.5-mL volume subcutaneously, two times a day, for three days^[35,36]. Across both groups of rats treated with indomethacin, one of the rats treated with only indomethacin was found dead on the sixth day of the experiment. A necropsy was not performed on this rat.

The indomethacin and control groups received saline placebo for 13 d through an orogastric tube. Nilotinib, administered 20 mg/kg/d (Novartis Pharma AG, Basel, Switzerland) in two divided doses, was administered to the nilotinib group of rats ($n = 7$) for 13 d through an orogastric tube, beginning on the same day as indomethacin administration.

Blood and tissue samples for pathological examination were obtained from all rats under ether anesthesia at the end of the 13-d period. All animals were then sacrificed by decapitation. The abdominal cavity was opened by a midline incision, and the stomach, small intestine and colon were dissected. The intestinal lumen was washed with saline and then removed and opened along its length. The intestinal tissue was then fixed with buffered formalin.

Pathological examinations

A pathologist, who was blinded to the group identity of the intestinal samples, performed the pathological evaluation of all tissue samples twice. The pathologist first examined the tissues macroscopically, recording the number and size of the ulcers noted. In addition, each small and large intestinal column was longitudinally opened according to the method reported by Vilaseca *et al.*^[37], and macroscopic scoring was performed. Tissue sections of the gross ulcerative lesions and surrounding normal mucosa were then stained with hematoxylin-eosin (HE). The pathologist then performed microscopic scoring according to the method reported by Dieleman *et al.*^[38].

Apoptosis

The pathologist then stained all tissue samples using the TUNEL method. Mucosal crypts and apoptotic

cells were counted along the surface epithelium under a microscope (Olympus DX51 Tokyo, Japan) at a magnification of $\times 400$. Using the TUNEL technique, all cut sections were preserved with lysine for three nights at 37 °C and then treated for one night at 60 °C in an incubator. Thereafter, deparaffinization was performed with three changes with xylene (20 min) (first xylene in the incubator, and the others at room temperature). The tissue sections were then rehydrated by flushing with a series of alcohol solutions of decreasing degree (absolute, 96%, 80%, and 70%); the samples were then stored in distilled water for 5 min. After absorbing water from the edge of each section, proteinase K (Invitrogen, United States) was applied for 10 min at room temperature. The sections were then washed twice with phosphate-buffered solution (PBS) for a period of 2 min each. After drying the cross sections, 3% H₂O₂ (Merck, Germany) was applied for 5 min to inhibit tissue endogenous peroxidase, and the sections were then washed twice with PBS for 5 min each. The cross-section slices were then dried, and an equilibration buffer (ApopTag Plus peroxidase kit, Millipore, United States) was applied for 10 min at room temperature. A total of 55 μ L of the enzyme terminal deoxynucleotidyl transferase was then applied to each cross section. The cross sections were cover-slipped (ApopTag Plus peroxidase kit, Millipore, United States) and incubated for 1 h at 37 °C. Stop/wash buffer (ApopTag Plus peroxidase kit, Millipore, United States) was then applied to the sections that were removed from the incubator for 10 min at room temperature. The sections were then washed three times (for 1 min each) with PBS at room temperature, dried, and incubated with anti-streptavidin-peroxidase (ApopTag Plus peroxidase kit, Millipore, United States) at room temperature for 30 min. The sections were then washed with PBS four times for 2 min each to determine the visibility of the TUNEL reaction, and the samples were then stained with diaminobenzidine (DAB) (DAB-PLUS kit, Invitrogen, United States). After washing with distilled water, ground staining was performed using methyl green. The sections were then washed with three changes of distilled water. After three changes of the searing process with xylene for 20 min, closure was performed with Entella.

Tissue homogenization and measurement of the tissue serum TNF- α

The tissue samples obtained from the terminal ileum were placed in 2-mL microcentrifuge tubes and stored at -80 °C until further use. These tissues were then removed on the day of the study and warmed to 4 °C. Then, 60-80-mg pieces were obtained from these samples and placed into a tube containing 5-mm-diameter stainless steel beads and phosphate buffer with a 1:7 ratio (pH 7.2). Microcentrifuge tubes were introduced into a pre-chilled TissueLyser LT device

and replaced in a TissueLyser (Qiagen-Germany) tissue homogenization device. The frequency and time were adjusted to 50 and 5 min, respectively. The resulting homogenate was centrifuged for 10 min at 4 °C and 5000 $\times g$. Next, an enzyme-linked immunosorbent assay (ELISA) was performed on tissue supernatants, and serum was obtained from centrifugation for identifying TNF- α in accordance with the manufacturer's recommendations (Invitrogen, Rat TNF- α , United States). Finally, the ELISA plates were spectrophotometrically evaluated at 450 nm (Biotech Synergy HT, United States).

PDGFR α and β levels

The PDGFR α and β levels were assessed through staining scores and compared among the groups by immunohistochemistry. For immunohistochemical staining, 2-3-micron sections were stored overnight in the incubator at 40 °C. The following day, the sections were washed with xylene, in descending alcohol series, and distilled water for 20 min. Afterwards, the samples were boiled for 20 min in an EDTA solution at pH 8.0. The samples were then stored in DakoFlex peroxidase solution for 5 min and washed again with Tris-buffered saline. A primary antibody was then applied: PDGFR α , in a 1:100 dilution (NOVUS Biologicals, NBP1-19 423, United States) and PDGFR β , in a 1:50 dilution (NOVUS Biologicals, NBP1-19 473, United States). The samples were incubated for 30 min, washed with Tris buffer, stored in DakoFlex HRP solution for 20 min, washed with Tris buffer again, and stored in DakoFlex DAB for 7 min. These samples were then washed with Tris-buffered saline, kept under tap water for 5 min, stained with Mayer's hematoxylin solution for 10 min, washed with tap water for 1 min, rinsed in an alcohol series, and cleaned with xylene for 5-10 min.

The PDGFR α and β positivity was determined according to a devised scoring system. According to this system, a score of +1 was assigned if PDGFR α and β positivity was confirmed in inflammatory cells as well as in cells of the lamina propria, stroma, and submucosal endothelium. A score of +2 was assigned if PDGFR α and β positivity was confirmed in the lamina propria and submucosa. A score of +3 was assigned if PDGFR α and β positivity was confirmed with widespread staining in the ulcerated areas or inflammatory cells, fibroblasts, endothelial cells, submucosa, and mucosa of the surrounding tissue.

Statistical analysis

All statistical procedures were performed using SPSS software (version 15.0). The Kruskal-Wallis test was used for multigroup comparisons, while the Mann-Whitney *U* test was used to compare the means of two groups. A *P* value less than 0.05 was considered significant.

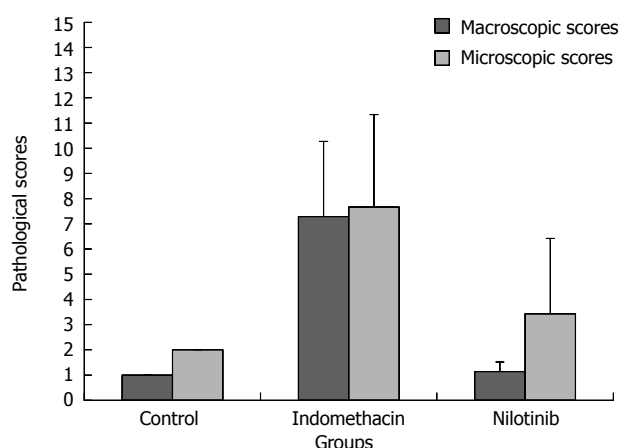


Figure 1 Small intestine macroscopic and microscopic scores.

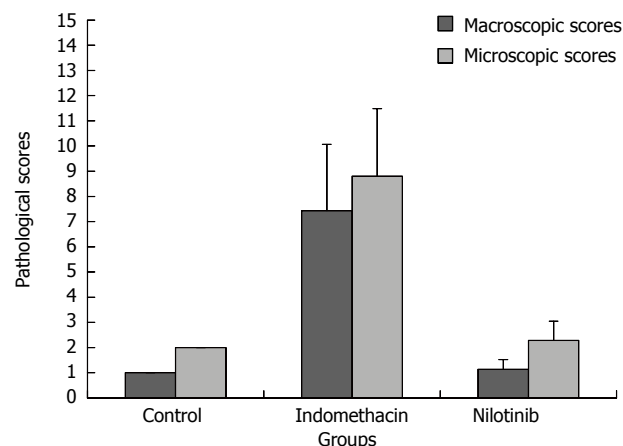


Figure 2 Colon macroscopic and microscopic scores.

RESULTS

On the first experimental day, the average rat weights were similar in all study groups. The average rat weights were determined daily. The average weight of the control group of rats increased to 14.14 g after 13 d. The indomethacin group of rats lost an average of 30 g throughout the study, and the nilotinib group of rats lost an average of 11 g. There was a significant difference among the groups with respect to average weight throughout the study ($P = 0.002$). The differences in the weight between the control and nilotinib groups and between the control and indomethacin groups were significant (+14.14 g and -11 g, respectively, $P = 0.013$ and +14.14 g and -30 g, respectively, $P = 0.003$). There was no significant difference in weight between the indomethacin and nilotinib groups (-30 g and -11 g, respectively; $P = 0.085$).

The mean macroscopic pathological score of the small intestine and colon of the control group was 1 ± 0 . In the indomethacin group, the macroscopic pathological score of the small intestine was 7.29 ± 2.98 and that of the colon was 7.43 ± 2.64 . On the other hand, in the nilotinib group, the mean macroscopic pathological scores of the small intestine and colon were the same, 1.14 ± 0.38 and 1.14 ± 0.38 . Adhesion, strictures, broad-based ulcers and mesenteric cohesiveness were observed in the indomethacin group of rats. The control and nilotinib groups were similar in terms of the macroscopic scores of the small intestine and colon ($P > 0.05$). Macroscopic scores were significantly lower in the control and nilotinib groups than in the indomethacin group for the small intestine (1 and 7.29 ± 2.98 , $P = 0.003$; 1.14 ± 0.38 and 7.29 ± 2.98 , $P = 0.005$, respectively). The macroscopic scores were significantly lower in the control and nilotinib groups than in the indomethacin group for the colon (1 and 7.43 ± 2.64 , $P = 0.001$; 1.14 ± 0.38 and 7.43 ± 2.64 , $P = 0.001$, respectively; Figure 1 and 2; Figures S1

and S2).

The mean microscopic score of the small intestine and colon in the control group was 2 ± 0 . The microscopic pathological scores of the small intestine and colon were 7.67 ± 3.67 and 8.80 ± 2.68 , respectively, in the indomethacin group. In the nilotinib group, the mean microscopic pathological score of the small intestine was 3.43 ± 2.99 , and that of the colon was 2.29 ± 0.76 . The mean microscopic scores of the small intestine were significantly lower in the control and nilotinib groups than in the indomethacin group (2 ± 0 and 7.67 ± 3.67 , $P = 0.004$; 3.43 ± 2.99 and 7.67 ± 3.67 , $P = 0.043$, respectively). The control and nilotinib groups were similar in terms of the mean microscopic scores ($P > 0.05$). The mean microscopic scores of the colon were significantly lower in the control and nilotinib groups than in the indomethacin group (2 ± 0 and 8.80 ± 2.68 , $P = 0.001$; 2.29 ± 0.76 and 8.80 ± 2.68 , $P = 0.003$, respectively; Figures 1 and 2; Figures S1 and S2).

In the PDGFR α and β scoring system, the samples were classified as +1, +2, and +3, according to their staining properties. The PDGFR α scores of the small intestine and colon in the control group were 1 ± 0 and 1.14 ± 0.38 , respectively. In the indomethacin group, the PDGFR α scores of the small intestine and colon were 2 ± 0.82 and 3 ± 0 , respectively. The PDGFR α scores of the small intestine and colon in the nilotinib group were 1.43 ± 0.79 and 1.71 ± 0.49 , respectively. There was a significant difference among the groups in the PDGFR α scores of the small intestine and colon ($P = 0.026$, $P = 0$, respectively). The PDGFR α scores of the colon were significantly lower in the control and nilotinib groups than in the indomethacin group (1.14 ± 0.39 and 3 ± 0 , $P = 0.001$; 1.71 ± 0.49 and 3 ± 0 , $P = 0.001$, respectively). The PDGFR α scores of the small intestine were significantly lower in the control group than in the indomethacin group (1 ± 0 and 2 ± 0.82 , $P = 0.009$). The control and nilotinib groups as well as indomethacin and nilotinib groups were similar in terms of the PDGFR α scores of

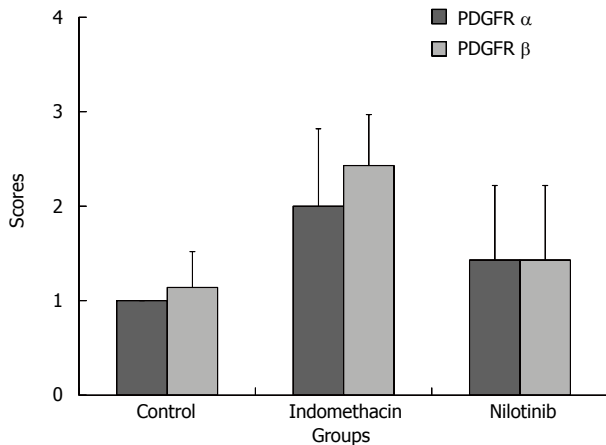


Figure 3 Small intestine platelet-derived growth factor receptor α and β scores. PDGFR: Platelet-derived growth factor receptor.

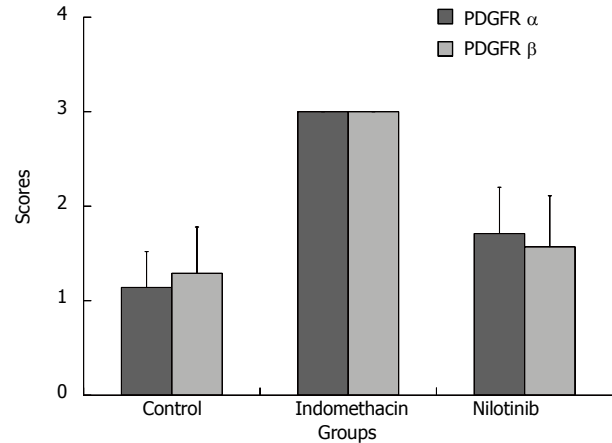


Figure 4 Colon platelet-derived growth factor receptor α and β scores. PDGFR: Platelet-derived growth factor receptor.

the small intestine ($P > 0.05$). The control and nilotinib groups were similar in terms of the PDGFR α scores of the colon ($P > 0.05$; Figures 3 and 4).

The mean PDGFR β scores of the small intestine and colon in the control, indomethacin, and nilotinib groups were 1.14 ± 0.38 and 1.29 ± 0.49 ; 2.43 ± 0.54 and 3 ± 0 ; and 1.43 ± 0.79 and 1.57 ± 0.54 , respectively. There was a significant difference among all groups in terms of the mean PDGFR β scores of the small intestine and colon ($P = 0.004$, $P = 0.001$, respectively). The PDGFR β scores of the small intestine were significantly lower in the control and nilotinib groups than in the indomethacin group (1.14 ± 0.38 and 2.43 ± 0.54 , $P = 0.002$; 1.43 ± 0.79 and 2.43 ± 0.54 , $P = 0.021$, respectively). The PDGFR β scores of the colon were significantly lower in the control and nilotinib groups than in the indomethacin group (1.29 ± 0.49 and 3 ± 0 , $P = 0.001$; 1.57 ± 0.54 and 3 ± 0 , $P = 0.001$, respectively). The PDGFR β scores of the small intestine and colon in the control and nilotinib groups were similar ($P > 0.05$; Figures 3 and 4; Figure S3).

The mean serum TNF- α levels in the control, indomethacin, and nilotinib groups were 0.071 ± 0.003 pg/mL, 0.065 ± 0.005 pg/mL, and 0.083 ± 0.037 pg/mL, respectively. There was no significant difference observed among the groups in terms of the mean serum TNF- α levels ($P > 0.05$; Figure 5). The average tissue TNF- α levels in the control, indomethacin, and nilotinib groups were 0.145 ± 0.242 ng/mL, 0.268 ± 0.061 ng/mL, and 0.292 ± 0.086 ng/mL, respectively. There was a significant difference among all groups ($P = 0.002$). The tissue TNF- α levels were significantly lower in the control group than in the indomethacin and nilotinib groups (0.145 ± 0.242 ng/mL and 0.268 ± 0.061 ng/mL, $P = 0.004$; 0.145 ± 0.242 ng/mL and 0.292 ± 0.086 ng/mL, $P = 0.002$, respectively). However, there was no significant difference between the indomethacin and nilotinib groups in terms of the mean tissue TNF- α levels ($P >$

0.05; Figure 5).

The mean numbers of apoptotic cells in the small intestine and colon in the control, indomethacin, and nilotinib groups were 1.57 ± 0.79 and 1.57 ± 1.13 ; 2.50 ± 0.84 and 7.40 ± 2.88 ; 2.14 ± 1.46 and 4 ± 1.29 , respectively. Although, a significant difference was observed among the groups in the colon ($P = 0.002$), there was no significant difference among the groups in the small intestine ($P > 0.05$). The numbers of apoptotic cells in the colon were significantly lower in the control group than in the indomethacin and nilotinib groups (1.57 ± 1.13 and 7.40 ± 2.88 , $P = 0.004$; 1.57 ± 1.13 and 4 ± 1.29 , $P = 0.007$, respectively). There was a significant difference between the indomethacin and nilotinib groups in terms of the mean number of apoptotic cells in the colon (7.40 ± 2.88 and 4 ± 1.29 , $P = 0.038$; Figure 6).

DISCUSSION

Many management strategies that involve targeting particular pathways involved in the development of IBD have been developed^[39,40]. However, unresponsiveness to medical treatment in IBD still poses a therapeutic challenge.

TK receptors play an important role in controlling most fundamental cellular processes, including cell cycle, migration, metabolism and survival, as well as cell proliferation and differentiation^[41]. Nilotinib is a second-generation tyrosine kinase inhibitor that is 30-fold more potent than imatinib against BCL-ABL kinase. Nilotinib affects the cornerstone of the steps in the pathogenesis of IBD, including TNF- α , PDGFR and nitric oxide synthesis. In our previous study, we demonstrated that nilotinib has a significant effect on weight loss and macroscopic and microscopic pathological scores, and it also leads to significant mucosal healing in a TNBS-induced acute colitis rat model^[34]. Until now, no reports in the literature

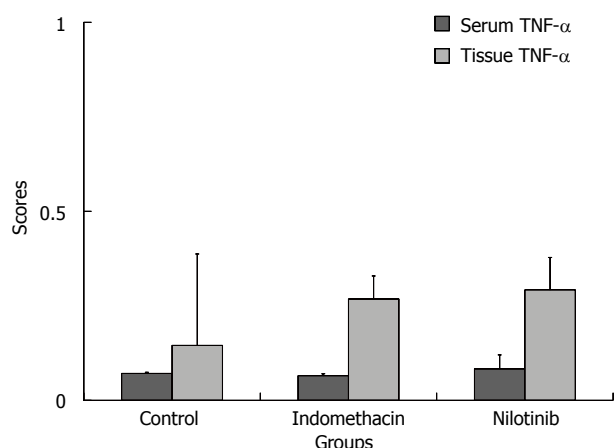


Figure 5 Serum and tissue tumor necrosis factor- α scores. TNF: Tumor necrosis factor.

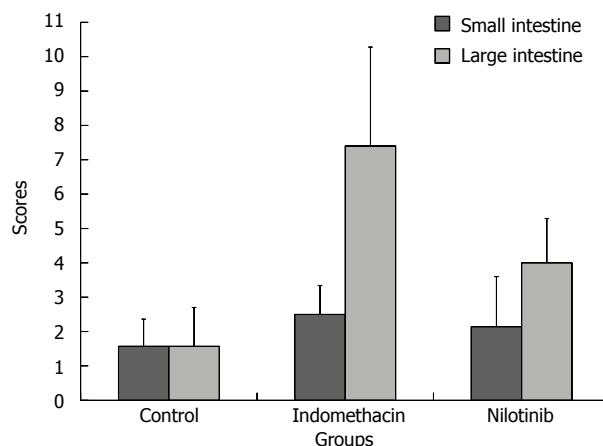


Figure 6 Apoptotic cell number.

had evaluated the efficacy of nilotinib in either an enterocolitis rat model or human enterocolitis. In the present study, we evaluated the efficacy of nilotinib in a chronic indomethacin-induced enterocolitis rat model.

In this study, the weights of the control and experimental rats were monitored daily. At the end of the study, the nilotinib group of rats lost less weight than the indomethacin group of rats, while the control rats gained weight. However, there was no significant difference in the weight changes between the indomethacin and nilotinib groups ($P > 0.05$). In our previous study, the nilotinib group rats lost significantly less weight than the TNBS group rats ($P = 0.047$)^[34]. In another study by Cuzzocrea *et al.*^[42], weight loss was significantly reduced by seven days of treatment with a TK inhibitor, Tyrphostin AG 126, in a dinitrobenzene sulfonic acid-induced colitis animal model.

In recent years, mucosal healing, which is referred to as 'endoscopic remission,' has gained acceptance as a measure of disease activity and as an end point in clinical trials. In the present study, the macroscopic and microscopic pathological scores were significantly lower in the control and nilotinib groups than in the indomethacin group for the small intestine and colon ($P < 0.05$). The control and nilotinib groups were similar in terms of the macroscopic and microscopic scores of the small intestine and colon. These pathological scores were remarkable and indicate the significant mucosal healing effect of nilotinib on the small intestine and colon. These results parallel the results of previous studies. In our previous study, we demonstrated that nilotinib has a significant mucosal healing effect on a TNBS-induced rat model of colitis^[34]. In another study conducted by Cuzzocrea *et al.*^[42], TK inhibitor treatment had a significant histological improvement compared with control rats. Although there are no human studies investigating the use of TK inhibitors in patients with IBD, the case report by Margo *et al.*^[43], in which there was long-standing remission of CD under imatinib

therapy, supports this conclusion. Further experimental investigations can provide more definitive evidence for humans.

PDGF is related to the progression and repair of inflammation and is predictive of both oxidative stress and angiogenesis in the intestine. PDGF is released in response to inflammatory and thrombotic stimuli^[44]. PDGF and its receptors are expressed in mononuclear inflammatory cells in areas of active inflammation in the ulcer base as well as in mucosal inflammation. It plays an important role in neovascularization in acute inflammation, the repair process and fibrogenesis in IBD^[45]. Therefore, control of PDGFR β expression may be beneficial in chronic intestinal inflammation and prevent intestinal fibrosis. In our study, PDGFR β scores were significantly lower in the nilotinib group than in the indomethacin group in the small intestine and colon ($P < 0.05$), while the PDGFR β scores in the control and nilotinib groups were similar. These results parallel those of our previous study, which investigated the effects of nilotinib in a TNBS-induced model of rat colitis^[34]. However, no previous studies have investigated the effect of TK inhibitors on PDGFR β in an enterocolitis animal model. The results of our study suggest that nilotinib demonstrates its effect on mucosal healing in enterocolitis by reducing PDGFR.

TNF- α is expressed on immune cells and plays a critical role in the immune response and pathogenesis of IBD. TNF- α affects the expression of adhesion molecules, fibroblast proliferation, procoagulant factors, initiation of cytotoxic, apoptotic and acute-phase responses^[46]. The TNF- α level correlates with the clinical activity of IBD^[47]. Therefore, the management of IBD has dramatically changed with the advent of biological therapies. In our study, the levels of serum and tissue TNF- α levels were similar in the nilotinib and indomethacin groups. Similarly, our previous study showed that nilotinib has no significant effect on the TNF- α levels in a TNBS-induced model of colitis in rats^[34]. These results indicated that nilotinib might have no significant effect on the TNF- α levels

in intestinal tissue. However, previous studies have shown that TNF- α and IL-1 β , both proinflammatory cytokines synthesized in the colon, are reduced with TK inhibitors^[42,48]. TNF- α is an unstable molecule that is affected by environmental factors. In a previous study, serum and tissue TNF- α levels were only measured once, and the results may be more reliable if the samples are measured more often.

CD is the result of an imbalanced mucosal T cell response. The recent data have shown that the most powerful therapeutic approaches inhibit T cell survival by inducing apoptosis, and these approaches include effects on complex pathways. Several studies have shown that the absence of PDGFR β induces the intrinsic pathway of TNF-related apoptosis, resulting in ligand-induced apoptosis^[49-51]. In the present study, no significant difference was observed among the groups in terms of the apoptotic index in the small intestine, while the apoptotic indexes in the nilotinib and indomethacin group of rats were higher than in the control group of rats. On the other hand, in the colon, the apoptotic indexes of the nilotinib and indomethacin groups were significantly higher than that of the control group. D'Argenio *et al.*^[52] reported on apoptotic cells and the expression levels of apoptotic proteins and in TNBS-induced colitis over a period of 4 wk. According to the study results, the apoptotic cell count was significantly decreased after the first week, according to the TUNEL method. The similar apoptotic scores that were detected in our study may be because the apoptotic cell peak could not be obtained after 14 d. Furthermore, similar results for the TNF- α levels and apoptosis scores in our study may also suggest that nilotinib has no significant effect on the TNF- α levels and apoptosis.

In conclusion, nilotinib has a significant healing effect on the macroscopic and microscopic pathologic scores and ensures considerable mucosal healing in the indomethacin-induced enterocolitis rat model. While nilotinib decreased the PDGFR α and β levels and apoptotic scores in the colon, it did not have a significant effect on the weight and TNF- α levels. Further experimental investigations could provide more definitive evidence for humans.

COMMENTS

Background

The pathogenesis of inflammatory bowel diseases (IBD) is only partially understood; complex interactions between the immune system, enteric commensal bacteria and the host genotype are thought to underlie IBD development. These particular pathways are targets for drugs used to treat IBD. Side effects, unresponsiveness, high relapse rates, immune-mediated adverse reactions and loss of efficacy with time have limited the use of these drugs. The protein tyrosine kinases (TKs) constitute a large family of homologous proteins that have an important role in regulating intracellular signal transduction pathways and control a range of fundamental cellular process, including growth, metabolism, differentiation, adhesion and apoptosis. To establish a new alternative treatment option, the authors selected a TK inhibitor drug, nilotinib, that affects TNF- α , platelet-derived growth factor receptor (PDGFR) and nitric oxide (NO) synthesis.

Research frontiers

Nilotinib is a TK inhibitor used as an anticancer drug that affects the cornerstone of the steps in the pathogenesis of IBD, including TNF- α , PDGFR and NO synthesis. The authors concluded that nilotinib has a significant healing effect on the macroscopic and microscopic pathologic scores and ensures considerable mucosal healing in the indomethacin-induced enterocolitis rat model. While nilotinib decreased the PDGFR α and β levels and apoptotic scores in the colon, it did not have a significant effect on weight or TNF- α levels.

Innovations and breakthroughs

Available medical treatment options are still far from resulting in complete long-term remission and mucosal healing in IBD. Therefore, it is critically important to identify new medical treatment options for IBD. Nilotinib is a strong TK inhibitor that affects the cornerstone of IBD pathogenesis. Previously, Ataca *et al* demonstrated that nilotinib prevents weight loss, decreases macroscopic and microscopic pathological scores, and improves mucosal healing in a trinitrobenzene sulfonic acid-induced colitis model in rats. In the present study, the authors evaluated the efficacy of nilotinib in a chronic indomethacin-induced enterocolitis rat model.

Applications

The results of this study suggest that nilotinib has a significant effect on the macroscopic and microscopic pathologic scores in the indomethacin-induced enterocolitis rat model. While nilotinib decreased the PDGFR α and β levels and apoptotic scores in the colon, it did not have a significant effect on weight or TNF- α levels. Nilotinib can demonstrate its effect on mucosal healing in enterocolitis by reducing PDGFR. These results suggest that nilotinib may be effective in patients with IBD. The findings of this study shed light on important considerations for future clinical practice. Therefore, further experimental investigations could provide more definitive evidence for humans.

Terminology

IBD are a group of idiopathic, chronic, and relapsing inflammatory conditions of the gastrointestinal tract. The protein TKs constitute a large family of homologous proteins that have an important role in regulating intracellular signal transduction pathways and control a range of fundamental cellular process, including growth, metabolism, differentiation, adhesion and apoptosis. TK inhibitors are drugs that block these pathways. Nilotinib is a highly potent TK inhibitor. Indomethacin-induced enterocolitis is well-established rat model of mucosal inflammation that has been used in the study of IBD pathogenesis.

Peer-review

This is a very well-designed study that focuses on an area of clinical need in the treatment of IBD. The authors investigated the ability of nilotinib to treat various clinical, laboratory and pathological parameters. The authors demonstrated that nilotinib decreased macroscopic and microscopic pathological scores and improved mucosal healing in an indomethacin-induced enterocolitis rat model. The authors showed that while nilotinib decreased PDGFR α and β levels and apoptotic scores in the colon, the treatment did not have a significant effect on weight or TNF- α levels.

REFERENCES

- 1 Loftus EV. Clinical epidemiology of inflammatory bowel disease: Incidence, prevalence, and environmental influences. *Gastroenterology* 2004; **126**: 1504-1517 [PMID: 15168363 DOI: 10.1053/j.gastro.2004.01.063]
- 2 Hanauer SB, Present DH. The state of the art in the management of inflammatory bowel disease. *Rev Gastroenterol Disord* 2003; **3**: 81-92 [PMID: 12776005]
- 3 Sandborn WJ, Feagan BG. Review article: mild to moderate Crohn's disease--defining the basis for a new treatment algorithm. *Aliment Pharmacol Ther* 2003; **18**: 263-277 [PMID: 12895211 DOI: 10.1046/j.1365-2036.2003.01661.x]
- 4 Cammà C, Giunta M, Rosselli M, Cottone M. Mesalamine in the maintenance treatment of Crohn's disease: a meta-analysis adjusted for confounding variables. *Gastroenterology* 1997; **113**: 1465-1473

- [PMID: 9352848 DOI: 10.1053/gast.1997.v113.pm9352848]
- 5 **Lochs H**, Mayer M, Fleig WE, Mortensen PB, Bauer P, Genser D, Petritsch W, Raithel M, Hoffmann R, Gross V, Plauth M, Staun M, Nesje LB. Prophylaxis of postoperative relapse in Crohn's disease with mesalamine: European Cooperative Crohn's Disease Study VI. *Gastroenterology* 2000; **118**: 264-273 [PMID: 10648454 DOI: 10.1016/S0016-5085(00)70208-3]
 - 6 **Stein RB**, Hanauer SB. Medical therapy for inflammatory bowel disease. *Gastroenterol Clin North Am* 1999; **28**: 297-321 [PMID: 10372270 DOI: 10.1016/S0889-8553(05)70058-3]
 - 7 **Feagan BG**, Rochon J, Fedorak RN, Irvine EJ, Wild G, Sutherland L, Steinhart AH, Greenberg GR, Gillies R, Hopkins M. Methotrexate for the treatment of Crohn's disease. The North American Crohn's Study Group Investigators. *N Engl J Med* 1995; **332**: 292-297 [PMID: 7816064 DOI: 10.1056/NEJM199502023320503]
 - 8 **Feagan BG**, Fedorak RN, Irvine EJ, Wild G, Sutherland L, Steinhart AH, Greenberg GR, Koval J, Wong CJ, Hopkins M, Hanauer SB, McDonald JW. A comparison of methotrexate with placebo for the maintenance of remission in Crohn's disease. North American Crohn's Study Group Investigators. *N Engl J Med* 2000; **342**: 1627-1632 [PMID: 10833208 DOI: 10.1056/NEJM200006013422202]
 - 9 **Williams I**, Goh J. Investigational new drugs in the treatment of inflammatory bowel disease: a review. *J Exp Pharmacol* 2011; **3**: 13-19 [DOI: 10.2147/JEP.S7806]
 - 10 **Ardizzone S**, Bianchi Porro G. Inflammatory bowel disease: new insights into pathogenesis and treatment. *J Intern Med* 2002; **252**: 475-496 [PMID: 12472908 DOI: 10.1046/j.1365-2796.2002.01067.x]
 - 11 **Kakkar A**, Wasan SK, Farraye FA. Targeting mucosal healing in Crohn's disease. *Gastroenterol Hepatol (N Y)* 2011; **7**: 374-380 [PMID: 21869869]
 - 12 **Landi B**, Anh TN, Cortot A, Soule JC, Rene E, Gendre JP, Bories P, See A, Metman EH, Florent C. Endoscopic monitoring of Crohn's disease treatment: a prospective, randomized clinical trial. The Groupe d'Etudes Therapeutiques des Affections Inflammatoires Digestives. *Gastroenterology* 1992; **102**: 1647-1653 [PMID: 1568574]
 - 13 **Modigliani R**, Mary JY, Simon JF, Cortot A, Soule JC, Gendre JP, Rene E. Clinical, biological, and endoscopic picture of attacks of Crohn's disease. Evolution on prednisolone. Groupe d'Etude Therapeutique des Affections Inflammatoires Digestives. *Gastroenterology* 1990; **98**: 811-818 [PMID: 2179031]
 - 14 **Mañosa M**, Naves JE, Leal C, Cabré E, Moreno V, Lorenzo-Zuñiga V, Boix J, Domènech E. Does methotrexate induce mucosal healing in Crohn's disease? *Inflamm Bowel Dis* 2010; **16**: 377-378 [PMID: 19575354 DOI: 10.1002/ibd.21015]
 - 15 **Laharie D**, Reffet A, Belleannée G, Chabrun E, Subtil C, Razaire S, Capdepon M, de Lédighen V. Mucosal healing with methotrexate in Crohn's disease: a prospective comparative study with azathioprine and infliximab. *Aliment Pharmacol Ther* 2011; **33**: 714-721 [PMID: 21235604 DOI: 10.1111/j.1365-2036.2010.04569.x]
 - 16 **Sandborn WJ**, Van O EC, Zins BJ, Tremaine WJ, Mays DC, Lipsky JJ. An intravenous loading dose of azathioprine decreases the time to response in patients with Crohn's disease. *Gastroenterology* 1995; **109**: 1808-1817 [PMID: 7498645 DOI: 10.1016/0016-5085(95)90747-5]
 - 17 **D'Haens G**, Geboes K, Ponette E, Penninckx F, Rutgeerts P. Healing of severe recurrent ileitis with azathioprine therapy in patients with Crohn's disease. *Gastroenterology* 1997; **112**: 1475-1481 [PMID: 9136824 DOI: 10.1016/S0016-5085(97)70027-1]
 - 18 **D'Haens G**, Geboes K, Rutgeerts P. Endoscopic and histologic healing of Crohn's (ileo-) colitis with azathioprine. *Gastrointest Endosc* 1999; **50**: 667-671 [PMID: 10536324]
 - 19 **D'Haens GR**, Vermeire S, Van Assche G, Noman M, Aerden I, Van Olmen G, Rutgeerts P. Therapy of metronidazole with azathioprine to prevent postoperative recurrence of Crohn's disease: a controlled randomized trial. *Gastroenterology* 2008; **135**: 1123-1129 [PMID: 18727929 DOI: 10.1053/j.gastro.2008.07.010]
 - 20 **Colombel JF**, Sandborn WJ, Reinisch W, Mantzaris GJ, Kornbluth A, Rachmilewitz D, Lichtiger S, D'Haens G, Diamond RH, Broussard DL, Tang KL, van der Woude CJ, Rutgeerts P. Infliximab, azathioprine, or combination therapy for Crohn's disease. *N Engl J Med* 2010; **362**: 1383-1395 [PMID: 20393175 DOI: 10.1056/NEJMoa0904492]
 - 21 **Rutgeerts P**, Feagan BG, Lichtenstein GR, Mayer LF, Schreiber S, Colombel JF, Rachmilewitz D, Wolf DC, Olson A, Bao W, Hanauer SB. Comparison of scheduled and episodic treatment strategies of infliximab in Crohn's disease. *Gastroenterology* 2004; **126**: 402-413 [PMID: 14762776 DOI: 10.1053/j.gastro.2003.11.014]
 - 22 **Hanauer SB**, Feagan BG, Lichtenstein GR, Mayer LF, Schreiber S, Colombel JF, Rachmilewitz D, Wolf DC, Olson A, Bao W, Rutgeerts P. Maintenance infliximab for Crohn's disease: the ACCENT I randomised trial. *Lancet* 2002; **359**: 1541-1549 [PMID: 12047962 DOI: 10.1016/S0140-6736(02)08512-4]
 - 23 **Rutgeerts P**, Van Assche G, Sandborn WJ, Wolf DC, Geboes K, Colombel JF, Reinisch W, Kumar A, Lazar A, Camez A, Lomax KG, Pollack PF, D'Haens G. Adalimumab induces and maintains mucosal healing in patients with Crohn's disease: data from the EXTEND trial. *Gastroenterology* 2012; **142**: 1102-1111.e2 [PMID: 22326435 DOI: 10.1053/j.gastro.2012.01.035]
 - 24 **Colombel JF**, Lémann M, Bouhnik Y. Endoscopic Mucosal Improvement in Patients With Active Crohn's Disease Treated With Certolizumab Pegol: Week 10 and 54 Results of the Music Trial. *Gastroenterology AGA* 2010; **138**: S166 [DOI: 10.1016/S0016-5085(10)60761-5]
 - 25 **Sandborn WJ**, Colombel JF, Enns R, Feagan BG, Hanauer SB, Lawrance IC, Panaccione R, Sanders M, Schreiber S, Targan S, van Deventer S, Goldblum R, Despain D, Hogge GS, Rutgeerts P. Natalizumab induction and maintenance therapy for Crohn's disease. *N Engl J Med* 2005; **353**: 1912-1925 [PMID: 16267322 DOI: 10.1056/NEJMoa043335]
 - 26 **Papi C**, Fasci-Spurio F, Rogai F, Settesoldi A, Margagnoni G, Annesse V. Mucosal healing in inflammatory bowel disease: treatment efficacy and predictive factors. *Dig Liver Dis* 2013; **45**: 978-985 [PMID: 24018244 DOI: 10.1016/j.dld.2013.07.006]
 - 27 **Dave M**, Loftus EV. Mucosal healing in inflammatory bowel disease-a true paradigm of success? *Gastroenterol Hepatol (N Y)* 2012; **8**: 29-38 [PMID: 22347830]
 - 28 **Robinson DR**, Wu YM, Lin SF. The protein tyrosine kinase family of the human genome. *Oncogene* 2000; **19**: 5548-5557 [PMID: 11114734 DOI: 10.1038/sj.onc.1203957]
 - 29 **Manley PW**, Stiefl N, Cowan-Jacob SW, Kaufman S, Mestan J, Wartmann M, Wiesmann M, Woodman R, Gallagher N. Structural resemblances and comparisons of the relative pharmacological properties of imatinib and nilotinib. *Bioorg Med Chem* 2010; **18**: 6977-6986 [PMID: 20817538 DOI: 10.1016/j.bmc.2010.08.026]
 - 30 **Weisberg E**, Manley PW, Breitenstein W, Brügger J, Cowan-Jacob SW, Ray A, Huntly B, Fabbro D, Fendrich G, Hall-Meyers E, Kung AL, Mestan J, Daley GQ, Callahan L, Catley L, Cavazza C, Azam M, Neuberger D, Wright RD, Gilliland DG, Griffin JD. Characterization of AMN107, a selective inhibitor of native and mutant Bcr-Abl. *Cancer Cell* 2005; **7**: 129-141 [PMID: 15710326 DOI: 10.1016/j.ccr.2005.01.007]
 - 31 **Weisberg E**, Manley P, Mestan J, Cowan-Jacob S, Ray A, Griffin JD. AMN107 (nilotinib): a novel and selective inhibitor of BCR-ABL. *Br J Cancer* 2006; **94**: 1765-1769 [PMID: 16721371 DOI: 10.1038/sj.bjc.6603170]
 - 32 **Manley PW**, Druce P, Fendrich G, Furet P, Liebetanz J, Martiny-Baron G, Mestan J, Trappe J, Wartmann M, Fabbro D. Extended kinase profile and properties of the protein kinase inhibitor nilotinib. *Biochim Biophys Acta* 2010; **1804**: 445-453 [PMID: 19922818 DOI: 10.1016/j.bbapap.2009.11.008]
 - 33 **Rhee CK**, Lee SH, Yoon HK, Kim SC, Lee SY, Kwon SS, Kim YK, Kim KH, Kim TJ, Kim JW. Effect of nilotinib on bleomycin-induced acute lung injury and pulmonary fibrosis in mice. *Respiration* 2011; **82**: 273-287 [PMID: 21659722 DOI: 10.1159/000304492]

- 10.1159/000327719]
- 34 **Ataca P**, Soyuturk M, Karaman M, Unlu M, Sagol O, Dervis Hakim G, Yilmaz O. Nilotinib-mediated mucosal healing in a rat model of colitis. *World J Gastroenterol* 2013; **19**: 6237-6244 [PMID: 24115822 DOI: 10.3748/wjg.v19.i37.6237]
 - 35 **Yamada T**, Deitch E, Specian RD, Perry MA, Sartor RB, Grisham MB. Mechanisms of acute and chronic intestinal inflammation induced by indomethacin. *Inflammation* 1993; **17**: 641-662 [PMID: 7906675 DOI: 10.1007/BF00920471]
 - 36 **Kawada M**, Arihiro A, Mizoguchi E. Insights from advances in research of chemically induced experimental models of human inflammatory bowel disease. *World J Gastroenterol* 2007; **13**: 5581-5593 [PMID: 17948932 DOI: 10.3748/wjg.v13.i42.5581]
 - 37 **Vilaseca J**, Salas A, Guarner F, Rodríguez R, Martínez M, Malagelada JR. Dietary fish oil reduces progression of chronic inflammatory lesions in a rat model of granulomatous colitis. *Gut* 1990; **31**: 539-544 [PMID: 2161781 DOI: 10.1136/gut.31.5.539]
 - 38 **Dieleman LA**, Palmen MJ, Akol H, Bloemena E, Peña AS, Meuwissen SG, Van Rees EP. Chronic experimental colitis induced by dextran sulphate sodium (DSS) is characterized by Th1 and Th2 cytokines. *Clin Exp Immunol* 1998; **114**: 385-391 [PMID: 9844047 DOI: 10.1046/j.1365-2249.1998.00728.x]
 - 39 **Baumgart DC**, Carding SR. Inflammatory bowel disease: cause and immunobiology. *Lancet* 2007; **369**: 1627-1640 [PMID: 17499605 DOI: 10.1016/S0140-6736(07)60750-8]
 - 40 **Engel MA**, Neurath MF. New pathophysiological insights and modern treatment of IBD. *J Gastroenterol* 2010; **45**: 571-583 [PMID: 20213337 DOI: 10.1007/s00535-010-0219-3]
 - 41 **Schlessinger J**. Cell signaling by receptor tyrosine kinases. *Cell* 2000; **103**: 211-225 [PMID: 11057895 DOI: 10.1016/S0092-8674(00)00114-8]
 - 42 **Cuzzocrea S**, McDonald MC, Mazzone E, Mota-Filipe H, Lepore V, Ciccolo A, Terranova ML, Britti D, Caputi AP, Thiemermann C. The tyrosine kinase inhibitor tyrphostin AG 126 reduced the development of colitis in the rat. *Lab Invest* 2000; **80**: 1439-1453 [PMID: 11005212 DOI: 10.1038/Labinvest.3780151]
 - 43 **Magro F**, Costa C. Long-standing remission of Crohn's disease under imatinib therapy in a patient with Crohn's disease. *Inflamm Bowel Dis* 2006; **12**: 1087-1089 [PMID: 17075351 DOI: 10.1097/01.mib.0000232468.15950.34]
 - 44 **Krzystek-Korpacka M**, Neubauer K, Matusiewicz M. Platelet-derived growth factor-BB reflects clinical, inflammatory and angiogenic disease activity and oxidative stress in inflammatory bowel disease. *Clin Biochem* 2009; **42**: 1602-1609 [PMID: 19679116 DOI: 10.1016/j.clinbiochem.2009.08.002]
 - 45 **Bonner JC**. Regulation of PDGF and its receptors in fibrotic diseases. *Cytokine Growth Factor Rev* 2004; **15**: 255-273 [PMID: 15207816 DOI: 10.1016/j.cytogfr.2004.03.006]
 - 46 **Baumann H**, Gauldie J. The acute phase response. *Immunol Today* 1994; **15**: 74-80 [PMID: 7512342 DOI: 10.1016/0167-5699(94)90137-6]
 - 47 **Reimund JM**, Wittersheim C, Dumont S, Muller CD, Baumann R, Poindron P, Duclos B. Mucosal inflammatory cytokine production by intestinal biopsies in patients with ulcerative colitis and Crohn's disease. *J Clin Immunol* 1996; **16**: 144-150 [PMID: 8734357 DOI: 10.1007/BF01540912]
 - 48 **De Backer O**, Lefebvre RA. Is there a role for imatinib in inflammatory bowel disease? *Inflamm Bowel Dis* 2008; **14**: 579-581 [PMID: 18050299 DOI: 10.1002/ibd.20320]
 - 49 **Nair DG**, Miller KG, Lourenssen SR, Blennerhassett MG. Inflammatory cytokines promote growth of intestinal smooth muscle cells by induced expression of PDGF-R β . *J Cell Mol Med* 2014; **18**: 444-454 [PMID: 24417820 DOI: 10.1111/jcmm.12193]
 - 50 **Liu Y**, Wang Z, Kwong SQ, Lui EL, Friedman SL, Li FR, Lam RW, Zhang GC, Zhang H, Ye T. Inhibition of PDGF, TGF- β , and Abl signaling and reduction of liver fibrosis by the small molecule Bcr-Abl tyrosine kinase antagonist Nilotinib. *J Hepatol* 2011; **55**: 612-625 [PMID: 21251937 DOI: 10.1016/j.jhep.2010.11.035]
 - 51 **Wang Y**, Mandal D, Wang S, Kleinerman ES, Pollock RE, Lev D, Hayes-Jordan A. Platelet-derived growth factor receptor beta inhibition increases tumor necrosis factor-related apoptosis-inducing ligand (TRAIL) sensitivity: imatinib and TRAIL dual therapy. *Cancer* 2010; **116**: 3892-3902 [PMID: 20564078 DOI: 10.1002/cncr.25107]
 - 52 **D'Argenio G**, Farrace MG, Cosenza V, De Ritis F, Della Valle N, Manguso F, Piacentini M. Expression of apoptosis-related proteins in rat with induced colitis. *Int J Colorectal Dis* 2004; **19**: 451-460 [PMID: 15083321 DOI: 10.1007/s00384-004-0585-5]

P- Reviewer: Benkoe T S- Editor: Yu J L- Editor: A
E- Editor: Zhang DN





Published by **Baishideng Publishing Group Inc**

8226 Regency Drive, Pleasanton, CA 94588, USA

Telephone: +1-925-223-8242

Fax: +1-925-223-8243

E-mail: bpgoffice@wjgnet.com

Help Desk: <http://www.wjgnet.com/esps/helpdesk.aspx>

<http://www.wjgnet.com>



ISSN 1007-9327



9 771007 932045