

Management of early hepatic artery occlusion after liver transplantation with failed rescue

Chih-Yang Hsiao, Cheng-Maw Ho, Yao-Ming Wu, Ming-Chih Ho, Rey-Heng Hu, Po-Huang Lee

Chih-Yang Hsiao, Cheng-Maw Ho, Yao-Ming Wu, Ming-Chih Ho, Rey-Heng Hu, Po-Huang Lee, Department of Surgery, National Taiwan University Hospital and National Taiwan University College of Medicine, Taipei 100, Taiwan

Author contributions: Hsiao CY, Ho CM and Hu RH contributed to data collection, interpretation of data, and drafted the manuscript; Ho MC and Hu RH contributed to study concept and design; Hsiao CY, Ho CM, Wu YM, Ho MC, Hu RH and Lee PH contributed to critical revision of the manuscript.

Conflict-of-interest statement: All authors declare no conflicts of interest.

Open-Access: This article is an open-access article which was selected by an in-house editor and fully peer-reviewed by external reviewers. It is distributed in accordance with the Creative Commons Attribution Non Commercial (CC BY-NC 4.0) license, which permits others to distribute, remix, adapt, build upon this work non-commercially, and license their derivative works on different terms, provided the original work is properly cited and the use is non-commercial. See: <http://creativecommons.org/licenses/by-nc/4.0/>

Correspondence to: Ming-Chih Ho, MD, Attending Surgeon, Department of Surgery, National Taiwan University Hospital and National Taiwan University College of Medicine, Taipei 100, Taiwan. mcho1215@ntu.edu.tw
Telephone: +886-2-23123456
Fax: +886-2-23934358

Received: May 20, 2015
Peer-review started: May 22, 2015
First decision: June 2, 2015
Revised: June 23, 2015
Accepted: August 30, 2015
Article in press: August 31, 2015
Published online: November 28, 2015

Abstract

Hepatic artery thrombosis is a serious complication

after liver transplantation which often results in biliary complications, early graft loss, and patient death. It is generally thought that early hepatic artery thrombosis without urgent re-vascularization or re-transplantation almost always leads to mortality, especially if the hepatic artery thrombosis occurs within a few days after transplantation. This series presents 3 cases of early hepatic artery thrombosis after living donor liver transplantation, in which surgical or endovascular attempts at arterial re-vascularization failed. Unexpectedly, these 3 patients survived with acceptable graft function after 32 mo, 11 mo, and 4 mo follow-up, respectively. The literatures on factors affecting this devastating complication were reviewed from an anatomical perspective. The collective evidence from survivors indicated that modified nonsurgical management after liver transplantation with failed revascularization may be sufficient to prevent mortality from early hepatic artery occlusion. Re-transplantation may be reserved for selected patients with unrecovered graft function.

Key words: Complication; Hepatic artery; Thrombosis; Liver transplantation; Revascularization

© **The Author(s) 2015.** Published by Baishideng Publishing Group Inc. All rights reserved.

Core tip: We present 3 cases of early hepatic artery thrombosis after living donor liver transplantation, in which surgical or endovascular attempts at arterial re-vascularization failed. Unexpectedly, these 3 patients survived with acceptable graft function after 32 mo, 11 mo, and 4 mo follow-up, respectively. The literatures on factors affecting this devastating complication were reviewed from an anatomical perspective. Our three cases raise the possibility that a modified nonsurgical management strategy may be sufficient for recovery from early hepatic artery thrombosis after liver transplantation with failed revascularization procedures.

Hsiao CY, Ho CM, Wu YM, Ho MC, Hu RH, Lee PH. Management of early hepatic artery occlusion after liver transplantation with failed rescue. *World J Gastroenterol* 2015; 21(44): 12729-12734 Available from: URL: <http://www.wjgnet.com/1007-9327/full/v21/i44/12729.htm> DOI: <http://dx.doi.org/10.3748/wjg.v21.i44.12729>

INTRODUCTION

Hepatic artery thrombosis (HAT) is a serious complication after liver transplantation (LT) which often results in biliary complications, early graft loss, and patient death^[1-3]. HAT is defined according to the time of onset, with early HAT occurring 30 d or less after LT and late HAT occurring more than 30 d after LT^[2]. In a large study of 21822 patients who underwent LT^[3], the overall incidence of early HAT was 4.4%, higher in children than in adults (8.3% vs 2.9%), and diagnosed at a median of postoperative day (POD) 7. Early HAT resulted in an overall re-transplantation rate of 53.1% (children higher than adults, 62% vs 50%) and an overall mortality rate of 33.3% (adults higher than children, 34.3% vs 25%)^[3]. It is generally thought that early HAT (especially within the first few days after transplantation) without urgent re-vascularization or re-transplantation almost always leads to mortality. However, in this case series, 3 patients with early HAT after living donor LT with failed arterial re-vascularization survived with acceptable graft function after 32 mo, 11 mo, and 4 mo follow-up, respectively (Table 1). Possible explanations were discussed from an anatomical perspective. Our three cases raise the possibility that a modified nonsurgical management strategy may be sufficient for recovery from early HAT after LT with failed revascularization procedures.

CASE REPORT

Case 1

A 60-year-old woman with recurrent hepatocellular carcinoma (HCC) and hepatitis C virus-related liver cirrhosis underwent living donor LT (right lobe from her 31-year-old son). Hepatic artery anastomosis was performed smoothly under an operating microscope. Extubation was performed on POD 2. However, she had abrupt elevation of liver enzymes and hyperbilirubinemia on POD 7 [alanine transaminase (ALT) 1183 U/L from 211 U/L on POD 6, total bilirubin (T-bil) 4.25 mg/dL from 1.78 mg/dL]. Doppler ultrasonography showed no HA blood flow. CT angiography further disclosed the absence of intrahepatic arterial flow and a hypodense lesion suspected to be an infarction at S7-8 of the liver. Angiography confirmed the diagnosis of thrombosis at the proper HA anastomosis (Figure 1), and the angiographic micro-catheter failed to pass through the occlusion site. She then underwent urgent laparotomy. Re-

anastomosis of the HA failed and the HA graft was not suitable for another attempt at re-anastomosis. Under supportive treatment, the patient's liver function recovered gradually (POD 31: ALT 160 U/L, T-bil 2.02 mg/dL) and she was discharged 31 d after liver transplantation. The patient took aspirin 100 mg daily thereafter. She had 3 episodes of biliary tract infection (BTI) on the 2nd, 4th, and 5th month after LT, which required hospitalization for intravenous antibiotics treatment. CT scan at the post-operative 5th month showed no remarkable intrahepatic duct dilatation or infarction of the liver parenchyma. She has remained well with normal graft function after 32 mo of follow-up.

Case 2

A 49-year-old man with alcoholic liver cirrhosis underwent living donor LT (right lobe from her 23-year-old son). The HA was anastomosed end-to-end under an operating microscope. Extubation was performed on POD 1. Elevation of liver enzymes and hyperbilirubinemia were found on POD 1 (ALT 456 U/L from 17 U/L, T-bil 7.78 mg/dL from 1.73 mg/dL). Doppler ultrasonography showed no HA flow. CT angiography disclosed total occlusion of the grafted HA. An attempt to place an intra-arterial catheter for endovascular management on POD 1 resulted in extravasation distal to the anastomosis site. On POD3, an intra-arterial catheter was placed at the anastomosis site for endovascular thrombolysis, but still no arterial flow was noted. On POD7, the intra-arterial catheter was re-implanted for urokinase infusion (60000 IU/h for 4 h), but angiography on POD8 showed persistent thrombosis at the anastomosis site (Figure 2A). The patient's liver function improved gradually under supportive treatment (POD 17: AST 53 U/L, ALT 169 U/L, T-bil 2.98 mg/dL, D-bil 1.51 mg/dL) and he was discharged on POD 17 after LT. The patient took aspirin 100 mg daily after discharge. In the following 9 mo, he had one episode of BTI at the 7th month after LT which required hospitalization for intravenous antibiotics treatment. Magnetic resonance angiography on the 8th month after LT showed recanalization of the intrahepatic artery *via* another artery (possibly the right inferior phrenic artery; Figure 2B). He has remained well with normal graft function after 11 mo of follow-up.

Case 3

A 13-year-old boy with primary sclerosing cholangitis (after common bile duct excision and Reux-en-Y hepaticojejunostomy at age 11) underwent living donor LT (left lobe from his 44-year-old mother). Hepatic artery anastomosis had been performed twice because of donor artery intima dissection. He had elevated liver enzymes on POD1 (ALT 699 U/L from 61 U/L, T-bil 8.21 mg/dL from 1.77 mg/dL). CT on POD 2 showed occlusion of the proper HA at the anastomosis

Table 1 Demographic and clinical data of patients with early hepatic artery thrombosis after living donor liver transplantation

	Case 1	Case 2	Case 3
Age (yr)	60	49	13
Gender	Female	Male	Male
Indication of LT	HCV/HCC	Alcoholic cirrhosis	PSC
Donor age (yr)/gender	31/male	23/male	44/female
Graft	Right lobe	Right lobe	Left lobe
HA anastomosis condition	9-0, once	9-0, twice	8-0, twice
	82 min	36 + 43 min	30 + 99 min
Time of diagnosis of HAT	POD 7	POD 1	POD 2
Management	Surgical reanastomosis, failed	Angiographic procedure, failed	Angiographic procedure, failed
Discharge time	POD 31	POD 17	POD 36
Follow-ups	32 mo	11 mo	4 mo
	(BTI × 3)	(BTI × 1)	(no BTI)

LT: Liver transplantation; HCV: Hepatitis C virus; HCC: Hepatocellular carcinoma; PSC: Primary sclerosing cholangitis; POD: Postoperative day; BTI: Biliary tract infection.

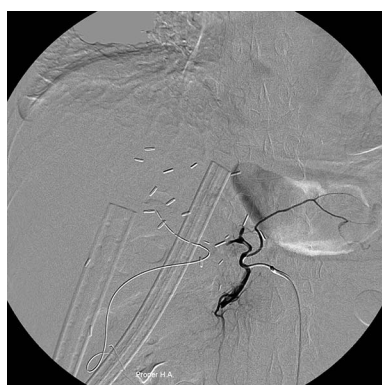

Figure 1 Angiography in a 60-year-old woman 9 d after living donor liver transplantation shows thrombosis at the proper hepatic artery anastomosis, in which endovascular intervention failed to restore blood flow through the hepatic artery occlusion.

site. Angiography showed total occlusion of the proper HA (Figure 3), prompting urokinase 20000 IU injection through a microcatheter with its tip inserted within the thrombosed proper HA, but in vain. The patient's liver function improved gradually with no further treatment of the thrombosed HA (POD 36: ALT 23 U/L, T-bil 0.69 mg/dL). He was discharged on POD 36 after LT and prolonged ascites drainage. He has remained well with normal graft function 4 mo after LT without any BTI episode during follow-up.

DISCUSSION

HAT is a serious complication after LT which often results in patient death and is the 2nd leading cause of early graft failure after primary nonfunction^[1]. The etiology of early HAT is thought to be related not only to surgical factors such as vessel kinking, stenotic anastomosis, and intimal dissection, but also to non-surgical factors such as elderly donors, hypercoagulable state, and rejection episodes^[4]. Risk factors of early HAT reported in literature include cytomegalovirus mismatch, re-transplantation, use

of an arterial conduit, prolonged operation time, low recipient body weight, variant arterial anatomy, lower volume LT hospital^[3], and delay in arterial reperfusion^[4]. Besides, use of continuous rather than interrupted sutures to anastomose the ends of an hepatic artery was associated with higher incidence of HAT^[5]. The most frequent clinical presentation (30%) of early HAT is acute fulminant hepatic failure^[1], and the diagnosis of early HAT is often confirmed by thrombo/embolic occlusion of the hepatic artery on Doppler ultrasonography and/or CT/angiography. Routine Doppler ultrasonography in the first 3 d after LT allows early detection of HAT, and makes rescue interventions before liver damage possible^[6]. Introduction of microvascular reconstruction has significantly decreased the incidence of HAT^[7].

Therapeutic options for HAT include arterial revascularization and re-transplantation. Revascularization could be surgical re-anastomosis (or thrombectomy) or endovascular treatments such as intra-arterial thrombolysis and percutaneous transluminal angioplasty with/without stent placement or balloon dilatation. Although re-transplantation is traditionally the gold standard of therapy for HAT, in areas with organ shortage such as Asia, timely re-transplantation may not be feasible. Thus endovascular or surgical revascularization is often the first line treatment for patients with HAT. Arterial revascularization *via* endovascular or surgical procedures may reduce graft loss and improve outcome in both adult^[8] and pediatric^[9] LT recipients with early HAT. Most studies suggest the use of endovascular urokinase or heparin for HAT after LT^[10], which has a 68% success rate (with internal bleeding as its most common complication)^[10]. Several studies reported that antiplatelet prophylaxis can reduce the incidence of HAT in selected adult patients after LT, with no increase in the incidence of bleeding events and wound complications^[11,12].

HAT causes ischemic injury of the biliary system and liver parenchyma leading to biliary necrosis

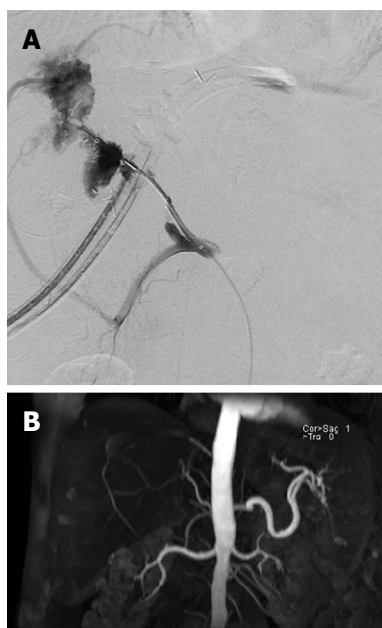


Figure 2 Angiography in a 49-year-old man 8 d after living donor liver transplantation shows persistent thrombosis at the anastomosis site of hepatic artery (A), however magnetic resonance angiography at the 8th month after liver transplantation shows recanalization of intrahepatic artery via right inferior phrenic artery (B).

and the formation of liver abscesses^[1,2]. In our 3 cases, endovascular or surgical revascularization was performed but failed to restore blood flow. However, the grafts functioned well, without the need for re-transplantation. Recently, Boleslawski *et al.*^[13] recommended HA ligation as a reasonable option for HA ruptures following LT. Of the seven patients who received HA ligation for HA rupture, six survived well with functional grafts during follow-up. It is unclear why these patients did not develop severe ischemic cholangiopathy. Looking at this problem from an anatomical perspective, the biliary system has three zones with different blood supplies: the intrahepatic bile ducts, hilar ducts, and extrahepatic bile ducts. The intrahepatic bile ducts are surrounded by a rich microvascular network (the peribiliary plexus)^[14]. Some experimental studies have supported the suggestion of arteriportal communication through the peribiliary plexus^[15]. The peribiliary plexus represents a collateral source of arterial blood to the liver when the hepatic artery is occluded^[16]. Therefore, biliary ischemia of the distal bile ducts usually occurs because of injury to the arteries supplying the distal extrahepatic ducts but is not always inevitable because of the existence of arteriportal collaterals^[17]. If the hepatic ducts of a liver graft were transected at a proximal level during the operation to remove the living donor's liver, the risk of devastating biliary ischemia after HA occlusion would be expected to be lower because proximal hepatic ducts behave more like the intrahepatic ducts. In 2 of our 3 cases, the bile ducts of the liver grafts were proximally transected, supporting our hypothesis.

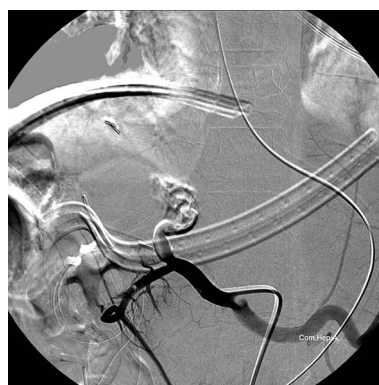


Figure 3 Angiography in a 13-year-old boy 2 d after living donor liver transplantation shows total occlusion of the proper hepatic artery despite injection of 10000 IU of urokinase through a microcatheter with tip inserted into the thrombosed proper hepatic artery.

In case 1, the bile ducts in the right lobe liver graft had two orifices, and in case 3, left donor hepatectomy was performed. Moreover, in a rat model of liver transplantation, arterial reconstruction was regarded as unnecessary and thus not routinely performed^[18]. Recent studies reported the same survival rate in LT rats with HA reconstruction and LT rats without HA reconstruction (though the latter are associated with more graft parenchymal damage in the early postoperative period)^[15]. The detail mechanism of hepatic arterial collateral formation *via* inferior phrenic artery is not clear, however, arterial collaterals through the bare area of liver in recurrent hepatocellular carcinoma after transarterial chemoembolization is not uncommon.

Development of HAT within 7 d of LT is an indication of emergency transplant status (UNOS status 1)^[19]. However, emergency LT and especially emergency re-transplantation are often associated with lower patient and graft survival as compared with non-emergency LT and elective re-transplantation^[20-23]. Considering that the real outcome of early HAT may not be as bad as once thought, patients may not need to undergo high risk emergency re-transplantation routinely. As a result, we recommend a short-term “wait and see” policy when patients developed early HAT even if it happens within 7 d of LT, as long as their biochemical and hemodynamic status remains relatively stable. Re-transplantation may be reserved for select patients who present with unrecovered graft function after early HAT and fail to be rescued by endovascular or surgical intervention. Besides, mesenteric arteriovenous shunt (partial portal arterialization) had been reported effective in preventing hepatic failure caused by interruption of hepatic artery flow, and might also be an option to gain time until collateral arterial vessels develop or re-transplant^[24]. In summary, our cases illustrate that very early HAT without successful urgent re-vascularization or urgent re-transplantation may not always lead to mortality. In patients with very early HAT, urgent endovascular intervention or surgical

exploration for re-vascularization is recommended. However, when re-vascularization fails, observation with supportive care such as maintaining relatively high blood pressure and arterial patency by anti-platelet therapy may be a feasible strategy. Re-transplantation may be preserved for selected cases such as those who fail to recover graft function.

COMMENTS

Case characteristics

Three patients presented with symptoms of liver dysfunction within one week after living-donor liver transplantations.

Clinical diagnosis

Hepatic artery thrombosis after living donor liver transplantations.

Differential diagnosis

Primary graft nonfunction, rejection, portal vein thrombosis.

Laboratory diagnosis

The three patients had various degree of elevation of liver enzymes and hyperbilirubinemia.

Imaging diagnosis

For three cases, computed tomographic angiography scan showed occlusion of hepatic artery.

Pathological diagnosis

No pathological diagnosis in these three cases.

Treatment

The first patient underwent urgent surgical re-anastomosis of the hepatic artery but failed. All of the three patients underwent endovascular treatment but failed.

Related reports

One recent study recommended hepatic artery ligation as a reasonable option for hepatic artery ruptures following liver transplantations.

Term explanation

Hepatic artery thrombosis is a serious complication after liver transplantation which often results in biliary complications, early graft loss, and patient death.

Experiences and lessons

These three cases raise the possibility that a modified nonsurgical management strategy may be sufficient for recovery from early hepatic artery thrombosis after liver transplantation with failed revascularization procedures.

Peer-review

The authors have described three cases of early hepatic artery thrombosis after living donor liver transplantation, in which surgical or endovascular attempts at arterial re-vascularization failed. Unexpectedly, these 3 patients survived with acceptable graft function after 32 mo, 11 mo, and 4 mo follow-up, respectively. These cases outlines that a modified nonsurgical management strategy may be sufficient for recovery from early hepatic artery thrombosis.

REFERENCES

- 1 **Pareja E**, Cortes M, Navarro R, Sanjuan F, López R, Mir J. Vascular complications after orthotopic liver transplantation: hepatic artery thrombosis. *Transplant Proc* 2010; **42**: 2970-2972 [PMID: 20970585 DOI: 10.1016/j.transproceed.2010.07.063]
- 2 **Wu L**, Zhang J, Guo Z, Tai Q, He X, Ju W, Wang D, Zhu X, Ma Y, Wang G, Hu A. Hepatic artery thrombosis after orthotopic liver transplant: a review of the same institute 5 years later. *Exp Clin Transplant* 2011; **9**: 191-196 [PMID: 21649568 DOI: 10.1053/jlts.2001.22040]
- 3 **Bekker J**, Ploem S, de Jong KP. Early hepatic artery thrombosis after liver transplantation: a systematic review of the incidence, outcome and risk factors. *Am J Transplant* 2009; **9**: 746-757 [PMID: 19298450 DOI: 10.1111/j.1600-6143.2008.02541.x]
- 4 **Warner P**, Fusai G, Glantzounis GK, Sabin CA, Rolando N, Patch D, Sharma D, Davidson BR, Rolles K, Burroughs AK. Risk factors associated with early hepatic artery thrombosis after orthotopic liver transplantation - univariable and multivariable analysis. *Transpl Int* 2011; **24**: 401-408 [PMID: 21210866 DOI: 10.1111/j.1432-2277.2010.01211.x]
- 5 **Coelho GR**, Leitao AS, Cavalcante FP, Brasil IR, Cesar-Borges G, Costa PE, Barros MA, Lopes PM, Nascimento EH, da Costa JI, Viana CF, Rocha TD, Vasconcelos JB, Garcia JH. Continuous versus interrupted suture for hepatic artery anastomosis in liver transplantation: differences in the incidence of hepatic artery thrombosis. *Transplant Proc* 2008; **40**: 3545-3547 [PMID: 19100434 DOI: 10.1016/j.transproceed.2008.06.066]
- 6 **García-Criado A**, Gilabert R, Nicolau C, Real I, Arguis P, Bianchi L, Vilana R, Salmerón JM, García-Valdecasas JC, Brú C. Early detection of hepatic artery thrombosis after liver transplantation by Doppler ultrasonography: prognostic implications. *J Ultrasound Med* 2001; **20**: 51-58 [PMID: 11149529]
- 7 **Uchiyama H**, Hashimoto K, Hiroshige S, Harada N, Soejima Y, Nishizaki T, Shimada M, Suehiro T. Hepatic artery reconstruction in living-donor liver transplantation: a review of its techniques and complications. *Surgery* 2002; **131**: S200-S204 [PMID: 11821811 DOI: 10.1067/msy.2002.119577]
- 8 **Scarinci A**, Sainz-Barriga M, Berrevoet F, van den Bossche B, Colle I, Geerts A, Rogiers X, van Vlierberghe H, de Hemptinne B, Troisi R. Early arterial revascularization after hepatic artery thrombosis may avoid graft loss and improve outcomes in adult liver transplantation. *Transplant Proc* 2010; **42**: 4403-4408 [PMID: 21168708 DOI: 10.1016/j.transproceed.2010.07.014]
- 9 **Warnaar N**, Polak WG, de Jong KP, de Boer MT, Verkade HJ, Sieders E, Peeters PM, Porte RJ. Long-term results of urgent revascularization for hepatic artery thrombosis after pediatric liver transplantation. *Liver Transpl* 2010; **16**: 847-855 [PMID: 20583091 DOI: 10.1002/lt.22063]
- 10 **Singhal A**, Stokes K, Sebastian A, Wright HI, Kohli V. Endovascular treatment of hepatic artery thrombosis following liver transplantation. *Transpl Int* 2010; **23**: 245-256 [PMID: 20030796 DOI: 10.1111/j.1432-2277.2009.01037.x]
- 11 **Vivarelli M**, La Barba G, Cucchetti A, Lauro A, Del Gaudio M, Ravaioli M, Grazi GL, Pinna AD. Can antiplatelet prophylaxis reduce the incidence of hepatic artery thrombosis after liver transplantation? *Liver Transpl* 2007; **13**: 651-654 [PMID: 17457885 DOI: 10.1002/lt.21028]
- 12 **Shay R**, Taber D, Pilch N, Meadows H, Tischer S, McGillicuddy J, Bratton C, Baliga P, Chavin K. Early aspirin therapy may reduce hepatic artery thrombosis in liver transplantation. *Transplant Proc* 2013; **45**: 330-334 [PMID: 23267805 DOI: 10.1016/j.transproceed.2012.05.075]
- 13 **Boleslawski E**, Bouras AF, Truant S, Liddo G, Herrero A, Badic B, Audet M, Altieri M, Laurent A, Declercq N, Navarro F, Létoublon C, Wolf P, Chiche L, Cherqui D, Pruvot FR. Hepatic artery ligation for arterial rupture following liver transplantation: a reasonable option. *Am J Transplant* 2013; **13**: 1055-1062 [PMID: 23398886 DOI: 10.1111/ajt.12135]
- 14 **Terada T**, Ishida F, Nakanuma Y. Vascular plexus around intrahepatic bile ducts in normal livers and portal hypertension. *J Hepatol* 1989; **8**: 139-149 [PMID: 2541196 DOI: 10.1016/0168-8278(89)90001-9]
- 15 **Cho KJ**, Lunderquist A. The peribiliary vascular plexus: the microvascular architecture of the bile duct in the rabbit and in

- clinical cases. *Radiology* 1983; **147**: 357-364 [PMID: 6836115 DOI: 10.1148/radiology.147.2.6836115]
- 16 **Stapleton GN**, Hickman R, Terblanche J. Blood supply of the right and left hepatic ducts. *Br J Surg* 1998; **85**: 202-207 [PMID: 9501816 DOI: 10.1046/j.1365-2168.1998.00511.x]
 - 17 **Deltenre P**, Valla DC. Ischemic cholangiopathy. *Semin Liver Dis* 2008; **28**: 235-246 [PMID: 18814077 DOI: 10.1055/s-0028-1085092]
 - 18 **Kamada N**, Sumimoto R, Kaneda K. The value of hepatic artery reconstruction as a technique in rat liver transplantation. *Surgery* 1992; **111**: 195-200 [PMID: 1736390]
 - 19 **Hori T**, Gardner LB, Chen F, Baine AM, Hata T, Uemoto S, Nguyen JH. Impact of hepatic arterial reconstruction on orthotopic liver transplantation in the rat. *J Invest Surg* 2012; **25**: 242-252 [PMID: 22571774 DOI: 10.3109/08941939.2011.636476]
 - 20 **Wiesner RH**. MELD/PELD and the allocation of deceased donor livers for status 1 recipients with acute fulminant hepatic failure, primary nonfunction, hepatic artery thrombosis, and acute Wilson's disease. *Liver Transpl* 2004; **10**: S17-S22 [PMID: 15382286 DOI: 10.1002/lt.20273]
 - 21 **Bellido CB**, Martínez JM, Gómez LM, Artacho GS, Diez-Canedo JS, Pulido LB, Acevedo JM, Bravo MA. Indications for and survival after liver retransplantation. *Transplant Proc* 2010; **42**: 637-640 [PMID: 20304211 DOI: 10.1016/j.transproceed.2010.02.017]
 - 22 **Herden U**, Ganschow R, Grabhorn E, Briem-Richter A, Nashan B, Fischer L. Outcome of liver re-transplantation in children--impact and special analysis of early re-transplantation. *Pediatr Transplant* 2014; **18**: 377-384 [PMID: 24802344 DOI: 10.1111/ptr.12264]
 - 23 **Montenovo MI**, Hansen RN, Dick AA. Outcomes of adult liver re-transplant patients in the model for end-stage liver disease era: is it time to reconsider its indications? *Clin Transplant* 2014; **28**: 1099-1104 [PMID: 25041109 DOI: 10.1111/ctr.12423]
 - 24 **Hayashi H**, Takamura H, Tani T, Makino I, Nakagawara H, Tajima H, Kitagawa H, Onishi I, Shimizu K, Ohta T. Partial portal arterialization for hepatic arterial thrombosis after living-donor liver transplant. *Exp Clin Transplant* 2012; **10**: 247-251 [PMID: 22631061 DOI: 10.6002/ect.2011.0173]

P- Reviewer: Hashimoto N **S- Editor:** Ma YJ **L- Editor:** A
E- Editor: Zhang DN





Published by **Baishideng Publishing Group Inc**

8226 Regency Drive, Pleasanton, CA 94588, USA

Telephone: +1-925-223-8242

Fax: +1-925-223-8243

E-mail: bpgoffice@wjgnet.com

Help Desk: <http://www.wjgnet.com/esps/helpdesk.aspx>

<http://www.wjgnet.com>



ISSN 1007-9327



9 771007 932045