

## Retrospective Study

# Innovative technique of needlescopic grasper-assisted single-incision laparoscopic common bile duct exploration: A comparative study

Say-June Kim, Kee-Hwan Kim, Chang-Hyeok An, Jeong-Soo Kim

Say-June Kim, Department of Surgery, Daejeon St. Mary's Hospital, College of Medicine, The Catholic University of Korea, Daejeon 301-723, South Korea

Kee-Hwan Kim, Chang-Hyeok An, Jeong-Soo Kim, Department of Surgery, Uijeongbu St. Mary's Hospital, College of Medicine, The Catholic University of Korea, Uijeongbu-shi 480-717, Gyeonggi-do, South Korea.

**Author contributions:** Kim KH designed the study and approved the final version for publication; Kim SJ, An CH and Kim JS contributed equally to acquiring and analyzing the data; Kim SJ and Kim KH interpreted the data; Kim SJ wrote the manuscript.

**Institutional review board statement:** The study was reviewed and approved by the Ethics Committee at Uijeongbu St. Mary's Hospital (IRB code: UC15RIS10027).

**Informed consent statement:** The IRB has approved the informed consent procedures would appropriately be waived for all subject due to the nature of this study (retrospective analysis).

**Conflict-of-interest statement:** The authors declare that there are no conflicts of interest.

**Data sharing statement:** Technical appendix, statistical code, and dataset available from the corresponding author at keehwan@catholic.ac.kr.

**Open-Access:** This article is an open-access article which was selected by an in-house editor and fully peer-reviewed by external reviewers. It is distributed in accordance with the Creative Commons Attribution Non Commercial (CC BY-NC 4.0) license, which permits others to distribute, remix, adapt, build upon this work non-commercially, and license their derivative works on different terms, provided the original work is properly cited and the use is non-commercial. See: <http://creativecommons.org/licenses/by-nc/4.0/>

**Correspondence to:** Kee-Hwan Kim, MD, PhD, Department of Surgery, Uijeongbu St. Mary's Hospital, College of Medicine,

The Catholic University of Korea, #271, Cheonbo-ro, Uijeongbu-shi 480-717, Gyeonggi-do, South Korea. keehwan@catholic.ac.kr  
Telephone: +82-31-8203562  
Fax: +82-31-8472717

Received: March 26, 2015  
Peer-review started: March 30, 2015  
First decision: May 18, 2015  
Revised: May 22, 2015  
Accepted: September 2, 2015  
Article in press: September 2, 2015  
Published online: December 7, 2015

## Abstract

**AIM:** To investigate the safety and feasibility of needlescopic grasper-assisted single-incision laparoscopic common bile duct exploration (nSIL-CBDE) by comparing the surgical outcomes of this technique with those of conventional laparoscopic CBDE (CL-CBDE).

**METHODS:** We retrospectively analyzed the clinical data of patients who underwent CL-CBDE or nSIL-CBDE for the treatment of common bile duct (CBD) stones between January 2000 and December 2014. For performing nSIL-CBDE, a needlescopic grasper was also inserted through a direct puncture below the right subcostal line after introducing a single-port through the umbilicus. The needlescopic grasper helped obtain the critical view of safety by retracting the gallbladder laterally and by preventing crossing or conflict between laparoscopic instruments. The gallbladder was then partially dissected from the liver bed and used for retraction. CBD stones were usually extracted through a longitudinal supraduodenal choledochotomy, mostly using flushing a copious amount of normal saline through

a ureteral catheter. Afterward, for the certification of CBD clearance, CBDE was performed mostly using a flexible choledochoscope. The choledochotomy site was primarily closed without using a T-tube, and simultaneous cholecystectomies were performed.

**RESULTS:** During the study period, 40 patients underwent laparoscopic CBDE. Of these patients, 20 underwent CL-CBDE and 20 underwent nSIL-CBDE. The operative time for nSIL-CBDE was significantly longer than that for CL-CBDE ( $238 \pm 76$  min *vs*  $192 \pm 39$  min,  $P = 0.007$ ). The stone clearance rate was 100% (40/40) in both groups. Postoperatively, the nSIL-CBDE group required less intravenous analgesic (pethidine) ( $46.5 \pm 63.5$  mg/kg *vs*  $92.5 \pm 120.1$  mg/kg,  $P = 0.010$ ) and had a shorter hospital stay than the CL-CBDE group ( $3.8 \pm 2.0$  d *vs*  $5.1 \pm 1.7$  d,  $P = 0.010$ ). There was no significant difference in the incidence of postoperative complications between the two groups.

**CONCLUSION:** The results of this study suggest that nSIL-CBDE could be safe and feasible while improving cosmetic outcomes when performed by surgeons trained in conventional laparoscopic techniques.

**Key words:** Choledocholithiasis; Choledochotomy; Common bile duct exploration; Laparoscopy; Single-incision laparoscopic surgery

© **The Author(s) 2015.** Published by Baishideng Publishing Group Inc. All rights reserved.

**Core tip:** Though single-incision laparoscopic surgery has been applied in various fields worldwide, the reports on the single-incision laparoscopic common bile duct exploration (SIL-CBDE) are very limited, possibly due to technical difficulties. In this study, we were intended to overcome these difficulties by using additional 2-mm needlescopic grasper. This grasper is separately entered into the right abdomen by a puncture, and helps to form a stable triangulation with the transumbilically placed instruments. Our SIL-CBDE resulted in comparable surgical outcomes as conventional laparoscopic CBDE, indicating that the nSIL-CBDE is not only cosmetically acceptable but also provides both operative safety and feasibility.

Kim SJ, Kim KH, An CH, Kim JS. Innovative technique of needlescopic grasper-assisted single-incision laparoscopic common bile duct exploration: A comparative study. *World J Gastroenterol* 2015; 21(45): 12857-12864 Available from: URL: <http://www.wjgnet.com/1007-9327/full/v21/i45/12857.htm> DOI: <http://dx.doi.org/10.3748/wjg.v21.i45.12857>

## INTRODUCTION

The introduction of single-incision laparoscopic surgery (SILS) has offered significant advantages to patients,

including nearly scarless wounds and reduced wound morbidity<sup>[1-11]</sup>. In the same time, it has also increased the burden on surgeons because the entire operation is performed solely through one small incision. Accordingly, SILS is usually limited to operations in which the procedure is uncomplicated or less technically demanding<sup>[12-14]</sup>. Common bile duct exploration (CBDE) is a complicated surgery that includes a series of steps such as choledochoscopic lithotripsy and common bile duct (CBD) repair. Hence, reports on single-incision laparoscopic (SIL) CBDE are limited<sup>[15-17]</sup>.

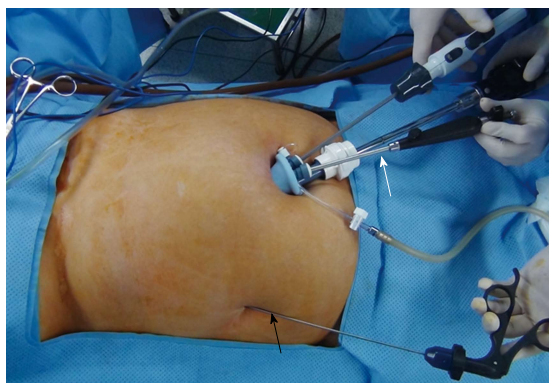
Recent advances in techniques and instruments have led to a progression of laparoscopic CBDE procedure. Moreover, current trends of no T-tube implementation during CBDE have further simplified the procedure<sup>[18-23]</sup>. Thus, these changes have opened wide the way for SIL-CBDE. Here, we describe needlescopic grasper-assisted single-incision CBDE (nSIL-CBDE). This technique is a modification of SIL-CBDE in order to reproduce the environment of laparoscopic CBDE by the addition of a very fine (2-mm) needlescopic grasper apart from the umbilical port. Simple addition of the needlescopic grasper to SIL-CBDE was expected to simultaneously enhance operative proficiency and minimize wound trauma. In this study, we aimed to demonstrate the safety and operative feasibility of nSIL-CBDE by comparing the surgical outcomes of nSIL-CBDE with those of conventional laparoscopic CBDE (CL-CBDE).

## MATERIALS AND METHODS

### Study design and data collection

We performed a retrospective analysis of prospectively collected data from patients who underwent laparoscopic CBDE - either CL-CBDE or nSIL-CBDE - for stone(s) in the Department of Surgery, Uijeongbu St. Mary's Hospital, College of Medicine, the Catholic University of Korea, between January 2000 and December 2014. The Ethics Committee at Uijeongbu St. Mary's Hospital (IRB code: UC15RISI0027) approved the study. A total 40 laparoscopic CBDE procedures were performed during the study period.

Preoperatively, all the patients underwent ultrasonography, computed tomography, or magnetic resonance cholangiography. The inclusion criteria for CL-CBDE and nSIL-CBDE were identical and included all types of CBD stones that were estimated from preoperative evaluations, regardless of the severity of the inflammation or a history of abdominal laparotomy. In March 2012, we first performed nSIL-CBDE, and since then nSIL-CBDE was considered first for all the patients with CBD stone(s). The exclusion criteria for both CL-CBDE and nSIL-CBDE included CBD stone(s) combined with hepatolithiasis, lesion(s) suspected to be malignant, an American Society of Anesthesiologists (ASA) physical status classification of IV or V, severe medical conditions such as a recent history of myo-



**Figure 1** External view of needlescopic grasper-assisted single-incision laparoscopic common bile duct exploration. The needlescopic grasper (black arrow) was used for traction through a direct puncture on the right abdomen along the right anterior axillary line. The snake liver retractor (white arrow) was used for cephalad traction of the liver to obtain better visualization.

cardial infarction, and combined operation(s) outside the biliary tract. The total follow-up duration was 61.1 (6-171) mo.

The operative time was defined as the interval between the initial skin incision and the completion of wound closure as documented by the anesthesiologist. Open conversion was defined as completion of the operation with an incision for open surgery. In terms of postoperative complications, a minor bile leak was defined as bile drainage from the drain site prior to the seventh postoperative day that did not require radiological or operative interventions.

#### **Needlescopic grasper-assisted single-incision laparoscopic common bile duct exploration technique**

Under general anesthesia, patients were placed in the supine position, and the monitor was placed on the right-hand side of the patient, opposite the operating surgeon. In performing CL-CBDE, standard 4-port approach was utilized: one 10-mm infra-umbilical port for laparoscope, one 5-mm subxiphoidal, one 5-mm right flank, and one 5-mm ports along the midclavicular line below the right subcostal region. After meticulous dissecting the Calot's triangle, the critical view of safety was obtained. The cystic artery was clipped and divided, and then cystic duct was clipped. After making 5- to 10-mm vertical choledochotomy, CBD stone retrieval was attempted using a Stonebasket forcep (Olympus), Fogarty catheter, or triflange forceps (through a rigid nephroscope). To confirm the clearance of CBD, intraoperative cholangiography or flexible choledochoscopic exploration was performed. After CBD repairing, the gallbladder was completely removed from the liver, and trocar sites were repaired.

In performing nSIL-CBDE, a single, 25-mm vertical incision was made on the umbilicus and a dissection performed down to the peritoneum. Thereafter, a commercial single-port (SILSTM port; Covidien, Mansfield, MA) was then introduced through the

umbilicus. The instruments used through the single port were a 5-mm grasper (Echicon Endosurgery, Cincinnati, OH), liver retractor (Snake retractor; Snowden Pencer, Tucker, GA), and laparoscope (Endoeye Flex 10 mm videoscope; Olympus, Tokyo, Japan). The grasper was replaced intermittently with a hook cautery and suction probe (Endopath Electrosurgery Probe Plus II; Echicon Endo-Surgery, Cincinnati, OH) for meticulous dissection. The snake retractor played a substantial role in achieving operative vision by pushing the hepatic hilum upwards in the direction of the cephalad. Endograb™ internal retractor (Virtual Ports, Misgav, Israel) was intermittently used to assist in obtaining optimal retraction of the liver.

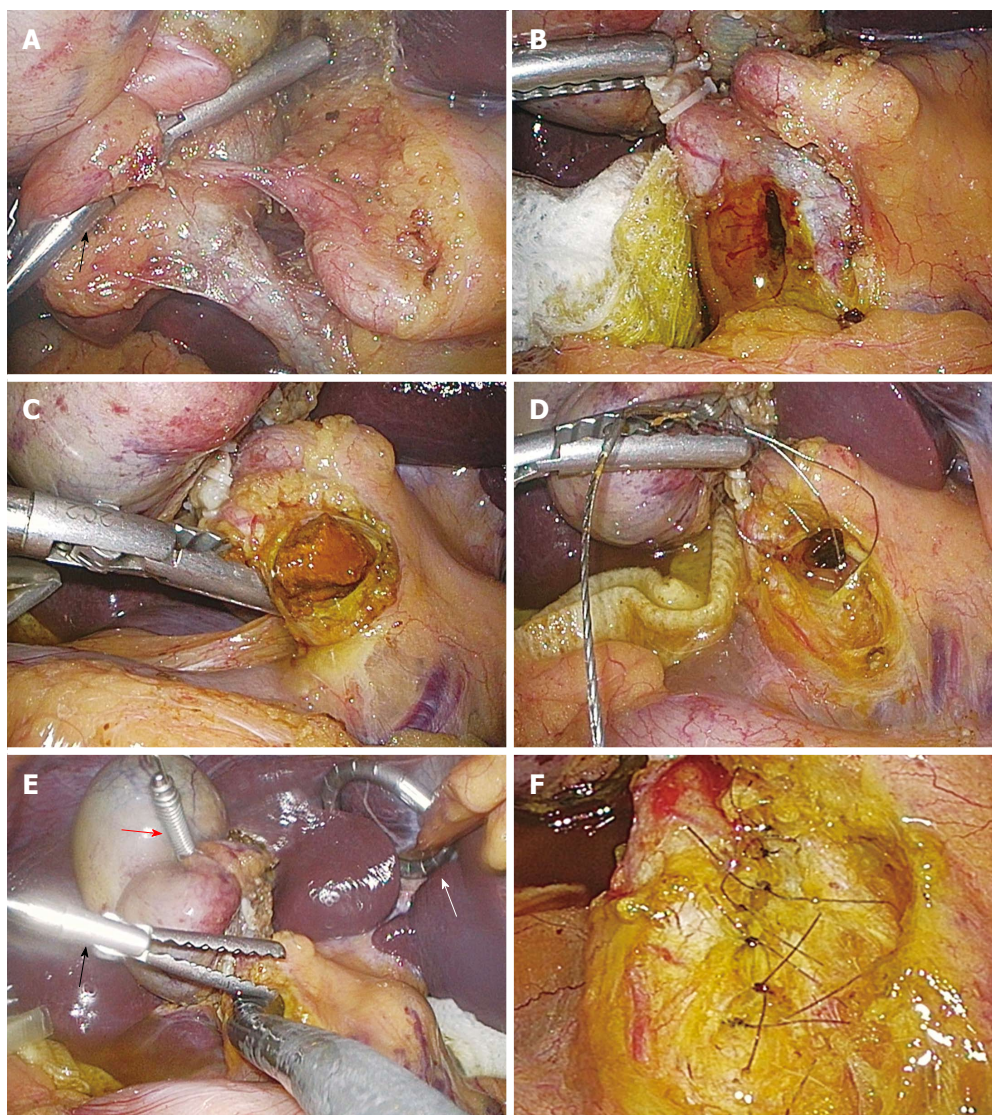
After abdominal insufflation, a needlescopic grasper (Minilap Grasper, Stryker, San Jose, CA or EndoRelief, Hirata Precision Co., Japan) was also inserted through a direct puncture below the right subcostal line along the right anterior axillary line (Figure 1). The needlescopic grasper helped obtain the critical view of safety (CVS)<sup>[24]</sup> by retracting the gallbladder laterally and by preventing crossing or conflict between laparoscopic instruments.

After dissection and identification of cystic artery and duct, they were ligated with 5-mm Hem-o-lok® clips (Weck Closure Systems, Research Triangle Park, NC), and then transected using laparoscopic scissors. The gallbladder was partially dissected from the liver bed and used for retraction. For CBD stone(s) retrieval, a longitudinal supraduodenal choledochotomy was made using an endoknife (Karl-Storz, Tuttlingen, Germany). Stones and debris from the CBD were extracted either by flushing a copious amount of normal saline through a ureteral catheter (3 - 5 French) or by using a Fogarty balloon catheter.

Afterwards, for the detection of residual CBD stone(s), CBDE was performed using a flexible choledochoscope (11-Fr, 30°; Karl-Storz). During choledochoscope manipulation (Figure 2), the needlescopic grasper effectively assisted the insertion of the choledochoscope into the CBD and changes in direction. It gently pushed the choledochoscope toward upper and lower part of the CBD to properly visualize both directions, enabling thorough visualization of both the upper (up to the right and left hepatic ducts) and lower (down to the papilla) portion of the CBD. Any residual stones were removed using a Stonebasket forcep or Fogarty catheter. In extracting residual stones, we selectively used a rigid nephroscope (17-Fr, 6°; Karl-Storz). It accommodates wide graspers, thereby making it possible to extract large stones under the direct vision. Therefore, it was commonly indicated at the time of failing to extract stones using stonebasket forcep or Fogarty catheter.

After CBD clearance, the choledochotomy site was primarily closed without using a T-tube. Initially, it was interruptedly repaired using a laparoscopic suturing device (Lap-suture®; Sejong Medical, Seoul, Korea).





**Figure 2** Operative illustrations of needlescopic grasper-assisted single-incision laparoscopic common bile duct exploration. The needlescopic grasper helped with obtaining a critical view of safety by retracting the gallbladder laterally (A). After ligation and transection of the cystic artery and duct, the common bile duct (CBD) was opened longitudinally using an endoknife (B). The CBD stones were extracted through various methods including direct extraction (C) or the use of a stone basket (D). After extraction of the CBD stones, completion choledochoscopy was performed to check for the presence of remnant stone(s) (E). After CBD clearance, the choledochotomy was primarily closed using either interrupted (F) or running sutures. Black arrows indicate lateral retraction of the gallbladder by the needlescopic grasper. A white and a red arrow indicate the snake retractor and Endograb, respectively.

Lap-suture is a pre-knotted suturing material which enables convenient suturing just by suturing, passing the needle through the pre-knotted hole, and then tightening it by pushing using a bar. Thereafter, it was replaced with continuous suturing using an absorbable monofilament suture (PDS® 6/0 Ethicon; Johnson and Johnson, Somerville, NJ). During intracorporeal suturing, the needlescopic grasper assisted a 5-mm straight needle holder (ENDOPATH Needle holder; Ethicon Endo-surgery) which had been entered *via* the transumbilical port.

We next dissected the gallbladder completely away from the liver. The resected gallbladder was placed in a specimen bag and was subsequently extracted from the abdomen through the umbilical wound. A Jackson-

Pratt drain was placed in the subhepatic space, if necessary. After abdominal deflation, intraumbilical fascial defects and transumbilical skin incisions were closed with interrupted sutures.

### Statistical analysis

Numeric data were presented as the mean and standard deviation or as the median and range. Continuous variables were analyzed using independent *t*-tests or Wilcoxon rank-sum tests. Categorical variables or proportions were compared using Pearson  $\chi^2$  tests or Fisher exact tests when appropriate. Statistical analyses were performed using SPSS version 15.0 (SPSS Inc., Chicago, IL). All *P* values were two-tailed. Statistical significance was accepted for *P*

**Table 1** Demographic and preoperative patient characteristics  
*n* (%)

	CL-LCBDE ( <i>n</i> = 20)	nSIL-CBDE ( <i>n</i> = 20)	<i>P</i> value
Age (yr)	51.0 ± 19.3	60.5 ± 17.2	0.068
Male:female	9:11	9:11	
Body mass index (kg/m <sup>2</sup> )			0.064
mean ± SD	25.00 ± 3.97	22.55 ± 2.69	
median (range)	25.10 (19.60-34.80)	22.45 (17.16-27.69)	
ASA classification			0.010
1	3 (15)	10 (50)	
2	15 (75)	10 (50)	
3	2 (10)	0 (0)	
Comorbidity			0.231
CCI = 0	17 (85)	20 (100)	
CCI ≥ 1	3 (15)	0 (0)	
Previous abdominal surgery)	4 (20)	4 (20)	1.000
Laboratory parameters			
Total leukocyte count (cells/mm <sup>3</sup> )	9117 ± 3756	9123 ± 2569	0.274
ALT (IU/dL)	319 ± 267	215 ± 240	0.068
Total bilirubin (mg/dL)	3.71 ± 2.24	2.18 ± 2.02	0.079
Alkaline phosphatase (IU/dL)	610 ± 321	453 ± 342	0.069
Radiological parameters			
Gallbladder wall thickening (≥ 4 mm)	4 (20)	7 (35)	0.480
Acute cholangitis	17 (85)	14 (70)	0.294
CBD stone(s)			1.000
Definite	18 (90)	19 (95)	
Suspicious	2 (10)	1 (5)	
Indication of CBDE			0.025
Primary intervention	7 (35)	15 (75)	
Secondary intervention	13 (65)	5 (25)	
After ERCP failure	7 (35)	5 (25)	
Remnant CBD stone(s) after ERCP	6 (30)	0 (0)	
Admission route			1.000
ER	12 (60)	13 (65)	
OPD	8 (40)	7 (35)	

ALT: Alanine transaminase; CBD: Common bile duct; CCI: Charlson comorbidity index; CL-CBDE: Conventional laparoscopic common bile duct exploration; ER: Emergency room; ERCP: Endoscopic retrograde cholangiopancreatography; nSIL-CBDE: Needleoscopic grasper-assisted single-incision laparoscopic common bile duct exploration; OPD: Outpatient clinic.

values < 0.05.

## RESULTS

### **Comparison of the baseline characteristics between patients who underwent conventional laparoscopic or needleoscopic grasper-assisted single-incision laparoscopic common bile duct exploration**

A total of 40 patients who underwent laparoscopic CBDE during the study period were included in this study. Of these patients, 20 (50%) underwent CL-CBDE and 20 (50%) underwent nSIL-CBDE. The mean patient age was 55.8 ± 18.7 (25-81) years.

Male patients accounted for 45% (18/40) of the total patients in the study. The mean body mass index (BMI) was 23.8 ± 3.8 (17.2-34.8) kg/m<sup>2</sup>. Table 1 shows a summary of comparisons in patient demographics and preoperative clinical parameters. The two operative groups were similar in age, sex, and BMI. Laboratory and radiological variables were also comparable between the two groups. However, a comparison of the ASA classifications in the two groups revealed that patients with more severe conditions were included in the CL-CBDE group (*P* = 0.010).

We classified the operative indications for laparoscopic CBDE into two categories: primary intervention and secondary intervention. The secondary intervention category was further subdivided into the inability or failure of therapeutic endoscopic retrograde cholangiopancreatography (ERCP) and remnant CBD stone(s) after ERCP attempt(s). We compared the operative indications between the two groups. CL-CBDE group included 37% (7/21) of patients with primary intervention, and nSIL-CBDE group included 75% (15/21) of patients with primary intervention (*P* = 0.025).

### **Comparison of operative and postoperative outcomes**

We next compared the operative results following CL-CBDE and nSIL-CBDE (Table 2). The operative time in the nSIL-CBDE group was significantly longer than that of the CL-CBDE group (238 ± 76 min vs 192 ± 39 min, *P* = 0.007). There was no significant difference in the estimated blood loss. The mean size and number of CBD stones that were retrieved were comparable. Successful retrievals of CBD stone(s) were reported in both groups, and there was no open conversion or addition of another port(s) during the procedure. Two methods were used to detect remnant stone(s) after CBD stone retrieval: completion cholangiography and completion choledochoscopy. All CL-CBDE patients, but not all nSIL-CBDE patients, underwent completion cholangiography (*P* = 0.018). Instead, all the nSIL-CBDE patients underwent completion choledochoscopy. In addition, Jackson-Pratt drains were less frequently placed in the nSIL-CBDE patients than in the CL-CBDE patients (15% vs 95.0%, *P* < 0.001).

Postoperatively, the nSIL-CBDE group had lesser intravenous analgesic (pethidine) administration (46.5 ± 63.5 mg/kg vs 92.5 ± 120.1 mg/kg, *P* = 0.010) and shorter duration of hospitalization (3.8 ± 2.0 d vs 5.1 ± 1.7 d, *P* = 0.010). Postoperative complications were comparable between the two groups. Specifically, CL-CBDE group included one patient with infected subhepatic fluid collection, and nSIL-CBDE group included one patient with minor bile leak and the other patient with subhepatic hematoma.

## DISCUSSION

To our best knowledge, this study was the first to compare CL-CBDE with nSIL-CBDE. Although nSIL-



**Table 2** Operative results of patients who underwent laparoscopic common bile duct exploration *n* (%)

	CL-LCBDE ( <i>n</i> = 20)	nSIL-CBDE ( <i>n</i> = 20)	<i>P</i> value
Operative time (skin to skin, min)			0.007
mean ± SD	192 ± 39	238 ± 76	
median (range)	197.5 (115-245)	215.0 (125-365)	
Estimated blood loss (mL)	132 ± 309	75 ± 161	0.101
Completion cholangiogram	5 (25)	0 (0)	0.018
Completion choledochoscopy	16 (80)	20 (100)	0.037
Stone clearance	20 (100)	20 (100)	1.000
CBD stone			0.348
Single CBD stone	12 (60)	9 (45)	
Multiple CBD stones	8 (40)	11 (55)	
Mean number of CBD stone extracted	1.9 ± 1.7	3.0 ± 3.2	0.316
The largest diameter of CBD stone (mm)			0.624
mean ± SD	12.3 ± 3.8	14.1 ± 4.6	
median (range)	14.0 (5.0-15.8)	13.6 (7.0-20.0)	
Open conversion	0	0	1.000
Addition of another port	0	0	1.000
Gallbladder pathology			0.234
Gangrene/empyema	1 (5)	4 (20)	
Acute inflammation	3 (15)	3 (15)	
Chronic inflammation	16 (80)	13 (65)	
Drain placed	19 (95)	3 (15)	< 0.001
Pethidine dose (mg/kg)	92.5 ± 120.1	46.5 ± 63.5	0.010
Postoperative hospital stay (d)			0.010
mean ± SD	5.1 ± 1.7	3.8 ± 2.0	
median (range)	5.0 (2.0-8.0)	3.0 (2.0-9.0)	
Postoperative complication			0.275
Infected subhepatic collection	1	0	
Minor bile leak	0	1	
Subhepatic seroma	0	1	

CBD: Common bile duct; CL-CBDE: Conventional laparoscopic common bile duct exploration; nSIL-CBDE: Needlescopic grasper-assisted single-incision laparoscopic common bile duct exploration.

CBD increased the total operative time, it significantly reduced both intravenous analgesic administration and the length of hospital stay. The two groups were similar in other variables, including the CBD clearance rate, open conversion rate, and incidence of postoperative complications. Besides, nSIL-CBDE has intuitive advantages of cosmetic superiority and lessened wound morbidity. Therefore, we conclude that nSIL-CBDE is a reasonable alternative to CL-CBDE when performed by a surgeon with sufficient laparoscopic experience.

Patients prefer cosmesis and quality of life, as long as their safety is guaranteed<sup>[25]</sup>. nSIL-CBDE provides cosmetic superiority because it reproduces laparoscopic CBDE environment using the nearly scarless incisions. nSIL-CBDE exclusively leaves two trivial wounds; one is usually concealed in the umbilicus and the other is often negligible because it is made by a puncture of a 2-mm instrument. Moreover, though we could not detect possibly due to relatively small patient

population, nSIL-CBDE is expected to reduce wound morbidity, as the number of port(s) is correlated with the number of the port-related complications, including trocar site hernia, and injury to the vessels, bowel, and other intra-abdominal organs<sup>[26-28]</sup>. Therefore, we believe that reducing the possibility of wound morbidity would be a major advantage of nSIL-CBDE.

Although SILS has been applied in various fields during the past two decades<sup>[11,12,29,30]</sup>, technical difficulties has prevented widespread use of SIL-CBDE to the patients with CBD stone(s). However, as SILS experiences have been accumulated, the more refined surgical techniques and instruments have been overcoming the significant proportion of the technical difficulties. For instance, it has been considered challenging to appropriately manipulate the choledochoscope during SIL-CBDE. In nSIL-CBDE, however, this difficulty can be circumvented by the addition of a convenient guiding grasper which is aligned with the laparoscope in a triangular shape. Likewise, nSIL-CBDE provides a similar environment as CL-CBDE in terms of the handling of the choledochoscope.

CBD repair is one of the most challenging step during laparoscopic CBDE and has been performed with various techniques. The degree of difficulty is particularly increased when the T-tube is inserted into the CBD. However, data from a recent meta-analysis have provided evidence that primary closure instead of T-tube drainage is superior in terms of operative time, overall postoperative complications, and postoperative hospital stay associated with laparoscopic CBDE<sup>[31,32]</sup>. In our study, we performed primary closure in all patients who underwent laparoscopic CBDE. After retrieval of CBD stones, open CBD can be primarily closed by either interrupted or continuous sutures. We initially performed interrupted suturing using laparoscopic suture loops, but later changed to continuous sutures using 6.0 PDS. Recently, an increasing number of reports have described the use of continuous suturing, which is also supported by favorable long-term outcomes<sup>[18,19,22,33]</sup>. We think that although continuous suturing may initially result in increased operative time, with practice, it may actually shorten the total operative time.

We believe that nSIL-CBDE is particularly advantageous in CBD repair. During CL-CBDE, the needle holder, which is usually inserted through an epigastric port, reaches the CBD at an oblique angle. This alignment often hinders the stable performance of CBD repair. However, during nSIL-CBDE, the needle holder is inserted through the umbilicus and reaches the CBD nearly vertically, which allows comfortable suturing. We used two kinds of needlescopic graspers for assistance: the Minilap™ and Endorelie™ graspers. While the Minilap™ has a 2-mm forceps, Endorelie™ has a 5-mm forceps, enabling a grasping power equivalent to that of a 5-mm grasper. After a period of testing, we preferred to use the Endorelie™, because it provided an operative efficiency that was equivalent

to that of the 5-mm grasper.

The nSIL-CBDE group had significantly longer operative times than the CL-CBDE group ( $237.8 \pm 76.4$  min vs  $192.1 \pm 39.0$  min,  $P = 0.007$ ). The most of nSIL-CBDE were performed during a learning period. Therefore, we expected that the operative times of nSIL-CBDE would be shorter once the learning curve was completed. In addition, although the series of nSIL-CBDE are our early experience, nSIL-CBDE significantly reduced the requirement for intravenous analgesic administration ( $P = 0.010$ ) and the duration of hospitalization ( $P = 0.010$ ). However, drain placement is one of the factors influencing postoperative pain<sup>[34]</sup>, and nSIL-CBDE group lesser placed the drain (15% vs 95%,  $P < 0.001$ ). Therefore, further investigation is required to determine whether or not nSIL-CBDE has the potential to reduce postoperative pain.

This study had several limitations. Because it was a retrospective study with a small sample size, future prospective randomized trials are required to definitively determine the efficacy and safety of nSIL-CBDE. In addition, the patient distribution was not completely balanced between the two groups. CL-CBDE group included more patients who had high ASA score ( $P = 0.010$ ). However, it seems not to be substantial because no differences observed in the other variables reflecting degree of inflammation, such as the serum leukocyte count, total bilirubin level, and radiologic findings, between the two groups. Finally, there was a chronological difference between the two groups. A total series of nSIL-CBDE was followed by a series of CL-CBDE. Because both CL-CBDE and nSIL-CBDE are same laparoscopic surgery by nature, the nSIL-CBDE technique could be refined with accumulated experience. However, because most of the nSIL-CBDE were performed during its learning period, we think the comparable surgical outcomes of nSIL-CBDE demonstrate the operative feasibility of this technique.

In conclusion, although nSIL-CBDE increased the total operative time, it could maintain the critical view of safety throughout the procedure. nSIL-CBDE showed similar surgical outcomes as CL-CBDE, especially in the CBD clearance rate and the incidences of open conversion and postoperative complications. Moreover, nSIL-CBDE significantly reduced requirement of postoperative analgesics and length of the postoperative hospital stay. Therefore, we think nSIL-CBDE could provide both operative safety and feasibility while improving cosmetic outcomes.

## COMMENTS

### Background

Common bile duct exploration (CBDE) is a complicated surgery that includes a strenuous series of steps, including choledochoscopic lithotripsy and common bile duct (CBD) repair. Hence, reports on single-incision laparoscopic (SIL) CBDE are limited. The authors were intended to overcome these limitations by the addition of a very fine (2-mm) needleoscopic grasper apart from the umbilical port.

### Research frontiers

In contrast to conventional laparoscopic CBDE which usually requires four incisions for trocar insertion, needleoscopic grasper-assisted single-incision laparoscopic (nSIL) CBDE only requires one umbilical incision and a negligible 2-mm incision.

### Innovations and breakthroughs

SIL-CBDE is very strenuous operation due to the difficulties provoked by the processes of choledochoscopic lithotripsy and common bile duct (CBD) repair. The results shows that simple addition of the needleoscopic grasper to SIL-CBDE enhances operative proficiency while minimizing wound trauma. It was more facilitated by recent trends of primary CBD closure instead of T-tube drainage after CBDE.

### Applications

Although CL-CBDE is a difficult operation, SIL-CBDE is even more difficult. nSIL-CBDE does not require the operator's surgical skill enough to perform SIL-CBDE; only the surgical skill to perform CL-CBDE is sufficient. In addition, nSIL-CBDE seems to be accustomed within a relatively short learning curve. Therefore, nSIL-CBDE could be safe and feasible while improving cosmetic outcomes when performed by surgeons trained in conventional laparoscopic techniques.

### Peer-review

This manuscript has novelty. This is the first study comparing needleoscopic grasper-assisted single incision with conventional laparoscopic common bile duct exploration.

## REFERENCES

- 1 Kim SJ, Ryu GO, Choi BJ, Kim JG, Lee KJ, Lee SC, Oh ST. The short-term outcomes of conventional and single-port laparoscopic surgery for colorectal cancer. *Ann Surg* 2011; **254**: 933-940 [PMID: 22107740 DOI: 10.1097/SLA.0b013e318237826b]
- 2 Weiss HG, Brunner W, Biebl MO, Schirnhöfer J, Pimpl K, Mittermair C, Obrist C, Brunner E, Hell T. Wound complications in 1145 consecutive transumbilical single-incision laparoscopic procedures. *Ann Surg* 2014; **259**: 89-95 [PMID: 23426333 DOI: 10.1097/SLA.0b013e31827b7818]
- 3 Ahmed K, Wang TT, Patel VM, Nagpal K, Clark J, Ali M, Deeba S, Ashrafian H, Darzi A, Athanasiou T, Paraskeva P. The role of single-incision laparoscopic surgery in abdominal and pelvic surgery: a systematic review. *Surg Endosc* 2011; **25**: 378-396 [PMID: 20623239 DOI: 10.1007/s00464-010-1208-6]
- 4 Asakuma M, Hayashi M, Komeda K, Shimizu T, Hirokawa F, Miyamoto Y, Okuda J, Tanigawa N. Impact of single-port cholecystectomy on postoperative pain. *Br J Surg* 2011; **98**: 991-995 [PMID: 21538340 DOI: 10.1002/bjs.7486]
- 5 Chow A, Purkayastha S, Nehme J, Darzi LA, Paraskeva P. Single incision laparoscopic surgery for appendicectomy: a retrospective comparative analysis. *Surg Endosc* 2010; **24**: 2567-2574 [PMID: 20336322 DOI: 10.1007/s00464-010-1004-3]
- 6 Hodgett SE, Hernandez JM, Morton CA, Ross SB, Albrink M, Rosemurgy AS. Laparoendoscopic single site (LESS) cholecystectomy. *J Gastrointest Surg* 2009; **13**: 188-192 [PMID: 19031097 DOI: 10.1007/s11605-008-0735-0]
- 7 Lee PC, Lo C, Lai PS, Chang JJ, Huang SJ, Lin MT, Lee PH. Randomized clinical trial of single-incision laparoscopic cholecystectomy versus minilaparoscopic cholecystectomy. *Br J Surg* 2010; **97**: 1007-1012 [PMID: 20632264 DOI: 10.1002/bjs.7087]
- 8 Marks J, Tacchino R, Roberts K, Onders G, Denoto G, Paraskeva P, Rivas H, Soper N, Rosemurgy A, Shah S. Prospective randomized controlled trial of traditional laparoscopic cholecystectomy versus single-incision laparoscopic cholecystectomy: report of preliminary data. *Am J Surg* 2011; **201**: 369-72; discussion 372-3 [PMID: 21367381 DOI: 10.1016/j.amjsurg.2010.09.012]
- 9 Raman JD, Bagrodia A, Cadeddu JA. Single-incision, umbilical laparoscopic versus conventional laparoscopic nephrectomy: a

- comparison of perioperative outcomes and short-term measures of convalescence. *Eur Urol* 2009; **55**: 1198-1204 [PMID: 18715694 DOI: 10.1016/j.eururo.2008.08.019]
- 10 **Teixeira J**, McGill K, Koshy N, McGinty J, Todd G. Laparoscopic single-site surgery for placement of adjustable gastric band—a series of 22 cases. *Surg Obes Relat Dis* 2010; **6**: 41-45 [PMID: 19560980 DOI: 10.1016/j.soard.2009.03.220]
  - 11 **Vestweber B**, Alfes A, Paul C, Haaf F, Vestweber KH. Single-incision laparoscopic surgery: a promising approach to sigmoidectomy for diverticular disease. *Surg Endosc* 2010; **24**: 3225-3228 [PMID: 20464419 DOI: 10.1007/s00464-010-1090-2]
  - 12 **Carus T**. Current advances in single-port laparoscopic surgery. *Langenbecks Arch Surg* 2013; **398**: 925-929 [PMID: 24037311 DOI: 10.1007/s00423-013-1113-2]
  - 13 **Goel R**, Lomanto D. Controversies in single-port laparoscopic surgery. *Surg Laparosc Endosc Percutan Tech* 2012; **22**: 380-382 [PMID: 23047376 DOI: 10.1097/SLE.0b013e3182615776]
  - 14 **Kim SJ**, Choi BJ, Lee SC. Overview of single-port laparoscopic surgery for colorectal cancers: past, present, and the future. *World J Gastroenterol* 2014; **20**: 997-1004 [PMID: 24574772 DOI: 10.3748/wjg.v20.i4.997]
  - 15 **Chuang SH**, Chen PH, Chang CM, Tsai YF, Lin CS. Single-incision laparoscopic common bile duct exploration with conventional instruments: an innovative technique and a comparative study. *J Gastrointest Surg* 2014; **18**: 737-743 [PMID: 24347312 DOI: 10.1007/s11605-013-2420-1]
  - 16 **Shibao K**, Higure A, Yamaguchi K. Laparoendoscopic single-site common bile duct exploration using the manual manipulator. *Surg Endosc* 2013; **27**: 3009-3015 [PMID: 23436088 DOI: 10.1007/s00464-013-2837-3]
  - 17 **Yeo D**, Mackay S, Martin D. Single-incision laparoscopic cholecystectomy with routine intraoperative cholangiography and common bile duct exploration via the umbilical port. *Surg Endosc* 2012; **26**: 1122-1127 [PMID: 22170316 DOI: 10.1007/s00464-011-2009-2]
  - 18 **Abellán Morcillo I**, Qurashi K, Abrisqueta Carrión J, Martínez Isla A. Laparoscopic common bile duct exploration. Lessons learned after 200 cases. *Cir Esp* 2014; **92**: 341-347 [PMID: 24559592 DOI: 10.1016/j.ciresp.2013.02.010]
  - 19 **Decker G**, Borie F, Millat B, Berthou JC, Deleuze A, Drouard F, Guillon F, Rodier JG, Fingerhut A. One hundred laparoscopic choledochotomies with primary closure of the common bile duct. *Surg Endosc* 2003; **17**: 12-18 [PMID: 12364990 DOI: 10.1007/s00464-002-9012-6]
  - 20 **Dong ZT**, Wu GZ, Luo KL, Li JM. Primary closure after laparoscopic common bile duct exploration versus T-tube. *J Surg Res* 2014; **189**: 249-254 [PMID: 24746254 DOI: 10.1016/j.jss.2014.03.055]
  - 21 **Lee HM**, Min SK, Lee HK. Long-term results of laparoscopic common bile duct exploration by choledochotomy for choledocholithiasis: 15-year experience from a single center. *Ann Surg Treat Res* 2014; **86**: 1-6 [PMID: 24761400 DOI: 10.4174/astr.2014.86.1.1]
  - 22 **Zhang HW**, Chen YJ, Wu CH, Li WD. Laparoscopic common bile duct exploration with primary closure for management of choledocholithiasis: a retrospective analysis and comparison with conventional T-tube drainage. *Am Surg* 2014; **80**: 178-181 [PMID: 24480219]
  - 23 **Zhou Y**, Wu XD, Fan RG, Zhou GJ, Mu XM, Zha WZ, Jia J. Laparoscopic common bile duct exploration and primary closure of choledochotomy after failed endoscopic sphincterotomy. *Int J Surg* 2014; **12**: 645-648 [PMID: 24879343 DOI: 10.1016/j.ijsu.2014.05.059]
  - 24 **Strasberg SM**, Hertl M, Soper NJ. An analysis of the problem of biliary injury during laparoscopic cholecystectomy. *J Am Coll Surg* 1995; **180**: 101-125 [PMID: 8000648]
  - 25 **Varadarajulu S**, Tamhane A, Drelichman ER. Patient perception of natural orifice transluminal endoscopic surgery as a technique for cholecystectomy. *Gastrointest Endosc* 2008; **67**: 854-860 [PMID: 18355816 DOI: 10.1016/j.gie.2007.09.053]
  - 26 **Rao PP**, Rao PP, Bhagwat S. Single-incision laparoscopic surgery - current status and controversies. *J Minim Access Surg* 2011; **7**: 6-16 [PMID: 21197236 DOI: 10.4103/0972-9941.72360]
  - 27 **Lowry PS**, Moon TD, D'Alessandro A, Nakada SY. Symptomatic port-site hernia associated with a non-bladed trocar after laparoscopic live-donor nephrectomy. *J Endourol* 2003; **17**: 493-494 [PMID: 14565880 DOI: 10.1089/089277903769013649]
  - 28 **Marcovici I**. Significant abdominal wall hematoma from an umbilical port insertion. *JSLS* 2001; **5**: 293-295 [PMID: 11548838]
  - 29 **Froggi F**, Sodergren MH, Darzi A, Paraskeva P. Single-incision Laparoscopic Surgery (SILS) in general surgery: a review of current practice. *Surg Laparosc Endosc Percutan Tech* 2010; **20**: 191-204 [PMID: 20729685 DOI: 10.1097/SLE.0b013e3181ed86c6]
  - 30 **Greaves N**, Nicholson J. Single incision laparoscopic surgery in general surgery: a review. *Ann R Coll Surg Engl* 2011; **93**: 437-440 [PMID: 21929912 DOI: 10.1308/003588411X590358]
  - 31 **Wu X**, Yang Y, Dong P, Gu J, Lu J, Li M, Mu J, Wu W, Yang J, Zhang L, Ding Q, Liu Y. Primary closure versus T-tube drainage in laparoscopic common bile duct exploration: a meta-analysis of randomized clinical trials. *Langenbecks Arch Surg* 2012; **397**: 909-916 [PMID: 22644601 DOI: 10.1007/s00423-012-0962-4]
  - 32 **Yin Z**, Xu K, Sun J, Zhang J, Xiao Z, Wang J, Niu H, Zhao Q, Lin S, Li Y. Is the end of the T-tube drainage era in laparoscopic choledochotomy for common bile duct stones is coming? A systematic review and meta-analysis. *Ann Surg* 2013; **257**: 54-66 [PMID: 23059495 DOI: 10.1097/SLA.0b013e318268314b]
  - 33 **Hua J**, Lin S, Qian D, He Z, Zhang T, Song Z. Primary closure and rate of bile leak following laparoscopic common bile duct exploration via choledochotomy. *Dig Surg* 2015; **32**: 1-8 [PMID: 25613528 DOI: 10.1159/000368326]
  - 34 **Eidy M**, Jesmi F, Raygan F, Pishgahroudsari M, Pazouki A. Evaluating the Effect of Drain Site on Abdominal Pain after Laparoscopic Gastric Bypass Surgery for Morbid Obesity: A Randomized Controlled Trial. *Bariatric Surg Pract Patient Care* 2015; **10**: 38-41 [PMID: 25830079 DOI: 10.1089/bari.2014.0032]

**P- Reviewer:** Kassir R, Wada H **S- Editor:** Yu J  
**L- Editor:** A **E- Editor:** Wang CH







Published by **Baishideng Publishing Group Inc**

8226 Regency Drive, Pleasanton, CA 94588, USA

Telephone: +1-925-223-8242

Fax: +1-925-223-8243

E-mail: [bpgoffice@wjgnet.com](mailto:bpgoffice@wjgnet.com)

Help Desk: <http://www.wjgnet.com/esps/helpdesk.aspx>

<http://www.wjgnet.com>



ISSN 1007-9327

