

Contained colonic perforation due to cecal retroflexion

Zhuo Geng, Deepak Agrawal, Amit G Singal, Stephen Kircher, Samir Gupta

Zhuo Geng, Department of Internal Medicine, Case Western Reserve University - Metrohealth Medical Center, Cleveland, OH 44109, United States

Deepak Agrawal, Amit G Singal, Department of Internal Medicine, Division of Digestive and Liver Diseases, University of Texas Southwestern Medical Center, Dallas, TX 75390, United States

Stephen Kircher, Department of Radiology, University of Texas Southwestern Medical Center, Dallas, TX 75390, United States

Samir Gupta, Veterans Affairs San Diego Healthcare System, San Diego, CA 92161, United States

Samir Gupta, Department of Internal Medicine, Division of Gastroenterology, and the Moores Cancer Center, University of California San Diego, San Diego, CA 92103, United States

Author contributions: Geng Z, Gupta S, Singal AG and Agrawal D contributed to conception and design, analysis and interpretation of data; Geng Z and Gupta S contributed to drafting of the article; all authors contributed to critical revision of the article for important intellectual content and final approval of the article.

Supported by (in part) Merit Review Award number 1 I01 HX001574-01A1 (Gupta, PI) from the United States Department of Veterans Affairs Health Services Research and Development Service of the VA Office of Research and Development. The views expressed in this article are those of the author(s) and do not necessarily represent the views of the Department of Veterans Affairs.

Institutional review board statement: The study was reviewed and approved by the University of Texas Southwestern Institutional Review Board, with a waiver of the informed consent requirement for human subjects research.

Informed consent statement: A waiver of informed consent was granted by the University of Texas Southwestern Institutional Review Board.

Conflict-of-interest statement: None of the authors have any relevant financial or personal conflicts of interests to declare related to this work.

Open-Access: This article is an open-access article which was selected by an in-house editor and fully peer-reviewed by external reviewers. It is distributed in accordance with the Creative Commons Attribution Non Commercial (CC BY-NC 4.0) license, which permits others to distribute, remix, adapt, build upon this work non-commercially, and license their derivative works on different terms, provided the original work is properly cited and the use is non-commercial. See: <http://creativecommons.org/licenses/by-nc/4.0/>

Correspondence to: Samir Gupta, MD, MSCS, Veterans Affairs San Diego Healthcare System, 3350 La Jolla Village Dr, MC 111D, San Diego, CA 92161, United States. slgupta@ucsd.edu
Telephone: +1-858-5528585
Fax: +1-858-5524327

Received: August 4, 2015
Peer-review started: August 10, 2015
First decision: September 9, 2015
Revised: September 10, 2015
Accepted: October 23, 2015
Article in press: October 26, 2015
Published online: March 21, 2016

Abstract

Complications of cecal retroflexion performed during colonoscopy have not previously been reported to occur. We report a case of contained colonic perforation secondary to using cecal retroflexion technique to examine the colon, and review available published reports of complications associated with this technique. We conclude that complications may rarely occur with use of cecal retroflexion, and that the clinical benefit of this technique is uncertain.

Key words: Cecal retroflexion; Colonoscopy; Cecum

© **The Author(s) 2016.** Published by Baishideng Publishing Group Inc. All rights reserved.

Core tip: Complications and benefits of cecal retro-

flexion have undergone limited study. This case report of a contained colonic perforation associated with cecal retroflexion suggests that cecal retroflexion may be associated with rare complications that should be considered in the differential diagnosis of patients exposed to the technique presenting with post-colonoscopy complications.

Geng Z, Agrawal D, Singal AG, Kircher S, Gupta S. Contained colonic perforation due to cecal retroflexion. *World J Gastroenterol* 2016; 22(11): 3285-3288 Available from: URL: <http://www.wjgnet.com/1007-9327/full/v22/i11/3285.htm> DOI: <http://dx.doi.org/10.3748/wjg.v22.i11.3285>

INTRODUCTION

Colorectal cancer (CRC) incidence and mortality can be reduced through screening^[1-4]. Nonetheless, available evidence suggests risk reduction for CRC mortality is suboptimal, especially in the proximal colon, ranging from 0% to 50%^[1-4]. Variable outcomes may be partially due to polyps and CRC that are prevalent but missed at the time of colonoscopic examination using standard examination techniques. Cecal retroflexion may reduce CRC risk by improving polyp and CRC detection in the proximal colon^[5]. However, there are few reports on the benefits and potential risks associated with this technique. In this report we present the first case of cecal retroflexion related complication in literature, and review both published and our own experience with cecal retroflexion and associated complications.

CASE REPORT

A 76-year-old female underwent colonoscopy for evaluation of painless hematochezia. Four polyps were removed without use of electrocautery (see Table 1), including a 3 mm ascending colonic polyp could only be visualized and removed *via* cecal retroflexion technique. Four hours post-colonoscopy, the patient presented with acute sharp right lower quadrant abdominal pain, exacerbated by movement, and associated with nausea. She was unable to pass flatus and had not had a bowel movement since the procedure. On exam, she was alert, afebrile, and normotensive. Her abdomen was non-distended, with localized tenderness and guarding in right lower quadrant, but no rebound pain. The white blood cell count was $15.5 \times 10^9/L$. Computed tomography abdomen/pelvis with contrast revealed fluid attenuation along the posterior half of the cecum and ascending colon over a 6 cm extent, beginning at the level of the ileocecal valve, but no free air was noted (Figure 1). The patient's symptoms and imaging findings were felt to be most consistent with contained colonic perforation related to colonoscopy, with use of cecal retroflexion to examine the colon and remove the

Table 1 Characteristics of polyps detected and removed for case patient

Location	Size (mm)	Removal technique	Pathology
Ascending colon	3	Cold biopsy forceps	Tubular adenoma ¹
Transverse colon	4	Cold biopsy forceps	Hyperplastic polyp
Transverse colon	5	Cold snare	Hyperplastic polyp
Rectum	15	Cold snare	Tubulovillous adenoma with focal high grade dysplasia

¹Detected and removed by cecal retroflexion.

polyp. She was admitted for observation, kept nothing by mouth, and treated empirically with intravenous fluids and broad-spectrum antibiotics. On hospitalization day 3, she reported significant improvement in her abdominal pain. She was discharged home on a 14-d course of oral ciprofloxacin and metronidazole. She reported feeling well at 1-wk follow-up with resolution of abdominal pain, normal bowel movements, and full recovery of appetite.

DISCUSSION

Complications of cecal retroflexion have undergone limited study, with prior work reporting no associated major complications^[5-12]. To our knowledge, contained colonic perforation has not been reported as a potential complication of cecal retroflexion. In a review of 1127 colonoscopy reports for individuals who underwent colonoscopy by the senior author (S.G.) over a 6-year period with ($n = 607$) vs without ($n = 520$) exposure to cecal retroflexion, we found that the incidence of major complications was similar (estimated to be 3.3 vs 7.7 complications per 1000 procedures for individuals exposed vs unexposed to cecal retroflexion, $P > 0.05$). Thus, in our own experience, and in the published literature, complications associated with cecal retroflexion appear to be rare.

We speculate that there are two potential explanations for the observed complication reported in this case. One is that the tip of the colonoscope may have torn the cecum wall when the endoscopist straightened the scope from the hairpin-shaped position. The other explanation is that the bending section of the colonoscope may have been pushed deep into the cecum wall while the endoscopist was trying to remove the adenoma located on the proximal side of the ascending colonic fold. We postulate that increased attention to careful control of the scope tip when straightening the scope after the retroflexion maneuver, and care in avoiding pushing the blunt end of the retroflexed scope into the cecal base might reduce future chances of retroflexion associated complications.

The benefit of cecal retroflexion has also undergone limited study. Two randomized control trials assigned patients underwent forward-view colonoscopy to a

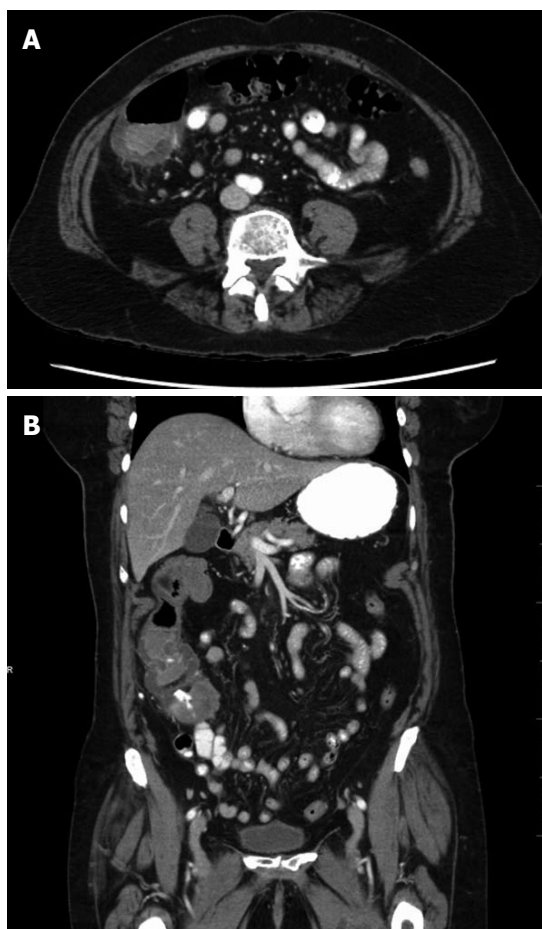


Figure 1 Computed tomographic scan images of contained colonic perforation suspected secondary to cecal retroflexion. The cecum with an associated contained fluid collection is shown in axial (A) and coronal (B) views.

second examination of the proximal colon in either forward view or retroflexed view, but neither showed a benefit of cecal retroflexion over second forward-view examination^[8,11]. In contrast, prospective cohort studies suggested a significant increase in adenoma detection rate when performing retroflexion in patients underwent initial forward-view examination^[5,12].

Overall, we report that use of cecal retroflexion may be associated with rare complications, such as contained colonic perforation. This potential complication should be considered in the differential diagnosis of causes for post-colonoscopy complications among patients exposed to this technique. Given that cecal retroflexion does not appear to have a clear advantage over forward view inspection (especially repeat forward view exam) in detection of adenomas, future studies should focus on other approaches to improve right-sided colonic lesion detection, such as split dose bowel preparation^[13,14], training in subtle polyp recognition, and novel endoscope technology.

COMMENTS

Case characteristics

A 76-year-old female with no significant medical history presented with acute

sharp right lower quadrant abdominal pain 4 h post-colonoscopy, with cecal retroflexion performed and 4 colonic polyps removed during procedure.

Clinical diagnosis

Upon physical examination, abdomen was non-distended, with localized tenderness and guarding in right lower quadrant, but no rebound pain, consistent with post colonoscopy abdominal pain.

Differential diagnosis

Cecal retroflexion-caused perforation/microperforation, postpolypectomy syndrome, or polypectomy-caused perforation/microperforation.

Laboratory diagnosis

White blood cell count was $15.5 \times 10^9/L$.

Imaging diagnosis

Computed tomography abdomen/pelvis with contrast revealed fluid attenuation along the posterior half of the cecum and ascending colon over a 6 cm extent, beginning at the level of the ileocecal valve, but no free air was noted.

Treatment

She was managed with supportive care, kept nothing by mouth, and treated empirically with intravenous fluids and broad-spectrum antibiotics.

Related reports

There are few reports on the benefits and potential risks associated with cecal retroflexion, and none has reported associated major complications.

Term explanation

Cecal retroflexion is a maneuver during scope withdrawal by making a U-turn with the bending section of the colonoscope in the cecum/proximal colon, so the viewing lens is looking backward and the insertion tube is visible to the endoscopist.

Experiences and lessons

Cecal retroflexion associates with rare complications, and does not add proven benefit in cancer detection

Peer-review

This article could be interesting but they need to add more information about personal history of patient and diagnostic result.

REFERENCES

- 1 **Nishihara R**, Wu K, Lochhead P, Morikawa T, Liao X, Qian ZR, Inamura K, Kim SA, Kuchiba A, Yamauchi M, Imamura Y, Willett WC, Rosner BA, Fuchs CS, Giovannucci E, Ogino S, Chan AT. Long-term colorectal-cancer incidence and mortality after lower endoscopy. *N Engl J Med* 2013; **369**: 1095-1105 [PMID: 24047059 DOI: 10.1056/NEJMoa1301969]
- 2 **Baxter NN**, Goldwasser MA, Paszat LF, Saskin R, Urbach DR, Rabeneck L. Association of colonoscopy and death from colorectal cancer. *Ann Intern Med* 2009; **150**: 1-8 [PMID: 19075198]
- 3 **Singh H**, Nugent Z, Demers AA, Kliewer EV, Mahmud SM, Bernstein CN. The reduction in colorectal cancer mortality after colonoscopy varies by site of the cancer. *Gastroenterology* 2010; **139**: 1128-1137 [PMID: 20600026 DOI: 10.1053/j.gastro.2010.06.052]
- 4 **Boland BS**, Rivera-Nieves J, Gupta S. Lower endoscopy and prevention of colon cancer. *Gastroenterology* 2014; **147**: 245-246 [PMID: 24866428 DOI: 10.1053/j.gastro.2014.05.019]
- 5 **Hewett DG**, Rex DK. Miss rate of right-sided colon examination during colonoscopy defined by retroflexion: an observational study. *Gastrointest Endosc* 2011; **74**: 246-252 [PMID: 21679946 DOI: 10.1016/j.gie.2011.04.005]
- 6 **Rex DK**. Accessing proximal aspects of folds and flexures during

- colonoscopy: impact of a pediatric colonoscope with a short bending section. *Am J Gastroenterol* 2003; **98**: 1504-1507 [PMID: 12873570 DOI: 10.1111/j.1572-0241.2003.07470.x]
- 7 **Rex DK**, Khashab M. Colonoscopic polypectomy in retroflexion. *Gastrointest Endosc* 2006; **63**: 144-148 [PMID: 16377332 DOI: 10.1016/j.gie.2005.09.016]
- 8 **Harrison M**, Singh N, Rex DK. Impact of proximal colon retroflexion on adenoma miss rates. *Am J Gastroenterol* 2004; **99**: 519-522 [PMID: 15056095 DOI: 10.1111/j.1572-0241.2004.04070.x]
- 9 **Kessler WR**, Rex DK. Impact of bending section length on insertion and retroflexion properties of pediatric and adult colonoscopes. *Am J Gastroenterol* 2005; **100**: 1290-1295 [PMID: 15929759 DOI: 10.1111/j.1572-0241.2005.41454.x]
- 10 **Pishvaian AC**, Al-Kawas FH. Retroflexion in the colon: a useful and safe technique in the evaluation and resection of sessile polyps during colonoscopy. *Am J Gastroenterol* 2006; **101**: 1479-1483 [PMID: 16863549 DOI: 10.1111/j.1572-0241.2006.00606.x]
- 11 **Kushnir VM**, Oh YS, Hollander T, Chen CH, Sayuk GS, Davidson N, Mullady D, Murad FM, Sharabash NM, Ruettgers E, Dassopoulos T, Easler JJ, Gyawali CP, Edmundowicz SA, Early DS. Impact of retroflexion vs. second forward view examination of the right colon on adenoma detection: a comparison study. *Am J Gastroenterol* 2015; **110**: 415-422 [PMID: 25732415 DOI: 10.1038/ajg.2015.21]
- 12 **Chandran S**, Parker F, Vaughan R, Mitchell B, Fanning S, Brown G, Yu J, Efthymiou M. Right-sided adenoma detection with retroflexion versus forward-view colonoscopy. *Gastrointest Endosc* 2015; **81**: 608-613 [PMID: 25440687 DOI: 10.1016/j.gie.2014.08.039]
- 13 **Kilgore TW**, Abdinoor AA, Szary NM, Schowengerdt SW, Yust JB, Choudhary A, Matteson ML, Puli SR, Marshall JB, Bechtold ML. Bowel preparation with split-dose polyethylene glycol before colonoscopy: a meta-analysis of randomized controlled trials. *Gastrointest Endosc* 2011; **73**: 1240-1245 [PMID: 21628016 DOI: 10.1016/j.gie.2011.02.007]
- 14 **Gurudu SR**, Ramirez FC, Harrison ME, Leighton JA, Crowell MD. Increased adenoma detection rate with system-wide implementation of a split-dose preparation for colonoscopy. *Gastrointest Endosc* 2012; **76**: 603-608.e1 [PMID: 22732876 DOI: 10.1016/j.gie.2012.04.456]

P-Reviewer: Martinez O **S-Editor:** Ma YJ
L-Editor: A **E-Editor:** Liu XM





Published by **Baishideng Publishing Group Inc**

8226 Regency Drive, Pleasanton, CA 94588, USA

Telephone: +1-925-223-8242

Fax: +1-925-223-8243

E-mail: bpgoffice@wjgnet.com

Help Desk: <http://www.wjgnet.com/esps/helpdesk.aspx>

<http://www.wjgnet.com>



ISSN 1007-9327



9 771007 932045