

Periodontal and inflammatory bowel diseases: Is there evidence of complex pathogenic interactions?

Ronaldo Lira-Junior, Carlos Marcelo Figueredo

Ronaldo Lira-Junior, Carlos Marcelo Figueredo, Department of Periodontology, Faculty of Odontology, Rio de Janeiro State University, Rio de Janeiro, RJ 20551-030, Brazil

Author contributions: Lira-Junior R and Figueredo CM contributed equally to this manuscript; both authors conceived the paper, performed the literature search and interpretation, wrote the article, and gave final approval of the manuscript.

Conflict-of-interest statement: The authors declare no potential conflict of interest.

Open-Access: This article is an open-access article which was selected by an in-house editor and fully peer-reviewed by external reviewers. It is distributed in accordance with the Creative Commons Attribution Non Commercial (CC BY-NC 4.0) license, which permits others to distribute, remix, adapt, build upon this work non-commercially, and license their derivative works on different terms, provided the original work is properly cited and the use is non-commercial. See: <http://creativecommons.org/licenses/by-nc/4.0/>

Manuscript source: Invited manuscript

Correspondence to: Dr. Carlos Marcelo Figueredo, Department of Periodontology, Faculty of Odontology, Rio de Janeiro State University, Boulevard 28 de Setembro 157, 20 Andar, Vila Isabel, Rio de Janeiro, RJ 20551-030, Brazil. cmfigueredo@hotmail.com
Telephone: +55-21-28688282

Received: March 29, 2016
Peer-review started: April 4, 2016
First decision: May 30, 2016
Revised: June 29, 2016
Accepted: August 1, 2016
Article in press: August 1, 2016
Published online: September 21, 2016

Abstract

Periodontal disease and inflammatory bowel disease (IBD) are both chronic inflammatory diseases. Their

pathogenesis is mediated by a complex interplay between a dysbiotic microbiota and the host immune-inflammatory response, and both are influenced by genetic and environmental factors. This review aimed to provide an overview of the evidence dealing with a possible pathogenic interaction between periodontal disease and IBD. There seems to be an increased prevalence of periodontal disease in patients with IBD when compared to healthy controls, probably due to changes in the oral microbiota and a higher inflammatory response. Moreover, the induction of periodontitis seems to result in gut dysbiosis and altered gut epithelial cell barrier function, which might contribute to the pathogenesis of IBD. Considering the complexity of both periodontal disease and IBD, it is very challenging to understand the possible pathways involved in their coexistence. In conclusion, this review points to a complex pathogenic interaction between periodontal disease and IBD, in which one disease might alter the composition of the microbiota and increase the inflammatory response related to the other. However, we still need more data derived from human studies to confirm results from murine models. Thus, mechanistic studies are definitely warranted to clarify this possible bidirectional association.

Key words: Periodontal disease; Inflammatory bowel disease; Crohn's disease; Ulcerative colitis; Inflammation

© **The Author(s) 2016.** Published by Baishideng Publishing Group Inc. All rights reserved.

Core tip: The prevalence of periodontal disease seems to be increased in patients with inflammatory bowel disease (IBD). Moreover, the induction of periodontitis seems to result in gut dysbiosis and altered gut epithelial cell barrier function. This review points to a complex pathogenic interaction between periodontal disease and IBD, in which one disease might alter the composition of the microbiota and increase the inflammatory response related to the other disease.

Lira-Junior R, Figueredo CM. Periodontal and inflammatory bowel diseases: Is there evidence of complex pathogenic interactions? *World J Gastroenterol* 2016; 22(35): 7963-7972 Available from: URL: <http://www.wjgnet.com/1007-9327/full/v22/i35/7963.htm> DOI: <http://dx.doi.org/10.3748/wjg.v22.i35.7963>

INTRODUCTION

Periodontal disease is a biofilm-induced chronic inflammatory condition that affects the tooth-supporting tissues, which in its severe form may lead to tooth loss and negatively affect systemic health. Although host immune and inflammatory responses are crucial in the control of this biofilm, their persistence and dysregulation may lead to destruction of periodontal tissues^[1], where neutrophils and macrophages might play an important role^[2,3]. Moreover, it has been shown that periodontitis is associated with several chronic inflammatory diseases, among which inflammatory bowel disease has raised special attention^[4,5].

Inflammatory bowel disease (IBD) is a chronic inflammatory condition of the gastrointestinal tract, which comprises two main forms, Crohn's disease and ulcerative colitis^[6]. The pathogenesis of IBD involves genetic and environmental factors, such as diet, smoking, stress, and microorganisms^[7], and it is characterized by intestinal inflammation and epithelial injury^[8,9]. Crohn's disease (CD) is characterized by macrophage aggregation, frequently forming non-caseating granulomas and transmural inflammation. The terminal ileum is the most common site affected, but the disease can involve any site of the gastrointestinal tract. Ulcerative colitis (UC) is characterized by a significant infiltration of neutrophils within the lamina propria and the crypts, forming micro-abscesses and superficial mucosal ulceration. The distal colon is the most affected region^[6,7]. As previously mentioned, both cell types, macrophages and neutrophils, are also relevant to the pathogenesis of periodontal disease, suggesting that under a similar cytokine signalling, these diseases might share similar pathways.

Indeed, the presence of periodontal disease is more frequent in patients with IBD when compared to controls^[4]. In addition, greater severity and extent of periodontitis have been found in IBD patients when compared to healthy controls^[5]. This might be related to a higher expression of IL-18 in the serum of IBD patients with periodontitis^[10]. However, different cytokine clustering patterns were observed in gingival tissues in comparison to those found in intestinal tissues^[11]. This might suggest that although a common pathway may exist in serum, local cytokine behaviour may be slightly different.

Considering the complexity of both periodontal disease and IBD, it is very challenging to comprehend the possible pathways involved in their coexistence.

Therefore, this review aimed to provide an overview of the evidence dealing with a possible pathogenic interaction between periodontal disease and IBD.

PERIODONTAL DISEASE

Periodontal disease is one of the most prevalent chronic diseases of mankind. Gingivitis, the initial lesion, is a reversible inflammatory condition of the soft tissue surrounding the teeth, induced by a direct immune response to the biofilm formed on the tooth surfaces on a daily basis. Periodontitis is a multifactorial inflammatory disease that destroys the tooth-supporting structures and may lead to tooth loss^[12]. Its severe form affects over 740 million people worldwide^[13]. Figure 1 depicts a simplistic view of healthy periodontal tissue on one side and diseased tissue on the other.

The pathogenesis of periodontal disease, similarly to that of IBD, involves a complex interplay between periodontopathogens and the host immune-inflammatory response, greatly influenced by genetic and environmental factors. Although the presence of microorganisms is required, it is not sufficient for disease initiation^[14]. Rather, it is the unbalanced, persistent host inflammatory reaction against the pathogens that results in the destruction of periodontal tissues^[14].

While it was once believed that a few specific microorganisms, mainly those forming the so-called "red complex" (*Porphyromonas gingivalis*, *Treponema denticola* and *Tannerella forsythia*), were involved in the aetiology of periodontitis, advances in technology and our deeper understanding of microbiome dynamics have pointed to a dysbiotic microbial community as responsible for eliciting a non-resolving chronic inflammation and tissue destruction^[15,16]. This dysbiotic community provides a constant challenge to the innate immune system^[17]. Bacterial components, such as lipopolysaccharides, peptidoglycans and proteases, induce an inflammatory response through stimulation of pattern recognition receptors on inflammatory cells as well as on resident cells.

This host inflammatory response is mediated mainly by neutrophils, monocytes/macrophages, and T and B lymphocytes. As a result, inflammatory mediators, including cytokines, chemokines and proteolytic enzymes, are produced and contribute to tissue degradation and bone resorption. Neutrophils are the first cells to arrive at the inflammatory infiltrate and predominate within the junctional epithelium and gingival crevice^[18]. Previous studies from our group have shown that neutrophils from periodontitis patients are hyper-reactive and contribute to tissue destruction^[3,19,20]. These neutrophils have also been shown to present a cytokine hyper-reactivity^[21] and a dysfunctional chemotaxis^[22].

When the resolution of inflammation is not achieved, antigen-presenting cells are activated by bacterial pro-

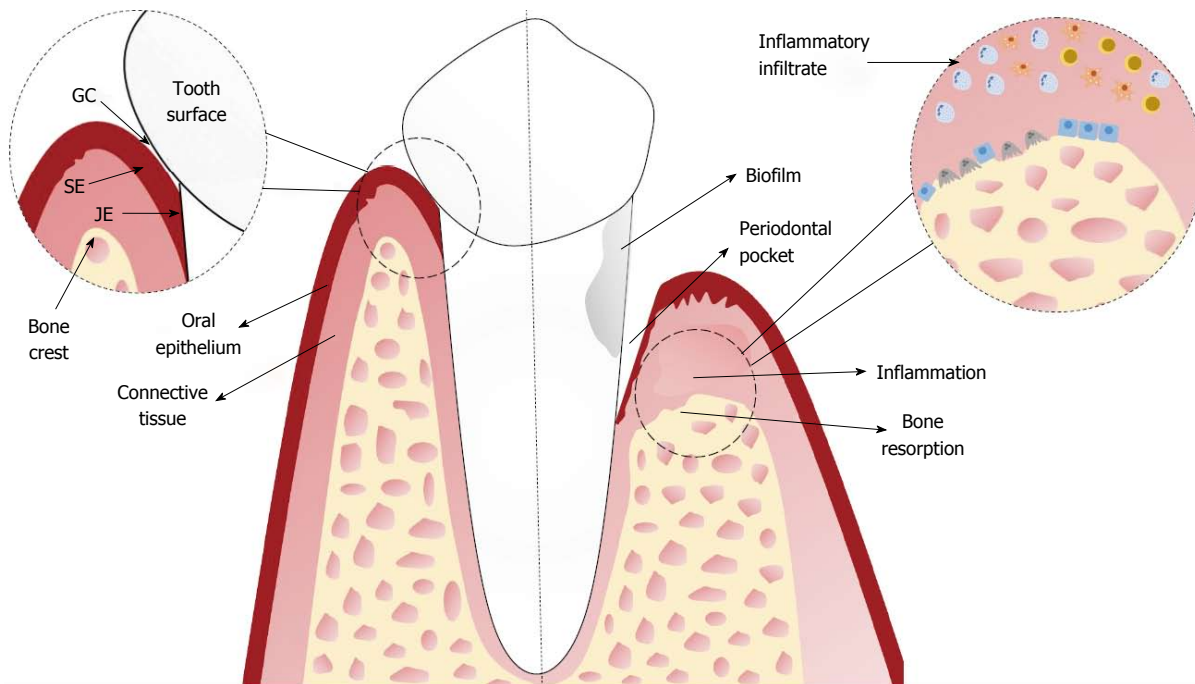


Figure 1 Depiction of the tooth inserted into the alveolar bone in a scenario of periodontal health (left) and periodontitis (right). In periodontal health, the alveolar bone and connective tissue are covered by the oral epithelium. The junctional epithelium (JE) connects the gingiva to the tooth, and the gingival crevice (GC) is the area between the sulcular epithelium (SE) and the tooth surface. In periodontitis, there is a periodontal pocket, a severe inflammatory infiltrate in response to the biofilm, and bone resorption.

ducts and interact with naïve T helper cells (Th0), driving their differentiation into several subsets, such as Th1, Th2, Th17, and Treg. These subsets are characterized according to the cytokines they produce^[18]. For a long time, periodontitis lesions were conceptually defined based on a Th1/Th2 paradigm, with inconclusive studies pointing to both Th1 and Th2 responses as characterizing disease progression^[23]. More recently, the Th17 subset has been implicated in periodontitis pathogenesis, mainly due to its involvement as the specialized lymphocyte linking T-cell activation to bone resorption^[24]. In a non-human primate model of periodontitis, Ebersole *et al*^[25] have shown an overexpression of the Th17/Treg responses (IL-1 β , IL-6, TGF- β , and IL-21) in disease initiation, followed by a persistence of the Th17 response in periodontitis progression.

In conjunction with infiltrating inflammatory cells, gingival fibroblasts take part in the inflammatory process in the periodontium and contribute to the disease persistence^[18]. These cells are able to produce cytokines, chemokines and matrix metalloproteinases^[26-28]. Baek *et al*^[26] have found that gingival fibroblasts from periodontitis patients expressed higher mRNA of IL-1 β , IL-6 and TIMP-3, and lower mRNA of IL-4, than fibroblasts from healthy patients. Periodontal ligament fibroblasts also participate in the inflammatory response and play an important role in alveolar bone remodelling^[29]. When in cell-cell contact with osteoclast precursors, periodontal ligament fibroblasts up-regulated osteoclastogenesis-

related genes and significantly increased the number of osteoclast-like cells^[30].

As a consequence of the unresolved inflammation and an increased concentration of inflammatory mediators, tissue destruction occurs. Matrix metalloproteinases (MMPs) are proteolytic enzymes involved in the homeostasis of connective tissue and the balance between MMPs and their endogenous inhibitors (tissue inhibitor of matrix metalloproteinases - TIMPs) controls the MMP activity^[18,31]. MMPs play an important role in tissue degradation observed in periodontitis and there is strong evidence of their increased activity in periodontitis^[32,33], as well as of an imbalance between MMPs and TIMPs^[34].

Regarding bone loss, the main system regulating normal bone resorption and deposition activities that occur during bone remodelling is RANK/RANKL/OPG. RANKL (receptor-activator of nuclear factor- κ B ligand) is expressed by several cell types and binds to RANK on osteoclast precursors, causing them to differentiate into active cells that secrete enzymes that degrade bone. OPG (osteoprotegerin) is a soluble decoy receptor of RANKL that prevents the RANK-RANKL interaction^[17]. In periodontitis, higher levels of RANKL and lower levels of OPG have been detected in gingival crevicular fluid^[35,36]. Several cytokines, such as IL-1 β , TNF- α , IL-6, and IL-17, have the ability to stimulate bone resorption, whereas others, such as IL-4, IL-10 and TGF- β , act as inhibitors^[37]. Therefore, the inflammatory periodontal milieu, which is rich in pro-resorptive cytokines, can directly affect bone loss

Table 1 Summary of the main epidemiological studies assessing the relationship between inflammatory bowel disease and periodontitis

Ref.	Methods	Principal findings
Flemmig <i>et al</i> ^[74] 1991	107 IBD patients (46 with CD and 61 with UC). Periodontal examination was carried out at two sites of all teeth in two quadrants. There was no control group and results were compared with the assessment of Oral Health of United States Adults	IBD patients presented an 11.9% higher prevalence, but lower severity
Grossner-Schreiber <i>et al</i> ^[42] 2006	62 patients with IBD (46 with CD and 16 with UC) and 59 healthy controls. Periodontal examination was performed in two quadrants	IBD patients had more sites with attachment loss of at least 4 and 5 mm, although periodontal disease was not clearly different from the control group
Brito <i>et al</i> ^[4] 2008	179 patients with IBD (99 with CD and 80 with UC) and 74 controls. Full-mouth periodontal examination was performed	CD and UC patients had higher prevalence of periodontitis than controls, but smoking was an effect modifier
Habashneh <i>et al</i> ^[5] 2012	160 patients with IBD (59 with CD and 101 with UC) and 100 control patients. Full-mouth periodontal examination was performed	Patients with IBD have higher prevalence, severity and extent of periodontitis compared with those having no IBD
Vavricka <i>et al</i> ^[75] 2013	113 patients with IBD (69 with CD and 44 with UC) and 113 controls	Gingivitis and periodontitis markers were higher in patients with IBD than in healthy control. No clear association was found between IBD clinical activity and periodontitis
Koutsochristou <i>et al</i> ^[76] 2015	55 children and adolescents with IBD and 55 controls. Community periodontal treatment needs indices were evaluated	More clinical signs of gingival inflammation and increased periodontal treatment needs were observed in children and adolescents with IBD

CD: Crohn's disease; UC: Ulcerative colitis; IBD: Inflammatory bowel disease.

by increasing RANKL/OPG ratio^[17].

IMPACT OF IBD ON PERIODONTAL DISEASE

The clinical presentation of IBD is characterized by the co-existence of extra-intestinal manifestations, which may affect eyes, joints, skin, liver, pancreas, blood, and mouth^[7]. These extra-intestinal manifestations may precede or follow the intestinal symptoms by years^[38]. Oral manifestations of CD were first described in 1969^[39], and can include pyostomatis vegetans, gingival hyperplasia, papillomatosis of the oral mucosa, vesicular eruptions such as in pemphigus vegetans, periodontitis, and caries^[4,40]. Also, oral and gingival mucosa may be affected by hypertrophy and swelling of lips, cobblestone appearance of the oral mucosa and palate, presence of vesicles, erosions, ulcers, aphthous-like ulcerations, polypoid lesions, and areas of necrosis^[38,41].

Some epidemiological studies have been performed to investigate a possible increase in the prevalence of periodontal disease in patients with IBD. These studies have presented conflicting results. Grössner-Schreiber *et al*^[42] have shown that periodontal status was not significantly distinct from the control group, suggesting the IBD did not appear to enhance the susceptibility to periodontal disease. However, only partial periodontal examinations were performed in that study. Other studies using full-mouth periodontal examination have found an increased prevalence of periodontal disease^[4,5], as well as higher severity and extent of periodontitis, in IBD patients^[5]. These changes seemed to be more pronounced in UC than in CD patients^[4,5]. A summary of the main epidemiological studies

assessing the association between periodontitis and IBD is presented in Table 1.

The reasons why IBD patients presented poorer periodontal health have not been comprehensively investigated. Since both diseases share pathogenic similarities and their development is related to an aberrant immune response to a dysbiotic microbiota, disturbances of these factors are proposed as the mechanisms responsible for the interaction between the diseases.

Microbiological impact

An important topic that has been evaluated as a possible factor responsible for the altered susceptibility to periodontal disease in IBD patients is the oral microbiota. Van Dyke *et al*^[43] have assessed the periodontal microflora of patients with IBD and found a microflora composed predominantly of small, motile, Gram-negative rods that were most consistent with the genus *Wolinella*. Another study has reported decreased overall diversity of the oral microbiota in pediatric patients with CD, but not in patients with UC^[44]. Said *et al*^[45] have found a significant difference in salivary microbiota composition in patients with IBD. The authors also observed a significant increase of the genus *Prevotella* in the salivary microbiota of IBD patients. In mouse models of colitis, changes were seen in the microbiota of the tongue, buccal mucosa and saliva. Also, the microbial community in saliva was more sensitive to change than that in tongue and buccal mucosa^[46].

Our group has analysed the subgingival microbiota in patients with untreated periodontal disease and IBD. We found that several species, such as *Campylobacter gracilis* and *Treponema denticola* differed between

patients with CD, UC and controls in inflamed sites irrespective of the degree of periodontal destruction, and these differences were more pronounced in CD patients. These species might be harmful for the microbe-host interaction^[47]. Kelsen *et al.*^[48], in a cohort of pediatric patients with CD, have shown that Capnocytophaga, Rothia, and TM7 were more abundant in CD relative to healthy controls. The importance of these alterations to the pathogenesis of periodontal disease needs further evaluation.

Immunological impact

The immune-inflammatory response is the main factor driving the tissue damage observed in IBD and periodontitis. Therefore, it is reasonable to assume that the inflammatory response could be the leading factor for posing an increased risk for periodontitis in the IBD population.

Our group investigated the expression of IL-1 β , IL-4, IL-6, IL-10, IL-12p40, IL-12p70, IL-18, and INF- γ in gingival crevicular fluid and serum from patients with untreated periodontitis and IBD. We found a significantly decreased level of IL-4 in inflamed sites without tissue destruction from UC patients in comparison with controls. However, for the other cytokines analysed, the expression in gingival fluid was similar in all groups. In serum, IL-18 showed significantly higher levels in CD and UC patients when compared with controls^[10]. Similarly to the gingival fluid results, we found that there were no significant differences in the expression of an array of cytokines (IL-1 β , IL-4, IL-6, IL-10, IL-21, IL-22, IL-23, IL-25, IL-31, IL-33, IL-17A, IL-17F, IFN- γ , sCD40L, and TNF- α) between CD and UC when assessing the gingival tissue of these patients^[11]. Unpublished data from our group suggests that IBD activity probably increases the inflammatory response in the gingival tissue of IBD patients with periodontitis, as evidenced by significantly higher levels of IL-4, IL-10 and IL-21 and a tendency towards higher levels of IL-1 β .

Some investigations have focused on the salivary alterations in patients with IBD. Increased levels of pro-inflammatory cytokines have been found in IBD patients, especially those with active disease^[49,50]. Aleksandra Nielsen *et al.*^[51] have reported increased salivary levels of IL-6 in patients with CD and not in patients with UC, but only seven patients were analysed in the UC group. Szczeklik *et al.*^[49] have found higher salivary levels of IL-1 β , IL-6, and TNF- α in patients with active CD than in patients with inactive disease and in controls. Interestingly, CD patients also presented significant reductions in total antioxidant capacity, and increased TGF- β (1), nitric oxide, and lipid peroxidation^[50]; UC patients presented higher TGF- β (1) and nitric oxide levels in comparison to the control group^[52].

Decreased lysozyme and increased IgA and LL37 in saliva have also been reported in CD and UC pati-

ents^[46]. It seems that the salivary inflammatory state tended to be slightly higher in UC than in CD group^[46]. It is noteworthy that these studies have not always assessed the presence of periodontal disease, which could have entailed a strong confounding effect on the results, since periodontal disease could alter the level of biomarkers in saliva^[53]. Though it is tempting to speculate that these salivary changes might account for the increased prevalence of periodontitis in IBD patients, how these alterations might affect the development and/or progression of periodontal disease still needs further investigation.

Interestingly, it has also been reported that buccal epithelial cells from pediatric patients with CD without oral lesions released increased amounts of chemokines (CXCL-8, CXCL-9, and CXCL-10) when compared to epithelial cells from healthy controls, children with UC and adults with CD. Adults with CD did not exhibit increased chemokine production. In addition, stimulation with lipopolysaccharide or zymosan resulted in increased chemokine production by epithelial cells from pediatric patients with CD^[54].

Neutrophil behaviour, which plays an important role in the pathogenesis of periodontitis, has also been investigated in patients with IBD. Lamster *et al.*^[55] have shown that peripheral neutrophils from patients with active IBD displayed greater metabolic activity than neutrophils from patients with inactive IBD, which presented greater metabolic activity than neutrophils from patients without systemic disease. On the other hand, salivary neutrophils from IBD patients displayed an average of 45% less activity than salivary neutrophils from patients without systemic disease. The authors speculated that this might relate to a prior activation of peripheral neutrophils in the circulation of IBD patients. This activation in peripheral blood may compromise the ability of the neutrophils to respond to what becomes a second challenge. Van Dyke *et al.*^[43] have revealed a serum-mediated defect in neutrophil chemotaxis in IBD patients with periodontal disease, although neutrophil phagocytosis was normal. Interestingly, in this study, the levels of PGE2 in gingival fluid from IBD patients were four times higher than the levels of the control group^[43].

The impact of single nucleotide polymorphisms on periodontal status in patients with CD has also been a matter of investigation. Stein *et al.*^[56] have found a decreased frequency of *Prevotella intermedia* in carriers of CARD15 mutations compared to the wild type, although the clinical periodontal parameters did not differ significantly between them. On the other hand, Schulz *et al.*^[57] have shown that CD patients carrying the A allele (cDNA-238G>A) or GA haplotype (cDNA-308G>A/cDNA-238G>A) of the TNF- α polymorphisms presented worse clinical periodontal symptoms: increased bleeding on probing, probing depth, and clinical attachment level.

It is interesting to note that in a mouse model

of progressive CD-like ileitis (SAMP1/YitFc), the occurrence of spontaneous periodontal disease was observed in the absence of any exogenous stimuli^[58]. The authors have observed similar alveolar bone resorption on both sides of the mouth, suggesting a systemic phenomenon. Thus, they concluded that periodontal disease and IBD likely share similar aetiopathogenic features and multiple pathogenic mechanisms^[58]. Previously, Oz *et al.*^[59] had shown that the oral administration of the low dose DSS (dextran sulphate sodium) induced alveolar bone loss and chronic colitis, as evidenced by severe shrinkage of the colonic tissue and infiltration of inflammatory cells into the colonic tissue. The authors pointed out that this model elicits chronic inflammatory responses in the gut and oral cavity that mimic aspects of IBD and periodontal disease progression in patients.

Furthermore, Park *et al.*^[60] have used a T-cell transfer model of IBD, using CD4+CD45RB^{high} T cells, to assess the alveolar bone metabolism. It was found that this T cell subset was sufficient for the induction of alveolar bone resorption. It was also reported that alveolar bone marrow stromal cells showed decreased osteogenic and increased adipogenic potential. The authors suggested that diseases such as IBD, through the induction of generalized inflammation, could potentially contribute to alveolar bone resorption. More studies are certainly warranted to further investigate these aspects.

When assessing the possible association between periodontitis and IBD, we have to consider that altered bone metabolism is frequent in IBD patients, where excessive bone loss is a common finding. The exact mechanisms for this are only partially understood, but it has been speculated that corticosteroid therapy, calcium and vitamin D deficiency, hypogonadism, malnutrition, smoking, alcohol consumption, and reduced physical activity are all contributory factors^[61]. Also, systemic inflammatory activity is an important factor for the development of osteoporosis in IBD patients^[62]. These factors could somehow take part in the association between IBD and periodontitis, contributing to the increased alveolar bone loss seen in this group of patients. Our previous study found that IBD patients taking immunosuppressive drugs had significantly lower concentrations of IL-4 and IFN- γ in the gingival fluid when compared with controls^[10].

IMPACT OF PERIODONTAL DISEASE ON IBD

Periodontitis has been associated with other chronic inflammatory diseases for over 20 years. The inflammation evoked by periodontitis could result in low-grade systemic inflammation and thus it is plausible to speculate that periodontitis might influence IBD. Locally produced pro-inflammatory cytokines might enter the systemic circulation, induce an acute-

phase response in the liver, and contribute to several processes, such as an atherosclerotic process^[63].

Also, as large quantities of oral bacteria are constantly swallowed *via* the saliva into the gut, it has been proposed that swallowed *P. gingivalis* may cause alterations to the gut microbiota, thereby leading to increased gut epithelial permeability and endotoxemia, which causes systemic inflammation^[63]. Arimatsu *et al.*^[64] have used a mouse model to evaluate whether endotoxemia is responsible for inflammation in several organs and tissues. Oral administration of *P. gingivalis*, a proposed periodontopathogen, induced changes of bacterial composition of the gut microbiota along with alterations of gut epithelial cell barrier function. Insulin resistance and change of gene expression in adipose tissue and liver were also observed. Interestingly, *P. gingivalis* was not detected in the gut. Thus, the mechanisms responsible for the changes in gut microbiota remain to be established.

The effects of a single administration of *P. gingivalis* on the gut microbiota, gut barrier function, and influx of gut bacteria into the liver were investigated in a mouse model. This single administration had a great impact on the gut microbiota, as evidenced by an increased proportion of the phylum Bacteroidetes and a decreased proportion of the phylum Firmicutes. In addition, the administration of *P. gingivalis* downregulated the expression of the tight junction protein 1 (*tjp-1*) and occluding (*ocln*) in the small intestine, in parallel with an influx of bacteria into the liver. IL-6 expression was significantly elevated and Ror γ t expression was significantly decreased in the small intestine, whereas TNF- α expression was significantly increased in the large intestine^[65]. Another study by the same group, using a ligature-induced periodontitis model, has shown that the ligature placement induced qualitative but not quantitative changes in the gut microbiota, together with trends toward lower expression of *tjp1* and *ocln* in the small intestine and of *ocln* in the large intestine^[66].

Recently, Blasco-Baque *et al.*^[67] set up a mouse model of periodontitis by infecting the periodontal tissue with *P. gingivalis*, *F. nucleatum* and *P. intermedia*. The mice were fed with either a normal chow diet or a diabetogenic, high-fat, carbohydrate-free diet and were then assessed for periodontal and gut microbiota changes. The authors have found that in mice fed a normal chow diet, periodontitis was associated with modest changes of the gut microbiota which included increased members of the *Actinobacteria* and *Deltaproteobacteria* groups. Similarly, in mice fed a high-fat, carbohydrate-free diet, subtle changes of gut microbiota were also observed.

Another study has postulated that salivary microbiota can affect the development of gut microbiota to some extent, since saliva always flows into the gastrointestinal tract, and thus, salivary bacteria have many opportunities to reach the intestine^[46]. In a

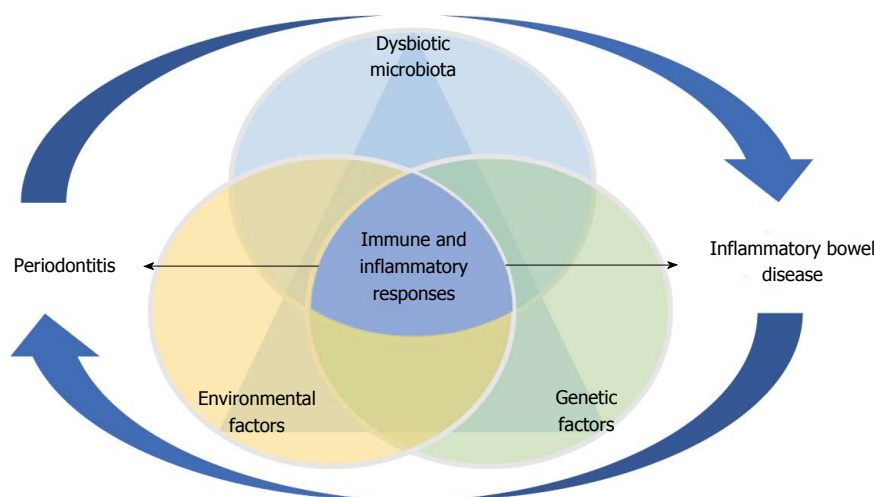


Figure 2 Model of pathogenesis of both periodontal disease and inflammatory bowel disease. This involves a complex interplay between the immune-inflammatory response and a dysbiotic microbiota under the influence of genetic and environmental factors, where the diseases might have a cyclic impact on each other.

study performed to assess the metatranscriptome and metagenome of the human gut microbiota, it was found that oral species, derived from saliva samples, were detectable in the gut at the DNA level, although they showed minimal transcriptional activity there^[68]. Interestingly, it was reported that in patients with liver cirrhosis, most of the patient-enriched species in the gut microbiome are of oral origin, suggesting that oral bacterial species could invade the gut^[69].

Our study that evaluated the subgingival microbiota found that IBD patients harbour higher levels of bacteria that are related to opportunistic infections, such as *S. aureus* and *S. anginosus*^[47]. As shown by Van Dyke *et al.*^[43], the *Wolinella* isolates, the predominant genus in periodontal microflora of IBD patients, had a profound effect on neutrophil chemotaxis *in vitro*, suggesting that this oral pathogen could play a role in IBD as an infectious agent or as a host response modifier. The impact of these disturbances on IBD remains unknown.

In a study performed to assess the effects of probiotic supplementation on ligature-induced periodontitis and intestinal morphology in rats, Messori *et al.*^[70] have found that the animals with ligature-induced periodontitis showed alteration in the intestinal structure, such as defects of the villi, epithelial stratification, basal lamina degeneration, and neutrophil infiltration in the small intestine. Also, ligature-induced periodontitis seemed to have shortened and damaged the villi of the jejunum. Probiotic supplementation attenuated these alterations. Another study by the same group has also shown that ligature-induced periodontitis altered villous height and crypt depth in the small intestine^[71]. Pietropaoli *et al.*^[58], in a mouse model of progressive CD-like ileitis (SAMP1/YitFc), have found evidence of a correlation between the severity of periodontal disease and the severity of ileal scores, and this correlation was independent of age. Furthermore, it was shown, in ApoE^{null} mice, that oral infection with *P. gingivalis*, *T. denticola* and *T. forsythia*

impaired the BH₄/nNOS/NRF2 pathway in proximal, mid- and distal colon. These results raised the possibility that oral bacteria associated with periodontitis might contribute to colonic motility dysfunctions^[72].

A recent study was performed in order to assess the global transcriptome of periodontitis, as well as its association with cardiovascular disease, rheumatoid arthritis and UC, using gingival biopsies. Processes related to immune responses, cell motion, cell death, and homeostasis were up-regulated in all the diseases, but only one gene, pleckstrin (*PLEK*), was commonly up-regulated in all four diseases, suggesting that it could be a key link between periodontitis and these inflammatory diseases. *MMP7* and B-cell lymphoma 2-related protein A1 (*BCL2A1*) were also up-regulated across periodontitis and UC^[73].

Taken all together, the studies cited herein show that a model of the interaction of the pathogenesis of periodontitis and inflammatory bowel disease involves a complex interplay between the immune-inflammatory response and the dysbiotic microbiota, under the influence of environmental and genetic factors. We also suggest that there is an interplay between both diseases, where the diseases might have a cyclic impact on each other, which can be seen in Figure 2.

CONCLUSION

This review points to a complex pathogenic interaction between periodontal disease and IBD, in which one disease might alter the composition of the microbiota and increase the inflammatory response related to the other. However, we still need more data derived from human studies to confirm these preliminary results from murine models. Thus, mechanistic studies are definitely warranted to clarify the possible bidirectional association between periodontitis and IBD.

REFERENCES

- 1 **Garlet GP.** Destructive and protective roles of cytokines in periodontitis: a re-appraisal from host defense and tissue destruction viewpoints. *J Dent Res* 2010; **89**: 1349-1363 [PMID: 20739705 DOI: 10.1177/0022034510376402]
- 2 **Hienz SA, Paliwal S, Ivanovski S.** Mechanisms of Bone Resorption in Periodontitis. *J Immunol Res* 2015; **2015**: 615486 [PMID: 26065002 DOI: 10.1155/2015/615486]
- 3 **Figueredo CM, Fischer RG, Gustafsson A.** Aberrant neutrophil reactions in periodontitis. *J Periodontol* 2005; **76**: 951-955 [PMID: 15948690 DOI: 10.1902/jop.2005.76.6.951]
- 4 **Brito F, de Barros FC, Zaltman C, Carvalho AT, Carneiro AJ, Fischer RG, Gustafsson A, Figueredo CM.** Prevalence of periodontitis and DMFT index in patients with Crohn's disease and ulcerative colitis. *J Clin Periodontol* 2008; **35**: 555-560 [PMID: 18400026 DOI: 10.1111/j.1600-051X.2008.01231.x]
- 5 **Habashneh RA, Khader YS, Alhumouz MK, Jadallah K, Ajlouni Y.** The association between inflammatory bowel disease and periodontitis among Jordanians: a case-control study. *J Periodontol Res* 2012; **47**: 293-298 [PMID: 22050539 DOI: 10.1111/j.1600-0765.2011.01431.x]
- 6 **Xavier RJ, Podolsky DK.** Unravelling the pathogenesis of inflammatory bowel disease. *Nature* 2007; **448**: 427-434 [PMID: 17653185 DOI: 10.1038/nature06005]
- 7 **Neurath MF.** Cytokines in inflammatory bowel disease. *Nat Rev Immunol* 2014; **14**: 329-342 [PMID: 24751956 DOI: 10.1038/nri3661]
- 8 **Baumgart DC, Sandborn WJ.** Crohn's disease. *Lancet* 2012; **380**: 1590-1605 [PMID: 22914295 DOI: 10.1016/S0140-6736(12)60026-9]
- 9 **Danese S, Fiocchi C.** Ulcerative colitis. *N Engl J Med* 2011; **365**: 1713-1725 [PMID: 22047562 DOI: 10.1056/NEJMra1102942]
- 10 **Figueredo CM, Brito F, Barros FC, Menegat JS, Pedreira RR, Fischer RG, Gustafsson A.** Expression of cytokines in the gingival crevicular fluid and serum from patients with inflammatory bowel disease and untreated chronic periodontitis. *J Periodontol Res* 2011; **46**: 141-146 [PMID: 20701671 DOI: 10.1111/j.1600-0765.2010.01303.x]
- 11 **Menegat JS, Lira-Junior R, Siqueira MA, Brito F, Carvalho AT, Fischer RG, Figueredo CM.** Cytokine expression in gingival and intestinal tissues of patients with periodontitis and inflammatory bowel disease: An exploratory study. *Arch Oral Biol* 2016; **66**: 141-146 [PMID: 26946440 DOI: 10.1016/j.archoralbio.2016.02.018]
- 12 **Kinane DF.** Causation and pathogenesis of periodontal disease. *Periodontol 2000* 2001; **25**: 8-20 [PMID: 11155179 DOI: 10.1034/j.1600-0757.2001.22250102.x]
- 13 **Kassebaum NJ, Bernabé E, Dahiya M, Bhandari B, Murray CJ, Marcenes W.** Global burden of severe periodontitis in 1990-2010: a systematic review and meta-regression. *J Dent Res* 2014; **93**: 1045-1053 [PMID: 25261053 DOI: 10.1177/0022034514552491]
- 14 **Graves D.** Cytokines that promote periodontal tissue destruction. *J Periodontol* 2008; **79**: 1585-1591 [PMID: 18673014 DOI: 10.1902/jop.2008.080183]
- 15 **Wang GP.** Defining functional signatures of dysbiosis in periodontitis progression. *Genome Med* 2015; **7**: 40 [PMID: 25926890 DOI: 10.1186/s13073-015-0165-z]
- 16 **Hajishengallis G, Lamont RJ.** Beyond the red complex and into more complexity: the polymicrobial synergy and dysbiosis (PSD) model of periodontal disease etiology. *Mol Oral Microbiol* 2012; **27**: 409-419 [PMID: 23134607 DOI: 10.1111/j.2041-1014.2012.00663.x]
- 17 **Darveau RP.** Periodontitis: a polymicrobial disruption of host homeostasis. *Nat Rev Microbiol* 2010; **8**: 481-490 [PMID: 20514045 DOI: 10.1038/nrmicro2337]
- 18 **Yucel-Lindberg T, Båge T.** Inflammatory mediators in the pathogenesis of periodontitis. *Expert Rev Mol Med* 2013; **15**: e7 [PMID: 23915822 DOI: 10.1017/erm.2013.8]
- 19 **Figueredo CM, Gustafsson A, Asman B, Bergström K.** Expression of intracellular elastase activity in peripheral neutrophils from patients with adult periodontitis. *J Clin Periodontol* 2000; **27**: 572-577 [PMID: 10959783 DOI: 10.1034/j.1600-051x.2000.027008572.x]
- 20 **Figueredo CM, Gustafsson A, Asman B, Bergström K.** Increased release of elastase from in vitro activated peripheral neutrophils in patients with adult periodontitis. *J Clin Periodontol* 1999; **26**: 206-211 [PMID: 10223390 DOI: 10.1034/j.1600-051X.1999.260402.x]
- 21 **Ling MR, Chapple IL, Matthews JB.** Peripheral blood neutrophil cytokine hyper-reactivity in chronic periodontitis. *Innate Immun* 2015; **21**: 714-725 [PMID: 26055820 DOI: 10.1177/1753425915589387]
- 22 **Roberts HM, Ling MR, Insall R, Kalna G, Spengler J, Grant MM, Chapple IL.** Impaired neutrophil directional chemotactic accuracy in chronic periodontitis patients. *J Clin Periodontol* 2015; **42**: 1-11 [PMID: 25360483 DOI: 10.1111/jcpe.12326]
- 23 **Gaffen SL, Hajishengallis G.** A new inflammatory cytokine on the block: re-thinking periodontal disease and the Th1/Th2 paradigm in the context of Th17 cells and IL-17. *J Dent Res* 2008; **87**: 817-828 [PMID: 18719207 DOI: 10.1177/154405910808700908]
- 24 **Sato K, Suematsu A, Okamoto K, Yamaguchi A, Morishita Y, Kadono Y, Tanaka S, Kodama T, Akira S, Iwakura Y, Cua DJ, Takayanagi H.** Th17 functions as an osteoclastogenic helper T cell subset that links T cell activation and bone destruction. *J Exp Med* 2006; **203**: 2673-2682 [PMID: 17088434 DOI: 10.1084/jem.20061775]
- 25 **Ebersole JL, Kirakodu S, Novak MJ, Stromberg AJ, Shen S, Orraca L, Gonzalez-Martinez J, Burgos A, Gonzalez OA.** Cytokine gene expression profiles during initiation, progression and resolution of periodontitis. *J Clin Periodontol* 2014; **41**: 853-861 [PMID: 24975876 DOI: 10.1111/jcpe.12286]
- 26 **Baek KJ, Choi Y, Ji S.** Gingival fibroblasts from periodontitis patients exhibit inflammatory characteristics in vitro. *Arch Oral Biol* 2013; **58**: 1282-1292 [PMID: 24011303 DOI: 10.1016/j.archoralbio.2013.07.007]
- 27 **Scheres N, Laine ML, de Vries TJ, Everts V, van Winkelhoff AJ.** Gingival and periodontal ligament fibroblasts differ in their inflammatory response to viable *Porphyromonas gingivalis*. *J Periodontol Res* 2010; **45**: 262-270 [PMID: 19778323 DOI: 10.1111/j.1600-0765.2009.01229.x]
- 28 **Kida Y, Kobayashi M, Suzuki T, Takeshita A, Okamoto Y, Hanazawa S, Yasui T, Hasegawa K.** Interleukin-1 stimulates cytokines, prostaglandin E2 and matrix metalloproteinase-1 production via activation of MAPK/AP-1 and NF-kappaB in human gingival fibroblasts. *Cytokine* 2005; **29**: 159-168 [PMID: 15652448 DOI: 10.1016/j.cyt.2004.10.009]
- 29 **Sokos D, Everts V, de Vries TJ.** Role of periodontal ligament fibroblasts in osteoclastogenesis: a review. *J Periodontol Res* 2015; **50**: 152-159 [PMID: 24862732 DOI: 10.1111/jre.12197]
- 30 **Bloemen V, Schoenmaker T, de Vries TJ, Everts V.** Direct cell-cell contact between periodontal ligament fibroblasts and osteoclast precursors synergistically increases the expression of genes related to osteoclastogenesis. *J Cell Physiol* 2010; **222**: 565-573 [PMID: 19927302 DOI: 10.1002/jcp.21971]
- 31 **Cekici A, Kantarci A, Hasturk H, Van Dyke TE.** Inflammatory and immune pathways in the pathogenesis of periodontal disease. *Periodontol 2000* 2014; **64**: 57-80 [PMID: 24320956 DOI: 10.1111/prd.12002]
- 32 **Hernández M, Gamonal J, Tervahartiala T, Mäntylä P, Rivera O, Dezerega A, Dutzan N, Sorsa T.** Associations between matrix metalloproteinase-8 and -14 and myeloperoxidase in gingival crevicular fluid from subjects with progressive chronic periodontitis: a longitudinal study. *J Periodontol* 2010; **81**: 1644-1652 [PMID: 20653434 DOI: 10.1902/jop.2010.100196]
- 33 **Alpagot T, Bell C, Lundergan W, Chambers DW, Rudin R.** Longitudinal evaluation of GCF MMP-3 and TIMP-1 levels as prognostic factors for progression of periodontitis. *J Clin Periodontol* 2001; **28**: 353-359 [PMID: 11314892 DOI: 10.1034/j.1600-051x.2001.028004353.x]
- 34 **Soell M, Elkaim R, Tenenbaum H.** Cathepsin C, matrix metalloproteinases, and their tissue inhibitors in gingiva and gingival crevicular fluid from periodontitis-affected patients. *J*

- Dent Res* 2002; **81**: 174-178 [PMID: 11876270 DOI: 10.1177/154405910208100306]
- 35 **Bostanci N**, Ilgenli T, Emingil G, Afacan B, Han B, Töz H, Atilla G, Hughes FJ, Belibasakis GN. Gingival crevicular fluid levels of RANKL and OPG in periodontal diseases: implications of their relative ratio. *J Clin Periodontol* 2007; **34**: 370-376 [PMID: 17355365 DOI: 10.1111/j.1600-051X.2007.01061.x]
 - 36 **Mogi M**, Ootogoto J, Ota N, Togari A. Differential expression of RANKL and osteoprotegerin in gingival crevicular fluid of patients with periodontitis. *J Dent Res* 2004; **83**: 166-169 [PMID: 14742657 DOI: 10.1177/154405910408300216]
 - 37 **Walsh MC**, Kim N, Kadono Y, Rho J, Lee SY, Lorenzo J, Choi Y. Osteoimmunology: interplay between the immune system and bone metabolism. *Annu Rev Immunol* 2006; **24**: 33-63 [PMID: 16551243 DOI: 10.1146/annurev.immunol.24.021605.090646]
 - 38 **Indriolo A**, Greco S, Ravelli P, Fagioli S. What can we learn about biofilm/host interactions from the study of inflammatory bowel disease. *J Clin Periodontol* 2011; **38** Suppl 11: 36-43 [PMID: 21323702 DOI: 10.1111/j.1600-051X.2010.01680.x]
 - 39 **Dudeney TP**. Crohn's disease of the mouth. *Proc R Soc Med* 1969; **62**: 1237 [PMID: 5363108]
 - 40 **Ruiz-Roca JA**, Berini-Aytés L, Gay-Escoda C. Pyostomatitis vegetans. Report of two cases and review of the literature. *Oral Surg Oral Med Oral Pathol Oral Radiol Endod* 2005; **99**: 447-454 [PMID: 15772593 DOI: 10.1016/j.tripleo.2003.08.022]
 - 41 **Ojha J**, Cohen DM, Islam NM, Stewart CM, Katz J, Bhattacharyya I. Gingival involvement in Crohn disease. *J Am Dent Assoc* 2007; **138**: 1574-181; quiz 1574-181; [PMID: 18056101 DOI: 10.14219/jada.archive.2007.0106]
 - 42 **Grössner-Schreiber B**, Fetter T, Hedderich J, Kocher T, Schreiber S, Jepsen S. Prevalence of dental caries and periodontal disease in patients with inflammatory bowel disease: a case-control study. *J Clin Periodontol* 2006; **33**: 478-484 [PMID: 16820035 DOI: 10.1111/j.1600-051X.2006.00942.x]
 - 43 **Van Dyke TE**, Dowell VR, Offenbacher S, Snyder W, Hersh T. Potential role of microorganisms isolated from periodontal lesions in the pathogenesis of inflammatory bowel disease. *Infect Immun* 1986; **53**: 671-677 [PMID: 3462153]
 - 44 **Docktor MJ**, Paster BJ, Abramowicz S, Ingram J, Wang YE, Correll M, Jiang H, Cotton SL, Kokaras AS, Bousvaros A. Alterations in diversity of the oral microbiome in pediatric inflammatory bowel disease. *Inflamm Bowel Dis* 2012; **18**: 935-942 [PMID: 21987382 DOI: 10.1002/ibd.21874]
 - 45 **Said HS**, Suda W, Nakagome S, Chinen H, Oshima K, Kim S, Kimura R, Irahia A, Ishida H, Fujita J, Mano S, Morita H, Dohi T, Oota H, Hattori M. Dysbiosis of salivary microbiota in inflammatory bowel disease and its association with oral immunological biomarkers. *DNA Res* 2014; **21**: 15-25 [PMID: 24013298 DOI: 10.1093/dnares/dst037]
 - 46 **Rautava J**, Pinnell LJ, Vong L, Akseer N, Assa A, Sherman PM. Oral microbiome composition changes in mouse models of colitis. *J Gastroenterol Hepatol* 2015; **30**: 521-527 [PMID: 25180790 DOI: 10.1111/jgh.12713]
 - 47 **Brito F**, Zaltman C, Carvalho AT, Fischer RG, Persson R, Gustafsson A, Figueredo CM. Subgingival microflora in inflammatory bowel disease patients with untreated periodontitis. *Eur J Gastroenterol Hepatol* 2013; **25**: 239-245 [PMID: 23060013 DOI: 10.1097/MEG.0b013e32835a2b70]
 - 48 **Kelsen J**, Bittinger K, Pauly-Hubbard H, Posivak L, Grunberg S, Baldassano R, Lewis JD, Wu GD, Bushman FD. Alterations of the Subgingival Microbiota in Pediatric Crohn's Disease Studied Longitudinally in Discovery and Validation Cohorts. *Inflamm Bowel Dis* 2015; **21**: 2797-2805 [PMID: 26288001 DOI: 10.1097/MIB.0000000000000557]
 - 49 **Szczeklik K**, Owczarek D, Pytko-Polończyk J, Kęsek B, Mach TH. Proinflammatory cytokines in the saliva of patients with active and non-active Crohn's disease. *Pol Arch Med Wewn* 2012; **122**: 200-208 [PMID: 22538761]
 - 50 **Rezaie A**, Ghorbani F, Eshgortk A, Zamani MJ, Dehghan G, Taghavi B, Nikfar S, Mohammadirad A, Daryani NE, Abdollahi M. Alterations in salivary antioxidants, nitric oxide, and transforming growth factor-beta 1 in relation to disease activity in Crohn's disease patients. *Ann N Y Acad Sci* 2006; **1091**: 110-122 [PMID: 17341608 DOI: 10.1196/annals.1378.060]
 - 51 **Aleksandra Nielsen A**, Nederby Nielsen J, Schmedes A, Brandslund I, Hey H. Saliva Interleukin-6 in patients with inflammatory bowel disease. *Scand J Gastroenterol* 2005; **40**: 1444-1448 [PMID: 16316893 DOI: 10.1080/0036520510023774]
 - 52 **Rezaie A**, Khalaj S, Shabihkhani M, Nikfar S, Zamani MJ, Mohammadirad A, Daryani NE, Abdollahi M. Study on the correlations among disease activity index and salivary transforming growth factor-beta 1 and nitric oxide in ulcerative colitis patients. *Ann N Y Acad Sci* 2007; **1095**: 305-314 [PMID: 17404043 DOI: 10.1196/annals.1397.034]
 - 53 **Salminen A**, Gursoy UK, Paju S, Hyvärinen K, Mäntylä P, Buhlin K, Könönen E, Nieminen MS, Sorsa T, Sinisalo J, Pussinen PJ. Salivary biomarkers of bacterial burden, inflammatory response, and tissue destruction in periodontitis. *J Clin Periodontol* 2014; **41**: 442-450 [PMID: 24460823 DOI: 10.1111/jcpe.12234]
 - 54 **Damen GM**, Hol J, de Ruiter L, Bouquet J, Sinaasappel M, van der Woude J, Laman JD, Hop WC, Büller HA, Escher JC, Nieuwenhuis EE. Chemokine production by buccal epithelium as a distinctive feature of pediatric Crohn disease. *J Pediatr Gastroenterol Nutr* 2006; **42**: 142-149 [PMID: 16456405 DOI: 10.1097/01.mpg.0000189336.70021.8a]
 - 55 **Lamster IB**, Rodrick ML, Sonis ST, Falchuk ZM. An analysis of peripheral blood and salivary polymorphonuclear leukocyte function, circulating immune complex levels and oral status in patients with inflammatory bowel disease. *J Periodontol* 1982; **53**: 231-238 [PMID: 6951992 DOI: 10.1902/jop.1982.53.4.231]
 - 56 **Stein JM**, Lammert F, Zimmer V, Granzow M, Reichert S, Schulz S, Ocklenburg C, Conrads G. Clinical periodontal and microbiologic parameters in patients with Crohn's disease with consideration of the CARD15 genotype. *J Periodontol* 2010; **81**: 535-545 [PMID: 20373538 DOI: 10.1902/jop.2009.090563]
 - 57 **Schulz S**, Reichert S, Streetz K, Trautwein C, Reichert Y, Gläser C, Schaller HG, Stein JM. Tumor necrosis factor- α and oral inflammation in patients with Crohn disease. *J Periodontol* 2014; **85**: 1424-1431 [PMID: 24678851 DOI: 10.1902/jop.2014.130644]
 - 58 **Pietropaoli D**, Del Pinto R, Corridoni D, Rodriguez-Palacios A, Di Stefano G, Monaco A, Weinberg A, Cominelli F. Occurrence of spontaneous periodontal disease in the SAMP1/YitFc murine model of Crohn disease. *J Periodontol* 2014; **85**: 1799-1805 [PMID: 25019175 DOI: 10.1902/jop.2014.140316]
 - 59 **Oz HS**, Chen T, Ebersole JL. A model for chronic mucosal inflammation in IBD and periodontitis. *Dig Dis Sci* 2010; **55**: 2194-2202 [PMID: 19902356 DOI: 10.1007/s10620-009-1031-x]
 - 60 **Park JC**, Kim BK, Jung IH, Choi E, Kim CS. Alveolar bone resorption induced by CD4+CD45RB high-density T-cell transfer in immunocompromised mice. *J Periodontol* 2014; **85**: e339-e347 [PMID: 24678850 DOI: 10.1902/jop.2014.140077]
 - 61 **Ardizzone S**, Bollani S, Bettica P, Bevilacqua M, Molteni P, Bianchi Porro G. Altered bone metabolism in inflammatory bowel disease: there is a difference between Crohn's disease and ulcerative colitis. *J Intern Med* 2000; **247**: 63-70 [PMID: 10672132 DOI: 10.1046/j.1365-2796.2000.00582.x]
 - 62 **Piodi LP**, Poloni A, Olivieri FM. Managing osteoporosis in ulcerative colitis: something new? *World J Gastroenterol* 2014; **20**: 14087-14098 [PMID: 25339798 DOI: 10.3748/wjg.v20.i39.14087]
 - 63 **Hajishengallis G**. Periodontitis: from microbial immune subversion to systemic inflammation. *Nat Rev Immunol* 2015; **15**: 30-44 [PMID: 25534621 DOI: 10.1038/nri3785]
 - 64 **Arimatsu K**, Yamada H, Miyazawa H, Minagawa T, Nakajima M, Ryder MI, Gotoh K, Motooka D, Nakamura S, Iida T, Yamazaki K. Oral pathobiont induces systemic inflammation and metabolic changes associated with alteration of gut microbiota. *Sci Rep* 2014; **4**: 4828 [PMID: 24797416 DOI: 10.1038/srep04828]
 - 65 **Nakajima M**, Arimatsu K, Kato T, Matsuda Y, Minagawa T, Takahashi N, Ohno H, Yamazaki K. Oral Administration of *P. gingivalis* Induces Dysbiosis of Gut Microbiota and Impaired

- Barrier Function Leading to Dissemination of Enterobacteria to the Liver. *PLoS One* 2015; **10**: e0134234 [PMID: 26218067 DOI: 10.1371/journal.pone.0134234]
- 66 **Matsuda Y**, Kato T, Takahashi N, Nakajima M, Arimatsu K, Minagawa T, Sato K, Ohno H, Yamazaki K. Ligature-induced periodontitis in mice induces elevated levels of circulating interleukin-6 but shows only weak effects on adipose and liver tissues. *J Periodontol Res* 2015; Epub ahead of print [PMID: 26667667 DOI: 10.1111/jre.12344]
 - 67 **Blasco-Baque V**, Garidou L, Pomie C, Escoula Q, Loubieres P, Le Gall-David S, Lemaitre M, Nicolas S, Klopp P, Waget A, Azalbert V, Colom A, Bonnaure-Mallet M, Kemoun P, Serino M, Burcelin R. Periodontitis induced by *Porphyromonas gingivalis* drives periodontal microbiota dysbiosis and insulin resistance via an impaired adaptive immune response. *Gut* 2016; Epub ahead of print [PMID: 26838600 DOI: 10.1136/gutjnl-2015-309897]
 - 68 **Franzosa EA**, Morgan XC, Segata N, Waldron L, Reyes J, Earl AM, Giannoukos G, Boylan MR, Ciulla D, Gevers D, Izard J, Garrett WS, Chan AT, Huttenhower C. Relating the metatranscriptome and metagenome of the human gut. *Proc Natl Acad Sci USA* 2014; **111**: E2329-E2338 [PMID: 24843156 DOI: 10.1073/pnas.1319284111]
 - 69 **Qin N**, Yang F, Li A, Prifti E, Chen Y, Shao L, Guo J, Le Chatelier E, Yao J, Wu L, Zhou J, Ni S, Liu L, Pons N, Batto JM, Kennedy SP, Leonard P, Yuan C, Ding W, Chen Y, Hu X, Zheng B, Qian G, Xu W, Ehrlich SD, Zheng S, Li L. Alterations of the human gut microbiome in liver cirrhosis. *Nature* 2014; **513**: 59-64 [PMID: 25079328 DOI: 10.1038/nature13568]
 - 70 **Messora MR**, Oliveira LF, Foureaux RC, Taba M, Zangerônimo MG, Furlaneto FA, Pereira LJ. Probiotic therapy reduces periodontal tissue destruction and improves the intestinal morphology in rats with ligature-induced periodontitis. *J Periodontol* 2013; **84**: 1818-1826 [PMID: 23327675 DOI: 10.1902/jop.2013.120644]
 - 71 **Foureaux Rde C**, Messora MR, de Oliveira LF, Napimoga MH, Pereira AN, Ferreira MS, Pereira LJ. Effects of probiotic therapy on metabolic and inflammatory parameters of rats with ligature-induced periodontitis associated with restraint stress. *J Periodontol* 2014; **85**: 975-983 [PMID: 24171503 DOI: 10.1902/jop.2013.130356]
 - 72 **Gangula P**, Ravella K, Chukkapalli S, Rivera M, Srinivasan S, Hale A, Channon K, Southerland J, Kesavalu L. Polybacterial Periodontal Pathogens Alter Vascular and Gut BH4/nNOS/NRF2-Phase II Enzyme Expression. *PLoS One* 2015; **10**: e0129885 [PMID: 26111153 DOI: 10.1371/journal.pone.0129885]
 - 73 **Lundmark A**, Davanian H, Båge T, Johannsen G, Koro C, Lundeberg J, Yucel-Lindberg T. Transcriptome analysis reveals mucin 4 to be highly associated with periodontitis and identifies pleckstrin as a link to systemic diseases. *Sci Rep* 2015; **5**: 18475 [PMID: 26686060 DOI: 10.1038/srep18475]
 - 74 **Flemmig TF**, Shanahan F, Miyasaki KT. Prevalence and severity of periodontal disease in patients with inflammatory bowel disease. *J Clin Periodontol* 1991; **18**: 690-697 [PMID: 1960238 DOI: 10.1111/j.1600-051X.1991.tb00111.x]
 - 75 **Vavricka SR**, Manser CN, Hediger S, Vögelin M, Scharl M, Biedermann L, Rogler S, Seibold F, Sanderink R, Attin T, Schoepfer A, Fried M, Rogler G, Frei P. Periodontitis and gingivitis in inflammatory bowel disease: a case-control study. *Inflamm Bowel Dis* 2013; **19**: 2768-2777 [PMID: 24216685 DOI: 10.1097/01.MIB.0000438356.84263.3b]
 - 76 **Koutsochristou V**, Zellos A, Dimakou K, Panayotou I, Siahianidou S, Roma-Giannikou E, Tsami A. Dental Caries and Periodontal Disease in Children and Adolescents with Inflammatory Bowel Disease: A Case-Control Study. *Inflamm Bowel Dis* 2015; **21**: 1839-1846 [PMID: 25985243 DOI: 10.1097/MIB.0000000000000452]

P- Reviewer: Vaithilingam RD **S- Editor:** Yu J **L- Editor:** A
E- Editor: Wang CH





Published by **Baishideng Publishing Group Inc**

8226 Regency Drive, Pleasanton, CA 94588, USA

Telephone: +1-925-223-8242

Fax: +1-925-223-8243

E-mail: bpgoffice@wjgnet.com

Help Desk: <http://www.wjgnet.com/esps/helpdesk.aspx>

<http://www.wjgnet.com>



ISSN 1007-9327

