

## Basic Study

# Percutaneous transgastric endoscopic tube ileostomy in a porcine survival model

Hong Shi, Su-Yu Chen, Yong-Guang Wang, Sheng-Jun Jiang, He-Li Cai, Kai Lin, Zhao-Fei Xie, Fen-Fang Dong

Hong Shi, Su-Yu Chen, Zhao-Fei Xie, Department of Gastrointestinal Endoscopy, Fujian Provincial Cancer Hospital, Affiliated Cancer Hospital of Fujian Medical University, Fuzhou 350014, Fujian Province, China

Yong-Guang Wang, Sheng-Jun Jiang, Department of Minimally Invasive Surgery, Beijing Chuiyangliu Hospital, Institute of Minimally Invasive Medicine of Tongji University, Beijing 100022, China

He-Li Cai, Department of Gastroenterology, Fuzhou Seventh Hospital, Fuzhou 350001, Fujian Province, China

Kai Lin, Department of General Surgery, Fuzhou Seventh Hospital, Fuzhou 350001, Fujian Province, China

Fen-Fang Dong, Faculty of Medical Technology and Engineering, Fujian Medical University, Fuzhou 350004, Fujian Province, China

**Author contributions:** Shi H and Chen SY contributed equally to this work; Shi H and Chen SY were responsible for the study concept and design, including endoscopic procedures; all authors conducted the endoscopic operations together; Chen SY drafted the manuscript; Shi H revised and finalized the manuscript.

**Supported by the Natural Science Foundation Project of Fujian Provincial Department of Science and Technology, No. 2014J01407; the Fuzhou Technology Planning Project, No. 2013-S-129-2; and the College Students' Innovation and Entrepreneurship Planning Project of Fujian Medical University, No. C1503.**

**Institutional review board statement:** The study was reviewed and approved by the Institutional Review Board of Fujian Provincial Tumor Hospital, Teaching Hospital of Fujian Medical University (protocol number: 2014J01407, 2013-S-129-2, C1503).

**Conflict-of-interest statement:** To the best of our knowledge, no conflict of interest exists.

**Data sharing statement:** No additional data are available.

**Open-Access:** This article is an open-access article which was selected by an in-house editor and fully peer-reviewed by external reviewers. It is distributed in accordance with the Creative Commons Attribution Non Commercial (CC BY-NC 4.0) license, which permits others to distribute, remix, adapt, build upon this work non-commercially, and license their derivative works on different terms, provided the original work is properly cited and the use is non-commercial. See: <http://creativecommons.org/licenses/by-nc/4.0/>

**Manuscript source:** Unsolicited manuscript

**Correspondence to:** Hong Shi, MD, Department of Gastrointestinal Endoscopy, Fujian Provincial Cancer Hospital, Affiliated Cancer Hospital of Fujian Medical University, Fuzhou 350014, Fujian Province, China. [endshihong@hotmail.com](mailto:endshihong@hotmail.com)  
**Telephone:** +86-591-83660063  
**Fax:** +86-591-83660063

**Received:** July 8, 2016

**Peer-review started:** July 12, 2016

**First decision:** August 8, 2016

**Revised:** August 18, 2016

**Accepted:** August 30, 2016

**Article in press:** August 30, 2016

**Published online:** October 7, 2016

## Abstract

### AIM

To introduce natural orifice transgastric endoscopic surgery (NOTES) tube ileostomy using pelvis-directed submucosal tunneling endoscopic gastrostomy and endoscopic tube ileostomy.

### METHODS

Six live pigs (three each in the non-survival and survival groups) were used. A double-channelled therapeutic endoscope was introduced perorally into the stomach. A gastrostomy was made using a 2-cm

transversal mucosal incision following the creation of a 5-cm longitudinal pelvis-directed submucosal tunnel. The pneumoperitoneum was established *via* the endoscope. In the initial three operations of the series, a laparoscope was transumbilically inserted for guiding the tunnel direction, intraperitoneal spatial orientation and distal ileum identification. Endoscopic tube ileostomy was conducted by adopting an introducer method and using a Percutaneous Endoscopic Gastrostomy Catheter Kit equipped with the Loop Fixture. The distal tip of the 15 Fr catheter was placed toward the proximal limb of the ileum to optimize intestinal content drainage. Finally, the tunnel entrance of the gastrostomy was closed using nylon endoloops with the aid of a twin grasper. The gross and histopathological integrity of gastrostomy closure and the abdominal wall-ileum stoma tract formation were assessed 1 wk after the operation.

## RESULTS

Transgastric endoscopic tube ileostomy was successful in all six pigs, without major bleeding. The mean operating time was 71 min (range: 60-110 min). There were no intraoperative complications or hemodynamic instability. The post-mortem, which was conducted 1-wk postoperatively, showed complete healing of the gastrostomy and adequate stoma tract formation of ileostomy.

## CONCLUSION

Transgastric endoscopic tube ileostomy is technically feasible and reproducible in an animal model, and this technique is worthy of further improvement.

**Key words:** Natural orifice transluminal endoscopic surgery; Tube ileostomy; Endoloop; Pigs; Submucosal tunneling

© **The Author(s) 2016.** Published by Baishideng Publishing Group Inc. All rights reserved.

**Core tip:** A novel technique, natural orifice transgastric endoscopic surgery tube ileostomy, may be successfully performed in a porcine survival model using pelvis-directed submucosal tunneling endoscopic gastrostomy, followed by endoscopic tube ileostomy using an Introducer Kit containing a loop fixture.

Shi H, Chen SY, Wang YG, Jiang SJ, Cai HL, Lin K, Xie ZF, Dong FF. Percutaneous transgastric endoscopic tube ileostomy in a porcine survival model. *World J Gastroenterol* 2016; 22(37): 8375-8381 Available from: URL: <http://www.wjgnet.com/1007-9327/full/v22/i37/8375.htm> DOI: <http://dx.doi.org/10.3748/wjg.v22.i37.8375>

## INTRODUCTION

Anastomotic leakage is one of the major complications that occurs after anterior resection of the rectum for

rectal cancer with a low extraperitoneal colorectal anastomosis<sup>[1,2]</sup>. With the development of surgery, a defunctioning stoma, colostomy or ileostomy has become a mainstay of proximal fecal diversion to protect against primary colorectal anastomosis, and to reduce the risk and lessen the severity of the sequelae of anastomotic leakage, such as fecal peritonitis and sepsis. However, established conventional defunctioning stomas, including loop colostomy and loop ileostomy, require a second surgical reversal<sup>[3]</sup>, which may cause morbidity and even mortality. Percutaneous tube ileostomy, which is achieved by inserting a tube into the distal ileum through the abdominal wall, has been reported as an alternative that can achieve similar temporary fecal diversion, ensuring greater comfort for the patient and easier management, as well as avoiding the additional surgical procedure required for the closure of a conventional loop-ostomy<sup>[4]</sup>.

Percutaneous tube ileostomy for anastomotic protection is clinically performed by laparotomy or laparoscopy. Natural orifice transluminal endoscopic surgery (NOTES)<sup>[5-8]</sup> may be an alternative for the execution of the tube ileostomy procedure, as this method is less invasive and is associated with less postoperative pain compared with the two former methods. To date, there is no literature regarding NOTES tube ileostomy. The aim of our study was to demonstrate the feasibility and reproducibility of a novel technique of percutaneous transgastric endoscopic tube ileostomy using an Introducer Kit in a porcine survival model.

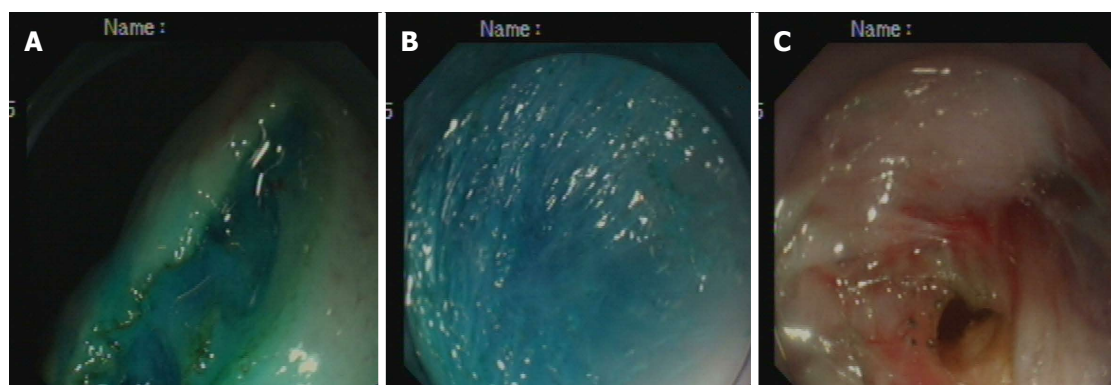
## MATERIALS AND METHODS

### Animal model

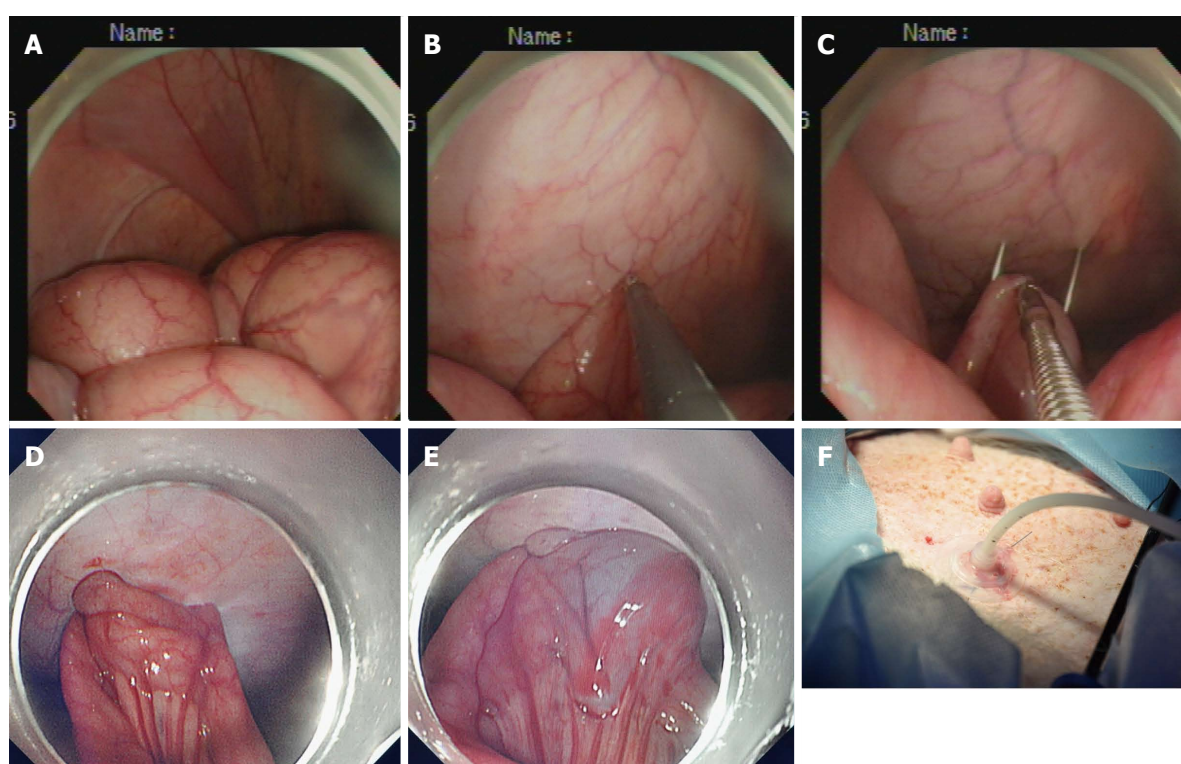
Our study was performed on six healthy female domestic pigs weighing between 15 and 20 kg, of which three were enrolled in a non-survival group and three in a 1-wk survival group. All animals were fasted for 24 h prior to surgery. Induction of anesthesia was achieved by intramuscular injection of 100 mg ketamine, 10 mg droperidol and 1 mg atropine, and maintenance of anesthesia was achieved by an intravenous drip of propofol at a dose of 10 mL/h, with endotracheal intubation. The heart rate and oxygen saturation of each animal were monitored during the operation. Animals were maintained in a supine position to allow for optimal access and peritoneal exploration. This study was approved by the Institutional Animal Use and Care Committee of Fujian Provincial Tumor Hospital, Teaching Hospital of Fujian Medical University, Fuzhou, China.

### NOTES tube ileostomy

**Creation of the gastrostomy by directed submucosal tunneling:** A 2-cm transversal mucosal incision was created near the gastroesophageal junction with a dual knife (KD650L; Olympus, Tokyo,



**Figure 1** Step-by-step procedure of pelvis-directed submucosal tunneling endoscopic gastrostomy. A: Gastric mucosal incision; B: Submucosal tunneling; C: Seromuscular incision.



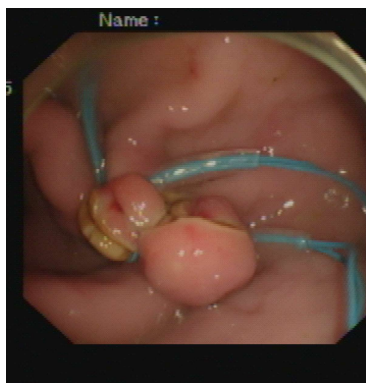**Figure 2** Step-by-step procedure of endoscopic tube ileostomy. A: Endoscopic identification of the distal ileum in the left lower quadrant; B: Endoscopic view of a loop of the distal ileum on its anti-mesenteric side grasped and held to the anterior abdominal wall; C: Percutaneous terminal ileum puncture; D: Endoscopic view of the distal ileum sutured to the abdominal wall with two stitches; E: Endoscopic view of the inflated balloon in the ileal lumen; F: Accomplished tube ileostomy.

Japan), followed by the creation of a 5-cm longitudinal submucosal pelvis-directed tunnel<sup>[9,10]</sup> (Figure 1A-C). The tunnel ended with a seromuscular incision, and the exit site was selected at the greater curvature of the stomach. A dual-channel therapeutic endoscope (GIF2TQ260M; Olympus) was advanced into the peritoneal cavity through the gastrostomy site. A pelvis-directed tunnel (left lower quadrant abdomen) was considered successful if the exit was in line with the urinary bladder, or the body or left horn of the uterus. The pneumoperitoneum was established *via* the endoscope. In the initial three operations in the non-survival group, transumbilical laparoscopic visualization was used to guide tunnel direction

assessment, intraperitoneal spatial orientation, and subsequent terminal ileum identification.

**Creation of the ileostomy using the introducer method:** A 15 Fr rubber-coated silicone balloon catheter (Cliny PEG Kit; Create Medic, Yokohama, Japan) was used as the tube stoma (Figure 2A-F). The optimal ileostomy site was determined by depressing the left lower abdominal wall with a finger until the tip of the finger was visible intraperitoneally under endoscopic visualization. The pneumoperitoneum was decompressed to bring the distal ileum closer to the parietal peritoneum. After being grasped and held toward the needle, which had penetrated through the





**Figure 3** An endoscopic view of gastrostomy closure with endoloop ligation.

anterior abdominal wall, the antimesenteric side of the distal ileum was punctured using a double-lumen loop fixture device under laparoscopic or endoscopic guidance. Two stitches were placed about 2-3 cm apart. An abdominal wall incision was made between the two suture points, and a trocar with a plastic "T" peel-away sheath was introduced into the ileum through the incision site. After removal of the trocar, a 15 Fr catheter was introduced into the plastic sheath. The distal tip of the 15 Fr catheter was placed toward the proximal limb of the ileum to optimize intestinal content drainage. The balloon at the tip of the catheter was inflated with 5 mL sterile water, and the catheter was pulled until the appropriate approximation of the balloon to the abdominal wall was achieved. The peel-away sheath was then removed, and the retaining plate was positioned.

**Closure of the gastrostomy:** The pneumoperitoneum was evacuated endoscopically, and the dual-channel therapeutic endoscope was withdrawn into the stomach through the gastrostomy site (Figure 3). An endoloop, followed by the twin grasper, was inserted into the gastric cavity through one of the two channels and placed at the gastrostomy side. The gastric tissues adjacent to the mucosal defect were clamped with the twin grasper and dragged into the transparent cap previously mounted on the tip of the endoscope, followed by fully aspirated into the transparent cap, and the bilateral gastric mucosal layers were approximated by tightening the endoloop. If the defect closure was incomplete, more endoloops were used to close the remaining portions. Two or three endoloops were placed to secure the closure.

#### **Postoperative care**

At 48 h after the procedure, the animals were fed a liquid oral diet for 2 d, followed by a semi-fluid diet for 3 d. Irrigation was performed once daily to keep the tube patent. The animals were monitored for food intake, defecation, infection and other postoperative complications for 1 wk.

#### **Euthanasia and necropsy**

Euthanasia was performed immediately in the non-survival group and 1 wk after the procedure in the survival group. Necropsy results, including injury to adjacent organs, vascular bleeding, gross and histopathological evaluation of gastrostomy closure and stoma tract formation of ileostomy, were recorded. Both the healing and formation processes were classified into three phases: inflammatory, proliferative, and remodeling. The inflammatory phase (first) was characterized by accumulation of polymorphonuclear neutrophils and vasodilation; the proliferation phase (second) was characterized by accumulation of macrophages and fibroblasts, angiogenesis, and collagen deposition; and the remodeling phase (third) was characterized by rearrangement of collagen fibers. The microscopic factors of the aforementioned phases were assessed using a semi-quantitative scoring method of 0-3 points, where 0 = absence, 1 = a little, 2 = moderate, and 3 = abundant<sup>[11]</sup>.

#### **Animal care and use statement**

The animal protocol was designed to minimize pain or discomfort to the animals. All animals were killed by barbiturate overdose (intravenous injection, 150 mg/kg pentobarbital sodium) for tissue collection.

## **RESULTS**

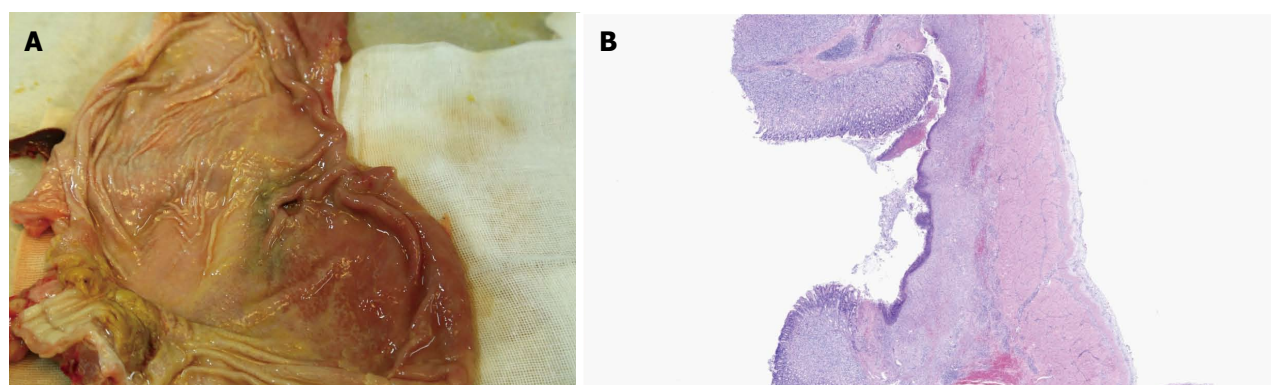
Transgastric endoscopic tube ileostomy was successfully performed in all six pigs, without major bleeding. The mean operating time was 71 min (range: 60-110 min). There were no intraoperative complications or hemodynamic instability.

In the non-survival group, the post-mortem showed secure closure of the gastrostomy created by submucosal tunneling and immediate patency of the ileostomy. Neither gastrostomy nor ileostomy leakage were identified on methylene blue evaluation.

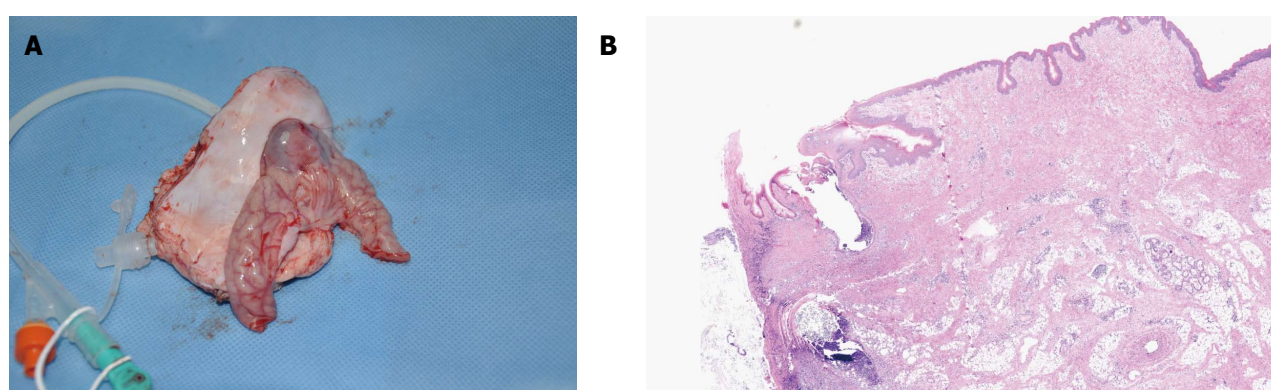
In the survival group, emission of both trans-ileostomy and trans-anal feces were observed. At necropsy, all three gastrostomy sites had completely healed (Figure 4A and B), the tubes were kept patent, and their corresponding ileostomy sites were intact, without evidence of serious infection or significant leakage, as determined by gross assessment. Formation of granulation tissue was observed around the central stoma tract (Figure 5A and B). On postoperative day 7, both the gastrostomy and ileostomy were classified as being in the proliferation phase (Table 1).

## **DISCUSSION**

To the best of our knowledge, this is the first study addressing NOTES tube ileostomy in a porcine survival model. Safe peritoneal access and secure closure of the access site during NOTES remain significant concerns and must be addressed before



**Figure 4** Gross and histopathological evaluation of gastrostomy closure 1 wk after natural orifice transgastric endoscopic surgery. A: Gross examination showing complete healing of gastrostomy; B: Histopathological examination showing complete healing of gastrostomy.



**Figure 5** Gross and histopathological evaluation of stoma tract formation of the ileostomy 1 wk after natural orifice transgastric endoscopic surgery. A: Gross examination showing adequate stoma tract formation of ileostomy; B: Histopathological examination showing adequate stoma tract formation of ileostomy.

**Table 1** Summary of procedures and outcomes following creation of natural orifice transgastric endoscopic surgery tube ileostomy in three surviving pigs

Observation parameters	Pig 1	Pig 2	Pig 3
Time required to create gastrostomy (min)	26	21	24
Time required to create tube ileostomy (min)	33	31	29
Time required to close gastrostomy (min)	5	11	7
Complications			
Major bleeding	-	-	-
Anastomotic leak	-	-	-
Necropsy on postoperative day 7			
Integrity of gastrostomy closure	The proliferation phase		
Stoma tract formation of the ileostomy	The proliferation phase		

its introduction into clinical practice. In our study, the pelvis-directed submucosal tunneling technique was applied to achieve transgastric peritoneal access. Under direct visualization, blood vessels can be clearly identified and precisely coagulated in the submucosal tunnel. Moreover, compared with a direct full-thickness incision, a seromuscular incision may minimize inadvertent injury because the adjacent organs can be visualized through the thin seromuscular layer of the stomach. Furthermore, a designed submucosal tunnel enables in-line endoscope positioning toward predetermined left lower abdominal target locations,

without the need for endoscopic retroflexion<sup>[10]</sup>.

As has been reported, the closure of the gastric mucosal incision site with conventional endoscopic clips was easy and secure<sup>[9,10]</sup>. In the current study, a novel technique of endoloop ligation<sup>[12,13]</sup>, in combination with the dedicated twin grasper, was introduced to facilitate endoscopic closure of the tunnel entrance to the stomach. The Ovesco twin grasper has two jaws that can open and close separately to approximate defect edges<sup>[14,15]</sup>. Histopathological examination showed satisfactory healing of the submucosal tunnel, thus proving that gastric closure with endoloops is both simple and reliable.

With regards to using tube ileostomy as a diversion procedure, there has been a re-emergence of interest in the use of tube ileostomy to de-function a distal colorectal anastomosis. A systematic review and pooled analysis of seven studies comparing tube with loop ileostomy showed no significant difference in anastomotic leak rate<sup>[1]</sup>. Tube ileostomy is an alternate diversion procedure that has few complications and is easy to construct and manage compared to conventional loop ileostomy. This procedure can divert the bowel contents and avoid the need for a second operation and its related complications<sup>[16-22]</sup>.

Clinically, there are two methods for placing the

tube. One is the transcecal approach, which after anastomosis, an appendectomy or cecostomy is performed, allowing the introduction of the tube into the cecal cavity and then into the terminal ileum *via* the ileocecal valve. The other method is to place the tube directly into the terminal ileum. In our study, the introducer method *via* the distal ileum approach was similar to gastropexy<sup>[23-29]</sup>. The only difference was that, in our study, the antimesenteric side of the distal ileum was sutured to the lower anterior abdominal wall, while gastropexy was achieved by suturing the anterior gastric wall to the anterior abdominal wall before PEG-catheter insertion. Gastropexy may prevent stomal leakage and subsequent peritonitis secondary to early inadvertent percutaneous gastrostomy dislodgement. Similarly, suturing the ileum to the abdominal wall may reduce the risk of peristomal cellulitis before stoma tract maturation. Adhesion of the ileum to the abdominal wall was achieved by placement of two stitches using a double-lumen loop fixture device around a target abdominal stoma site, which has not been previously reported.

The maturation of the stoma tract is critical to percutaneous gastrostomy, and this principle also applies to percutaneous tube ileostomy. Our study showed that the time required for stoma tract formation was about 1 wk after ileostomy, thus providing a safe timeframe for tube removal. Similar results were obtained in human studies, in which the exact timing of tube removal ranged from 7 d to > 3 wk postoperatively<sup>[1,30]</sup>.

In conclusion, this novel technique for performing tube ileostomy exclusively by NOTES is technically feasible and reproducible in an animal model and is worthy of further improvement.

## COMMENTS

### Background

Established conventional defunctioning stomas, loop colostomy and loop ileostomy have become a mainstay of proximal fecal diversion to protect against primary colorectal anastomosis and to reduce the risk and lessen the severity of the sequelae of anastomotic leakage, such as fecal peritonitis and sepsis. Percutaneous tube ileostomy has been reported as an alternative that can achieve similar temporary fecal diversion, ensuring greater comfort for the patient and easier management, as well as avoiding the additional surgical procedure required for the closure of a conventional loop-ostomy.

### Research frontiers

Percutaneous tube ileostomy for anastomotic protection is clinically performed by laparotomy or laparoscopy. To date, there is no literature regarding the natural orifice transgastric endoscopic surgery (NOTES) tube ileostomy.

### Innovations and breakthroughs

A novel technique of percutaneous transgastric endoscopic tube ileostomy may be successfully performed in a porcine survival model, using pelvis-directed submucosal tunneling endoscopic gastrostomy and endoscopic tube ileostomy using an Introducer Kit containing a loop fixture.

### Applications

This study demonstrates the potential application of percutaneous transgastric

endoscopic tube ileostomy using an Introducer Kit for temporary fecal diversion.

### Terminology

A novel NOTES tube ileostomy is performed using pelvis-directed submucosal tunneling endoscopic gastrostomy, following by endoscopic tube ileostomy using the introducer method.

### Peer-review

This is an interesting study about the percutaneous transgastric endoscopic tube ileostomy using an Introducer Kit in a porcine survival model. The study is well designed and the results are good discussed.

## REFERENCES

- 1 **Nachiappan S**, Datta U, Askari A, Faiz O. Tube ileostomy for faecal diversion in elective distal colorectal anastomosis: a systematic review and pooled analysis. *Colorectal Dis* 2015; **17**: 665-673 [PMID: 25959023 DOI: 10.1111/codi.12997]
- 2 **Sheng QS**, Hua HJ, Cheng XB, Wang WB, Chen WB, Xu JH, Lin JJ. A Modified Spontaneously Closed Defunctioning Tube Ileostomy After Anterior Resection of the Rectum for Rectal Cancer with a Low Colorectal Anastomosis. *Indian J Surg* 2016; **78**: 125-129 [PMID: 27303122 DOI: 10.1007/s12262-015-1332-6]
- 3 **Markides GA**, Wijetunga IU, Brown SR, Anwar S. Meta-analysis of handsewn versus stapled reversal of loop ileostomy. *ANZ J Surg* 2015; **85**: 217-224 [PMID: 24920298 DOI: 10.1111/ans.12684]
- 4 **Bugiantella W**, Rondelli F, Mariani L, Boni M, Ermili F, Avenia N, Mariani E. Temporary percutaneous ileostomy for faecal diversion after intestinal resection for acute abdomen in elderly: how to avoid the conventional loop ileostomy. *Int J Surg* 2014; **12** Suppl 2: S144-S147 [PMID: 25157995 DOI: 10.1016/j.ijss.2014.08.361]
- 5 **Kantsevov SV**, Armengol-Miro JR. Endoscopic Suturing, an Essential Enabling Technology for New NOTES Interventions. *Gastrointest Endosc Clin N Am* 2016; **26**: 375-384 [PMID: 27036903 DOI: 10.1016/j.giec.2015.12.005]
- 6 **Liu BR**, Song JT. Submucosal Tunneling Endoscopic Resection (STER) and Other Novel Applications of Submucosal Tunneling in Humans. *Gastrointest Endosc Clin N Am* 2016; **26**: 271-282 [PMID: 27036897 DOI: 10.1016/j.giec.2015.12.003]
- 7 **Yip HC**, Chiu PW. Recent advances in natural orifice transluminal endoscopic surgery†. *Eur J Cardiothorac Surg* 2016; **49** Suppl 1: i25-i30 [PMID: 26494866 DOI: 10.1093/ejcts/ezv364]
- 8 **Patel N**, Seneci C, Yang GZ, Darzi A, Teare J. Flexible platforms for natural orifice transluminal and endoluminal surgery. *Endosc Int Open* 2014; **2**: E117-E123 [PMID: 26135256 DOI: 10.1055/s-0034-1377171]
- 9 **Teoh AY**, Chiu PW, Chan SM, Wong TC, Lau JY, Ng EK. Direct incision versus submucosal tunneling as a method of creating transgastric accesses for natural orifice transluminal endoscopic surgery (NOTES) peritoneoscopy: randomized controlled trial. *Dig Endosc* 2013; **25**: 281-287 [PMID: 23368513 DOI: 10.1111/j.1443-1661.2012.01390.x]
- 10 **Pauli EM**, Haluck RS, Ionescu AM, Rogers AM, Shope TR, Moyer MT, Biswas A, Mathew A. Directed submucosal tunneling permits in-line endoscope positioning for transgastric natural orifice transluminal endoscopic surgery (NOTES). *Surg Endosc* 2010; **24**: 1474-1481 [PMID: 20033729 DOI: 10.1007/s00464-009-0760-4]
- 11 **Phillips JD**, Kim CS, Fonkalsrud EW, Zeng H, Dindar H. Effects of chronic corticosteroids and vitamin A on the healing of intestinal anastomoses. *Am J Surg* 1992; **163**: 71-77 [PMID: 1733376 DOI: 10.1016/0002-9610(92)90255-P]
- 12 **Zheng Z**, Jiao G, Wang T, Chen X, Wang B. Ligation-Assisted Endoscopic Enucleation for the Resection of Gastrointestinal Tumors Originating from the Muscularis Propria: Analysis of Efficacy and Facility. *Dig Surg* 2016; **33**: 488-494 [PMID: 27250727 DOI: 10.1159/000445957]
- 13 **von Renteln D**, Schmidt A, Vassiliou MC, Rudolph HU, Caca K. Endoscopic full-thickness resection and defect closure in the colon.



- Gastrointest Endosc* 2010; **71**: 1267-1273 [PMID: 20598252 DOI: 10.1016/j.gie.2009.12.056]
- 14 **von Renteln D**, Denzer UW, Schachschal G, Anders M, Groth S, Rösch T. Endoscopic closure of GI fistulae by using an over-the-scope clip (with videos). *Gastrointest Endosc* 2010; **72**: 1289-1296 [PMID: 20951989 DOI: 10.1016/j.gie.2010.07.033]
  - 15 **Guo J**, Liu Z, Sun S, Liu X, Wang S, Ge N, Wang G, Qi Y. Endoscopic full-thickness resection with defect closure using an over-the-scope clip for gastric subepithelial tumors originating from the muscularis propria. *Surg Endosc* 2015; **29**: 3356-3362 [PMID: 25701060 DOI: 10.1007/s00464-015-4076-2]
  - 16 **Zhou X**, Lin C, Chen W, Lin J, Xu J. Completely diverted tube ileostomy compared with loop ileostomy for protection of low colorectal anastomosis: a pilot study. *Colorectal Dis* 2014; **16**: O327-O331 [PMID: 24592884 DOI: 10.1111/codi.12604]
  - 17 **Rondelli F**, Balzarotti R, Bugiantella W, Mariani L, Pugliese R, Mariani E. Temporary percutaneous ileostomy versus conventional loop ileostomy in mechanical extraperitoneal colorectal anastomosis: a retrospective study. *Eur J Surg Oncol* 2012; **38**: 1065-1070 [PMID: 22951359 DOI: 10.1016/j.ejso.2012.07.110]
  - 18 **Patil V**, Vijayakumar A, Ajitha MB, Kumar L S. Comparison between Tube Ileostomy and Loop Ileostomy as a Diversion Procedure. *ISRN Surg* 2012; **2012**: 547523 [PMID: 23320194 DOI: 10.5402/2012/547523]
  - 19 **Danielsen AK**, Park J, Jansen JE, Bock D, Skullman S, Wedin A, Marinez AC, Haglind E, Angenete E, Rosenberg J. Early Closure of a Temporary Ileostomy in Patients With Rectal Cancer: A Multicenter Randomized Controlled Trial. *Ann Surg* 2016; Epub ahead of print [PMID: 27322187 DOI: 10.1097/SLA.0000000000001829]
  - 20 **Salamone G**, Licari L, Agrusa A, Romano G, Cocorullo G, Falco N, Tutino R, Gulotta G. Usefulness of ileostomy defunctioning stoma after anterior resection of rectum on prevention of anastomotic leakage A retrospective analysis. *Ann Ital Chir* 2016; **87**: 155-160 [PMID: 27179231]
  - 21 **Markides GA**, Wijetunga I, McMahon M, Gupta P, Subramanian A, Anwar S. Reversal of loop ileostomy under an Enhanced Recovery Programme - Is the stapled anastomosis technique still better than the handsewn technique? *Int J Surg* 2015; **23**: 41-45 [PMID: 26403069 DOI: 10.1016/j.ijsu.2015.09.039]
  - 22 **Brook AJ**, Mansfield SD, Daniels IR, Smart NJ. Incisional hernia following closure of loop ileostomy: The main predictor is the patient, not the surgeon. *Surgeon* 2016; Epub ahead of print [PMID: 27161097 DOI: 10.1016/j.surge.2016.03.004]
  - 23 **Maxwell CI**, Hilden K, Glasgow RE, Ollerenshaw J, Carlisle JG, Fang JC. Evaluation of gastropexy and stoma tract maturation using a novel introducer kit for percutaneous gastrostomy in a porcine model. *JPEN J Parenter Enteral Nutr* 2011; **35**: 630-635 [PMID: 21765053 DOI: 10.1177/0148607111413596]
  - 24 **Imaeda H**, Nakajima K, Hosoe N, Nakahara M, Zushi S, Kato M, Kashiwagi K, Matsumoto Y, Kimura K, Nakamura R, Wada N, Tsujii M, Yahagi N, Hibi T, Kanai T, Takehara T, Ogata H. Percutaneous endoscopic gastrostomy under steady pressure automatically controlled endoscopy: First clinical series. *World J Gastrointest Endosc* 2016; **8**: 186-191 [PMID: 26862369 DOI: 10.4253/wjge.v8.i3.186]
  - 25 **Adachi Y**, Akino K, Mita H, Kikuchi T, Yamashita K, Sasaki Y, Arimura Y, Endo T. Systemic Prophylactic Antibiotics for the Modified Introducer Method for Percutaneous Endoscopic Gastrostomy: A Prospective, Randomized, Double-Blind Study. *J Clin Gastroenterol* 2016; **50**: 727-732 [PMID: 26756107 DOI: 10.1097/MCG.0000000000000470]
  - 26 **Fox-Alvarez WA**, Case JB, Cooke KL, Garcia-Pereira FL, Buckley GJ, Monnet E, Toskich BB. Temporary percutaneous T-fastener gastropexy and continuous decompressive gastrostomy in dogs with experimentally induced gastric dilatation. *Am J Vet Res* 2016; **77**: 771-778 [PMID: 27347832 DOI: 10.2460/ajvr.77.7.771]
  - 27 **Milovanovic L**, Kennedy SA, Chrea B, Midia M. Safety and Short-Term Complication Rates Using Single-Puncture T-Fastener Gastropexy. *J Vasc Interv Radiol* 2016; **27**: 898-904 [PMID: 27134109 DOI: 10.1016/j.jvir.2016.02.033]
  - 28 **Al-Jazaeri A**, Al-Dekhayel M, Al-Saleh N, Al-Turki A, Al-Dhaheri M, Khan S. Guided Transabdominal U-Stitches Gastropexy: A Simplified Technique for Secure Laparoscopic Gastrostomy Tube Insertion. *J Laparoendosc Adv Surg Tech A* 2016; Epub ahead of print [PMID: 26953774 DOI: 10.1089/lap.2015.0263]
  - 29 **Round S**, Popovitch C. Prophylactic Gastropexy Incorporating a Gastrotomy Incision in Dogs: A Retrospective Study of 21 Cases (2011-2013). *J Am Anim Hosp Assoc* 2016; **52**: 115-118 [PMID: 26808434 DOI: 10.5326/JAAHA-MS-6285]
  - 30 **Hua H**, Xu J, Chen W, Zhou X, Wang J, Sheng Q, Lin J. Defunctioning cannula ileostomy after lower anterior resection of rectal cancer. *Dis Colon Rectum* 2014; **57**: 1267-1274 [PMID: 25285693 DOI: 10.1097/DCR.0000000000000217]

**P- Reviewer:** Higuchi K, Mulvihill S, Yamaoka Y  
**S- Editor:** Gong ZM **L- Editor:** Kerr C **E- Editor:** Wang CH





Published by **Baishideng Publishing Group Inc**

8226 Regency Drive, Pleasanton, CA 94588, USA

Telephone: +1-925-223-8242

Fax: +1-925-223-8243

E-mail: [bpgoffice@wjgnet.com](mailto:bpgoffice@wjgnet.com)

Help Desk: <http://www.wjgnet.com/esps/helpdesk.aspx>

<http://www.wjgnet.com>



ISSN 1007-9327



9 771007 932045