

Supraclavicular lymph node metastases from malignant gastrointestinal stromal tumor of the jejunum: A case report with review of the literature

Chi Ma, Shao-Long Hao, Xin-Cheng Liu, Jin-Yao Nin, Guo-Chang Wu, Li-Xin Jiang, Alessandro Fancellu, Alberto Porcu, Hai-Tao Zheng

Chi Ma, Jin-Yao Nin, Guo-Chang Wu, Li-Xin Jiang, Hai-Tao Zheng, Department of Gastrointestinal and Thyroid Surgery, Yuhuangding Hospital Affiliated to Qingdao University, Yantai 264000, Shandong Province, China

Shao-Long Hao, Xin-Cheng Liu, Qingdao University Medical College, Qingdao 266021, Shandong Province, China

Alessandro Fancellu, Alberto Porcu, Unit of General Surgery, Department of Clinical and Experimental Medicine, University of Sassari, 07100 Sassari, Italy

Author contributions: Ma C drafted the manuscript, and contributed to acquisition of material; Hao SL and Liu XC collected material; Ning JY collected patient's information; Wu GC revised the manuscript, collected patient's information; Jiang LX revised the manuscript; Fancellu A and Porcu A revised the manuscript and modified the language; Zheng HT drafted the manuscript, and contributed to the acquisition of patient's information.

Institutional review board statement: Approved by the Yuhuangding Hospital Affiliated to Qingdao University Institutional Review Board.

Informed consent statement: All study participants, or their legal guardian, provided informed written consent prior to study enrollment.

Conflict-of-interest statement: There is no conflict of interest.

Open-Access: This article is an open-access article which was selected by an in-house editor and fully peer-reviewed by external reviewers. It is distributed in accordance with the Creative Commons Attribution Non Commercial (CC BY-NC 4.0) license, which permits others to distribute, remix, adapt, build upon this work non-commercially, and license their derivative works on different terms, provided the original work is properly cited and the use is non-commercial. See: <http://creativecommons.org/licenses/by-nc/4.0/>

Manuscript source: Unsolicited manuscript

Correspondence to: Hai-Tao Zheng, PhD, Department of Gastrointestinal and Thyroid Surgery, Yuhuangding Hospital Affiliated to Qingdao University, No. 20 Yuhuangdingdong Road, Zhifu District, Yantai 264000, Shandong Province, China. machi_sdu@163.com
Telephone: +86- 535-6691999

Received: October 26, 2016

Peer-review started: October 28, 2016

First decision: December 19, 2017

Revised: January 5, 2017

Accepted: January 18, 2017

Article in press: January 18, 2017

Published online: March 14, 2017

Abstract

Gastrointestinal stromal tumors (GISTs) represent the most common mesenchymal tumors of the alimentary tract. These tumors may have different clinical and biological behaviors. Malignant forms usually spread via a hematogenous route, and lymph node metastases rarely occur. Herein, we report a patient with a jejunal GIST who developed supraclavicular lymph node metastasis. We conclude that lymphatic diffusion via the mediastinal lymphatic station to the supraclavicular lymph nodes can be a potential metastatic route for GISTs.

Key words: Gastrointestinal stromal tumor; Metastasis; Lymph nodes

© The Author(s) 2017. Published by Baishideng Publishing Group Inc. All rights reserved.

Core tip: Unlike gastrointestinal carcinomas, lymph node metastases rarely develop in patients with malignant gastrointestinal stromal tumors (GISTs). We

report a patient with a jejunal GIST who developed supraclavicular lymph nodes metastasis and review the related literature. We conclude that lymphatic diffusion *via* mediastinal lymphatic station to the supraclavicular lymph nodes can be a potential metastatic route of GISTs.

Ma C, Hao SL, Liu XC, Nin JY, Wu GC, Jiang LX, Fancellu A, Porcu A, Zheng HT. Supraclavicular lymph node metastases from malignant gastrointestinal stromal tumor of the jejunum: A case report with review of the literature. *World J Gastroenterol* 2017; 23(10): 1920-1924 Available from: URL: <http://www.wjgnet.com/1007-9327/full/v23/i10/1920.htm> DOI: <http://dx.doi.org/10.3748/wjg.v23.i10.1920>

INTRODUCTION

Gastrointestinal stromal tumors (GISTs) represent the most common mesenchymal tumors of the alimentary tract. These tumors may have different clinical and biological behavior. Malignant forms usually spread *via* hematogenous route, and lymph nodes metastases rarely occur. Herein, we report a patient with jejunal GIST who developed supraclavicular lymph nodes metastasis.

CASE REPORT

A 56-year-old man with a 24-h history of melena was admitted to the gastrointestinal department of the Yuhuangding Hospital affiliated to Qingdao University, China. Laboratory assessment revealed a hemoglobin level of 8 g/dL. Urgent gastroduodenoscopy, colonoscopy, and enhanced computed tomography (CT) did not reveal any source of bleeding. During the next 24 h, the patient had further episodes of melena and became hemodynamically unstable after receiving a transfusion of 5 units of packed red blood cells and hemostatic agents. Therefore, emergency laparotomy was performed. Upon surgical exploration, a bleeding solid mass was found in the jejunum. Resection of a small bowel loop measuring 20 cm in length was performed. Gross examination revealed a nodular well-encapsulated tumor measuring 2 cm. Histologic sections showed a GIST infiltrating through all bowel layers, and it had features of mixed spindle and epithelioid types of cells. The mitotic index was $> 5/50$ high-power fields (HPFs). There was no infiltration of the surgical margins, and two harvested lymph nodes were free of metastases (Figure 1). CD117, CD34, and Dog-1 were positive in immunohistochemical studies; the Ki67 index was 20%. A diagnosis of GIST of the small intestine with high-grade malignancy was established based on the modified NIH GIST criteria^[1]. Postoperative total body CT scan and positron emission tomography-computed tomography (PET-CT) were negative for metastatic disease. Adjuvant imatinib

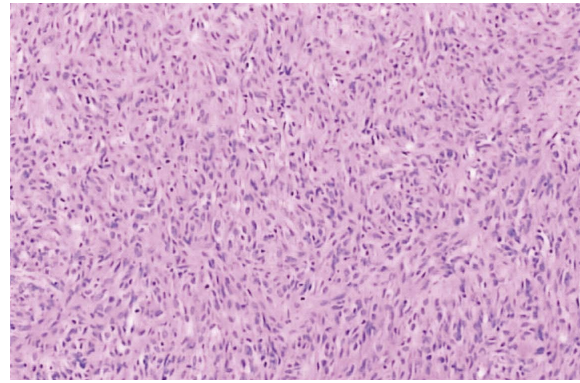


Figure 1 Histopathologic section of the primary tumor. The tumor was composed of spindle and epithelioid cells, which were predominantly arranged in spiral and lace-like shape (HE staining $\times 400$).

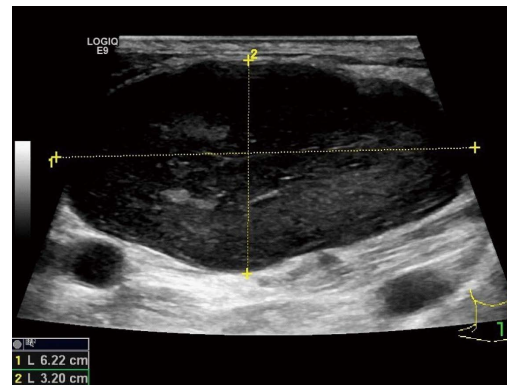


Figure 2 Ultrasonography of cervical mass: The mass was hypoechoic, with a smooth border and un-even internal echo.

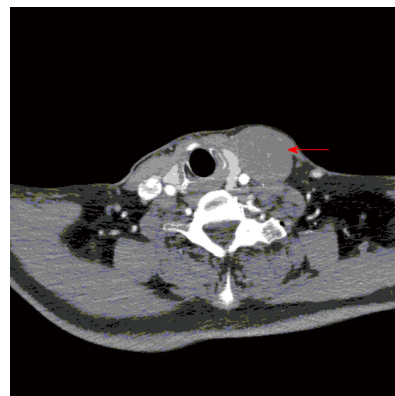


Figure 3 Computed tomography: The mass appeared as a low density cyst with clear edge without contrast enhancement.

therapy was prescribed, but he declined it due to family and economic reasons.

One year later, the patient was admitted to the thyroid department at same hospital complaining of a left cervical mass that had been gradually enlarging over one month. Ultrasound revealed a hypoechoic mass above the left clavicle, measuring 3.1 cm \times 4.6 cm; this mass was unenhanced in a contrast-enhanced CT scan (Figures 2 and 3). Interestingly,

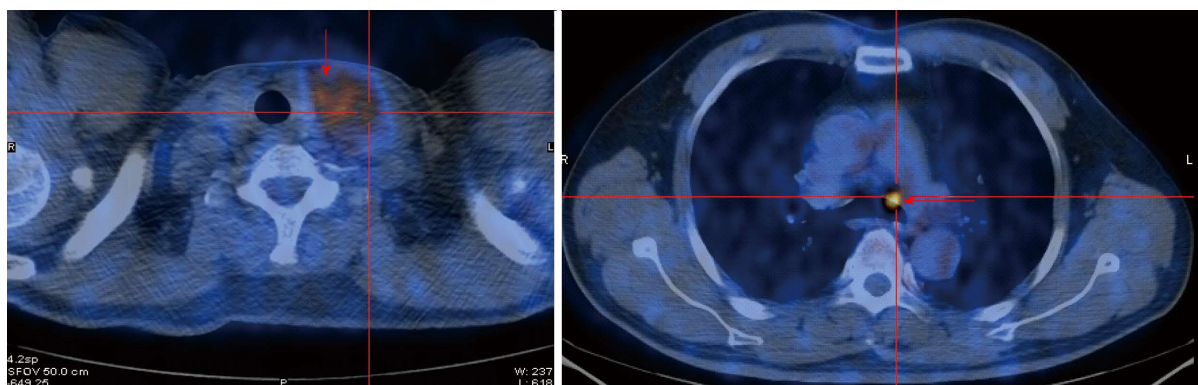


Figure 4 Positron emission tomography-computed tomography: FDG accumulated unevenly in the cervical mass and multiple lymph nodes in mediastinum.

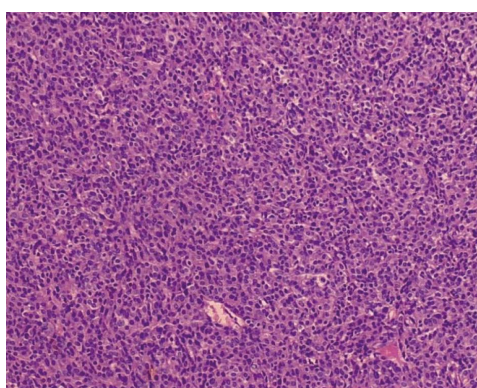


Figure 5 Histopathologic section of the cervical tumor (HE staining). The epithelioid cells were arranged in sheets, with abundant eosinophilic cytoplasm and prominent nuclei (HE staining $\times 400$).

there were no alterations of the thyroid in imaging studies. Core needle biopsy was performed, and histopathological examination with hematoxylin-eosin staining revealed lymph node metastasis from a GIST. In immunohistochemical studies, CD117, CD34, and vim were positive, whereas calponin, estrogen, progesterone, and thyroglobulin were negative. A PET-CT scan showed uneven ^{18}F -fluorodeoxyglucose (FDG) uptake in the cervical mass and multiple lymph nodes in the mediastinum (Figure 4). The patient underwent surgical removal of the cervical mass. Gross examination of the excised lymph node demonstrated that it measured 5 cm \times 6 cm \times 8 cm and appeared irregular, smooth, and well encapsulated. Histopathologic examination again confirmed a metastasis from a GIST (Figure 5). Immunohistochemical studies of the resected lymph node showed positivity for CD117 and CD34 and negativity for Dog-1 and S-100. The Ki67 index was 30%. Insertion of GCC TAT in exon 9 of the c-KIT gene was identified with mutation analysis. Exons 11, 13, and 17 and the PDGFR α gene were wild type. After the second operation, the patient was regularly given imatinib at a dose of 400 mg per day. At 1 year following the surgery, the patient was asymptomatic,

and there were no signs of tumor recurrence or progression (Table 1).

DISCUSSION

GISTs represent the most common neoplasms of mesenchymal origin of the gastrointestinal tract. GISTs may have different clinical and biological behavior, ranging from small benign tumors to aggressive forms that have a dismal prognosis. Approximately 20%-25% of GISTs are located in the stomach, and 40%-50% of those located in the small intestine were malignant neoplasms with features such as local recurrence after surgical removal, intraperitoneal dissemination and distant metastases^[2]. However, unlike gastrointestinal carcinomas, lymph node metastases (LNMs) rarely develop in patients with malignant GISTs. The mainstay of treatment for GISTs is complete surgical resection without a regional lymph adenectomy^[3,4].

The rates of LNMs from GISTs range from 0% to 5%^[3,5,6]. A few studies reporting on this subject are summarized in Table 1^[5,7-19]. Most of the reported cases are peritumoral lymph nodes metastases, which have occasionally been discovered with histopathological examination of surgical specimens. We found only 3 cases that could be defined as distant LNMs^[14,18], including 2 inguinal lymph nodes and 1 axillary lymph node. In our case, LNMs developed in the left supraclavicular and mediastinal basins. This behavior is similar to that observed in malignant gastrointestinal tumors of an epithelial origin. To the best of our knowledge, this is the first case report of the lymphatic spread of a gastric GIST to supraclavicular and mediastinum lymph nodes. This might indicate that a particular subgroup of GISTs has biological characteristics similar to carcinomas.

According to the modified NIH GIST criteria, our case was a high-grade malignancy^[1]. Ki67 expression changed from 20% in the primary tumor to 30% in the supraclavicular metastasis. Interestingly, Dog-1

Table 1 Clinical characteristics of cases reported

| Ref. | Primary site | HPF | T size (cm) | Treatment | LNM site | LNM time | Gene mutation |
|--|------------------|----------|-------------|---|-------------------------------------|----------|------------------------------|
| Sato <i>et al</i> ^[7] | Gastric | | 4 | Proximal gastrectomy | Right cardia | Pre | deletion mutation in exon 11 |
| | Gastric | | 2.5 | Wedge resection + partial hepatectomy | Adjacent to the tumor Mesenteric | Pre | No mutation |
| El Demellawy <i>et al</i> ^[8] | Small bowel | | | | | Pre | |
| Hu <i>et al</i> ^[9] | Hepatic | 4/10 | 15 × 10 | Right hepatic lobectomy | Hilar | Post | |
| Canda <i>et al</i> ^[12] | Gastric | 25/50 | 8 × 8 × 4 | Distal gastrectomy + perigastric LN dissection | Perigastric | Pre | No mutation |
| Kong <i>et al</i> ^[13] | Small intestinal | 2/50 | 6 × 7 | Partial resection of the ileum | Peri-intestine | Pre | deletion 559-569 in exon 11 |
| | Small intestinal | 2/50 | 5 × 5 | Partial resection of the ileum | Peri-intestine | Pre | Deletion 559-565 in exon 11 |
| Zhang <i>et al</i> ^[14] | Gastric | | | Distal gastrectomy, perigastric lymphadenectomy and hepatectomy | Inguinal LN | Post | deletion 557/558 in exon 11 |
| Yamada <i>et al</i> ^[15] | Gastric | > 5/50 | 4.5 × 3.5 | Gastrectomy + lymph node dissection | Perigastric | Pre | |
| Catani <i>et al</i> ^[19] | Gastric | | | Gastrectomy + resection of the tail of the pancreas, the spleen, and the transverse colon | Perigastric | Pre | |
| Masuda <i>et al</i> ^[16] | Esophagus | 15/50 | 9.5 | Subtotal esophagectomy | Periesophagus | Pre | |
| Shafizad <i>et al</i> ^[17] | Gastric | | 8 | Total gastrectomy and omentectomy | Perigastric | Pre | |
| Vassos <i>et al</i> ^[18] | Ileum | | | Partial resection of the ileum | Inguinal | Pre | |
| | Gastric | | | Extended gastrectomy, atypical liver resection, splenectomy | Auxiliary | Post | |
| Sakurai <i>et al</i> ^[10] | Esophagus | | | Middle and lower esophagectomy | Multiple | Post | |
| Asakage <i>et al</i> ^[11] | Gastric | | | Total gastrectomy with distal pancreateosplenectomy and segmental liver resection | Perigastric | Pre | |
| Tashiro <i>et al</i> ^[5] | Gastric | | 1-5 | | | | No mutation |
| | Gastric | Ki67 10% | 2.5 | Proximal gastrectomy with sampling of the regional LNs | | | Exon 11 |

HPF: High-power fields; LNM: Lymph node metastases; Pre: Before or during operation; Post: After operation.

was negative in the LNM, whereas it was positive in primary tumor. It could be speculated that the Ki67 and Dog-1 levels may be markers of a primary tumor de-differentiation tendency.

Activating mutations of the c-kit gene (especially exons 11 and 9) are present in most GISTs and probably play a fundamental role in the development of these tumors. Among the reported cases of LNMs from GISTs, few gene detection results have been described, most of which are exon 11 mutations^[5,7,13,14]. In the study by Kong *et al*^[13], the exon 11 mutation was linked to the likelihood of LNMs. However, in our case, we found an exon 9 mutation. This genetic mutation in the LNMs from GISTs has not been reported to date. The relationship between gene mutations and LNMs is still not clear, but many authors have stated that KIT exon 9-mutant tumors developed imatinib resistance more frequently than exon 11-mutant tumors^[20,21]. Cases with exon 9-mutant tumors should be treated with increased imatinib doses. Because the patient declined imatinib treatment after the first surgery, he was treated with 400 mg of imatinib per day after the second operation.

In conclusion, complete surgical resection remains the mainstay of treatment for resectable GISTs. Imatinib is currently indicated for the first-line treatment of patients with metastatic or unresectable KIT-positive GISTs. Adjuvant therapy with imatinib was deemed necessary for this patient following complete

resection of a primary jejunal tumor because it was an aggressive, high-risk form of GIST. Unfortunately, he did not take imatinib after his first operation, and distant lymph node metastases occurred after 12 months. Following the second operation, the patient received imatinib treatment and had survived without disease progression at the 1-year follow up.

This case confirms that LNMs in the mediastinum and supraclavicular lymph nodes is a potential metastatic route for malignant GISTs. Further studies are needed to clarify the mechanism of lymph node metastases in patients with GISTs.

COMMENTS

Case characteristics

The patient was admitted to hospital, complaining of a left cervical mass, which had been diagnosed as a jejunum gastrointestinal stromal tumor (GIST) and cured by surgery 1 year before.

Clinical diagnosis

For the differential diagnoses of thyroid tumor, lymphoma, or metastatic carcinoma, the patient underwent computed tomography (CT), ultrasound (US), positron emission tomography-computed tomography (PET-CT) and biopsy. US, CT and PET-CT revealed a hypoechoic, unenhanced and uneven FDG uptake mass above the left clavicle measuring 3.1 cm × 4.6 cm.

Laboratory diagnosis

After a biopsy of the cervical mass, this patient was diagnosed as having supraclavicular lymph node metastases from GISTs.

Pathological diagnosis

Core needle biopsy was carried out, and the histopathological examination using hematoxylin-eosin stain showed lymph node metastasis from GIST.

Treatment

The patient underwent surgical removal of the cervical mass and was regularly given imatinib 400 mg per day after the second operation.

Experiences and lessons

This case confirms that LNM in the mediastinum and supraclavicular lymph nodes are a potential metastatic route of malignant GISTs. Physicians should be aware of this during operation and chemotherapy. In this case report, we tried to give some but not sufficient evidence of the possible mechanisms of the supraclavicular lymph node metastasis.

Peer-review

This case report is well organized and had much information including genetic analysis data on primary GIST and metastatic lesion.

REFERENCES

- 1 **Joensuu H.** Risk stratification of patients diagnosed with gastrointestinal stromal tumor. *Hum Pathol* 2008; **39**: 1411-1419 [PMID: 18774375 DOI: 10.1016/j.humpath.2008.06.025]
- 2 **Miettinen M, Lasota J.** Gastrointestinal stromal tumors: review on morphology, molecular pathology, prognosis, and differential diagnosis. *Arch Pathol Lab Med* 2006; **130**: 1466-1478 [PMID: 17090188 DOI: 10.1043/1543-2165(2006)130]
- 3 **DeMatteo RP, Lewis JJ, Leung D, Mudan SS, Woodruff JM, Brennan MF.** Two hundred gastrointestinal stromal tumors: recurrence patterns and prognostic factors for survival. *Ann Surg* 2000; **231**: 51-58 [PMID: 10636102]
- 4 **Pierie JP, Choudry U, Muzikansky A, Yeap BY, Souba WW, Ott MJ.** The effect of surgery and grade on outcome of gastrointestinal stromal tumors. *Arch Surg* 2001; **136**: 383-389 [PMID: 11296107]
- 5 **Tashiro T, Hasegawa T, Omatsu M, Sekine S, Shimoda T, Katai H.** Gastrointestinal stromal tumour of the stomach showing lymph node metastases. *Histopathology* 2005; **47**: 438-439 [PMID: 16178904 DOI: 10.1111/j.1365-2559.2005.02133.x]
- 6 **Aparicio T, Boige V, Sabourin JC, Crenn P, Ducreux M, Le Cesne A, Bonvalot S.** Prognostic factors after surgery of primary resectable gastrointestinal stromal tumours. *Eur J Surg Oncol* 2004; **30**: 1098-1103 [PMID: 15522557 DOI: 10.1016/j.ejso.2004.06.016]
- 7 **Sato T, Kanda T, Nishikura K, Hirota S, Hashimoto K, Nahagawa S, Ohashi M, Hatakeyama K.** Two cases of gastrointestinal stromal tumor of the stomach with lymph node metastasis. *Hepatogastroenterology* 2007; **54**: 1057-1060 [PMID: 17629038]
- 8 **El Demellawy D, Shokry P, Ing A, Khalifa M.** Polypoid gastrointestinal stromal tumor of small bowel metastasizing to mesenteric lymph nodes: a case report. *Pathol Res Pract* 2008; **204**: 197-201 [PMID: 18096326 DOI: 10.1016/j.prp.2007.10.007]
- 9 **Hu X, Forster J, Damjanov I.** Primary malignant gastrointestinal stromal tumor of the liver. *Arch Pathol Lab Med* 2003; **127**: 1606-1608 [PMID: 14632569 DOI: 10.1043/1543-2165(2003)127<1606:pmgst>2.0.co;2]

- 10 **Sakurai N, Yamauchi J, Shibuma H, Ikeda E, Sasou S.** [A case of recurrent GIST of the esophagus which completely responded to imatinib mesilate]. *Gan To Kagaku Ryoho* 2007; **34**: 237-240 [PMID: 17301535]
- 11 **Asakage N, Kobayashi S, Gotou T, Sasaki M, Tsukada K, Suzuki T, Yamamoto T, Sekine M, Miyazaki E, Hirai S, Yamasaki S.** [Two cases of gastrointestinal stromal tumor (GIST) of the stomach and a consideration of its malignancy potential and treatment strategy - report of two cases]. *Gan To Kagaku Ryoho* 2007; **34**: 919-923 [PMID: 17565257]
- 12 **Canda AE, Ozsoy Y, Nalbant OA, Sagol O.** Gastrointestinal stromal tumor of the stomach with lymph node metastasis. *World J Surg Oncol* 2008; **6**: 97 [PMID: 18775061 DOI: 10.1186/1477-7819-6-97]
- 13 **Kong M, Wang YL, Xu LJ, Teng XD.** [Gastrointestinal stromal tumor of small intestine associated with lymph node metastasis: a report of 2 cases with review of literatures]. *Zhonghua Bing Li Xue Za Zhi* 2009; **38**: 617-620 [PMID: 20079191]
- 14 **Zhang Q, Yu JW, Yang WL, Liu XS, Yu JR.** Gastrointestinal stromal tumor of stomach with inguinal lymph nodes metastasis: a case report. *World J Gastroenterol* 2010; **16**: 1808-1810 [PMID: 20380018 DOI: 10.3748/wjg.v16.i14.1808]
- 15 **Yamada E, Oyaizu T, Miyashita T.** [A case of gastrointestinal stromal tumor of the stomach with lymph node metastasis followed up for 7 years without evidence of recurrence after surgery]. *Nihon Shokakibyo Gakkai Zasshi* 2010; **107**: 743-749 [PMID: 20460848]
- 16 **Masuda T, Toh Y, Kabashima A, Aoki Y, Harimoto N, Ito S, Taomoto J, Ikeda O, Ohga T, Adachi E, Sakaguchi Y, Hirahashi M, Nishiyama K, Okamura T.** Overt lymph node metastases from a gastrointestinal stromal tumor of the esophagus. *J Thorac Cardiovasc Surg* 2007; **134**: 810-811 [PMID: 17723845 DOI: 10.1016/j.jtcvs.2007.06.002]
- 17 **Shafizad A, Mohammadianpanah M, Nasrolahi H, Mokhtari M, Mousavi SA.** Lymph Node Metastasis in Gastrointestinal Stromal Tumor (GIST): to Report a Case. *Iran J Cancer Prev* 2014; **7**: 171-174 [PMID: 25250169]
- 18 **Vassos N, Agaimy A, Hohenberger W, Croner RS.** Extraabdominal lymph node metastasis in gastrointestinal stromal tumors (GIST). *J Gastrointest Surg* 2011; **15**: 1232-1236 [PMID: 21336495 DOI: 10.1007/s11605-011-1464-3]
- 19 **Catani M, De Milito R, Simi M.** [New orientations in the management of advanced, metastatic gastrointestinal stromal tumors (GIST): combination of surgery and systemic therapy with imatinib in a case of primary gastric location]. *Chir Ital* 2005; **57**: 127-133 [PMID: 15832750]
- 20 **Heinrich MC, Owzar K, Corless CL, Hollis D, Borden EC, Fletcher CD, Ryan CW, von Mehren M, Blanke CD, Rankin C, Benjamin RS, Bramwell VH, Demetri GD, Bertagnolli MM, Fletcher JA.** Correlation of kinase genotype and clinical outcome in the North American Intergroup Phase III Trial of imatinib mesylate for treatment of advanced gastrointestinal stromal tumor: CALGB 150105 Study by Cancer and Leukemia Group B and Southwest Oncology Group. *J Clin Oncol* 2008; **26**: 5360-5367 [PMID: 18955451 DOI: 10.1200/jco.2008.17.4284]
- 21 **Lee JH, Kim Y, Choi JW, Kim YS.** Correlation of imatinib resistance with the mutational status of KIT and PDGFRA genes in gastrointestinal stromal tumors: a meta-analysis. *J Gastrointest Liver Dis* 2013; **22**: 413-418 [PMID: 24369323]

P- Reviewer: Alimehmeti RH, Kim ST **S- Editor:** Qi Y
L- Editor: Ma JY **E- Editor:** Wang CH





Published by **Baishideng Publishing Group Inc**

8226 Regency Drive, Pleasanton, CA 94588, USA

Telephone: +1-925-223-8242

Fax: +1-925-223-8243

E-mail: bpgoffice@wjgnet.com

Help Desk: <http://www.wjgnet.com/esps/helpdesk.aspx>

<http://www.wjgnet.com>



ISSN 1007-9327



9 771007 932045

