

World Journal of *Gastroenterology*

World J Gastroenterol 2017 July 28; 23(28): 5041-5256



**EDITORIAL**

- 5041** Colorectal cancer in young adults: A difficult challenge

Campos FG

- 5045** Precision medicine: In need of guidance and surveillance

Lin JZ, Long JY, Wang AQ, Zheng Y, Zhao HT

REVIEW

- 5051** Barrett's oesophagus: Current controversies

Amadi C, Gatenby P

- 5068** Gastrointestinal neuroendocrine peptides/amines in inflammatory bowel disease

El-Salhy M, Solomon T, Hausken T, Gilja OH, Hatlebakk JG

- 5086** Colorectal cancer screening: An updated review of the available options

Issa IA, Noureddine M

- 5097** Therapeutic potential of flavonoids in inflammatory bowel disease: A comprehensive review

Salaritabar A, Darvishi B, Hadjiakhoondi F, Manayi A, Sureda A, Nabavi SF, Fitzpatrick LR, Nabavi SM, Bishayee A

ORIGINAL ARTICLE**Basic Study**

- 5115** Myo-inositol reduces β -catenin activation in colitis

Bradford EM, Thompson CA, Goretsky T, Yang GY, Rodriguez LM, Li L, Barrett TA

- 5127** Involvement of CRF2 signaling in enterocyte differentiation

Ducarouge B, Pelissier-Rota M, Powell R, Buisson A, Bonaz B, Jacquier-Sarlin M

- 5146** Bone marrow-derived monocyte infusion improves hepatic fibrosis by decreasing osteopontin, TGF- β 1, IL-13 and oxidative stress

de Souza VCA, Pereira TA, Teixeira VW, Carvalho H, de Castro MCAB, D'assunção CG, de Barros AF, Carvalho CL, de Lorena VMB, Costa VMA, Teixeira AAC, Figueiredo RCBQ, de Oliveira SA

- 5158** Single amino acid mutation of SR-BI decreases infectivity of hepatitis C virus derived from cell culture in a cell culture model

Gao R, Gao W, Xu G, Xu J, Ren H

- 5167 Fibroblast-derived CXCL12/SDF-1 α promotes CXCL6 secretion and co-operatively enhances metastatic potential through the PI3K/Akt/mTOR pathway in colon cancer

Ma JC, Sun XW, Su H, Chen Q, Guo TK, Li Y, Chen XC, Guo J, Gong ZQ, Zhao XD, Qi JB

Case Control Study

- 5179 Association between *CYP24A1* polymorphisms and the risk of colonic polyps and colon cancer in a Chinese population

Chen XQ, Mao JY, Li WB, Li J, Yang H, Qian JM, Li JN

Retrospective Cohort Study

- 5187 Clinical significance of glycemic parameters on venous thromboembolism risk prediction in gastrointestinal cancer

Guadagni F, Riondino S, Formica V, Del Monte G, Morelli AM, Lucchetti J, Spila A, D'Alessandro R, Della-Morte D, Ferroni P, Roselli M

- 5196 Sex-dependent difference in the effect of metformin on colorectal cancer-specific mortality of diabetic colorectal cancer patients

Park JW, Lee JH, Park YH, Park SJ, Cheon JH, Kim WH, Kim TI

Retrospective Study

- 5206 Sex-influenced association of non-alcoholic fatty liver disease with colorectal adenomatous and hyperplastic polyps

Chen QF, Zhou XD, Sun YJ, Fang DH, Zhao Q, Huang JH, Jin Y, Wu JS

Observational Study

- 5216 Development and validation of a simple and multifaceted instrument, GERD-TEST, for the clinical evaluation of gastroesophageal reflux and dyspeptic symptoms

Nakada K, Matsuhashi N, Iwakiri K, Oshio A, Joh T, Higuchi K, Haruma K

- 5229 Modified B-ultrasound method for measurement of antral section only to assess gastric function and guide enteral nutrition in critically ill patients

Liu Y, Gao YK, Yao L, Li L

Prospective Study

- 5237 Chronic liver failure-consortium acute-on-chronic liver failure and acute decompensation scores predict mortality in Brazilian cirrhotic patients

Picon RV, Bertol FS, Tovo CV, de Mattos ÁZ

CASE REPORT

- 5246 Refractory hepatic encephalopathy in a patient with hypothyroidism: Another element in ammonia metabolism

Díaz-Fontenla F, Castillo-Pradillo M, Díaz-Gómez A, Ibáñez-Samaniego L, Gancedo P, Guzmán-de-Villoria JA, Fernández-García P, Bañares-Cañizares R, García-Martínez R

- 5253** Endoscopic occlusion with silicone spigots for the closure of refractory esophago-bronchiole fistula after esophagectomy

Uesato M, Kono T, Akutsu Y, Murakami K, Kagaya A, Muto Y, Nakano A, Aikawa M, Tamachi T, Amagai H, Arasawa T, Muto Y, Matsubara H

Contents

World Journal of Gastroenterology
Volume 23 Number 28 July 28, 2017

ABOUT COVER

Editorial board member of *World Journal of Gastroenterology*, Edoardo G Giannini, FACC, MD, PhD, Assistant Professor, Department of Internal Medicine, University of Genoa, 16132 Genova, Italy

AIMS AND SCOPE

World Journal of Gastroenterology (*World J Gastroenterol*, *WJG*, print ISSN 1007-9327, online ISSN 2219-2840, DOI: 10.3748) is a peer-reviewed open access journal. *WJG* was established on October 1, 1995. It is published weekly on the 7th, 14th, 21st, and 28th each month. The *WJG* Editorial Board consists of 1375 experts in gastroenterology and hepatology from 68 countries.

The primary task of *WJG* is to rapidly publish high-quality original articles, reviews, and commentaries in the fields of gastroenterology, hepatology, gastrointestinal endoscopy, gastrointestinal surgery, hepatobiliary surgery, gastrointestinal oncology, gastrointestinal radiation oncology, gastrointestinal imaging, gastrointestinal interventional therapy, gastrointestinal infectious diseases, gastrointestinal pharmacology, gastrointestinal pathophysiology, gastrointestinal pathology, evidence-based medicine in gastroenterology, pancreatology, gastrointestinal laboratory medicine, gastrointestinal molecular biology, gastrointestinal immunology, gastrointestinal microbiology, gastrointestinal genetics, gastrointestinal translational medicine, gastrointestinal diagnostics, and gastrointestinal therapeutics. *WJG* is dedicated to become an influential and prestigious journal in gastroenterology and hepatology, to promote the development of above disciplines, and to improve the diagnostic and therapeutic skill and expertise of clinicians.

INDEXING/ABSTRACTING

World Journal of Gastroenterology (*WJG*) is now indexed in Current Contents[®]/Clinical Medicine, Science Citation Index Expanded (also known as SciSearch[®]), Journal Citation Reports[®], Index Medicus, MEDLINE, PubMed, PubMed Central and Directory of Open Access Journals. The 2017 edition of Journal Citation Reports[®] cites the 2016 impact factor for *WJG* as 3.365 (5-year impact factor: 3.176), ranking *WJG* as 29th among 79 journals in gastroenterology and hepatology (quartile in category Q2).

FLYLEAF

I-IX Editorial Board

EDITORS FOR THIS ISSUE

Responsible Assistant Editor: *Xiang Li*
Responsible Electronic Editor: *Fen-Fen Zhang*
Proofing Editor-in-Chief: *Lian-Sheng Ma*

Responsible Science Editor: *Yuan Qi*
Proofing Editorial Office Director: *Jin-Lei Wang*

NAME OF JOURNAL
World Journal of Gastroenterology

ISSN
ISSN 1007-9327 (print)
ISSN 2219-2840 (online)

LAUNCH DATE
October 1, 1995

FREQUENCY
Weekly

EDITORS-IN-CHIEF
Damian Garcia-Olmo, MD, PhD, Doctor, Professor, Surgeon, Department of Surgery, Universidad Autonoma de Madrid; Department of General Surgery, Fundacion Jimenez Diaz University Hospital, Madrid 28040, Spain

Stephen C Strom, PhD, Professor, Department of Laboratory Medicine, Division of Pathology, Karolinska Institutet, Stockholm 141-86, Sweden

Andrzej S Tarnawski, MD, PhD, DSc (Med), Professor of Medicine, Chief Gastroenterology, VA Long Beach Health Care System, University of California, Irvine, CA, 5901 E. Seventh Str., Long Beach,

CA 90822, United States

EDITORIAL BOARD MEMBERS
All editorial board members resources online at <http://www.wjgnet.com/1007-9327/editorialboard.htm>

EDITORIAL OFFICE
Jin-Lei Wang, Director
Yuan Qi, Vice Director
Ze-Mao Gong, Vice Director
World Journal of Gastroenterology
Baishideng Publishing Group Inc
7901 Stoneridge Drive, Suite 501,
Pleasanton, CA 94588, USA
Telephone: +1-925-2238242
Fax: +1-925-2238243
E-mail: editorialoffice@wjgnet.com
Help Desk: <http://www.f6publishing.com/helpdesk>
<http://www.wjgnet.com>

PUBLISHER
Baishideng Publishing Group Inc
7901 Stoneridge Drive, Suite 501,
Pleasanton, CA 94588, USA
Telephone: +1-925-2238242
Fax: +1-925-2238243
E-mail: bpgoffice@wjgnet.com
Help Desk: <http://www.f6publishing.com/helpdesk>

<http://www.wjgnet.com>

PUBLICATION DATE
July 28, 2017

COPYRIGHT
© 2017 Baishideng Publishing Group Inc. Articles published by this Open-Access journal are distributed under the terms of the Creative Commons Attribution Non-commercial License, which permits use, distribution, and reproduction in any medium, provided the original work is properly cited, the use is non commercial and is otherwise in compliance with the license.

SPECIAL STATEMENT
All articles published in journals owned by the Baishideng Publishing Group (BPG) represent the views and opinions of their authors, and not the views, opinions or policies of the BPG, except where otherwise explicitly indicated.

INSTRUCTIONS TO AUTHORS
Full instructions are available online at <http://www.wjgnet.com/bpg/gerinfo/204>

ONLINE SUBMISSION
<http://www.f6publishing.com>

Refractory hepatic encephalopathy in a patient with hypothyroidism: Another element in ammonia metabolism

Fernando Díaz-Fontenla, Marta Castillo-Pradillo, Arantxa Díaz-Gómez, Luis Ibañez-Samaniego, Pilar Gancedo, Juan Adan Guzmán-de-Villoria, Pilar Fernández-García, Rafael Bañares-Cañizares, Rita García-Martínez

Fernando Díaz-Fontenla, Marta Castillo-Pradillo, Arantxa Díaz-Gómez, Luis Ibañez-Samaniego, Rafael Bañares-Cañizares, Rita García-Martínez, Unidad de Hepatología, Servicio de Aparato Digestivo, Hospital General Universitario Gregorio Marañón, 28007 Madrid, Spain

Luis Ibañez-Samaniego, Rafael Bañares-Cañizares, Rita García-Martínez, Instituto de Investigación Sanitaria Hospital Gregorio Marañón, 28007 Madrid, Spain

Pilar Gancedo, Servicio de Aparato Digestivo, Hospital Santa Bárbara, Puertollano, 13500 Ciudad Real, Spain

Juan Adan Guzmán-de-Villoria, Pilar Fernández-García, Servicio de Radiodiagnóstico, Hospital General Universitario Gregorio Marañón, 28007 Madrid, Spain

Juan Adan Guzmán-de-Villoria, Pilar Fernández-García, Centro de Investigación Biomédica en Red de Salud Mental, 28007 Madrid, Spain

Rafael Bañares-Cañizares, Rita García-Martínez, Centro de Investigación Biomédica en Red de Enfermedades Hepáticas y Digestivas, 28007 Madrid, Spain

Rita García-Martínez, Facultad de Medicina, Universidad San Pablo CEU, 28007 Madrid, Spain

Author contributions: Díaz-Fontenla F, Castillo-Pradillo M, Díaz-Gómez A, Ibañez-Samaniego L, Fernández-García P and García-Martínez R contributed to the clinical evaluation and management of patient the and data acquisition; Guzmán-de-Villoria JA and Fernández-García P contributed to magnetic resonance data acquisition and interpretation; Bañares-Cañizares R critically reviewed the manuscript; García-Martínez R interpreted the data and drafted the manuscript; all authors contributed to this manuscript.

Institutional review board statement: This case report was exempt from the Institutional Review Board Standards at Hospital General Universitario Gregorio Marañón, Madrid, Spain.

Informed consent statement: All the procedures performed

were in agreement with standard clinical practice. The patient gave written informed consent for publication.

Conflict-of-interest statement: The authors do not have anything to disclose regarding funding or conflict of interest with respect to this manuscript.

Open-Access: This article is an open-access article which was selected by an in-house editor and fully peer-reviewed by external reviewers. It is distributed in accordance with the Creative Commons Attribution Non Commercial (CC BY-NC 4.0) license, which permits others to distribute, remix, adapt, build upon this work non-commercially, and license their derivative works on different terms, provided the original work is properly cited and the use is non-commercial. See: <http://creativecommons.org/licenses/by-nc/4.0/>

Manuscript source: Unsolicited manuscript

Correspondence to: Dr. Rita García-Martínez, Unidad de Hepatología, Servicio de Aparato Digestivo, Hospital General Universitario Gregorio Marañón, Calle del Doctor Esquerdo 46, 28007 Madrid, Spain. rgarciamartinez3@salud.madrid.org
Telephone: +34-91-5868308
Fax: +34-34-91-4265125

Received: December 15, 2016

Peer-review started: December 17, 2016

First decision: January 10, 2017

Revised: February 21, 2017

Accepted: May 4, 2017

Article in press: May 4, 2017

Published online: July 28, 2017

Abstract

Hepatic encephalopathy (HE) remains a diagnosis of exclusion due to the lack of specific signs and symptoms. Refractory HE is an uncommon but serious condition that requires the search of hidden precipitating events (*i.e.*, portosystemic shunt) and alternative

diagnosis. Hypothyroidism shares clinical manifestations with HE and is usually considered within the differential diagnosis of HE. Here, we describe a patient with refractory HE who presented a large portosystemic shunt and post-ablative hypothyroidism. Her cognitive impairment, hyperammonaemia, electroencephalograph alterations, impaired neuropsychological performance, and magnetic resonance imaging and spectroscopy disturbances were highly suggestive of HE, paralleled the course of hypothyroidism and normalized after thyroid hormone replacement. There was no need for intervention over the portosystemic shunt. The case findings support that hypothyroidism may precipitate HE in cirrhotic patients by inducing hyperammonaemia and/or enhancing ammonia brain toxicity. This case led us to consider hypothyroidism not only in the differential diagnosis but also as a precipitating factor of HE.

Key words: Hepatic encephalopathy; Hypothyroidism; Cognitive impairment; Cirrhosis; Portosystemic shunt; Magnetic resonance spectroscopy

© The Author(s) 2017. Published by Baishideng Publishing Group Inc. All rights reserved.

Core tip: Hepatic encephalopathy (HE) remains a diagnosis of exclusion due to the lack of specific signs and symptoms. Refractory HE requires the search of hidden precipitating events and alternative diagnosis. We describe a patient with refractory HE who presented with large portosystemic shunt and post-ablative hypothyroidism. Her cognitive impairment, hyperammonaemia, electroencephalograph alterations, impaired neuropsychological performance and magnetic resonance imaging and spectroscopy disturbances suggestive of HE paralleled the course of hypothyroidism and improved after thyroid hormone replacement. The case findings support that hypothyroidism may precipitate HE in cirrhotic patients by inducing hyperammonaemia and/or enhancing ammonia brain toxicity.

Díaz-Fontenla F, Castillo-Pradillo M, Díaz-Gómez A, Ibáñez-Samaniego L, Gancedo P, Guzmán-de-Villoria JA, Fernández-García P, Bañares-Cañizares R, García-Martínez R. Refractory hepatic encephalopathy in a patient with hypothyroidism: Another element in ammonia metabolism. *World J Gastroenterol* 2017; 23(28): 5246-5252 Available from: URL: <http://www.wjgnet.com/1007-9327/full/v23/i28/5246.htm> DOI: <http://dx.doi.org/10.3748/wjg.v23.i28.5246>

INTRODUCTION

Hepatic encephalopathy (HE) is a brain dysfunction that frequently affects patients with chronic liver failure. Its symptoms and signs are not specific and may also be present in other causes of brain dysfunction^[1]. In cirrhotic patients, an episode of HE is usually triggered

by a clinical event that exacerbates the toxic effects of ammonia and other substances on the brain. The search and adequate treatment of such precipitating factors are fundamental to revert the HE of these patients. Refractory HE is an uncommon but serious condition that requires the search of alternative diagnosis and non-identified precipitating factors.

Hypothyroidism shares clinical manifestations with HE, such as disturbances in memory and attention, and is considered in the differential diagnosis of HE. However, little is known on whether hypothyroidism coexists with or precipitates HE. Herein, we describe a patient with a large portosystemic shunt who developed refractory HE during post-ablative hypothyroidism. The case's clinical manifestations, electroencephalographic pattern and magnetic resonance imaging (MRI) and spectroscopy (MRS) findings were consistent with HE. Treatment with thyroid hormone normalized ammonia levels and improved clinical alterations and electroencephalograph (EEG). MRI and MRS showed an improvement in markers of ammonia toxicity, suggesting that hypothyroidism might increase brain exposition to ammonia and precipitate HE. This case led us to consider hypothyroidism not only in the differential diagnosis, but also as a precipitating factor of HE.

CASE REPORT

A 58-year-old woman with the diagnosis of chronic and refractory HE in the setting of liver cirrhosis and large portosystemic shunt was referred to our Liver Unit from a secondary hospital. Her liver disease was diagnosed in 2011 when she presented her first episode of overt HE (type C, grade II). Due to a history of alcohol abuse for years and other causes of liver disease being ruled out, a diagnosis of alcoholic cirrhosis Child-Pugh B7 was established. The patient had no ascites nor hepatocellular carcinoma, and primary prophylaxis with propranolol because of oesophageal varices grade II-III/IV was started. At that time, the patient abandoned alcohol consumption, and remained asymptomatic and compensated from the liver point of view.

As comorbidities, the patient had diabetes mellitus, arterial hypertension and multinodular goitre diagnosed in 2011 in a pre-toxic state. In January 2012, she started carbimazole and received radioiodine therapy in February 2012 because of hyperthyroidism. Carbimazole was stopped after 4 mo, and treatment with levothyroxine (October 2012-April 2013) was subsequently started because of post-ablative hypothyroidism. In August 2013, carbimazole was restarted due to recurrent toxic multinodular goitre, and a second session of radioiodine was administered in November 2014. Carbimazole was stopped at the end of November 2014 and levothyroxine was again prescribed in middle of January 2015 because of

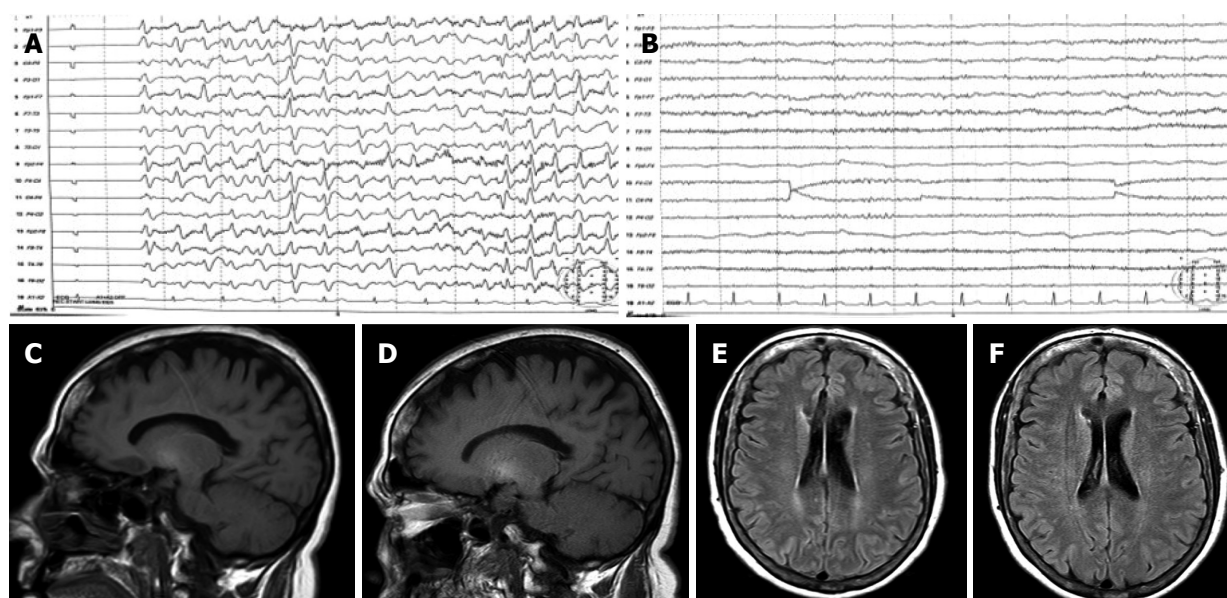


Figure 1 Electroencephalograph and magnetic resonance findings at baseline and after treatment with thyroid hormone. A: EEG at baseline showing slow activity and generalized triphasic waves; B: EEG after treatment showing normalization of brain activity; C: T1-weighted MRI showed high-signal in basal ganglia at baseline; D: T1-weighted MRI performed after thyroid hormone replacement showed non-significant changes; E: FLAIR MRI sequence at baseline demonstrated subtle periventricular white matter hyperintensities; F: FLAIR MRI image after thyroid hormone replacement demonstrated a normalization of periventricular white matter signal abnormalities. EEG: Electroencephalograph; MRI: Magnetic resonance imaging.

subclinical hypothyroidism (thyroid-stimulating hormone (TSH) 8 mUI/L, normal range: 0.5–4.5 mUI/L).

In February 2015, the patient was admitted to another hospital because of a subacute neurological syndrome consistent with daily hypersomnia, dysarthria, mental slowness, bizarre behaviour (“she wanted to turn on the TV with her keys”) and diminished voluntary movements. At the physical exam, she was conscious and oriented, although she presented mental slowness and slow speech rate, shortened attention span and irritability. The patient had asterixis, with no other evident motor or neurological alterations. Laboratory test showed mild macrocytosis, with no other abnormalities and the brain computed tomography (CT) scan was also normal. Precipitating factors were not found (no infection, gastrointestinal bleeding or recent alcohol abuse was documented) and oral and rectal lactulose was started, producing adequate laxative response. However, rifaximin was added because of lack of clinical efficacy.

An EEG was performed and showed slow activity with the presence of generalized triphasic waves (Figure 1A). Because of persistent neurological impairment consistent with HE, an abdominal CT scan searching for portosystemic shunts was performed and revealed a large shunt communicating portal and left renal veins. The patient was then referred to our tertiary hospital for shunt embolization.

At admission, the patient showed similar neurological status with hypersomnia, mental slowness, shortened attention span, and memory difficulties, but was oriented in time and space. Asterixis and temporal disorientation was occasionally present but other

neurological abnormalities were not observed. She reported pronounced constipation and gained weight of 3 kg within the last weeks. During her stay in the hospital, she remained neurologically stable despite high doses of oral lactulose (with adequate daily bowel movements) and rifaximin, developing occasionally confusion, disorientation and asterixis without clear precipitating factor and with partial response to lactulose intensification.

Laboratory testing (Table 1) showed macrocytosis without anaemia and hyperammonaemia and thyroid test demonstrated hypothyroidism (TSH 70 mUI/L and T4 0.6 ng/dL; normal range: 0.6–1.4 ng/dL). A Psychometric Hepatic Encephalopathy Score (PHES) was performed and showed a pathological performance with a score of 9 SD below the reference population (Table 1). MRI and MRS were performed using 1.5T equipment (Figure 1C–F). T1-weighted hyperintensity in basal ganglia (Figure 1C) and periventricular white matter high signals on FLAIR sequence were shown (Figure 1E).

A therapeutic decision of treating and resolving first hypothyroidism and re-evaluating the patient afterwards was based on three aspects: (1) time course (neurological impairment is coincident with the progression of thyroid disturbance); (2) lack of previous neurological impairment attributable to portosystemic shunt (completely asymptomatic over the past 4 year); and (3) although many symptoms of the patient could be attributable to either hypothyroidism or HE, some others (constipation and weight gain) were highly indicative of thyroid dysfunction that could potentially contribute to the clinical syndrome.

Table 1 Anthropometric, laboratory, neuropsychological and spectroscopic data of the patient at hospital admission and 1 year after discharge

	March 2015	May 2016
Anthropometric		
Weight in kg	75	72
BMI	28.2	27.7
Laboratory		
Hb in g/dL	12.7	15.3
MCV	103.8	98.8
Leucocytes as 10 ³ /μL	3.9	5.7
Platelets as 10 ³ /μL	120	165
INR	1.18	1.14
AST in U/L	33	31
ALT in U/L	41	34
GGT in U/L	145	165
AP in U/L	90	116
Albumin in g/dL	3.3	4.3
Bilirubin in mg/dL	1	1.3
Creatinine in mg/dL	0.59	0.5
Na in mmol/L	139	144
Child-Pugh	B (7)	A (6)
MELD	8	9
Ammonia in μmol/L	62	23
Thyroid function		
TSH in mIU/L	69.86	2.66
T4free in ng/dL	0.6	
PHES		
Symbol digit test as points	8	34
Number connection test A in s	78	25
Number connection test B in s	514	73
Serial dotting test in s	79	37
Line tracing test as seconds + errors	200	100
Final score	-9	1
Magnetic resonance spectroscopy		
Glx/Cr	1.884	0.439
Cho/Cr	0.934	1.204
mI/Cr	0.064	0.529

ALT: Alanine aminotransferase; AP: Alkaline phosphatase; AST: Aspartate aminotransferase; BMI: Body mass index; Cho/Cr: Choline/creatine; GGT: Gamma-glutamyl transferase; GLx/Cr: Glutamate-glutamine/creatine; Hb: Haemoglobin; INR: International normalized ratio; MCV: Mean corpuscular volume; MELD: Model for end-stage liver disease; mI/Cr: Myoinositol/creatine; T4free: free thyroxine; TSH: Thyroid-stimulating hormone.

Increasing levothyroxine dose resulted in steady clinical and laboratory improvements. At 1 wk later, the patient was discharged under levothyroxine 75 μg/d, rifaximin 600 mg/12 h, lactulose and carvedilol 6.25 mg/12 h leading to clinical improvement and restoration of thyroid function in the following 4 wk. She had no admission or decompensations during the next months, rifaximin was removed and lactulose was used occasionally.

The patient was re-evaluated 1 year later. She was completely asymptomatic, fully active, back to work without mental complaints, as reported by her and her relatives. She had stable liver disease (Table 1), normal thyroid function and venous ammonia levels. Her performance at PHES improved dramatically in all the tests, with a final score within the reference population. Similarly, an improvement in her EEG

was observed (Figure 1B). MRI showed no changes in the hyperintensity in basal ganglia on T1-weighted images (Figure 1D) but it showed an improvement in periventricular white matter hyperintensities on FLAIR images (Figure 1F). Single voxel proton MRS located in the right centrum semiovale (Table 1) showed a decrease in the glutamate-glutamine/creatine peak (Glx/Cr), together with an increase in the myoinositol/creatine (mI/Cr) and choline/creatine (Cho/Cr) peaks at short echo-time (23 ms).

We considered that currently there was no need for an intervention over the porto-systemic shunt. Her routine follow-up showed that she is clinically stable and asymptomatic under medical treatment (carvedilol 6.25 mg/12 h, levothyroxine 112 μg/d, sitagliptin 50 mg/d and lactulose occasionally).

DISCUSSION

Since hypothyroidism shares symptoms with HE, it is considered within the differential diagnosis of HE. However, there is scarce information on whether hypothyroidism may coexist and even precipitate HE and on how to attribute brain dysfunction to one or the other entity. The present report supports the role of hypothyroidism as a precipitating factor of HE by inducing hyperammonaemia and illustrates the difficulties in diagnosing HE when it coexists with other causes of brain dysfunction.

The lack of specific symptoms or laboratory tests that ensure the diagnosis of HE make therapeutic decisions sometimes difficult. A practical approach would be treating all the potential aetiologies of brain dysfunction, but this may not be the optimal strategy if it involves aggressive treatments with high risk of serious complications. Shunt embolization may be a good option in patients with HE secondary to portosystemic shunts, but such patients should be carefully selected since a rise in portal pressure with risk of variceal bleeding and ascites may occur.

The question, whether the neurological impairment was caused by the hypothyroidism or was attributable to the large portosystemic shunt, was very important to make further therapeutic decisions. Although both hypothyroidism and HE may present with mental slowness and memory impairment^[1], asterix and disorientation are more commonly observed in HE. Our patient's EEG pattern (slow activity and generalized triphasic waves) is characteristic of, although not specific for, HE^[2] and has seldom been reported in hypothyroidism^[3]. Furthermore, MRI depicted on T1-weighted images high signal in basal ganglia, which is frequently seen in patients with cirrhosis or portal-systemic shunts. Besides, FLAIR sequences showed high signal intensity in hemispheric white matter. This finding has been shown to improve after resolution of episodic HE or liver transplantation (LT) and has been attributed to mild brain oedema^[4]. All these findings

Table 2 Clinical cases of patients with hypothyroidism and hyperammonaemia reported in the literature

Year	Ref.	Clinical presentation	Thyroid disease	Liver disease	Evolution
1992	Hitoshi <i>et al</i> ^[6]	Mild dementia, slow speech, hyperreflexia, dysmetria, asterixis with hyperammonaemia. Progression to coma despite lactulose treatment.	Hypothalamic hypothyroidism	Cirrhosis and portal hypertension	Thyroid hormone replacement improved: Hypothyroidism Hyperammonaemia NRL disturbances
1999	De Nardo <i>et al</i> ^[7]	Hoarseness, fatigue, tongue swelling, myopathy. Hyperammonaemia.	Primary hypothyroidism	none	Thyroid hormone replacement improved: Hypothyroidism Hyperammonaemia Systemic symptoms and myopathy
2000	Thobe <i>et al</i> ^[8]	Coma, hyperammonaemia. Unresponsive to lactulose.	Primary hypothyroidism	Compensated cirrhosis	Thyroid hormone replacement improved: Hypothyroidism Hyperammonaemia NRL disturbances
2001	Yamamoto <i>et al</i> ^[9]	Dysarthria, disorientation.	Primary hypothyroidism	Decompensated cirrhosis	Thyroid hormone replacement improved: Hypothyroidism Hyperammonaemia NRL disturbances
2007	Rimar <i>et al</i> ^[10]	Coma, hyperammonaemia. Unresponsive to lactulose.	Primary hypothyroidism	Compensated cirrhosis	Thyroid hormone replacement improved: Hypothyroidism Hyperammonaemia NRL disturbances
2007	Khairy <i>et al</i> ^[11]	Grade III hepatic encephalopathy.	Primary hypothyroidism	Decompensated cirrhosis	Thyroid hormone replacement improved: Hypothyroidism NRL disturbances
2012	Redkar <i>et al</i> ^[12]	Coma, hyperammonaemia. Unresponsive to lactulose.	Primary hypothyroidism	Decompensated cirrhosis	Thyroid hormone replacement improved: Hypothyroidism Hyperammonaemia NRL disturbances

support the diagnosis of HE. However, the parallelism between the time course of the cognitive impairment and the hypothyroidism, the lack of response to hypoammonaemic measures, and the neurological improvement following normalization of thyroid function implies a relevant role for hypothyroidism.

Ammonia is thought to have an important role in HE. In normal conditions, ammonia is mainly generated in the gut, then is extracted in the liver and eliminated as urea by the kidney. In liver failure and/or in patients with portal-systemic shunts, ammonia reaches the systemic circulation and the central nervous system^[1]. Ammonia is metabolized to glutamine in astrocytes through the glutamine synthetase enzyme and both ammonia and glutamine exert their toxic effects on the brain. Muscle and kidney glutamine synthetase, together with kidney glutaminase, also regulate plasma ammonia levels and they are especially relevant in the context of liver failure. Patients with cirrhosis characteristically show an increase in Glx/Cr peak and a decrease of Cho/Cr and mI/Cr in MRS of the brain. Abnormalities in Glx/Cr have been interpreted as an increase in brain glutamine secondary to the ammonia

detoxification in astrocytes, whereas disturbances in Cho/Cr and mI/Cr have been interpreted as a compensatory response to the increased intracellular osmolality caused by glutamine accumulation. The severity of these disturbances has been associated with HE, and they are reversible following successful LT^[5].

A potential interaction between thyroid status and ammonia metabolism arose in our patient. Hyperammonaemia in patients with hypothyroidism has been seldom described over the last two decades, and only in sporadic cases reports^[6-12] (Table 2). Six out of seven of these patients (86%) are patients with liver cirrhosis. All those cirrhotic patients exhibited clinical manifestations suggestive of HE (grade I to IV), whereas the subject without liver disease had not. A common finding in all these cirrhotic patients with hypothyroidism was that neurological disturbances were refractory to hypoammonaemic therapy and improved with thyroid hormone replacement.

The mechanisms by which hypothyroidism may induce hyperammonaemia are not identified. In a rodent model, hypothyroidism was associated with increased urea cycle enzyme activity and decreased

glutamine synthetase in the liver^[13]. However, a decreased urea synthesis rate was found in women with hypothyroid^[14], suggesting a decrease in ammonia clearance *via* urea synthesis during hypothyroidism. We are not aware of data regarding a potential effect of thyroid hormone on muscle glutamine synthetase or gut glutaminase, which could also influence ammonia metabolism. A potential mechanism could involve thyroid hormone impact on glutamine synthetase activity not only in liver but also in muscle and kidney. A decrease in glutamine synthetase activity during hypothyroidism could contribute to hyperammonaemia that might revert with thyroid function restitution.

Hashimoto's encephalopathy, an autoimmune disease of the thyroid gland, may manifest as a wide range of neurological symptoms. It could lead to hypothyroidism and should be considered when evaluating patients with neurological disturbances refractory to standard therapy.

As in previous reports, our patient exhibited clinical manifestations suggestive of HE as well as hyperammonaemia refractory to hypoammonaemic measures, both of which reversed with thyroid hormone. Additionally, thyroid hormone replacement was also linked to an improvement in the periventricular white matter hyperintensities on FLAIR images and in MRS results, with a decreased in the Glx/Cr peak and an increase in the mI/Cr and Cho/Cr peaks. This novel observation supports that neurological disturbances were concomitant with hyperammonaemia and higher brain exposition to ammonia consistent with HE.

In conclusion, this clinical case shows that hypothyroidism is associated with hyperammonaemia and enhanced ammonia brain exposition. In agreement with the few cases previously reported, these data support that hypothyroidism may precipitate HE in cirrhotic patients by inducing hyperammonaemia and/or enhancing ammonia brain toxicity. Therefore, patients with cirrhosis and refractory HE should be evaluated for hypothyroidism, particularly if aggressive treatments are being considered.

ACKNOWLEDGMENTS

We acknowledge our gratitude to the patient who gave informed consent for this case report's publication. The authors are grateful to Dr. Javier Vaquero for his critical review of the manuscript and helpful advice.

COMMENTS

Case characteristics

A 58-year-old woman with cognitive impairment consistent with persistent hepatic encephalopathy (HE) and portosystemic shunt refractory to standard treatment was referred to our hospital.

Clinical diagnosis

Refractory cognitive impairment consistent with HE that paralleled the course of

post-ablative hypothyroidism.

Differential diagnosis

The main differential diagnosis was neurological disturbances secondary to hypothyroidism vs refractory HE secondary to portosystemic shunt. The clinical, laboratory, electroencephalograph (EEG) and magnetic resonance imaging findings, together with the clinical resolution following thyroid replacement, support the role of hypothyroidism as a precipitating event of HE.

Laboratory diagnosis

Laboratory tests demonstrated hypothyroidism, hyperammonaemia and alterations consistent with cirrhosis.

Imaging diagnosis

T1-weighted hyperintensities in basal ganglia and periventricular white matter high signals on FLAIR sequence, together with markers of brain ammonia exposition in magnetic resonance, supported the diagnosis of HE.

Treatment

The patient was refractory to standard HE treatment. Thyroid hormone replacement was associated with clinical resolution of the syndrome, together with normalization of plasma ammonia levels, neuropsychological performance, EEG and magnetic resonance markers of brain ammonia exposition.

Related reports

Very few case reports linked refractory neurological impairment in cirrhotic patients with hypothyroidism. This case shows an improvement in hyperammonaemia and brain ammonia exposition following thyroid hormone replacement, which was associated with clinical resolution of neurological impairment.

Term explanation

HE is a brain dysfunction that frequently affects patients with chronic liver failure. Its symptoms and signs are not specific and may be present in other causes of brain dysfunction.

Experiences and lessons

In cirrhotic patients, hypothyroidism may precipitate HE by enhancing ammonia brain toxicity.

Peer-review

This is an excellent case report describing an incidence whereby hypothyroidism was a precipitating factor that contributed to a recurrence of HE in a patient with liver cirrhosis. Overall, the report was very well written, with a clear description of the time line of events followed by a thorough discussion of the literature and known interactions between hypothyroidism and HE.

REFERENCES

- 1 **Vilstrup H**, Amodio P, Bajaj J, Cordoba J, Ferenci P, Mullen KD, Weissenborn K, Wong P. Hepatic encephalopathy in chronic liver disease: 2014 Practice Guideline by the American Association for the Study of Liver Diseases and the European Association for the Study of the Liver. *Hepatology* 2014; **60**: 715-735 [PMID: 25042402 DOI: 10.1002/hep.27210]
- 2 **Guerit JM**, Amantini A, Fischer C, Kaplan PW, Mecarelli O, Schnitzler A, Ubiali E, Amodio P; members of the ISHEN commission on Neurophysiological Investigations. Neurophysiological investigations of hepatic encephalopathy: ISHEN practice guidelines. *Liver Int* 2009; **29**: 789-796 [PMID: 19638107 DOI: 10.1111/j.1478-3231.2009.02030.x]
- 3 **River Y**, Zelig O. Triphasic waves in myxedema coma. *Clin Electroencephalogr* 1993; **24**: 146-150 [PMID: 8403447]
- 4 **Rovira A**, Alonso J, Córdoba J. MR imaging findings in hepatic encephalopathy. *AJNR Am J Neuroradiol* 2008; **29**: 1612-1621 [PMID: 18583413 DOI: 10.3174/ajnr.A1139]

- 5 **Garcia-Martínez R**, Cordoba J. Brain Imaging in Hepatic Encephalopathy. In: Mullen KD and Prakash RK, eds. Hepatic Encephalopathy. New York: Springer, 2012: 123-137 [DOI: 10.1007/978-1-61779-836-8_10]
- 6 **Hitoshi S**, Terao Y, Sakuta M. Portal-systemic encephalopathy and hypothalamic hypothyroidism: effect of thyroid hormone on ammonia metabolism. *Intern Med* 1993; **32**: 655-658 [PMID: 8312666]
- 7 **De Nardo D**, Franconi G, Sabino D. [Hyperammonemia during hypothyroidism: an unusual biohumoral finding normalized by hormonal replacement treatment]. *Ann Ital Med Int* 1999; **14**: 196-201 [PMID: 10566186]
- 8 **Thobe N**, Pilger P, Jones MP. Primary hypothyroidism masquerading as hepatic encephalopathy: case report and review of the literature. *Postgrad Med J* 2000; **76**: 424-426 [PMID: 10878207]
- 9 **Yamamoto T**, Takeuchi K, Okuda C, Nagashima N, Honjo H, Sakurai N, Yoshizaki H, Kuyama Y. Symptomatic hypothyroidism in decompensated liver cirrhosis. *J Clin Gastroenterol* 2001; **33**: 172-173 [PMID: 11468452]
- 10 **Rimar D**, Kruzel-Davila E, Dori G, Baron E, Bitterman H. Hyperammonemic coma-barking up the wrong tree. *J Gen Intern Med* 2007; **22**: 549-552 [PMID: 17372808 DOI: 10.1007/s11606-007-0131-6]
- 11 **Khairy RN**, Mullen KD. Hypothyroidism as a mimic of liver failure in a patient with cirrhosis. *Ann Intern Med* 2007; **146**: 315-316 [PMID: 17310062]
- 12 **Redkar N**, Bendle M, Maidapwad V, Chavan R, Shriwastav R. Hepatic encephalopathy masking myxedema coma. *J Assoc Physicians India* 2012; **60**: 70-71 [PMID: 23547421]
- 13 **Marti J**, Portoles M, Jimenez-Nacher I, Cabo J, Jorda A. Effect of thyroid hormones on urea biosynthesis and related processes in rat liver. *Endocrinology* 1988; **123**: 2167-2174 [PMID: 2844505 DOI: 10.1210/endo-123-5-2167]
- 14 **Marchesini G**, Fabbri A, Bianchi GP, Motta E, Bugianesi E, Urbini D, Pascoli A, Lodi A. Hepatic conversion of amino nitrogen to urea nitrogen in hypothyroid patients and upon L-thyroxine therapy. *Metabolism* 1993; **42**: 1263-1269 [PMID: 8412738]

P- Reviewer: DeMorrow S, Moini M, Olesen SS, Schwabl P
S- Editor: Gong ZM **L- Editor:** Filipodia **E- Editor:** Zhang FF





Published by **Baishideng Publishing Group Inc**
7901 Stoneridge Drive, Suite 501, Pleasanton, CA 94588, USA
Telephone: +1-925-223-8242
Fax: +1-925-223-8243
E-mail: bpgoffice@wjgnet.com
Help Desk: <http://www.f6publishing.com/helpdesk>
<http://www.wjgnet.com>



ISSN 1007-9327



9 771007 932045