

# World Journal of *Gastroenterology*

*World J Gastroenterol* 2017 September 7; 23(33): 6009-6196



**EDITORIAL**

- 6009** Helminths as an alternative therapy for intestinal diseases

*Sipahi AM, Baptista DM*

**REVIEW**

- 6016** Dextran sodium sulfate colitis murine model: An indispensable tool for advancing our understanding of inflammatory bowel diseases pathogenesis

*Eichele DD, Kharbanda KK*

- 6030** Autoimmune hepatitis: Standard treatment and systematic review of alternative treatments

*Terziroli Beretta-Piccoli B, Mieli-Vergani G, Vergani D*

**MINIREVIEWS**

- 6049** Colorectal cancer, screening and primary care: A mini literature review

*Hadjipetrou A, Anyfantakis D, Galanakis CG, Kastanakis M, Kastanakis S*

- 6059** Behavioral gastroenterology: An emerging system and new frontier of action

*Jia L, Jiang SM, Liu J*

**ORIGINAL ARTICLE****Basic Study**

- 6065** Pharmacological evaluation of NSAID-induced gastropathy as a "Translatable" model of referred visceral hypersensitivity

*Hummel M, Knappenberger T, Reilly M, Whiteside GT*

- 6077** High yield reproducible rat model recapitulating human Barrett's carcinogenesis

*Matsui D, Omstead AN, Kosovec JE, Komatsu Y, Lloyd EJ, Raphael H, Kelly RJ, Zaidi AH, Jobe BA*

- 6088** Changes in expression of inhibitory substances in the intramural neurons of the stomach following streptozotocin- induced diabetes in the pig

*Bulc M, Palus K, Zielonka L, Gajęcka M, Calka J*

- 6100** HOX transcript antisense intergenic RNA represses E-cadherin expression by binding to EZH2 in gastric cancer

*Chen WM, Chen WD, Jiang XM, Jia XF, Wang HM, Zhang QJ, Shu YQ, Zhao HB*

- 6111  $\text{Ca}^{2+}$ /calmodulin-dependent protein kinase II regulates colon cancer proliferation and migration *via* ERK1/2 and p38 pathways

*Chen W, An P, Quan XJ, Zhang J, Zhou ZY, Zou LP, Luo HS*

- 6119 Aberrant DNA-PKcs and ERGIC1 expression may be involved in initiation of gastric cancer

*Wang FR, Wei YC, Han ZJ, He WT, Guan XY, Chen H, Li YM*

#### Retrospective Cohort Study

- 6128 Real world treatment patterns of gastrointestinal neuroendocrine tumors: A claims database analysis

*Benson III AB, Broder MS, Cai B, Chang E, Neary MP, Papayan E*

#### Retrospective Study

- 6137 Patients with inflammatory bowel disease have increased risk of autoimmune and inflammatory diseases

*Halling ML, Kjeldsen J, Knudsen T, Nielsen J, Koch-Hansen L*

- 6147 Suspicious brush cytology is an indication for liver transplantation evaluation in primary sclerosing cholangitis

*Boyd S, Vannas M, Jokelainen K, Isoniemi H, Mäkisalo H, Färkkilä MA, Arola J*

- 6155 Management of gastric mucosa-associated lymphoid tissue lymphoma in patients with extra copies of the *MALT1* gene

*Iwamuro M, Takenaka R, Nakagawa M, Moritou Y, Saito S, Hori S, Inaba T, Kawai Y, Toyokawa T, Tanaka T, Yoshino T, Okada H*

- 6164 Ketogenic diet poses a significant effect on imbalanced gut microbiota in infants with refractory epilepsy

*Xie G, Zhou Q, Qiu CZ, Dai WK, Wang HP, Li YH, Liao JX, Lu XG, Lin SF, Ye JH, Ma ZY, Wang WJ*

#### Observational Study

- 6172 Definition of colorectal anastomotic leakage: A consensus survey among Dutch and Chinese colorectal surgeons

*van Rooijen SJ, Jongen ACHM, Wu ZQ, Ji JF, Slooter GD, Roumen RMH, Bouvy ND*

#### CASE REPORT

- 6181 How to treat intestinal obstruction due to malignant recurrence after Whipple's resection for pancreatic head cancer: Description of 2 new endoscopic techniques

*Mouradides C, Taha A, Borbath I, Deprez PH, Moreels TG*

- 6187 Arteriportal shunt incidental to treatment with oxaliplatin that mimics recurrent gastric cancer

*Kim HB, Park SG*

**LETTERS TO THE EDITOR**

- 6194** Comment on "Effect of biofilm formation by clinical isolates of *Helicobacter pylori* on the efflux-mediated resistance to commonly used antibiotics"

*Kazakos EI, Dorrell N, Polyzos SA, Deretzi G, Kountouras J*

## ABOUT COVER

Editorial Board Member of World Journal of Gastroenterology, Mostafa Sira, MD, Associate Professor of Pediatric Hepatology, Gastroenterology and Nutrition, National Liver Institute, Menofiya University, Menofiya 32511, Egypt

## AIMS AND SCOPE

*World Journal of Gastroenterology* (*World J Gastroenterol*, *WJG*, print ISSN 1007-9327, online ISSN 2219-2840, DOI: 10.3748) is a peer-reviewed open access journal. *WJG* was established on October 1, 1995. It is published weekly on the 7<sup>th</sup>, 14<sup>th</sup>, 21<sup>st</sup>, and 28<sup>th</sup> each month. The *WJG* Editorial Board consists of 1375 experts in gastroenterology and hepatology from 68 countries.

The primary task of *WJG* is to rapidly publish high-quality original articles, reviews, and commentaries in the fields of gastroenterology, hepatology, gastrointestinal endoscopy, gastrointestinal surgery, hepatobiliary surgery, gastrointestinal oncology, gastrointestinal radiation oncology, gastrointestinal imaging, gastrointestinal interventional therapy, gastrointestinal infectious diseases, gastrointestinal pharmacology, gastrointestinal pathophysiology, gastrointestinal pathology, evidence-based medicine in gastroenterology, pancreatology, gastrointestinal laboratory medicine, gastrointestinal molecular biology, gastrointestinal immunology, gastrointestinal microbiology, gastrointestinal genetics, gastrointestinal translational medicine, gastrointestinal diagnostics, and gastrointestinal therapeutics. *WJG* is dedicated to become an influential and prestigious journal in gastroenterology and hepatology, to promote the development of above disciplines, and to improve the diagnostic and therapeutic skill and expertise of clinicians.

## INDEXING/ABSTRACTING

*World Journal of Gastroenterology* (*WJG*) is now indexed in Current Contents<sup>®</sup>/Clinical Medicine, Science Citation Index Expanded (also known as SciSearch<sup>®</sup>), Journal Citation Reports<sup>®</sup>, Index Medicus, MEDLINE, PubMed, PubMed Central and Directory of Open Access Journals. The 2017 edition of Journal Citation Reports<sup>®</sup> cites the 2016 impact factor for *WJG* as 3.365 (5-year impact factor: 3.176), ranking *WJG* as 29<sup>th</sup> among 79 journals in gastroenterology and hepatology (quartile in category Q2).

## FLYLEAF

## I-IX Editorial Board

## EDITORS FOR THIS ISSUE

Responsible Assistant Editor: *Xiang Li*  
Responsible Electronic Editor: *Yan Huang*  
Proofing Editor-in-Chief: *Lian-Sheng Ma*

Responsible Science Editor: *Li-Juan Wei*  
Proofing Editorial Office Director: *Jin-Lei Wang*

NAME OF JOURNAL  
*World Journal of Gastroenterology*

ISSN  
ISSN 1007-9327 (print)  
ISSN 2219-2840 (online)

LAUNCH DATE  
October 1, 1995

FREQUENCY  
Weekly

### EDITORS-IN-CHIEF

**Damian Garcia-Olmo, MD, PhD, Doctor, Professor, Surgeon**, Department of Surgery, Universidad Autonoma de Madrid; Department of General Surgery, Fundacion Jimenez Diaz University Hospital, Madrid 28040, Spain

**Stephen C Strom, PhD, Professor**, Department of Laboratory Medicine, Division of Pathology, Karolinska Institutet, Stockholm 141-86, Sweden

**Andrzej S Tarnawski, MD, PhD, DSc (Med), Professor of Medicine, Chief Gastroenterology**, VA Long Beach Health Care System, University of California, Irvine, CA, 5901 E. Seventh Str., Long Beach,

CA 90822, United States

### EDITORIAL BOARD MEMBERS

All editorial board members resources online at <http://www.wjgnet.com/1007-9327/editorialboard.htm>

### EDITORIAL OFFICE

Jin-Lei Wang, Director  
Yuan Qi, Vice Director  
Ze-Mao Gong, Vice Director  
*World Journal of Gastroenterology*  
Baishideng Publishing Group Inc  
7901 Stoneridge Drive, Suite 501,  
Pleasanton, CA 94588, USA  
Telephone: +1-925-2238242  
Fax: +1-925-2238243  
E-mail: [editorialoffice@wjgnet.com](mailto:editorialoffice@wjgnet.com)  
Help Desk: <http://www.f6publishing.com/helpdesk>  
<http://www.wjgnet.com>

### PUBLISHER

Baishideng Publishing Group Inc  
7901 Stoneridge Drive, Suite 501,  
Pleasanton, CA 94588, USA  
Telephone: +1-925-2238242  
Fax: +1-925-2238243  
E-mail: [bpgoffice@wjgnet.com](mailto:bpgoffice@wjgnet.com)  
Help Desk: <http://www.f6publishing.com/helpdesk>

<http://www.wjgnet.com>

PUBLICATION DATE  
September 7, 2017

### COPYRIGHT

© 2017 Baishideng Publishing Group Inc. Articles published by this Open-Access journal are distributed under the terms of the Creative Commons Attribution Non-commercial License, which permits use, distribution, and reproduction in any medium, provided the original work is properly cited, the use is non commercial and is otherwise in compliance with the license.

### SPECIAL STATEMENT

All articles published in journals owned by the Baishideng Publishing Group (BPG) represent the views and opinions of their authors, and not the views, opinions or policies of the BPG, except where otherwise explicitly indicated.

### INSTRUCTIONS TO AUTHORS

Full instructions are available online at <http://www.wjgnet.com/bpg/gerinfo/204>

ONLINE SUBMISSION  
<http://www.f6publishing.com>

## Retrospective Study

# Management of gastric mucosa-associated lymphoid tissue lymphoma in patients with extra copies of the *MALT1* gene

Masaya Iwamuro, Ryuta Takenaka, Masahiro Nakagawa, Yuki Moritou, Shunsuke Saito, Shinichiro Hori, Tomoki Inaba, Yoshinari Kawai, Tatsuya Toyokawa, Takehiro Tanaka, Tadashi Yoshino, Hiroyuki Okada

Masaya Iwamuro, Hiroyuki Okada, Department of Gastroenterology and Hepatology, Okayama University Graduate School of Medicine, Dentistry, and Pharmaceutical Sciences, Okayama 700-8558, Japan

Ryuta Takenaka, Department of Internal Medicine, Tsuyama Chuo Hospital, Tsuyama 708-0841, Japan

Masahiro Nakagawa, Department of Internal Medicine, Hiroshima City Hospital, Hiroshima 730-8518, Japan

Yuki Moritou, Department of Gastroenterology, Mitoyo General Hospital, Kanonji 769-1695, Japan

Shunsuke Saito, Department of Internal Medicine, Okayama Saiseikai General Hospital, Okayama 700-8511, Japan

Shinichiro Hori, Department of Gastroenterology, Shikoku Cancer Center, Matsuyama 791-0280, Japan

Tomoki Inaba, Department of Gastroenterology, Kagawa Prefectural Central Hospital, Takamatsu 760-8557, Japan

Yoshinari Kawai, Department of Gastroenterology, Onomichi Municipal Hospital, Onomichi 722-8503, Japan

Tatsuya Toyokawa, Department of Gastroenterology, Fukuyama Medical Center, Fukuyama 720-8520, Japan

Takehiro Tanaka, Department of Pathology, Okayama University Hospital, Okayama 700-8558, Japan

Tadashi Yoshino, Department of Pathology, Okayama University Graduate School of Medicine, Dentistry, and Pharmaceutical Sciences, Okayama 700-8558, Japan

**ORCID Number:** Masaya Iwamuro (0000-0002-1757-5754); Ryuta Takenaka (0000-0001-7632-1474); Masahiro Nakagawa (0000-0002-6144-3716); Yuki Moritou (0000-0002-4542-446X); Shunsuke Saito (0000-0001-6184-9946); Shinichiro Hori (0000-0002-9393-4413); Tomoki Inaba (0000-0003-0936-5834); Yoshinari Kawai (0000-0001-7893-0855); Tatsuya Toyokawa (0000-0002-8658-5892); Takehiro Tanaka (0000-0002-1509-5706); Tadashi Yoshino (0000-0003-2533-4210); Hiroyuki Okada

(0000-0003-2814-7146).

**Author contributions:** Iwamuro M organized the report and drafted the article; Takenaka R, Nakagawa M, Moritou Y, Saito S, Hori S, Inaba T, Kawai Y and Toyokawa T collected the data; Tanaka T and Yoshino T critically revised the article for important intellectual content; Okada H approved the final article.

**Institutional review board statement:** This study was reviewed and approved by the Ethical Committee of the Okayama University Hospital, Okayama, Japan.

**Informed consent statement:** This study is a retrospective study using medical records, and personal information protection measures are appropriately established so that the informed consent of the subject can be exempted.

**Conflict-of-interest statement:** All of the authors declare that they have no conflicts of interest associated with this article.

**Data sharing statement:** No additional data are available.

**Open-Access:** This article is an open-access article which was selected by an in-house editor and fully peer-reviewed by external reviewers. It is distributed in accordance with the Creative Commons Attribution Non Commercial (CC BY-NC 4.0) license, which permits others to distribute, remix, adapt, build upon this work non-commercially, and license their derivative works on different terms, provided the original work is properly cited and the use is non-commercial. See: <http://creativecommons.org/licenses/by-nc/4.0/>

**Manuscript source:** Invited manuscript

**Correspondence to:** Masaya Iwamuro, MD, PhD, Department of Gastroenterology and Hepatology, Okayama University Graduate School of Medicine, Dentistry, and Pharmaceutical Sciences, 2-5-1 Shikata-cho, Kita-Ku, Okayama 700-8558, Japan. [pr145h2k@okayama-u.ac.jp](mailto:pr145h2k@okayama-u.ac.jp)  
Telephone: +81-86-2357219  
Fax: +81-86-2255991

**Received:** May 22, 2017  
**Peer-review started:** May 22, 2017

First decision: June 22, 2017

Revised: July 21, 2017

Accepted: August 8, 2017

Article in press: August 8, 2017

Published online: September 7, 2017

## Abstract

### AIM

To identify the clinical features of gastric mucosa-associated lymphoid tissue (MALT) lymphoma with extra copies of *MALT1*.

### METHODS

This is a multi-centered, retrospective study. We reviewed 146 patients with MALT lymphoma in the stomach who underwent fluorescence *in situ* hybridization analysis for t(11;18) translocation. Patients were subdivided into patients without t(11;18) translocation or extra copies of *MALT1* (Group A, *n* = 88), patients with t(11;18) translocation (Group B, *n* = 27), and patients with extra copies of *MALT1* (Group C, *n* = 31). The clinical background, treatment, and outcomes of each group were investigated.

### RESULTS

Groups A and C showed slight female predominance, whereas Group B showed slight male predominance. Mean ages and clinical stages at lymphoma diagnosis were not different between groups. Complete response was obtained in 61 patients in Group A (69.3%), 22 in Group B (81.5%), and 21 in Group C (67.7%). *Helicobacter pylori* (*H. pylori*) eradication alone resulted in complete remission in 44 patients in Group A and 13 in Group C. In Group B, 14 patients underwent radiotherapy alone, which resulted in lymphoma disappearance. Although the difference was not statistically significant, event-free survival in Group C tended to be inferior to that in Group A (*P* = 0.10).

### CONCLUSION

Patients with t(11;18) translocation should be treated differently from others. Patients with extra copies of *MALT1* could be initially treated with *H. pylori* eradication, similar to patients without t(11;18) translocation or extra copies of *MALT1*.

**Key words:** Extranodal marginal zone lymphoma of mucosa-associated lymphoid tissue; Gastric neoplasms; Esophagogastroduodenoscopy; t(11;18) translocation; Trisomy 18

© The Author(s) 2017. Published by Baishideng Publishing Group Inc. All rights reserved.

**Core tip:** We subdivided and retrospectively reviewed 146 patients with gastric MALT lymphoma into patients without t(11;18) translocation or extra copies of *MALT1* (Group A, *n* = 88, 60.3%), patients with t(11;18)

translocation (Group B, *n* = 27, 18.5%), and patients with extra copies of *MALT1* (Group C, *n* = 31, 21.2%). Groups A and C exhibited similar clinical characteristics. *Helicobacter pylori* eradication alone resulted in complete remission in approximately half the patients in Group A and Group C. Consequently, patients with extra copies of *MALT1* could be treated similar to patients without t(11;18) translocation or extra copies of *MALT1*.

Iwamuro M, Takenaka R, Nakagawa M, Moritou Y, Saito S, Hori S, Inaba T, Kawai Y, Toyokawa T, Tanaka T, Yoshino T, Okada H. Management of gastric mucosa-associated lymphoid tissue lymphoma in patients with extra copies of the *MALT1* gene. *World J Gastroenterol* 2017; 23(33): 6155-6163 Available from: URL: <http://www.wjgnet.com/1007-9327/full/v23/i33/6155.htm> DOI: <http://dx.doi.org/10.3748/wjg.v23.i33.6155>

## INTRODUCTION

Extranodal marginal zone lymphoma of mucosa-associated lymphoid tissue (MALT lymphoma) is one of the non-Hodgkin lymphomas, originating in tissues or organs outside of the lymph nodes. Typically, this neoplasm involves the gastrointestinal tract, thyroid, ocular adnexa, lungs, salivary glands, liver, and skin<sup>[1,2]</sup>. Of these organs, the stomach is the most frequently identified primary site. Approximately two-thirds of patients with gastric MALT lymphoma have chronic *Helicobacter pylori* (*H. pylori*) infection in the stomach, which is believed to be the causative organism. Clinically, eradication of *H. pylori* is the first-line management of choice, resulting in regression of lymphoma in 75% to 80% of patients<sup>[3]</sup>. Meanwhile, cases with chromosomal abnormalities of t(11;18)(q21;q21)/*API2-MALT1* translocation have been shown to be resistant to *H. pylori* eradication. Consequently, evaluation of t(11;18)(q21;q21) translocation at the initial workup is valuable to forecast the response to antibiotic therapy against *H. pylori*<sup>[4]</sup>.

Previously, we reported a case of gastric MALT lymphoma with trisomy 18<sup>[5]</sup>. In that case, although there were no fusion genes of *API2-MALT1*, trisomy 18 was identified as extra copies of *MALT1*, using a fluorescence *in situ* hybridization (FISH) analysis for t(11;18)(q21;q21)/*API2-MALT1* translocation, since *MALT1* is located on chromosome 18q21. The patient required radiation therapy to treat the gastric lymphoma lesions, because the gastric lesions only partially improved after eradication therapy for *H. pylori*. Though radiation therapy resulted in complete remission, MALT lymphoma recurred in the stomach 16 mo later. Previous studies investigating chromosome aneuploidy in MALT lymphomas also reported that trisomy 18 might be indicative of progression or relapse in patients with gastric MALT

lymphoma<sup>[6-8]</sup>. Based on our experience and previous reports, we hypothesized that gastric MALT lymphoma with extra copies of the *MALT1* gene may be resistant to *H. pylori* eradication and may show more frequent progression or relapse than those without chromosomal aberrations. However, no studies have described the initial treatment and response in such patients. The purpose of this study is to reveal the clinical characteristics and outcomes of gastric MALT lymphoma in patients with t(11;18)(q21;q21)/*API2-MALT1* translocation or extra copies of *MALT1*, in order to determine initial treatment strategies for cases presenting with chromosomal aneuploidy.

## MATERIALS AND METHODS

Letters of inquiry regarding patients with gastric MALT lymphoma were sent from the Department of Gastroenterology and Hepatology, Okayama University Graduate School of Medicine, Dentistry and Pharmaceutical Sciences, to ten collaborating institutions. The inclusion criteria were: (1) patients with pathologically diagnosed MALT lymphoma in the stomach, and (2) patients who underwent fluorescence *in situ* hybridization analysis for t(11;18)(q21;q21)/*API2-MALT1* translocation on biopsy samples from the gastric MALT lymphoma lesions. FISH analysis was performed for all patients on fresh biopsy samples using dual-color, dual-fusion translocation probes for *API2/MALT1*. MALT lymphoma with a large-cell component was excluded from this study. Finally, a total of 146 patients diagnosed with gastric MALT lymphoma between October 1997 and November 2015 were identified. Thus, these patients were retrospectively registered in this study.

According to the FISH result for t(11;18) translocation, patients were subdivided into three groups as follows: (1) Group A: patients without t(11;18)(q21;q21)/*API2-MALT1* translocation or extra copies of *MALT1* (Figure 1A), (2) Group B: patients with t(11;18) translocation (Figure 1B), and (3) Group C: patients with extra copies of *MALT1* (Figure 1C). To determine the patient characteristics of gastric MALT lymphoma with or without chromosomal aberrations, we retrospectively examined the gender, age at diagnosis, endoscopic features, clinical stages according to Lugano classification<sup>[9]</sup>, *H. pylori* infection status, treatments, response to treatments, and outcomes. *H. pylori* infection status was examined by urea breath tests, rapid urease tests, microscopic observations or culture tests on endoscopically biopsied specimens, stool antigen tests, serum or urine antibody tests, or a combination of these methods. Success of *H. pylori* eradication was confirmed by urea breath tests, rapid urease tests, microscopic observations or culture tests on endoscopically biopsied specimens, or stool antigen tests. The follow-up period was defined as the period from the lymphoma diagnosis to death from any cause or to the patient's last hospital visit.

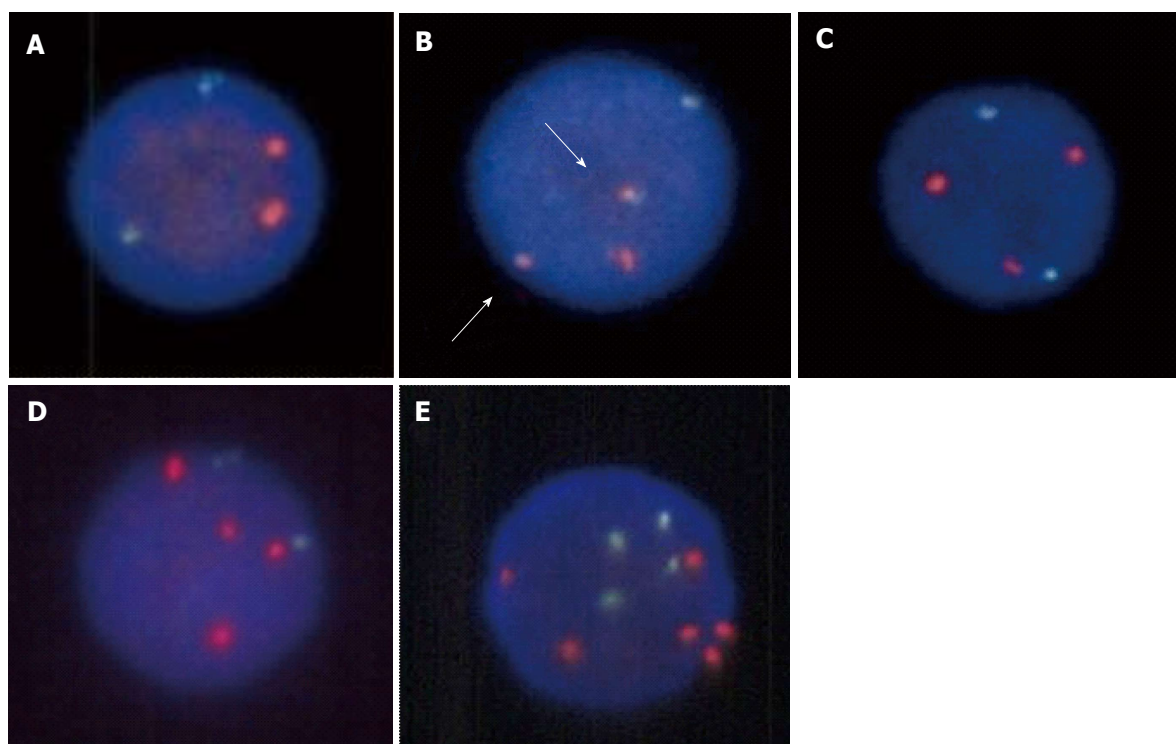
Macroscopic features of gastric lymphoma lesions observed during esophagogastroduodenoscopy were classified into the following six subtypes<sup>[10]</sup>: (1) erosions/ulcers; (2) early gastric cancer-like lesion that formed a slightly depressed area; (3) whitish mucosa; (4) cobblestone appearance; (5) submucosal tumor-like lesion; and (6) mixed (a combination of these five subtypes). All cases were reviewed and their subtypes were classified by board certified endoscopists.

Event-free survival was measured from diagnosis until documented progression/relapse, death from primary disease, or commencement of the second treatment for any reason. For the comparisons of the two groups, statistical analyses including *t*-tests,  $\chi^2$  tests, and *F*-tests were performed using JMP 8.0.1 software (SAS Institute, Cary, NC, United States). Cumulative event-free probabilities were calculated by Kaplan-Meier analysis and log-rank tests were performed using the JMP 8.0.1 software. *P* < 0.05 was considered to indicate a statistically significant difference. The present study was approved by the Ethical Committee of the Okayama University Hospital and adhered to the Declaration of Helsinki.

## RESULTS

In this study, clinical data of 146 patients (76 women and 70 men) were collected from nine institutions (Table 1). FISH analysis for t(11;18)(q21;q21)/*API2-MALT1* revealed that t(11;18) translocation and extra copies of *MALT1* were not identified in 88 patients (Figure 1A). Fusion genes of *API2-MALT1* indicating t(11;18)(q21;q21)/*API2-MALT1* translocation were detected in 27 patients (10 women and 17 men) (Figure 1B). Extra copies of *MALT1* were found in 31 patients; the ratio of *MALT1* signals to *API2* signals was 3:2 in 28 patients, suggesting trisomy 18 (Figure 1C), and 4:2 in one patient, suggesting tetrasomy 18, (Figure 1D). The remaining two patients had a combination of lymphoma cells with either trisomy 18 or tetrasomy 18. In one patient with extra copies of *MALT1*, several lymphoma cells had six *MALT1* signals with four *API2* signals, which is considered as trisomy 18 with tetraploidy (Figure 1E).

Patients without t(11;18) translocation or extra copies of *MALT1* (Group A) showed slight female predominance (48 women and 40 men), while patients with t(11;18)(q21;q21) translocation (Group B) showed slight male predominance (10 women and 17 men). However, there was no statistically significant difference between Groups A and B regarding sex ratio (*P* = 0.11). Patients with extra copies of *MALT1* (Group C) showed slight female predominance (18 females and 13 males) compared to Group A (*P* = 0.73). The mean ages at lymphoma diagnosis was 65.9 ± 12.3 years in Group A, 64.2 ± 11.2 years in Group B, and 65.0 ± 14.9 years in Group C and was not different between groups. Lymphoma lesions were localized in the stomach without lymph node or other organ



**Figure 1 FISH images of the lymphoma cells.** In the FISH analysis for t(11;18)(q21; q21) translocation, *API2* is visualized as a green signal and *MALT1* as a red signal. A: Two green signals and two red signals are seen in cases without t(11;18) translocation or extra copies of *MALT1*. B: Fusion genes of *API2-MALT1* are detected as yellow signals, indicating t(11;18) translocation (B, arrows). C: Although no fusion genes are visible, an extra copy of *MALT1* is noted, indicating trisomy 18. D: Two extra copies of *MALT1* are visible, indicating tetrasomy 18. E: In one patient, several lymphoma cells have six *MALT1* signals with four *API2* signals, which is considered as trisomy 18 with tetraploidy.

**Table 1 Clinical backgrounds of the study subjects *n* (%)**

	Total	Group A: No chromosome aberration <sup>1</sup>	Group B: t(11;18) positive	Group C: Extra copies of <i>MALT1</i>	Group A vs B, <i>p</i> value	Group A vs C, <i>p</i> value
<i>n</i>	146	88	27	31		
Sex						
Male	70 (47.9)	40 (45.5)	17 (63.0)	13 (41.9)	0.11	0.73
Female	76 (52.1)	48 (54.5)	10 (37.0)	18 (58.1)		
Age (mean ± SD, yr)	65.4 ± 12.6	65.9 ± 12.3	64.2 ± 11.2	65.0 ± 14.9	0.53	0.75
Stage (Lugano system)						
I	131	81	24	26	0.92 <sup>2</sup>	0.29 <sup>2</sup>
II 1	3	1	1	1		
II 2	1	1	0	0		
IV	11	5	2	4		
<i>H. pylori</i>						
Positive	89 (61.0)	66 (75.0)	2 (7.4)	21 (67.7)	< 0.01	0.439
Negative	57 (39.0)	22 (25.0)	25 (92.6)	10 (32.3)		

<sup>1</sup>Patients without t(11;18) translocation or extra copies of *MALT1*; <sup>2</sup>stage I and II 1 vs II 2 and IV.

involvement in most of the patients (131/146, 89.7%), thus they were classified as stage I according to the Lugano system of staging<sup>[10]</sup>. *H. pylori* infection status was examined in all patients. In Group A, 75.0% of the patients were positive for *H. pylori*. Group C had similar positivity for *H. pylori* (67.7%). In contrast, only 7.4% of the patients in Group B had *H. pylori* infection ( $P < 0.01$ , vs Group A). Endoscopic features are summarized in Table 2. Overall, gross findings of the gastric lymphoma lesions were as follows: erosions/ulcers in 44 patients (30.1%), whitish mucosa

in 42 patients (28.8%), submucosal tumor-like lesions in 29 patients (19.9%), cobblestone appearance in 17 patients (11.6%), early gastric cancer-like lesions in 10 patients (6.8%), and mixed lesions in four patients (2.7%). The ratio of each macroscopic morphology was similar between Groups A and C. Moreover, no patients in Group B presented with submucosal tumor-like lesions.

Treatments and outcomes are shown in Table 3. Follow-up periods were  $3.9 \pm 3.1$  years in Group A,  $5.1 \pm 4.5$  years in Group B, and  $2.9 \pm 2.2$  years in

**Table 2** Endoscopic features of the gastric lesions *n* (%)

	Total	Group A: No chromosome aberration <sup>1</sup>	Group B: t(11;18) positive	Group C: Extra copies of <i>MALT1</i>
Macroscopic feature				
Erosions/ulcers	44 (30.1)	23 (26.1)	9 (33.3)	12 (38.7)
Early gastric cancer-like	10 (6.8)	7 (8.0)	2 (7.4)	1 (3.2)
Whitish mucosa	42 (28.8)	25 (28.4)	12 (44.4)	5 (16.1)
Cobblestone appearance	17 (11.6)	12 (13.6)	3 (11.1)	2 (6.5)
Submucosal tumor	29 (19.9)	19 (21.6)	0	10 (32.3)
Mixed	4 (2.7)	2 (2.3)	1 (3.7)	1 (3.2)

<sup>1</sup>Patients without t(11;18) translocation or extra copies of *MALT1*.**Table 3** Treatment regimens and outcomes of the study subjects

	Total	Group A: No chromosome aberration <sup>1</sup>	Group B: t(11;18) positive	Group C: Extra copies of <i>MALT1</i>
Treatment				
Eradication alone	85	62	3	20
RT alone	23	8	15	0
Chemotherapy alone	8	3	2	3
RT and chemotherapy	2	1	0	1
Eradication RT	17	6	5	6
Eradication and chemotherapy	3	2	0	1
Eradication and RT and chemotherapy	2	1	1	0
None	6	5	1	0
Outcome				
Live without disease	103	61	21	21
Live with disease	33	20	5	8
Live, unknown disease status	6	5	1	0
Dead by other cause	3	1	0	2
Dead by MALT lymphoma	1	1	0	0
Follow-up period (mean $\pm$ SD, yr)	3.9 $\pm$ 3.3	3.9 $\pm$ 3.1	5.1 $\pm$ 4.5	2.9 $\pm$ 2.2

<sup>1</sup>Patients without t(11;18) translocation or extra copies of *MALT1*. RT: Radiotherapy; MALT: Mucosa-associated lymphoid tissue.

Group C. Only four patients died during the follow-up period: One patient in Group A died 2.4 years after lymphoma diagnosis because of concomitant advanced lung cancer, although complete response was obtained for gastric MALT lymphoma after *H. pylori* eradication. Two patients in Group C died of pneumonia 1.1 years and 2.0 years after lymphoma diagnosis, respectively. The other patient in Group A had stage IV lymphoma involving the stomach, ileum, colon, rectum, and lymphadenopathies of the neck, supraclavicular, subphrenic, and retroperitoneum. The patient underwent chemotherapy with cyclophosphamide, vincristine sulfate, and prednisone, followed by rituximab monotherapy and yttrium-90 ibritumomab tiuxetan monotherapy. However, the patient died of refractory lymphoma 1.4 years after

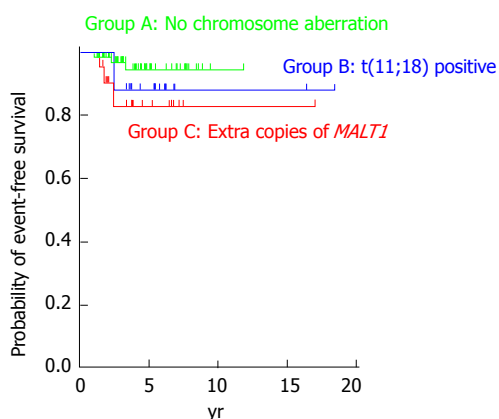
**Table 4** Treatment regimens resulted in complete remission

	Total	Group A: No chromosome aberration <sup>1</sup>	Group B: t(11;18) positive	Group C: Extra copies of <i>MALT1</i>
<i>n</i>	103	61	21	21
Treatment				
Eradication alone	58	44	1	13
RT alone	20	6	14	0
Chemotherapy alone	4	1	1	2
RT and chemotherapy	2	1	0	1
Eradication and RT	13	5	4	4
Eradication and chemotherapy	3	2	0	1
Eradication, RT and chemotherapy	1	0	1	0
None	2	2	0	0

<sup>1</sup>Patients without t(11;18) translocation or extra copies of *MALT1*. RT: Radiotherapy; MALT: Mucosa-associated lymphoid tissue.

the initial diagnosis due to intestinal perforation. Since pathological analysis was waived because of the patient's deteriorated condition, it was unknown whether histologic transformation occurred in the terminal stage. All patients, except for the four mortality cases, were alive at the patient's last visit to each institution. Five patients in Group A and one in Group B did not undergo esophagogastroduodenoscopy during the follow-up period, thus their lymphoma status, whether remitted or unchanged, was unknown. Complete response was obtained in 61 patients in Group A (69.3%), 22 in Group B (81.5%), and 21 in Group C (67.7%). On the other hand, lymphoma lesions were partially remitted or unchanged in 20 patients in Group A (22.7%), four in Group B (14.8%), and eight in Group C (25.8%).

With regard to treatment regimens, most of the patients without t(11;18) translocation or extra copies of *MALT1* (Group A) were treated with *H. pylori* eradication alone (*n* = 62, 70.5%). More than half of the patients with t(11;18)(q21;q21) translocation (Group B) were treated with radiotherapy alone (*n* = 15, 55.6%). Approximately two-thirds of the patients with extra copies of *MALT1* (Group C) were treated with *H. pylori* eradication alone (*n* = 20, 64.5%). Table 4 shows treatment regimens that resulted in complete remission of MALT lymphoma lesions. Complete remission of lymphoma was observed in



**Figure 2 Cumulative event-free probabilities for the three groups.** Although event-free survival of Group C patients appears to be inferior to that of the patients of the other two Groups, log-rank test revealed that the difference between Groups A and C was not statistically significant ( $P = 0.10$ ).

44 (72.1%) and 13 (61.9%) patients in Groups A and C, respectively, by *H. pylori* eradication alone. In contrast, only one (4.5%) patient achieved complete remission after *H. pylori* eradication alone, whereas 14 (63.6%) patients achieved complete remission after radiotherapy alone in Group B. Figure 2 shows cumulative event-free probabilities between the three groups. Although event-free survival of Group C patients seems to be inferior than that of the Group A and Group B patients, log-rank test revealed that the difference between Groups A and C was not statistically significant ( $P = 0.10$ ).

## DISCUSSION

To our knowledge, the present report is the largest retrospective study investigating chromosome aberrations in gastric MALT lymphoma. Our review of 146 patients revealed that 31 patients (21.2%) had extra copies of *MALT1*. Prevalence of trisomy 18 in MALT lymphomas has been reported to range from 5% to 39%<sup>[11-17]</sup>. Other chromosomal abnormalities involved in MALT lymphomas are trisomies 3, 7 and 12. The incidence varies between reports in the literature: trisomy 3 can be detected in 6% to 24%, trisomy 7 in 3% to 15%, and trisomy 12 in 3% to 38%<sup>[17]</sup>.

The clinical significance of these chromosomal numerical changes has been investigated in several studies<sup>[6-8,18-20]</sup>. Tanimoto *et al.*<sup>[19]</sup> investigated 34 patients with primary ocular adnexal MALT lymphoma and found that disease recurrence was documented in five cases, all of which had trisomy 18. Statistical analysis revealed that the time to recurrence was significantly shorter in patients with trisomy 18 than in those without trisomy 18 ( $P = 0.05$ ). We also reported a patient with gastric MALT lymphoma with trisomy 18 in whom only partial improvement was documented after eradication therapy for *H. pylori*,

and lymphoma recurred in the stomach 16 months after radiotherapy<sup>[5]</sup>. On the other hand, Taji *et al.*<sup>[17]</sup> retrospectively reviewed 13 patients with localized MALT lymphoma in the stomach, and reported that all patients with unresponsive or progressive disease had t(11;18) translocation or trisomy 3. Conversely, one patient with complete response had trisomy 18, and another patient with complete response had both trisomies 12 and 18. Based on these findings, the authors speculate that trisomy 3 is related to resistance to *H. pylori* eradication therapy and disease recurrence in gastric MALT lymphoma, whereas trisomies 12 and 18 are not. Nakamura and colleagues reviewed 90 cases of gastric MALT lymphoma and reported that extra copies of *MALT1* were found in 18 of 71 (25%) cases<sup>[6]</sup>. Although overall survival was not associated with the presence of extra copies of *MALT1*, disease progression or relapse of lymphoma was more frequently observed in patients with extra copies of *MALT1*. Possible correlations between extra copies of *MALT1* and progression or relapse of lymphoma have been described in other studies as well<sup>[7,8]</sup>. In the present study, although the difference was not statistically significant, log-rank test revealed similar tendencies (Figure 2). Consequently, patients with additional copies of *MALT1* may require more frequent clinical follow-up.

In the present study, the sex ratio of the patients with extra copies of *MALT1* (Group C) was similar to that of the patients without t(11;18) translocation or extra copies of *MALT1* (Group A), with the number of females being greater than males. On the contrary, although the difference was not statistically significant, patients with t(11;18) translocation (Group B) included more males than females. It was also noteworthy that Group C patients had similar prevalence of *H. pylori* infection to Group A. Other patient characteristics, such as the age at lymphoma diagnosis, clinical stages, and macroscopic morphology were not different between Groups A and C. The majority of Group A and Group C patients were treated with *H. pylori* eradication alone. Moreover, *H. pylori* eradication alone resulted in complete remission of lymphoma in 44 patients in Group A and 13 in Group C. Overall, the results observed in this study suggest that patients with trisomy and tetrasomy 18 require no distinct treatment from patients without aberrations. To our knowledge, the present study is the first to reveal clinical responsiveness to *H. pylori* eradication in gastric MALT lymphoma patients with extra copies of *MALT1*. In addition, in the present study, FISH analysis was performed by using fresh biopsy samples, whereas previous reports primarily involved analyses of archival pathologic specimens with the aim of clarifying the etiology of chromosomal aberrations. We believe that our results would be more readily interpreted in actual clinical settings for physicians responsible for gastric MALT lymphoma patient therapy.

The present study included 27 patients (18.5%)

with t(11;18)(q21;q21)/*API2-MALT1* translocation. t(11;18)(q21;q21)/*API2-MALT1* is the most frequent translocation among gastric, pulmonary, intestinal, and cutaneous MALT lymphomas, accounting for 13% to 35% of cases<sup>[3,21,22]</sup>. Other chromosomal aberrations detected in MALT lymphomas include t(1;14)(p22;q32), t(14;18)(q32;q21), t(3;14)(q27;q32), and t(3;14)(p14.1;q32)<sup>[3]</sup>. Several of such karyotypic alterations have been known to activate the nuclear pathway, which is considered to lead to lymphomagenesis. Thus, these translocation-positive MALT lymphomas arise independent of *H. pylori* infection and are unresponsive to antibiotic treatment<sup>[3]</sup>. Moreover, these patients often show a late response and lymphoma relapse during follow-up<sup>[18,23]</sup>. Regardless of the adverse clinical features, t(11;18) translocation is infrequently identified in transformed MALT lymphoma or diffuse large B-cell lymphoma, indicating that high-grade transformation is less likely to occur in translocation-positive MALT lymphomas than in those without chromosome aberration<sup>[3,8,18,24]</sup>. In this context, polymerase chain reaction or FISH analysis for t(11;18) translocation is essential during the initial workup to determine the appropriate treatment strategy<sup>[25]</sup>. Of additional clinical interest is that trisomy and tetrasomy 18 can be detected as extra copies of *MALT1* by FISH analysis, since *MALT1* is located on chromosome 18<sup>[18,20]</sup>.

In our study, all patients with t(11;18) translocation (Group B), except two, were negative for *H. pylori* infection. With regard to the macroscopic morphology of the gastric lesions, no patients in Group B presented with submucosal tumor-like lesions (Table 2). We speculate that this result reflects the lower proliferative potential of MALT lymphoma cells with t(11;18) translocation, compared to that of cells without t(11;18) translocation or extra copies of *MALT1*. Since almost no patients in Group B had *H. pylori* infection, most of the patients were treated with radiotherapy and/or chemotherapy. These clinical features were concordant with previously reported characteristics of MALT lymphoma with t(11;18) (q21;q21)/*API2-MALT1* translocation<sup>[8,22-24]</sup>.

There were several limitations associated with this study. First, the presence of extra copies of *MALT1* is often suggestive of partial or complete trisomy/tetrasomy 18; both are different. Trisomy/tetrasomy 18 should be determined only when extra copies are identified by FISH using centromere-specific probes for chromosome 18, or when gains of chromosome 18 are confirmed by array comparative genomic hybridization or by cytogenetic analysis (G-banding). However, these assays could not be performed because of the retrospective nature of this study. Second, not all chromosome alterations were investigated. As described above, trisomies 3, 7 and 12 and t(14;18) and t(3;14) translocations can be involved in MALT lymphomas<sup>[26,27]</sup>. Therefore, Group A may have been heterogeneous and included

patients with chromosomal aberrations other than t(11;18) translocation and trisomy 18. Third, only patients who underwent FISH analysis for t(11;18) translocation were enrolled in this study. FISH analysis may be waived for patients in which *H. pylori* was eradicated immediately following the diagnosis of MALT lymphoma and lymphoma regression was achieved. Thus, selection bias is a possibility in this study. Fourth, because this is a retrospective, multi-centered study, treatment strategies of each patient may have varied according to the attending physician's preference and the availability of chemotherapy and/or radiotherapy at each institution. Fifth, methods to examine *H. pylori* infection status varied among the different institutions participating in this study. Prospective studies utilizing uniform protocols are required to definitively compare treatment responses and prognosis in each group.

In conclusion, we reviewed 146 patients, including 31 (21.2%) with extra copies of *MALT1* and 27 (18.5%) with t(11;18)(q21;q21)/*API2-MALT1* translocation. Patients with t(11;18) translocation should be treated differently from others. However, patients with extra copies of *MALT1* have similar clinical characteristics to cases without t(11;18) translocation or extra copies of *MALT1*. We propose that these patients can be initially managed in the same way as cases without chromosomal aberrations. However, since progression or relapse tended to be more frequently seen in patients with extra copies of *MALT1*, these patients may require closer clinical follow-up.

## COMMENTS

### Background

Previous studies investigating chromosome aneuploidy in extranodal marginal zone lymphoma of mucosa-associated lymphoid tissue (MALT lymphoma) reported that trisomy 18 might be indicative of progression or relapse in patients with gastric MALT lymphoma.

### Research frontiers

No studies have described the initial treatment and response in patients with extra copies of *MALT1*.

### Innovations and breakthroughs

Patients with extra copies of *MALT1* have similar clinical characteristics to cases without t(11;18) translocation or extra copies of *MALT1*. The present study is the first to reveal clinical responsiveness to *Helicobacter pylori* eradication in gastric MALT lymphoma patients with extra copies of *MALT1*.

### Applications

Patients with extra copies of *MALT1* can be initially managed in the same way as cases without chromosomal aberrations.

### Terminology

MALT lymphoma is one of the non-Hodgkin lymphomas, originating in tissues or organs outside of the lymph nodes. Typically, this neoplasm involves the gastrointestinal tract, thyroid, ocular adnexa, lungs, salivary glands, liver, and skin. Of these organs, the stomach is the most frequently identified primary site.

### Peer-review

This is a well-designed multicenter study on the role of extra copies of *MALT1*

in gastric MALT lymphoma. The conclusion can be supported by the results. It can add something interest to current knowledge.

## REFERENCES

- Nakamura S, Matsumoto T. Helicobacter pylori and gastric mucosa-associated lymphoid tissue lymphoma: recent progress in pathogenesis and management. *World J Gastroenterol* 2013; **19**: 8181-8187 [PMID: 24363507 DOI: 10.3748/wjg.v19.i45.8181]
- Isaacson PG, Chott A, Nakamura S, Muller-Hermelink HK, Harris NL, Swerdlow SH. Extranodal marginal zone lymphoma of mucosa-associated lymphoid tissue (MALT lymphoma). In: Swerdlow SH, Campo E, Harris NL, Jaffe ES, Pileri SA, Stein H, editors. WHO Classification of Tumours of Haematopoietic and Lymphoid Tissues. 4<sup>th</sup> ed. IARC, Lyon, 2008: 214-217
- Raderer M, Kiesewetter B, Ferreri AJ. Clinicopathologic characteristics and treatment of marginal zone lymphoma of mucosa-associated lymphoid tissue (MALT lymphoma). *CA Cancer J Clin* 2016; **66**: 153-171 [PMID: 26773441]
- Nakamura T, Nakamura S, Yonezumi M, Seto M, Yokoi T. The t(11; 18)(q21; q21) translocation in H. pylori-negative low-grade gastric MALT lymphoma. *Am J Gastroenterol* 2000; **95**: 3314-3315 [PMID: 11095369 DOI: 10.1111/j.1572-0241.2000.03314.x]
- Ishikawa H, Iwamuro M, Okada H, Hori K, Kita M, Kawano S, Kawahara Y, Tanaka T, Kondo E, Yoshino T, Yamamoto K. Recurrence after radiotherapy for gastric mucosa-associated lymphoid tissue (MALT) lymphoma with trisomy 18. *Intern Med* 2015; **54**: 911-916 [PMID: 25876571 DOI: 10.2169/internalmedicine.54.3784]
- Nakamura S, Ye H, Bacon CM, Goatly A, Liu H, Banham AH, Ventura R, Matsumoto T, Iida M, Ohji Y, Yao T, Tsuneyoshi M, Du MQ. Clinical impact of genetic aberrations in gastric MALT lymphoma: a comprehensive analysis using interphase fluorescence in situ hybridisation. *Gut* 2007; **56**: 1358-1363 [PMID: 17525089 DOI: 10.1136/gut.2007.123729]
- Krugmann J, Tzankov A, Dirnhofer S, Fend F, Greil R, Siebert R, Erdel M. Unfavourable prognosis of patients with trisomy 18q21 detected by fluorescence in situ hybridisation in t(11;18) negative, surgically resected, gastrointestinal B cell lymphomas. *J Clin Pathol* 2004; **57**: 360-364 [PMID: 15047736]
- Remstein ED, Kurtin PJ, James CD, Wang XY, Meyer RG, Dewald GW. Mucosa-associated lymphoid tissue lymphomas with t(11;18)(q21;q21) and mucosa-associated lymphoid tissue lymphomas with aneuploidy develop along different pathogenetic pathways. *Am J Pathol* 2002; **161**: 63-71 [PMID: 12107090]
- Rohatiner A, d'Amore F, Coiffier B, Crowther D, Gospodarowicz M, Isaacson P, Lister TA, Norton A, Salem P, Shipp M. Report on a workshop convened to discuss the pathological and staging classifications of gastrointestinal tract lymphoma. *Ann Oncol* 1994; **5**: 397-400 [PMID: 8075046]
- Nakamura T, Nakamura S. Current review and reappraisal of gastrointestinal MALT lymphoma with special reference to endoscopic appearances and histopathological diagnoses. *Gastroenterol Endoscopy* 2000; **42**: 1163-1176 (in Japanese with English abstract)
- Wotherspoon AC, Finn TM, Isaacson PG. Trisomy 3 in low-grade B-cell lymphomas of mucosa-associated lymphoid tissue. *Blood* 1995; **85**: 2000-2004 [PMID: 7718871]
- Dierlamm J, Pittaluga S, Wlodarska I, Stul M, Thomas J, Boogaerts M, Michaux L, Driessen A, Mecucci C, Cassiman JJ, De Wolf-Peeters C, Van den Berghe H. Marginal zone B-cell lymphomas of different sites share similar cytogenetic and morphologic features. *Blood* 1996; **87**: 299-307 [PMID: 8547655]
- Ott G, Kalla J, Steinhoff A, Rosenwald A, Katzenberger T, Roblick U, Ott MM, Müller-Hermelink HK. Trisomy 3 is not a common feature in malignant lymphomas of mucosa-associated lymphoid tissue type. *Am J Pathol* 1998; **153**: 689-694 [PMID: 9736018 DOI: 10.1016/S0002-9440(10)65611-8]
- Blanco R, Lyda M, Davis B, Kraus M, Fenoglio-Preiser C. Trisomy 3 in gastric lymphomas of extranodal marginal zone B-cell (mucosa-associated lymphoid tissue) origin demonstrated by FISH in intact paraffin tissue sections. *Hum Pathol* 1999; **30**: 706-711 [PMID: 10374781]
- Brynes RK, Almaguer PD, Leathery KE, McCourty A, Arber DA, Medeiros LJ, Nathwani BN. Numerical cytogenetic abnormalities of chromosomes 3, 7, and 12 in marginal zone B-cell lymphomas. *Mod Pathol* 1996; **9**: 995-1000 [PMID: 8902837]
- Dierlamm J, Michaux L, Wlodarska I, Pittaluga S, Zeller W, Stul M, Criel A, Thomas J, Boogaerts M, Delaere P, Cassiman JJ, de Wolf-Peeters C, Mecucci C, Van den Berghe H. Trisomy 3 in marginal zone B-cell lymphoma: a study based on cytogenetic analysis and fluorescence in situ hybridization. *Br J Haematol* 1996; **93**: 242-249 [PMID: 8611468]
- Taji S, Nomura K, Matsumoto Y, Sakabe H, Yoshida N, Mitsufuji S, Nishida K, Horiike S, Nakamura S, Morita M, Taniwaki M. Trisomy 3 may predict a poor response of gastric MALT lymphoma to Helicobacter pylori eradication therapy. *World J Gastroenterol* 2005; **11**: 89-93 [PMID: 15609403 DOI: 10.3748/wjg.v11.i1.89]
- Ruskoné-Fourmestraux A, Fischbach W, Aleman BM, Boot H, Du MQ, Megraud F, Montalban C, Raderer M, Savio A, Wotherspoon A; EGILS group. EGILS consensus report. Gastric extranodal marginal zone B-cell lymphoma of MALT. *Gut* 2011; **60**: 747-758 [PMID: 21317175 DOI: 10.1136/gut.2010.224949]
- Tanimoto K, Sekiguchi N, Yokota Y, Kaneko A, Watanabe T, Maeshima AM, Matsuno Y, Harada M, Tobinai K, Kobayashi Y. Fluorescence in situ hybridization (FISH) analysis of primary ocular adnexal MALT lymphoma. *BMC Cancer* 2006; **6**: 249 [PMID: 17052360]
- Xia H, Nakayama T, Sakuma H, Yamada S, Sato F, Takino H, Okabe M, Fujiyoshi Y, Hattori H, Inagaki H. Analysis of API2-MALT1 fusion, trisomies, and immunoglobulin VH genes in pulmonary mucosa-associated lymphoid tissue lymphoma. *Hum Pathol* 2011; **42**: 1297-1304 [PMID: 21396678 DOI: 10.1016/j.humpath.2010.11.022]
- Nakamura S, Matsumoto T. Treatment Strategy for Gastric Mucosa-Associated Lymphoid Tissue Lymphoma. *Gastroenterol Clin North Am* 2015; **44**: 649-660 [PMID: 26314674 DOI: 10.1016/j.gtc.2015.05.012]
- Auer IA, Gascoyne RD, Connors JM, Cotter FE, Greiner TC, Sanger WG, Horsman DE. t(11;18)(q21;q21) is the most common translocation in MALT lymphomas. *Ann Oncol* 1997; **8**: 979-985 [PMID: 9402171]
- Yeh KH, Kuo SH, Chen LT, Mao TL, Doong SL, Wu MS, Hsu HC, Tzeng YS, Chen CL, Lin JT, Cheng AL. Nuclear expression of BCL10 or nuclear factor kappa B helps predict Helicobacter pylori-independent status of low-grade gastric mucosa-associated lymphoid tissue lymphomas with or without t(11;18)(q21;q21). *Blood* 2005; **106**: 1037-1041 [PMID: 15845895 DOI: 10.1182/blood-2005-01-0004]
- Tan SY, Ye H, Liu H, Lim KH, Toh HC, Ng CF, Chung YF, Wotherspoon AC, Du MQ. t(11;18)(q21;q21)-positive transformed MALT lymphoma. *Histopathology* 2008; **52**: 777-780 [PMID: 18439161 DOI: 10.1111/j.1365-2559.2008.03020.x]
- Extranodal marginal zone B-cell lymphoma, gastric MALT lymphoma. In: NCCN Clinical Practice Guidelines in Oncology (NCCN Guidelines) Non-Hodgkin's Lymphomas, version 4. 2014 Available from: URL: <https://www.nccn.org/about/nhl.pdf>. Accessed on 13 Feb 2017
- Streubel B, Simonitsch-Klupp I, Müllauer L, Lamprecht A, Huber D, Siebert R, Stolte M, Trautinger F, Lukas J, Puspök A, Formanek M, Assanasen T, Müller-Hermelink HK, Cerroni L, Raderer M, Chott A. Variable frequencies of MALT lymphoma-associated genetic aberrations in MALT lymphomas of different sites. *Leukemia* 2004; **18**: 1722-1726 [PMID: 15356642 DOI: 10.1038/sj.leu.2403501]
- Remstein ED, Dogan A, Einerson RR, Paternoster SF, Fink SR,

Law M, Dewald GW, Kurtin PJ. The incidence and anatomic site specificity of chromosomal translocations in primary extranodal marginal zone B-cell lymphoma of mucosa-associated lymphoid

tissue (MALT lymphoma) in North America. *Am J Surg Pathol* 2006; **30**: 1546-1553 [PMID: 17122510 DOI: 10.1097/01.pas.0000213275.60962.2a]

**P- Reviewer:** Abdel-Salam OM, Garcia-Olmo D, Koch TR, Milone M  
**S- Editor:** Ma YJ **L- Editor:** A **E- Editor:** Xu XR





Published by **Baishideng Publishing Group Inc**  
7901 Stoneridge Drive, Suite 501, Pleasanton, CA 94588, USA  
Telephone: +1-925-223-8242  
Fax: +1-925-223-8243  
E-mail: [bpgoffice@wjgnet.com](mailto:bpgoffice@wjgnet.com)  
Help Desk: <http://www.f6publishing.com/helpdesk>  
<http://www.wjgnet.com>



ISSN 1007-9327



9 771007 932045