

World Journal of *Gastroenterology*

World J Gastroenterol 2017 September 28; 23(36): 6549-6746



REVIEW

- 6549** Treatment options for alcoholic and non-alcoholic fatty liver disease: A review
Singh S, Osna NA, Kharbanda KK
- 6571** Nonalcoholic fatty liver disease: Evolving paradigms
Lonardo A, Nascimbeni F, Maurantonio M, Marrazzo A, Rinaldi L, Adinolfi LE
- 6593** New therapeutic perspectives in irritable bowel syndrome: Targeting low-grade inflammation, immuno-neuroendocrine axis, motility, secretion and beyond
Sinagra E, Morreale GC, Mohammadian G, Fusco G, Guarnotta V, Tomasello G, Cappello F, Rossi F, Amvrosiadis G, Raimondo D

MINIREVIEWS

- 6628** Glucocorticosteroid therapy in inflammatory bowel diseases: From clinical practice to molecular biology
Dubois-Camacho K, Ottum PA, Franco-Muñoz D, De la Fuente M, Torres-Riquelme A, Díaz-Jiménez D, Olivares-Morales M, Astudillo G, Quera R, Hermoso MA

ORIGINAL ARTICLE

Basic Study

- 6639** Attenuation of MET-mediated migration and invasion in hepatocellular carcinoma cells by SOCS1
Gui Y, Khan MGM, Bobbala D, Dubois C, Ramanathan S, Saucier C, Ilangumaran S
- 6650** Protective effects of oral glutathione on fasting-induced intestinal atrophy through oxidative stress
Uchida H, Nakajima Y, Ohtake K, Ito J, Morita M, Kamimura A, Kobayashi J
- 6665** Faecal and mucosal microbiota in patients with functional gastrointestinal disorders: Correlation with toll-like receptor 2/toll-like receptor 4 expression
Dong LN, Wang JP, Liu P, Yang YF, Feng J, Han Y

Case Control Study

- 6674** Genetic biomarkers for hepatocellular cancer risk in a caucasian population
De Mattia E, Cecchin E, Polesel J, Bignucolo A, Roncato R, Lupo F, Crovatto M, Buonadonna A, Tiribelli C, Toffoli G

Retrospective Cohort Study

- 6685** Prognostic value of lymphovascular invasion in Bismuth-Corlette type IV hilar cholangiocarcinoma
Li B, Xiong XZ, Zhou Y, Wu SJ, You Z, Lu J, Cheng NS

Retrospective Study

- 6694** Gastrointestinal symptom prevalence depends on disease duration and gastrointestinal region in type 2 diabetes mellitus

Fujishiro M, Kushiyama A, Yamazaki H, Kaneko S, Koketsu Y, Yamamotoya T, Kikuchi T, Sakoda H, Suzuki R, Kadowaki T

Observational Study

- 6705** Serum angiotensin-converting enzyme level for evaluating significant fibrosis in chronic hepatitis B

Noguchi R, Kaji K, Namisaki T, Moriya K, Kitade M, Takeda K, Kawaratani H, Okura Y, Aihara Y, Furukawa M, Mitoro A, Yoshiji H

- 6715** Wilson's disease in Lebanon and regional countries: Homozygosity and hepatic phenotype predominance

Barada K, El Haddad A, Katerji M, Jomaa M, Usta J

- 6726** Short-term outcomes of overlapped delta-shaped anastomosis, an innovative intracorporeal anastomosis technique, in totally laparoscopic colectomy for colon cancer

Zhou HT, Wang P, Liang JW, Su H, Zhou ZX

Prospective Study

- 6733** Effect of local wound infiltration with ropivacaine on postoperative pain relief and stress response reduction after open hepatectomy

Sun JX, Bai KY, Liu YF, Du G, Fu ZH, Zhang H, Yang JH, Wang B, Wang XY, Jin B

CASE REPORT

- 6741** Pedicled omental patch as a bridging procedure for iatrogenic bile duct injury

Ng JJ, Kow AWC

ABOUT COVER

Editorial board member of *World Journal of Gastroenterology*, Shinji Tanaka, MD, PhD, Associate Professor, Department of Hepato-Biliary-Pancreatic Surgery, Tokyo Medical and Dental University, Tokyo 113-8519, Japan

AIMS AND SCOPE

World Journal of Gastroenterology (*World J Gastroenterol*, *WJG*, print ISSN 1007-9327, online ISSN 2219-2840, DOI: 10.3748) is a peer-reviewed open access journal. *WJG* was established on October 1, 1995. It is published weekly on the 7th, 14th, 21st, and 28th each month. The *WJG* Editorial Board consists of 1375 experts in gastroenterology and hepatology from 68 countries.

The primary task of *WJG* is to rapidly publish high-quality original articles, reviews, and commentaries in the fields of gastroenterology, hepatology, gastrointestinal endoscopy, gastrointestinal surgery, hepatobiliary surgery, gastrointestinal oncology, gastrointestinal radiation oncology, gastrointestinal imaging, gastrointestinal interventional therapy, gastrointestinal infectious diseases, gastrointestinal pharmacology, gastrointestinal pathophysiology, gastrointestinal pathology, evidence-based medicine in gastroenterology, pancreatology, gastrointestinal laboratory medicine, gastrointestinal molecular biology, gastrointestinal immunology, gastrointestinal microbiology, gastrointestinal genetics, gastrointestinal translational medicine, gastrointestinal diagnostics, and gastrointestinal therapeutics. *WJG* is dedicated to become an influential and prestigious journal in gastroenterology and hepatology, to promote the development of above disciplines, and to improve the diagnostic and therapeutic skill and expertise of clinicians.

INDEXING/ABSTRACTING

World Journal of Gastroenterology (*WJG*) is now indexed in Current Contents[®]/Clinical Medicine, Science Citation Index Expanded (also known as SciSearch[®]), Journal Citation Reports[®], Index Medicus, MEDLINE, PubMed, PubMed Central and Directory of Open Access Journals. The 2017 edition of Journal Citation Reports[®] cites the 2016 impact factor for *WJG* as 3.365 (5-year impact factor: 3.176), ranking *WJG* as 29th among 79 journals in gastroenterology and hepatology (quartile in category Q2).

FLYLEAF

I-IX Editorial Board

EDITORS FOR THIS ISSUE

Responsible Assistant Editor: *Xiang Li*
Responsible Electronic Editor: *Fen-Fen Zhang*
Proofing Editor-in-Chief: *Lian-Sheng Ma*

Responsible Science Editor: *Yuan Qi*
Proofing Editorial Office Director: *Jin-Lei Wang*

NAME OF JOURNAL
World Journal of Gastroenterology

ISSN
ISSN 1007-9327 (print)
ISSN 2219-2840 (online)

LAUNCH DATE
October 1, 1995

FREQUENCY
Weekly

EDITORS-IN-CHIEF

Damian Garcia-Olmo, MD, PhD, Doctor, Professor, Surgeon, Department of Surgery, Universidad Autonoma de Madrid; Department of General Surgery, Fundacion Jimenez Diaz University Hospital, Madrid 28040, Spain

Stephen C Strom, PhD, Professor, Department of Laboratory Medicine, Division of Pathology, Karolinska Institutet, Stockholm 141-86, Sweden

Andrzej S Tarnawski, MD, PhD, DSc (Med), Professor of Medicine, Chief Gastroenterology, VA Long Beach Health Care System, University of California, Irvine, CA, 5901 E. Seventh Str., Long Beach,

CA 90822, United States

EDITORIAL BOARD MEMBERS

All editorial board members resources online at <http://www.wjgnet.com/1007-9327/editorialboard.htm>

EDITORIAL OFFICE

Jin-Lei Wang, Director
Yuan Qi, Vice Director
Ze-Mao Gong, Vice Director
World Journal of Gastroenterology
Baishideng Publishing Group Inc
7901 Stoneridge Drive, Suite 501,
Pleasanton, CA 94588, USA
Telephone: +1-925-2238242
Fax: +1-925-2238243
E-mail: editorialoffice@wjgnet.com
Help Desk: <http://www.f6publishing.com/helpdesk>
<http://www.wjgnet.com>

PUBLISHER

Baishideng Publishing Group Inc
7901 Stoneridge Drive, Suite 501,
Pleasanton, CA 94588, USA
Telephone: +1-925-2238242
Fax: +1-925-2238243
E-mail: bpgoffice@wjgnet.com
Help Desk: <http://www.f6publishing.com/helpdesk>

<http://www.wjgnet.com>

PUBLICATION DATE
September 28, 2017

COPYRIGHT

© 2017 Baishideng Publishing Group Inc. Articles published by this Open-Access journal are distributed under the terms of the Creative Commons Attribution Non-commercial License, which permits use, distribution, and reproduction in any medium, provided the original work is properly cited, the use is non commercial and is otherwise in compliance with the license.

SPECIAL STATEMENT

All articles published in journals owned by the Baishideng Publishing Group (BPG) represent the views and opinions of their authors, and not the views, opinions or policies of the BPG, except where otherwise explicitly indicated.

INSTRUCTIONS TO AUTHORS

Full instructions are available online at <http://www.wjgnet.com/bpg/gerinfo/204>

ONLINE SUBMISSION
<http://www.f6publishing.com>

Pedicated omental patch as a bridging procedure for iatrogenic bile duct injury

Jun Jie Ng, Alfred Wei Chieh Kow

Jun Jie Ng, Alfred Wei Chieh Kow, Department of Surgery, National University Hospital, Singapore 119074, Singapore

ORCID Number: Jun Jie Ng (0000-0003-0779-8468); Alfred Kow (0000-0001-8942-8262).

Author contributions: All the authors contributed to the acquisition of data, writing and revision of this manuscript.

Institutional review board statement: This case report was exempt from the Institutional Review Board standards at the National University Hospital in Singapore.

Informed consent statement: The patient provided verbal consent authorizing use and disclosure of her protected health information prior to the writing of this manuscript.

Conflict-of-interest statement: All the authors have no conflicts of interest to declare.

Open-Access: This article is an open-access article which was selected by an in-house editor and fully peer-reviewed by external reviewers. It is distributed in accordance with the Creative Commons Attribution Non Commercial (CC BY-NC 4.0) license, which permits others to distribute, remix, adapt, build upon this work non-commercially, and license their derivative works on different terms, provided the original work is properly cited and the use is non-commercial. See: <http://creativecommons.org/licenses/by-nc/4.0/>

Manuscript source: Unsolicited manuscript

Correspondence to: Jun Jie Ng, Senior Resident, Department of Surgery, National University Hospital, 5 Lower Kent Ridge Road, Singapore 119074, Singapore. jun_jie_ng@nuhs.edu.sg
Telephone: +65-97375930
Fax: +65-67795678

Received: May 4, 2017

Peer-review started: May 4, 2017

First decision: June 6, 2017

Revised: July 22, 2017

Accepted: August 25, 2017

Article in press: August 25, 2017

Published online: September 28, 2017

Abstract

Iatrogenic bile duct injuries during cholecystectomy can present as fulminant intra-abdominal sepsis which precludes immediate repair or biliary reconstruction. We report the case of a 29-year-old female patient who sustained a bile duct injury after an open cholecystectomy in a neighboring country. She presented to our institution 22 d after initial surgery with septic shock and multiple intra-abdominal collections. Endoscopic retrograde cholangiography revealed a large common hepatic duct defect corresponding to a Strasberg type D bile duct injury. Definitive reconstruction such as a hepaticojejunostomy cannot be performed due to the presence of dense adhesions with infected and friable tissues. She underwent a combination of endoscopic biliary stenting and pedicled omental patch repair of the bile duct to control bile leak and sepsis as a bridging procedure to definite hepaticojejunostomy three months later.

Key words: Cholecystectomy; Endoscopic retrograde cholangiopancreatography; Case reports; Bile ducts; Abdominal abscess

© **The Author(s) 2017.** Published by Baishideng Publishing Group Inc. All rights reserved.

Core tip: Iatrogenic bile duct injury is a challenging condition to treat. This case report describes a novel and innovative surgical technique, whereby a pedicled omental patch repair was performed as a bridging procedure to definitive repair such as a hepaticojejunostomy, in a patient who presented in a delayed fashion with severe intra-abdominal sepsis.

Ng JJ, Kow AWC. Pedicled omental patch as a bridging procedure for iatrogenic bile duct injury. *World J Gastroenterol* 2017; 23(36): 6741-6746 Available from: URL: <http://www.wjgnet.com/1007-9327/full/v23/i36/6741.htm> DOI: <http://dx.doi.org/10.3748/wjg.v23.i36.6741>

INTRODUCTION

Iatrogenic bile duct injuries (BDIs) are uncommon but can lead to significant morbidity and mortality in patients who had undergone cholecystectomy. Although the incidence of BDIs in LC was reported to be almost tenfold that of OC during the 1990s, LC has now become the gold standard in the treatment of gallstone disease, with a low and declining incidence of BDIs^[1,2]. Several studies have reported the rate of BDIs during LC to be between 0.4% to 0.7%, but a more recent retrospective review of more than 10000 patients who had undergone LC showed that the incidence of BDIs was 0.2%, which was comparable to that of OC^[3-5]. Approximately one-third of BDIs is diagnosed intra-operatively and are amenable to immediate repair or reconstruction. However, the majority of BDIs are recognized only in the post-operative period with varying clinical presentations such as abdominal pain, jaundice, bile peritonitis or shock^[6-8]. BDIs can be classified using the Strasberg classification, with most BDIs manifesting as biliary leaks (Strasberg type A) that can be managed using endoscopic techniques^[6]. The other large group of BDIs are common bile duct or common hepatic duct transections (Strasberg type E1 to E3) which usually warrants surgical repair^[9]. A tension-free Roux-en-Y hepaticojejunostomy is the preferred surgical procedure for reconstitution of bilio-enteric continuity in major common bile duct or common hepatic duct transections, but rarely, in some patients, the presence of severe intra-abdominal sepsis precludes immediate biliary reconstruction^[8]. We report a novel method of using a pedicled omental patch, combined with endoscopic biliary stenting, as a bridging procedure to control bile leak, in a patient with severe intra-abdominal sepsis from a large common hepatic duct transection after OC, before attempting definitive hepaticojejunostomy.

CASE REPORT

A 29-year-old female underwent an open cholecystectomy for acute calculous cholecystitis in a hospital from a neighbouring country. Exact intra-operative findings and details of her post-operative recovery were not made available to us. She developed obstructive jaundice on post-operative day three with bilious effluent from her abdominal drain on post-operative day seven. She was initially treated expectantly but due to persistent high bilious output from her abdominal drain, she underwent an exploratory laparotomy on post-operative day 16. The surgeons noted a collapsed common bile duct, but were not able to locate the exact site of bile leak. She was subsequently transferred to our institution on post-operative day 22 for further management for further management of her bile leak.

Upon presentation to our institution, the patient

was in septic shock. There was active leakage of bilious fluid from her a right subcostal incision. Her abdomen was distended with generalized tenderness. She was resuscitated and started on broad spectrum antibiotics. Laboratory investigations revealed elevated infective markers with a white cell count of $19 \times 10^9/L$ and a C-reactive protein level of 48 mg/L. Serum bilirubin was normal. Computed tomography scan of the abdomen revealed a 3 cm biloma at the gallbladder fossa (Figure 1A) with multiple rim-enhancing abdominal collections around the upper abdomen (Figure 1B) - the largest being a 9.3 cm \times 8.5 cm perisplenic collection (Figure 1C). Endoscopic retrograde cholangiography performed on post-operative day 23 revealed a large common hepatic duct defect just below the bifurcation, corresponding to a Strasberg type D BDI with contrast seen extravasating into the sub-hepatic recess (Figure 2A). After much difficulty, guide-wires were placed across the bile duct defect and plastic biliary stents were deployed into the left and right hepatic ducts respectively (Figure 2B).

In view of persistent sepsis with the presence of multiple intra-abdominal collections, a decision to perform damage control surgery was taken. At the exploratory laparotomy performed on post-operative day 24, a large 2 cm defect at the anterolateral aspect of the common hepatic duct with biliary stents visible from within was found (Figure 3A). There was a large perisplenic abscess with presence of turbid bile and debris in the sub-hepatic recess which was drained and washed out thoroughly. Neither primary repair of the biliary defect nor biliary reconstruction with a hepaticojejunostomy were suitable options due to dense adhesions around the hepatic hilum with infected and friable surrounding tissues. The biliary drains were unable to completely exclude the biliary system entirely due to the size of the biliary defect. Hence, a well-vascularized and healthy pedicled omental patch was harvested and tagged down circumferentially to the biliary defect using absorbable sutures (Figure 3B). An illustration of the pedicled omental patch is as demonstrated (Figure 4). Drains were placed and the abdomen was closed primarily. The patient improved after surgery with resolution of pyrexia and sepsis. Abdominal drains were removed within eight days of surgery. Laboratory infective markers normalized and serum bilirubin levels remained normal. Intra-abdominal cultures grew *Pseudomonas aeruginosa* and *Klebsiella pneumoniae* and the patient was sent home to complete four weeks of intravenous antibiotics.

A repeat computed tomography scan of the abdomen three months later revealed complete resolution of the intra-abdominal collections. Although the biliary stents were in-situ, there was mild intrahepatic biliary dilatation suggesting the possibility of a common hepatic duct stricture. The patient subsequently underwent creation of a hepaticojejunostomy one week later. Intra-operatively, there were dense adhesions around the porta hepatis with evidence of early stricture

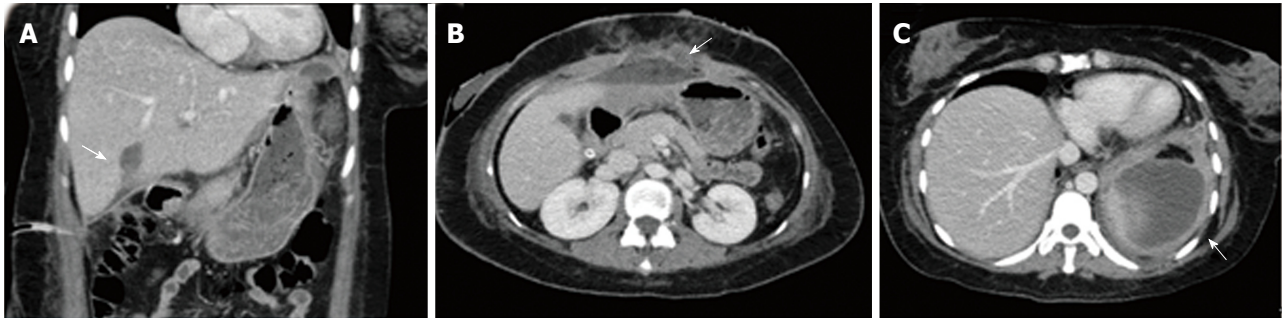


Figure 1 Computed tomography scan. A: Initial computed tomography scan of the abdomen revealing a 3 cm biloma at the gallbladder fossa with bile tracking into the sub-hepatic recess; B: Multiple rim-enhancing smaller intra-abdominal collections were also present in the upper abdomen; C: The largest intra-abdominal collection was a 9.3 cm × 8.5 cm perisplenic collection.

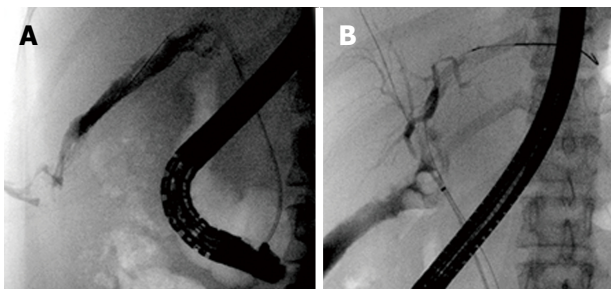


Figure 2 Endoscopic retrograde cholangiography. A: Endoscopic retrograde cholangiography revealed a large Strasberg Type D common hepatic duct defect with contrast seen immediately in the sub-hepatic recess; B: Plastic biliary stents inserted across the biliary defect into the left and right hepatic ducts.

formation at the previous site of BDI. The patient had an uneventful recovery after surgery and was discharged on post-operative day five.

DISCUSSION

BDIs rarely present in such a delayed fashion with fulminant intra-abdominal sepsis. The initial management of BDIs especially for patients that present late in the post-operative period is directed at delineating the type and extent of BDI, controlling sepsis and ongoing bile leak^[8]. We describe a technique that can be utilized as a bridge to definitive bilioenteric reconstruction such as a hepaticojejunostomy when prevailing conditions such as severe intra-abdominal sepsis renders immediate or early reconstruction unfavourable and not ideal. Our technique fulfils the above-mentioned principles of BDI management - first by using endoscopic retrograde cholangiogram to characterize the BDI with placement of biliary stents endoscopically to help control the bile leak. The stents will negate the function of the sphincter of Oddi as well as direct bile into the duodenum. Subsequent laparotomy will allow source control of sepsis *via* drainage of intra-abdominal abscesses whilst the placement of a pedicled omental patch will ensure proper sealing of the biliary defect and

exclusion of the biliary system from the peritoneal cavity. This restores continuity of bile flow, allows for resolution of intra-abdominal sepsis, inflammation and fibrosis, after which definitive bilioenteric reconstruction can be performed at an elective setting as the presence of peritonitis has been reported to confer a poorer outcome in patients undergoing biliary reconstruction^[10].

The use of omentum as an autologous graft to seal, patch or reinforce tissues during surgery is widely practiced, and its ability to support and adhere to local tissue is due to its abundant blood supply, angiogenic activity, innate immune function and high concentration of tissue factor^[11,12]. Moreover, animal studies have shown that the use of a pedicled omental flap in tissue reconstruction confers an anti-inflammatory effect, which can lead to an improved healing response^[13].

Omentum has been commonly used as a patch to close perforations in the gastro-intestinal tract such as a perforated duodenal ulcer. There have been several reports describing the use of omentum in biliary reconstruction. Meissner described his technique of "T-tube stented omentoplasty" used to successfully treat a common hepatic duct stricture. After incising the strictured segment of bile duct resulting in a 4 cm non-circumferential biliary defect, a large bore T-tube was placed within and a pedicled omental flap was then sutured down over the horizontal limb of the T-tube to bridge any remnant biliary defect as well as to envelop the vertical limb. The T-tube was removed after 6 mo with no sequelae and repeat ERC 19 years later showed normal biliary anatomy^[14]. Ebata *et al*^[15] also described a similar technique of "hilar cholangioplasty" where he used a pedicled omental flap with a 16F T-tube to seal a 2 cm × 3 cm ductal defect due to a biliohepatic fistula. T-tube cholangioscopy 1 mo after surgery revealed a yellowish polypoid mass at the previous ductal defect and a biopsy taken revealed normal biliary epithelium lining the surface of the grafted omentum. The patient was followed up for 3 years without evidence of cholangitis or abnormal liver function. Another similar technique was described

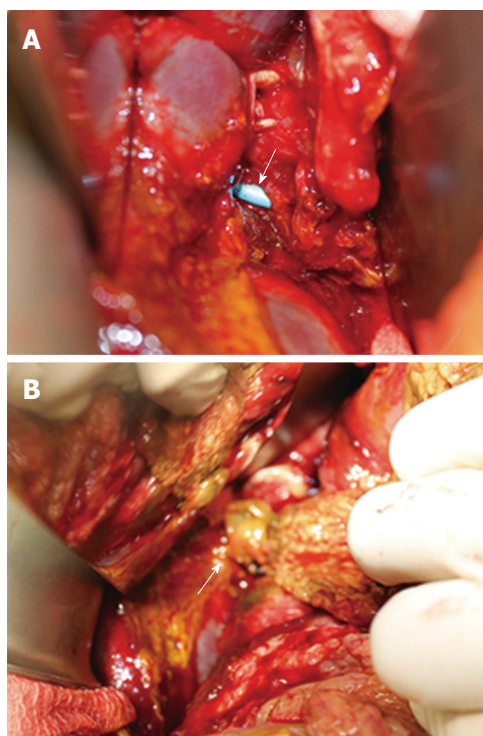


Figure 3 Damage control surgery. A: At the time of exploratory laparotomy, endoscopically placed biliary stents were visible within a large 2 cm anterolateral common hepatic duct defect; B: A pedicled omental patch was harvested and secured to the biliary defect using absorbable sutures.

by Chang but he used the falciform ligament instead of the omentum to patch a large bile duct defect due clip necrosis after laparoscopic cholecystectomy^[16]. Some authors have also used pedicled omental flaps to reinforce high risk biliary anastomoses in liver transplantation with good results^[17]. These examples, although limited to individual case reports reaffirms the ideal properties of omentum that make it a suitable autologous graft to aid in biliary reconstruction.

We postulate that our technique could also have been used as a stand-alone procedure without the need of a subsequent hepaticojejunostomy. The biliary stents could then be retrieved endoscopically after 10 to 12 wk. The above-mentioned case reports have shown good long-term patency of the reconstructed bile duct but established data is lacking. A hepaticojejunostomy would still confer the best long-term outcomes, especially in our patient who is young^[18]. Using our technique as a stand-alone procedure remains experimental and may be suitable in patients who cannot tolerate longer periods of general anaesthesia needed in a hepaticojejunostomy. Intensive follow-up would be necessary for such patients due to the risk of biliary strictures. We performed a definitive hepaticojejunostomy for our patient as she was due to return to a rural area with no access to regular follow-up for the development of biliary strictures.

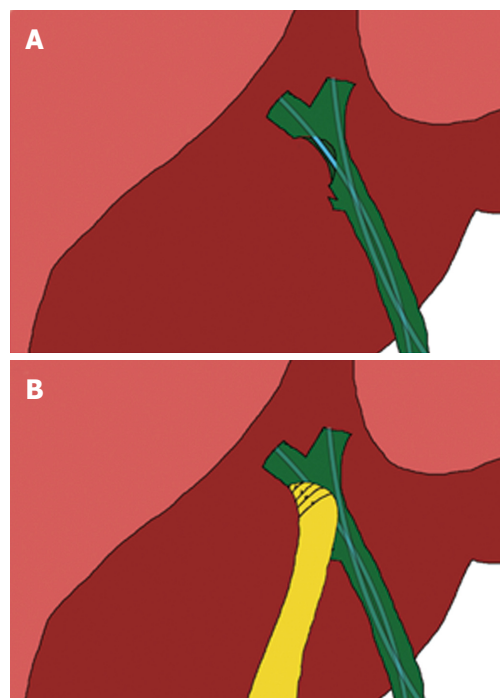


Figure 4 An illustration of the pedicled omental patch. A: An illustration showing the location of the common hepatic duct defect and endoscopic biliary stents placed across; B: The harvested pedicled omental patch was placed over the biliary defect and secured using absorbable sutures that run through the anterior and posterior margins of the biliary defect.

Alternative management strategies that could be deployed in our patient would be the placement of percutaneous trans-hepatic biliary drainage tubes or endoscopic biliary stents, combined with either percutaneous or surgically inserted intra-abdominal drains. This might be feasible if the ductal defect was small. However, if the ductal defect is large, the bile leak not be controlled leading to persistent biliary peritonitis and the development of intra-abdominal collections. Moreover, the drains would have to be placed on active suction for a significant period of time to be able to successfully divert and control the bile leak. More often than not, these drains would have to be kept for weeks to months until the patient undergoes definitive bilioenteric reconstruction. In a patient like ours who present with uncontrolled bile leak, intra-abdominal collections and sepsis, the utilization of our technique would allow for control of bile leak without any other additional percutaneous procedures or prolonged drain placement. Another management strategy that could be considered would be use of a T-tube in combination with an omental pedicled flap similar to techniques described above. We were, however, with the assistance of an experienced operator, able to cannulate the left and right hepatic ducts individually and place biliary stents across the biliary defect obviating the need of a T-tube.

Lastly, and most importantly, our case highlights the

need for early referral to an institution with experienced hepatobiliary surgeons, endoscopists, or interventional radiologists once a BDI is diagnosed. It is irrefutable evidence that best outcomes are obtained when first repair is performed in experienced tertiary centres^[18,19].

This case highlights the need for early referral of BDIs to specialist tertiary centres for further management once detected. Immediate repair or biliary reconstruction is contraindicated in patients with BDIs who present in a delayed fashion with severe intra-abdominal sepsis. We describe an alternative technique which combines endoscopic biliary stenting with a pedicled omental patch as a bridging procedure to definitive hepaticojejunostomy in this group of patients.

COMMENTS

Case characteristics

A 29-year-old female presented with septic shock and generalized abdominal pain following an open cholecystectomy performed three weeks ago in another hospital.

Clinical diagnosis

Physical examination revealed generalized abdominal tenderness and leakage of bile stained fluid from a right subcostal incision.

Differential diagnosis

Bile duct injury, duodenal injury, small bowel injury.

Laboratory diagnosis

Initial laboratory investigations revealed an elevated total white cell count and C-reactive protein levels.

Imaging diagnosis

Computed tomography scan of the abdomen revealed multiple large intra-abdominal collections. Endoscopic retrograde cholangiography revealed a large common hepatic duct defect (Strasberg type D bile duct injury).

Treatment

An exploratory laparotomy with a pedicled omental patch repair of the common hepatic duct was performed initially, followed by a definitive hepaticojejunostomy three months later.

Related reports

This is the first report describing the use of a pedicled omental patch combined with biliary stenting for treatment of a large bile duct injury. Two other case reports have described the use of a pedicled omental patch in conjunction with a T tube for similar bile duct injuries.

Experiences and lessons

In patients who present with severe intra-abdominal sepsis after bile duct injury, up-front creation of a definitive hepaticojejunostomy may not be possible. Instead, a pedicled omental patch repair of the biliary defect may be performed as a bridging procedure to a hepaticojejunostomy, or even as a stand-alone procedure.

Peer-review

The authors presented a novel and alternative technique by using a pedicled omental patch repair as a bridge to a definitive procedure in bile duct injuries.

REFERENCES

- Dolan JP**, Diggs BS, Sheppard BC, Hunter JG. Ten-year trend in the national volume of bile duct injuries requiring operative repair. *Surg Endosc* 2005; **19**: 967-973 [PMID: 15920680 DOI: 10.1007/s00464-004-8942-6]
- McPartland KJ**, Pomposelli JJ. Iatrogenic biliary injuries: classification, identification, and management. *Surg Clin North Am* 2008; **88**: 1329-1343; ix [PMID: 18992598 DOI: 10.1016/j.suc.2008.07.006]
- Adamsen S**, Hansen OH, Funch-Jensen P, Schulze S, Stage JG, Wara P. Bile duct injury during laparoscopic cholecystectomy: a prospective nationwide series. *J Am Coll Surg* 1997; **184**: 571-578 [PMID: 9179112]
- Flum DR**, Cheadle A, Prela C, Dellinger EP, Chan L. Bile duct injury during cholecystectomy and survival in medicare beneficiaries. *JAMA* 2003; **290**: 2168-2173 [PMID: 14570952 DOI: 10.1001/jama.290.16.2168]
- Pekolj J**, Alvarez FA, Palavecino M, Sánchez Clariá R, Mazza O, de Santibañes E. Intraoperative management and repair of bile duct injuries sustained during 10,123 laparoscopic cholecystectomies in a high-volume referral center. *J Am Coll Surg* 2013; **216**: 894-901 [PMID: 23518251 DOI: 10.1016/j.jamcollsurg.2013.01.051]
- Strasberg SM**, Hertl M, Soper NJ. An analysis of the problem of biliary injury during laparoscopic cholecystectomy. *J Am Coll Surg* 1995; **180**: 101-125 [PMID: 8000648]
- Sicklick JK**, Camp MS, Lillemoe KD, Melton GB, Yeo CJ, Campbell KA, Talamini MA, Pitt HA, Coleman J, Sauter PA, Cameron JL. Surgical management of bile duct injuries sustained during laparoscopic cholecystectomy: perioperative results in 200 patients. *Ann Surg* 2005; **241**: 786-792; discussion 793-795 [PMID: 15849514]
- Lau WY**, Lai EC, Lau SH. Management of bile duct injury after laparoscopic cholecystectomy: a review. *ANZ J Surg* 2010; **80**: 75-81 [PMID: 20575884 DOI: 10.1111/j.1445-2197.2009.05205.x]
- Pitt HA**, Sherman S, Johnson MS, Hollenbeck AN, Lee J, Daum MR, Lillemoe KD, Lehman GA. Improved outcomes of bile duct injuries in the 21st century. *Ann Surg* 2013; **258**: 490-499 [PMID: 24022441 DOI: 10.1097/SLA.0b013e3182a1b25b]
- Goykhman Y**, Kory I, Small R, Kessler A, Klausner JM, Nakache R, Ben-Haim M. Long-term outcome and risk factors of failure after bile duct injury repair. *J Gastrointest Surg* 2008; **12**: 1412-1417 [PMID: 18493825 DOI: 10.1007/s11605-008-0538-3]
- Goldsmith HS**. The omentum: Research and clinical applications. Springer-Verlag, New York, 1990
- Logmans A**, Schoenmakers CH, Haensel SM, Koolhoven I, Trimbos JB, van Lent M, van Ingen HE. High tissue factor concentration in the omentum, a possible cause of its hemostatic properties. *Eur J Clin Invest* 1996; **26**: 82-83 [PMID: 8682161]
- Uchibori T**, Takanari K, Hashizume R, Amoroso NJ, Kamei Y, Wagner WR. Use of a pedicled omental flap to reduce inflammation and vascularize an abdominal wall patch. *J Surg Res* 2017; **212**: 77-85 [PMID: 28550925 DOI: 10.1016/j.jss.2016.11.052]
- Meissner K**. Successful repair of Bismuth type 2 bile duct stricture by T-tube stented omentoplasty: 19 years follow-up. *HPB (Oxford)* 2001; **3**: 241-244 [PMID: 18333023 DOI: 10.1080/136518201752422299]
- Ebata T**, Takagi K, Nagino M. Hilar cholangioplasty using omentum for ductal defect in biliobiliary fistula. *J Hepatobiliary Pancreat Sci* 2011; **18**: 458-462 [PMID: 20886358 DOI: 10.1007/s00534-010-0332-y]
- Chang EG**. Repair of common bile duct injury with the round and falciform ligament after clip necrosis: case report. *JSLs* 2000; **4**: 163-165 [PMID: 10917125]
- Ye QF**, Niu Y, She XG, Ming YZ, Cheng K, Ma Y, Ren ZH. Pedicled greater omentum flap for preventing bile leak in liver transplantation patients with poor biliary tract conditions.

Hepatobiliary Pancreat Dis Int 2007; **6**: 470-473 [PMID: 17897907]

- 18 **Stewart L**, Way LW. Bile duct injuries during laparoscopic cholecystectomy. Factors that influence the results of treatment. *Arch Surg* 1995; **130**: 1123-1128; discussion 1129 [PMID:

7575127]

- 19 **Lillemoe KD**, Melton GB, Cameron JL, Pitt HA, Campbell KA, Talamini MA, Sauter PA, Coleman J, Yeo CJ. Postoperative bile duct strictures: management and outcome in the 1990s. *Ann Surg* 2000; **232**: 430-441 [PMID: 10973393]

P- Reviewer: Chiu CC, García-Flórez LJ, Tarnawski AS

S- Editor: Qi Y **L- Editor:** A **E- Editor:** Ma YJ





Published by **Baishideng Publishing Group Inc**
7901 Stoneridge Drive, Suite 501, Pleasanton, CA 94588, USA
Telephone: +1-925-223-8242
Fax: +1-925-223-8243
E-mail: bpgoffice@wjgnet.com
Help Desk: <http://www.f6publishing.com/helpdesk>
<http://www.wjgnet.com>



ISSN 1007-9327

