

World Journal of *Gastroenterology*

World J Gastroenterol 2018 May 7; 24(17): 1825-1924





REVIEW

- 1825 Is it possible to stop nucleos(t)ide analogue treatment in chronic hepatitis B patients?
Moreno-Cubero E, Sánchez del Arco RT, Peña-Asensio J, Sanz de Villalobos E, Miquel J, Larrubia JR
- 1839 Emergence of immunotherapy as a novel way to treat hepatocellular carcinoma
Mukaida N, Nakamoto Y

MINIREVIEWS

- 1859 Endoscopic management of Crohn's strictures
Bessissow T, Reinglas J, Aruljothy A, Lakatos PL, Van Assche G
- 1868 Anti-integrin therapy for inflammatory bowel disease
Park SC, Jeon YT
- 1881 Olfactomedin-4 in digestive diseases: A mini-review
Wang XY, Chen SH, Zhang YN, Xu CF

ORIGINAL ARTICLE

Basic Study

- 1888 Oral treatment with plecanatide or dolcanatide attenuates visceral hypersensitivity *via* activation of guanylate cyclase-C in rat models
Boulete IM, Thadi A, Beaufrand C, Patwa V, Joshi A, Foss JA, Eddy EP, Eutamene H, Palejwala VA, Theodorou V, Shailubhai K
- 1901 Mitochondrial pathway mediated by reactive oxygen species involvement in α -hederin-induced apoptosis in hepatocellular carcinoma cells
Li J, Wu DD, Zhang JX, Wang J, Ma JJ, Hu X, Dong WG

Retrospective Study

- 1911 Usefulness of three-dimensional visualization technology in minimally invasive treatment for infected necrotizing pancreatitis
Wang PF, Liu ZW, Cai SW, Su JJ, He L, Feng J, Xin XL, Lu SC

CASE REPORT

- 1919 Development of tenofovir disoproxil fumarate resistance after complete viral suppression in a patient with treatment-naïve chronic hepatitis B: A case report and review of the literature
Cho WH, Lee HJ, Bang KB, Kim SB, Song IH

ABOUT COVER

Editorial board member of *World Journal of Gastroenterology*, Khaled Ali Jadallah, MD, Associate Professor, Doctor, Department of Internal Medicine, King Abdullah University Hospital, Jordan University of Science and Technology, Irbid 22110, Jordan

AIMS AND SCOPE

World Journal of Gastroenterology (*World J Gastroenterol*, *WJG*, print ISSN 1007-9327, online ISSN 2219-2840, DOI: 10.3748) is a peer-reviewed open access journal. *WJG* was established on October 1, 1995. It is published weekly on the 7th, 14th, 21st, and 28th each month. The *WJG* Editorial Board consists of 642 experts in gastroenterology and hepatology from 59 countries.

The primary task of *WJG* is to rapidly publish high-quality original articles, reviews, and commentaries in the fields of gastroenterology, hepatology, gastrointestinal endoscopy, gastrointestinal surgery, hepatobiliary surgery, gastrointestinal oncology, gastrointestinal radiation oncology, gastrointestinal imaging, gastrointestinal interventional therapy, gastrointestinal infectious diseases, gastrointestinal pharmacology, gastrointestinal pathophysiology, gastrointestinal pathology, evidence-based medicine in gastroenterology, pancreatology, gastrointestinal laboratory medicine, gastrointestinal molecular biology, gastrointestinal immunology, gastrointestinal microbiology, gastrointestinal genetics, gastrointestinal translational medicine, gastrointestinal diagnostics, and gastrointestinal therapeutics. *WJG* is dedicated to become an influential and prestigious journal in gastroenterology and hepatology, to promote the development of above disciplines, and to improve the diagnostic and therapeutic skill and expertise of clinicians.

INDEXING/ABSTRACTING

World Journal of Gastroenterology (*WJG*) is now indexed in Current Contents[®]/Clinical Medicine, Science Citation Index Expanded (also known as SciSearch[®]), Journal Citation Reports[®], Index Medicus, MEDLINE, PubMed, PubMed Central and Directory of Open Access Journals. The 2017 edition of Journal Citation Reports[®] cites the 2016 impact factor for *WJG* as 3.365 (5-year impact factor: 3.176), ranking *WJG* as 29th among 79 journals in gastroenterology and hepatology (quartile in category Q2).

EDITORS FOR THIS ISSUE

Responsible Assistant Editor: *Xiang Li*
Responsible Electronic Editor: *Yan Huang*
Proofing Editor-in-Chief: *Lian-Sheng Ma*

Responsible Science Editor: *Fang-Fang Ji*
Proofing Editorial Office Director: *Ze-Mao Gong*

NAME OF JOURNAL
World Journal of Gastroenterology

ISSN
ISSN 1007-9327 (print)
ISSN 2219-2840 (online)

LAUNCH DATE
October 1, 1995

FREQUENCY
Weekly

EDITORS-IN-CHIEF
Damian Garcia-Olmo, MD, PhD, Doctor, Professor, Surgeon, Department of Surgery, Universidad Autonoma de Madrid; Department of General Surgery, Fundacion Jimenez Diaz University Hospital, Madrid 28040, Spain

Stephen C Strom, PhD, Professor, Department of Laboratory Medicine, Division of Pathology, Karolinska Institutet, Stockholm 141-86, Sweden

Andrzej S Tarnawski, MD, PhD, DSc (Med), Professor of Medicine, Chief Gastroenterology, VA Long Beach Health Care System, University of California, Irvine, CA, 5901 E. Seventh Str., Long Beach,

CA 90822, United States

EDITORIAL BOARD MEMBERS
All editorial board members resources online at <http://www.wjgnet.com/1007-9327/editorialboard.htm>

EDITORIAL OFFICE
Ze-Mao Gong, Director
World Journal of Gastroenterology
Baishideng Publishing Group Inc
7901 Stoneridge Drive, Suite 501,
Pleasanton, CA 94588, USA
Telephone: +1-925-2238242
Fax: +1-925-2238243
E-mail: editorialoffice@wjgnet.com
Help Desk: <http://www.f6publishing.com/helpdesk>
<http://www.wjgnet.com>

PUBLISHER
Baishideng Publishing Group Inc
7901 Stoneridge Drive, Suite 501,
Pleasanton, CA 94588, USA
Telephone: +1-925-2238242
Fax: +1-925-2238243
E-mail: bpgoffice@wjgnet.com
Help Desk: <http://www.f6publishing.com/helpdesk>
<http://www.wjgnet.com>

PUBLICATION DATE
May 7, 2018

COPYRIGHT
© 2018 Baishideng Publishing Group Inc. Articles published by this Open-Access journal are distributed under the terms of the Creative Commons Attribution Non-commercial License, which permits use, distribution, and reproduction in any medium, provided the original work is properly cited, the use is non commercial and is otherwise in compliance with the license.

SPECIAL STATEMENT
All articles published in journals owned by the Baishideng Publishing Group (BPG) represent the views and opinions of their authors, and not the views, opinions or policies of the BPG, except where otherwise explicitly indicated.

INSTRUCTIONS TO AUTHORS
Full instructions are available online at <http://www.wjgnet.com/bpg/gerinfo/204>

ONLINE SUBMISSION
<http://www.f6publishing.com>

Retrospective Study

Usefulness of three-dimensional visualization technology in minimally invasive treatment for infected necrotizing pancreatitis

Peng-Fei Wang, Zhi-Wei Liu, Shou-Wang Cai, Jun-Jun Su, Lei He, Jian Feng, Xian-Lei Xin, Shi-Chun Lu

Peng-Fei Wang, Zhi-Wei Liu, Shou-Wang Cai, Jun-Jun Su, Lei He, Jian Feng, Xian-Lei Xin, Shi-Chun Lu, Department of Hepatobiliary Surgery, PLA General Hospital, Beijing 100853, China

ORCID number: Peng-Fei Wang (0000-0002-2468-8976); Zhi-Wei Liu (0000-0003-3001-5310); Shou-Wang Cai (0000-0003-1652-1487); Jun-Jun Su (0000-0001-7647-7313); Lei He (0000-0003-4722-6923); Jian Feng (0000-0001-7804-5223); Xian-Lei Xin (0000-0003-4655-4132); Shi-Chun Lu (0000-0003-3847-3033).

Author contributions: Wang PF, Liu ZW and Cai SW carried out the studies, participated in collecting the data, and drafted the manuscript; He L and Feng J performed the statistical analysis and participated in its design; Su JJ, Xin XL and Lu SC helped to draft the manuscript; all authors read and approved the final manuscript.

Supported by Beijing Natural Science Foundation, No. 7172201.

Institutional review board statement: This study was approved by the ethics committee of the PLA General Hospital (20170078).

Informed consent statement: All participants provided written informed consent.

Conflict-of-interest statement: All authors declare no conflicts-of-interest related to this article.

Data sharing statement: No additional data are available.

Open-Access: This article is an open-access article which was selected by an in-house editor and fully peer-reviewed by external reviewers. It is distributed in accordance with the Creative Commons Attribution Non Commercial (CC BY-NC 4.0) license, which permits others to distribute, remix, adapt, build upon this work non-commercially, and license their derivative works on different terms, provided the original work is properly cited and the use is non-commercial. See: <http://creativecommons.org/licenses/by-nc/4.0/>

licenses/by-nc/4.0/

Manuscript source: Unsolicited manuscript

Correspondence to: Shou-Wang Cai, MD, PhD, Chief Doctor, Department of Hepatobiliary Surgery, PLA General Hospital, Beijing 100853, China. caisw8077.cai@vip.sina.com
Telephone: +86-10-66938130
Fax: +86-21-57643271

Received: March 7, 2018

Peer-review started: March 7, 2018

First decision: March 21, 2018

Revised: April 2, 2018

Accepted: April 9, 2018

Article in press: April 9, 2018

Published online: May 7, 2018

Abstract

AIM

To explore the value of three-dimensional (3D) visualization technology in the minimally invasive treatment for infected necrotizing pancreatitis (INP).

METHODS

Clinical data of 18 patients with INP, who were admitted to the PLA General Hospital in 2017, were retrospectively analyzed. Two-dimensional images of computed tomography were converted into 3D images based on 3D visualization technology. The size, number, shape and position of lesions and their relationship with major abdominal vasculature were well displayed. Also, percutaneous catheter drainage (PCD) number and puncture paths were designed through virtual surgery (percutaneous nephroscopic necrosectomy) based on the principle of maximum removal of infected necrosis conveniently.

RESULTS

Abdominal 3D visualization images of all the patients were well reconstructed, and the optimal PCD puncture paths were well designed. Infected necrosis was conveniently removed in abundance using a nephroscope during the following surgery, and the median operation time was 102 (102 ± 20.7) min. Only 1 patient underwent endoscopic necrosectomy because of residual necrosis.

CONCLUSION

The 3D visualization technology could optimize the PCD puncture paths, improving the drainage effect in patients with INP. Moreover, it significantly increased the efficiency of necrosectomy through the rigid nephroscope. As a result, it decreased operation times and improved the prognosis.

Key words: Infected necrotizing pancreatitis; Three-dimensional visualization; Percutaneous catheter drainage; Percutaneous nephroscopic necrosectomy

© The Author(s) 2018. Published by Baishideng Publishing Group Inc. All rights reserved.

Core tip: As a lethal disease, infected necrotizing pancreatitis is gradually treated by minimally invasive surgery. Percutaneous catheter drainage (PCD) is the prerequisite of various minimally invasive treatment, which has been of great significance for prognosis of the disease. In this study, three-dimensional (3D) visualization technology was used preoperatively to optimize the puncture position and direction of PCD path. As a result, it improved the drainage effect and increased the efficiency of subsequent necrosectomy. So, the 3D visualization technology was great help for the prognosis of infected necrotizing pancreatitis.

Wang PF, Liu ZW, Cai SW, Su JJ, He L, Feng J, Xin XL, Lu SC. Usefulness of three-dimensional visualization technology in minimally invasive treatment for infected necrotizing pancreatitis. *World J Gastroenterol* 2018; 24(17): 1911-1918 Available from: URL: <http://www.wjgnet.com/1007-9327/full/v24/i17/1911.htm> DOI: <http://dx.doi.org/10.3748/wjg.v24.i17.1911>

INTRODUCTION

Infected necrotizing pancreatitis (INP), which often leads to sepsis and multiple organ failure, is one of the most severe complications of acute pancreatitis^[1,2]. In recent years, various kinds of minimally invasive treatments have achieved good results in treating INP and improved prognosis of the patients^[3,4]. However, irrespective of the kind of minimally invasive surgeries applied, the prerequisite has been to establish a convenient surgical approach through preoperative percutaneous catheter drainage (PCD)^[5,6]. Whether the puncture paths of PCD were ultimately appropriate was related to not only the

effect of drainage but also the efficiency of subsequent minimally invasive removal of infected necrotic tissues.

In recent years, three-dimensional (3D) visualization technology has been widely applied in hepatobiliary and pancreatic surgeries, helping surgeons to intuitively identify the relationship between the shape of lesions and the important anatomical structures around^[7,8]. Therefore, this technique was applied in our center on patients with INP to improve the quality of PCD since January 2017. This study retrospectively analyzed the clinical data of enrolled patients to investigate the value of the 3D visualization technique in guiding PCD of INP.

MATERIALS AND METHODS

General data

Eighteen patients [12 males and 6 females, with an average age of 46 (51 ± 12.9) years] were enrolled in this study. The inclusion criteria were as follows: (1) acute pancreatitis with pancreatic or peripancreatic necrosis accompanied by infection but without any invasive treatment; and (2) patients or their families accepting the evaluation of 3D visual reconstruction. The exclusion criteria were as follows: patients with acute pancreatitis without local complications or liquefied necrotic lesions without infection in a stable condition. According to the 2012 Atlanta classification of acute pancreatitis^[9], 9 patients had moderately severe acute pancreatitis and the other 9 patients had severe acute pancreatitis. This study was approved by the ethics committee of the PLA General Hospital.

Methods

Data acquisition and 3D reconstruction: The 128-slice spiral computed tomography (CT) scanner (GE Corporation, Stamford, CT, United States) was used for obtaining abdominal enhanced CT scans of arterial and portal venous phases. The layer thickness was 1.5 mm, and the layer distance was 1.5 mm. Lipiodol was injected as the contrast medium (Beilu Pharmaceutical Co., Beijing, China); the concentration was 350 mg/mL. A high-pressure syringe was used for elbow vein injection. The dose was 60 mL, and the injection rate was 4 mL/s. The collected image data were stored in the form of Digital Imaging and Communications in Medicine and introduced into 3D visualization system (Mimics 17.0; Materialise Co., Leuven, Belgium) for reconstruction.

Anatomical evaluation and determination of position and paths of optimal puncture points: The reconstructed model could be viewed from any direction (magnified, contracted, rotated, or transparent) through the 3D visualization system. Therefore, the size, shape, position and number of the lesions and surrounding structure were intuitively demonstrated. Moreover, virtual operations could be done on the 3D image to observe different debridement ranges through various puncture points. At last, the optimal puncture number and paths were determined based on the following

principles. First, retroperitoneal access was preferred to transabdominal access, which meant less intraperitoneal contamination. Second, the paths were established along the longitudinal axis of the necrotic cavity, and the puncture point should be as close to the necrotic cavity as possible, facilitating the maximum removal of necrosis. Third, multiple drains should be placed during the same procedure, if necessary, to avoid the visual blind area or operational blind area, which were also estimated using the 3D virtual system.

PCD and percutaneous nephroscopic necrosectomy for removing necrotic tissues:

PCD was performed under the guidance of CT in strict accordance with the position and direction of puncture points designed by the 3D visualization system. Subsequently, an anti-inflammatory drug was administered according to the drainage culture and the results of drug sensitivity test. The changes in the disease were assessed with a reexamination of abdominal CT scan weekly. If the condition did not improve obviously or continued to aggravate, the percutaneous nephroscopic necrosectomy was performed under general anesthesia. Briefly, a 1.2-cm skin incision was made that was centered on the PCD. Amplatz renal dilators (Cook Urological Incorporated, Bloomington, IN, United States) were used to serially dilate to create a 30F tract, following which a 12-mm trocar was inserted.

An operating nephroscope (Hopkins Telescopes; Karl Storz-Endoskope, Tuttlingen, Germany) with an 8-mm working channel was then passed through the trocar into the necrotic cavity. Subsequently, the piecemeal removal of solid necrosis was performed repeatedly using a fenestrated grasper through the working channel. Finally, a 10F catheter sutured to a tube drain of 28F was placed into the distal end of the necrotic cavity to allow continuous lavage after surgery. All patients underwent CT scanning reexamination weekly to evaluate the results of necrosectomy and drain placement. The operation might be performed again, if necessary according to the changes in the condition. The position and range of the lesion, the time and number of surgery, postoperative complications, and the time of hospitalization of each patient were recorded.

Statistical analysis

The SPSS 17.0 software (SPSS Inc., Chicago, IL, United States) was used for statistical analysis. Measurement data were expressed as $\bar{x} \pm s$.

RESULTS

Results of 3D reconstruction

The 3D reconstruction was successfully completed for all of the 18 patients. The results clearly showed the shape, size and number of necrotic lesions, as well as the anatomical relationship with surrounding blood vessels and organs. Thus, the stereoscopic visual observation of the lesions from any angle and virtual surgery using

the aforementioned software system were performed. Further, the removal range and residual blind area of different puncture points were defined. Also, the individualized optimal position, direction and number of puncture paths suitable for patients were determined.

A typical case is given here to illustrate the use of 3D visualization technology: Patient No. 4, a 43-year-old male with alcoholic pancreatitis. The patient suffered from a high fever and abdominal pain for more than 2 wk till he was transferred to the hospital. The CT examination showed extensive peripancreatic necrosis in the retroperitoneal space. The results of 3D reconstruction clearly showed horseshoe-shaped necrosis, as the purple lesion shown in Figure 1A, involving the head of pancreas, uncinate process, root of mesentery, body and tail of pancreas, splenic hilus and left paracolic sulcus, which was closely related to surrounding organs and blood vessels. Virtual percutaneous nephroscopic necrosectomy was performed through the 3D virtual system to determine the three optimal puncture paths. As shown in Figure 1B, the necrosis in the blue area could be debrided from the right puncture path. As shown in Figure 1C, the necrosis in the green area could be debrided from the upper left puncture path. As shown in Figure 1D, the necrosis in the orange area could be debrided from the lower left puncture path. Residual necrosis was found without any single puncture path. Therefore, the three puncture paths were used simultaneously to avoid the operational blind area or residual necrosis. Figures 2–4 are the cross-section, coronal-section and 3D reconstruction images of puncture points on the right side, upper left side, and lower left side, respectively. These were critical to ensure the accuracy of PCD under the guidance of CT.

Clinical results

The CT-guided PCD of the 18 patients was successfully performed strictly according to 3D visualization design, and subsequent percutaneous nephroscopic necrosectomy was carried out according to the changes in the condition, debriding maximum necrosis. Twelve patients were cured by conducting one-time surgery. Five patients were cured after two-time surgery and only one patient underwent the surgery three times. Patient No. 14 underwent additionally endoscopic necrosectomy for removing residual small lesions due to the winding sinus. The median operation time was 102 (102 ± 20.7) min, and the postoperative hospitalization time was 35 (35 ± 8.1) d. No major surgical complications occurred. All the patients were cured and discharged from the hospital eventually (Table 1).

The patient in the aforementioned typical case underwent percutaneous nephroscopic necrosectomy for removing necrotic tissues 14 d after PCD. A large number of infected necrotic tissues were removed from the three puncture points. The clinical condition of the patient improved obviously after surgery. Figure 5 shows the results of abdominal CT re-examination on the 15th day after surgery. Finally, he was discharged from the

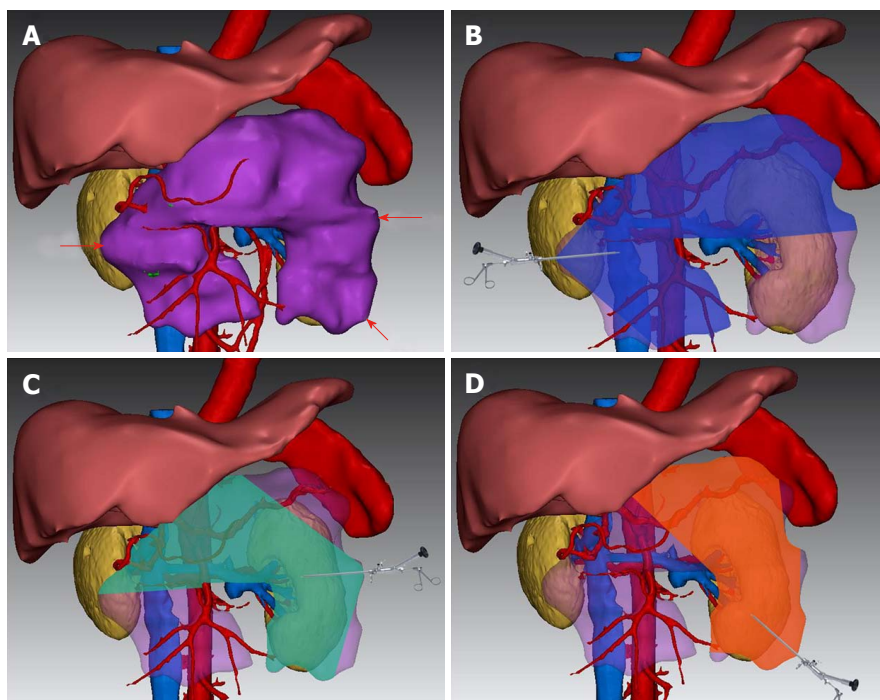


Figure 1 Three-dimensional visualized reconstruction image and virtual surgery for Patient No. 4. A: Horseshoe-shaped infected necrotic lesions (purple) adjacent to important organs and blood vessels; B: Debrided area of percutaneous nephroscopic necrosectomy through the point of puncture on the right puncture point (blue area); C: Debrided area of percutaneous nephroscopic necrosectomy through the point of puncture on the upper left puncture point (green area); D: Debrided area of percutaneous nephroscopic necrosectomy through the point of puncture on the lower left puncture point (orange area).

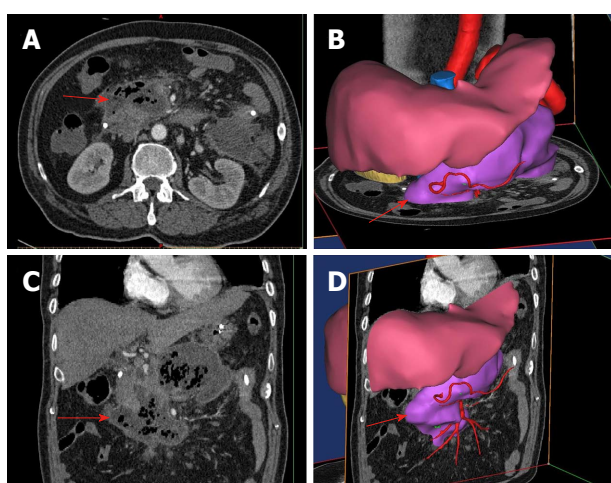


Figure 2 Cross-section, coronal-section and three-dimensional reconstruction images of the right-side puncture path for percutaneous catheter drainage in Patient No. 4. The red arrow represent the fictional direction and path of puncture.

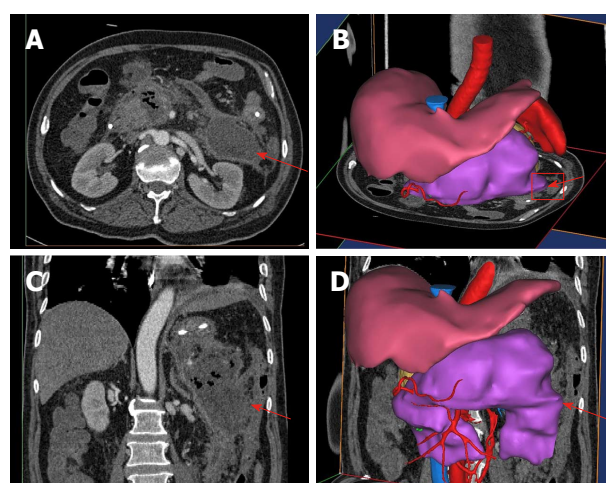


Figure 3 Cross-section, coronal section and three-dimensional reconstruction images of the upper left-side puncture path for percutaneous catheter drainage in Patient No. 4. The red arrow represents the fictional direction and path of puncture.

hospital on the 29th day postoperatively.

DISCUSSION

INP is a serious disease with a mortality of approximately 30% and up to 80% of cases having multiple organ failure^[10,11]. Open necrosectomy has been considered the gold standard treatment for decades. However, the morbidity and mortality rates of the surgery were high^[12,13]. In 2000, Carter *et al*^[14] reported a new treat-

ment method called minimal access retroperitoneal pancreatic necrosectomy, which yielded good results. Since then, various kinds of minimally invasive approaches have been increasingly used worldwide^[14-17].

The first randomized controlled trial compared a minimally invasive necrosectomy with traditional laparotomy necrosectomy and showed a significant decrease in the incidence of complications^[18]. Recently, another clinical study that summed up 394 cases in the last 17 years found that the mortality and incidence of

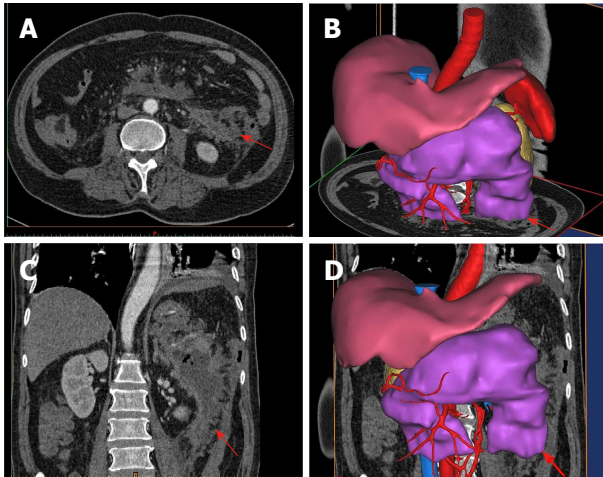


Figure 4 Cross-section, coronal section and three-dimensional reconstruction images of the lower left-side puncture path for percutaneous catheter drainage in Patient No. 4. The red arrow represents the fictional direction and path of puncture.

complications in the minimally invasive nephroscope group were 15.3% and 63.5%, respectively, which were significantly lower than those in the laparotomy group (23.3% and 81.7%, respectively)^[19]. All these studies were based on the belief that the necessary precondition of the minimally invasive surgery was correct PCD.

As the initial step of minimally invasive treatment, the purpose of PCD was to attenuate sepsis and establish an access track for further necrosectomy. Some patients with infected necrotic pancreatitis could even be cured only using PCD^[20,21]. More importantly, PCD established a guide channel for subsequent minimally invasive removal of necrotic tissues. The blind area in percutaneous nephroscopic necrosectomy could be avoided through a reasonable and correct PCD path, which was critical for prognosis. In our hospital, the minimally invasive method has been used since 2008^[22] to treat more than 200 patients with INP until now. A number of them were referrals from other hospitals, and some had undertaken PCD by interventional doctors without considering the convenience for subsequent surgical operation. A few of the patients even undertook a wrong PCD due to the doctors' lack of experience; the catheter passed through the colon, stomach or other hollow organs, which was a disaster for patients with severe pancreatitis. Therefore, it was believed that preoperatively reliable and visualized imaging guidance was crucial for correct PCD.

With the development of digital medicine, 3D visualization software has been gradually applied to clinical practice and proved useful in many diseases. Compared with the traditional two-dimensional ultrasound, CT or magnetic resonance imaging, the 3D visualization image has shown huge advantages in the objective, direct and visual image display of lesions and surrounding anatomical structures. Therefore, it could reduce doctor "mistakes" due to lack of experience.

In this study, the technique was first adopted to treat patients with INP. The site, shape and number of

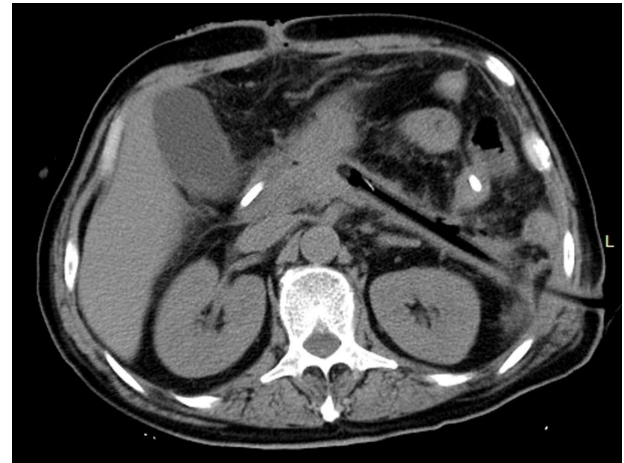


Figure 5 Image of abdominal CT reexamination of Patient No. 4. Abdominal CT reexamination 15 d after percutaneous nephroscopic necrosectomy showed that the abscess cavity disappeared and the drainage tube was unobstructed. CT: Computed tomography.

infected necrotic lesions, as well as their relationship with peripheral vessels and important organs, could be identified through image reconstruction based on CT before surgery, which instructed doctors on how to select the optimal puncture position and direction to establish an ideal PCD path. The infected necrotic tissue was fully drained using multiple ideal PCD paths, which was critically important to attenuate sepsis. Moreover, it helped avoid the blind area and maximally debride the necrosis conveniently in the subsequent surgery. This was the most important reason why two-thirds of patients were cured through a single operation, no patient was switched to laparotomy, and all were cured finally. Consequently, the operation-related complications and time of hospitalization decreased significantly.

The disadvantage of this study was the limited number of patients. Therefore, analysis of more cases is needed to support the findings. However, the initial good results of the study indicated that the 3D visualization technology was meaningful for this terrible disease.

In conclusion, 3D visualization technique could help clinicians in selecting the optimal puncture path of catheterization, which could not only maximize the degree of drainage of infected lesions in pancreatitis patients but also significantly improve the efficiency of subsequent percutaneous nephroscopic necrosectomy and therefore improve the prognosis.

ARTICLE HIGHLIGHTS

Infected necrotizing pancreatitis (INP) is a severe disease with high mortality, which generally requires percutaneous catheter drainage (PCD) and following surgical debridement if necessary. Whether the puncture paths of PCD are appropriate or not is related to not only the effect of drainage but also the efficiency of subsequent minimally invasive removal of infected necrosis. However, a number of patients' PCDs were insufficient or even the catheter passed through the hollow organs due to the doctors' lack of experience, which was a disaster for INP patients.

Table 1 Clinical data of the 6 patients with infected necrotizing pancreatitis after three-dimensional reconstruction and surgery

No.	Sex	Age	Severity	Infected necrosis position	No. of PCD	Operation time in minute	No. of operation times	Surgical complications	Postoperative hospitalization time in day
1	M	58	Moderate to severe	Body and tail of pancreas	1	85	1	None	34
2	F	38	Severe	Around the pancreas	2	145	2	None	48
3	M	39	Moderate to severe	Lesser peritoneal sac, and body and tail of pancreas	1	90	1	None	23
4	M	43	Severe	Head of pancreas, uncinate process, root of mesentery, neck of pancreas, body and tail of pancreas, porta lienis, and left paracolic sulcus	3	150	1	None	29
5	M	58	Moderate to severe	Body and tail of pancreas	1	90	1	None	28
6	M	44	Moderate to severe	Lesser peritoneal sac, and body and tail of pancreas	2	105	1	None	36
7	F	62	Severe	Body and tail of pancreas, paracolic sulcus, and head of pancreas	3	100	2	None	32
8	F	36	Severe	Head of pancreas, uncinate process, body and tail of pancreas, porta lienis, and left paracolic sulcus	3	120	3	None	48
9	M	32	Severe	Lesser peritoneal sac, and body and tail of pancreas	2	105	1	None	39
10	M	67	Severe	Head of pancreas, uncinate process, body and tail of pancreas, porta lienis, and left paracolic sulcus	3	120	1	None	34
11	M	51	Moderate to severe	Body and tail of pancreas, paracolic sulcus, and head of pancreas	2	95	1	None	30
12	F	27	Moderate to severe	Lesser peritoneal sac, and body and tail of pancreas	1	80	1	None	28
13	M	33	Severe	Body and tail of pancreas, paracolic sulcus, and head of pancreas	3	95	2	None	29
14	F	62	Severe	Body and tail of pancreas, paracolic sulcus, and head of pancreas	2	95	1	Residual uncinate process lesions; endoscopic necrosectomy was used for removal	41
15	M	44	Moderate to severe	Lesser peritoneal sac, and body and tail of pancreas	1	90	1	None	45
16	F	39	Severe	Body and tail of pancreas, paracolic sulcus, and head of pancreas	3	105	2	None	48
17	M	67	Moderate to severe	Lesser peritoneal sac, and body and tail of pancreas	1	70	2	None	25
18	M	35	Moderate to severe	Lesser peritoneal sac, and body and tail of pancreas	2	80	1	None	31

PCD: Percutaneous catheter drainage.

Research motivation

Three-dimensional (3D) visualization technology has been proved to be of great help for precise intervention or surgery, which also might be useful to optimize the puncture paths of multiple PCDs for INP patients.

Research objectives

To explore the value of 3D visualization technology for PCDs in INP patients.

Research methods

Preoperative computed tomography images were converted into 3D modellings through a software and the lesions were well displayed. PCD number and puncture paths were designed through virtual surgery (percutaneous nephroscopic necrosectomy) based on the principle of maximum removal of infected necrosis conveniently. We retrospectively analyzed 18 INP patients' clinical data and present a typical case in detail.

Research results

All the patients' 3D modellings was well reconstructed, through which the optimal PCD paths were designed. As a result, infected necrosis was conveniently removed in abundance using a nephroscope during the following surgery and two-thirds of the patients were cured after only one-time operation. Postoperative hospitalization time was 35 d on average, no major surgical complications occurred, and no one died.

Research conclusions

3D visualization technology was useful for INP patients to maximize the PCD effect. Moreover, it significantly improved the efficiency of subsequent percutaneous nephroscopic necrosectomy, which was critically important for improving the prognosis.

Research perspectives

Although the case number of this study was limited, the initial result indicated the value of 3D visualization technology for this terrible disease. Of course, analysis of more cases from multiple centers is needed to support the findings.

REFERENCES

- Whitcomb DC. Clinical practice. Acute pancreatitis. *N Engl J Med* 2006; **354**: 2142-2150 [PMID: 16707751 DOI: 10.1056/NEJMc054958]
- Werner J, Feuerbach S, Uhl W, Büchler MW. Management of acute pancreatitis: from surgery to interventional intensive care. *Gut* 2005; **54**: 426-436 [PMID: 15710995 DOI: 10.1136/gut.2003.035907]
- Raraty MG, Halloran CM, Dodd S, Ghaneh P, Connor S, Evans J, Sutton R, Neoptolemos JP. Minimal access retroperitoneal pancreatic necrosectomy: improvement in morbidity and mortality with a less invasive approach. *Ann Surg* 2010; **251**: 787-793 [PMID: 20395850 DOI: 10.1097/SLA.0b013e3181d96c53]
- Bakker OJ, van Santvoort HC, van Brunschot S, Gekus RB, Besselink MG, Bollen TL, van Eijck CH, Fockens P, Hazebroek EJ, Nijmeijer RM, Poley JW, van Ramshorst B, Vleggaar FP, Boermeester MA, Gooszen HG, Weusten BL, Timmer R; Dutch Pancreatitis Study Group. Endoscopic transgastric vs surgical necrosectomy for infected necrotizing pancreatitis: a randomized trial. *JAMA* 2012; **307**: 1053-1061 [PMID: 22416101 DOI: 10.1001/jama.2012.276]
- van Baal MC, van Santvoort HC, Bollen TL, Bakker OJ, Besselink MG, Gooszen HG; Dutch Pancreatitis Study Group. Systematic review of percutaneous catheter drainage as primary treatment for necrotizing pancreatitis. *Br J Surg* 2011; **98**: 18-27 [PMID: 21136562 DOI: 10.1002/bjs.7304]
- Working Group IAP/APA Acute Pancreatitis Guidelines. IAP/APA evidence-based guidelines for the management of acute pancreatitis. *Pancreatol* 2013; **13**: e1-15 [PMID: 24054878 DOI: 10.1016/j.pan.2013.07.063]
- Sasaki R, Kondo T, Oda T, Murata S, Wakabayashi G, Ohkohchi N. Impact of three-dimensional analysis of multidetector row computed tomography cholangiopancreatography in operative planning for hilar cholangiocarcinoma. *Am J Surg* 2011; **202**: 441-448 [PMID: 21861978 DOI: 10.1016/j.amjsurg.2010.06.034]
- Andolfi C, Plana A, Kania P, Banerjee PP, Small S. Usefulness of Three-Dimensional Modeling in Surgical Planning, Resident Training, and Patient Education. *J Laparoendosc Adv Surg Tech A* 2017; **27**: 512-515 [PMID: 27813710 DOI: 10.1089/lap.2016.0421]
- Banks PA, Bollen TL, Dervenis C, Gooszen HG, Johnson CD, Sarr MG, Tsiotos GG, Vege SS; Acute Pancreatitis Classification Working Group. Classification of acute pancreatitis--2012: revision of the Atlanta classification and definitions by international consensus. *Gut* 2013; **62**: 102-111 [PMID: 23100216 DOI: 10.1136/gutjnl-2012-302779]
- Banks PA, Freeman ML; Practice Parameters Committee of the American College of Gastroenterology. Practice guidelines in acute pancreatitis. *Am J Gastroenterol* 2006; **101**: 2379-2400 [PMID: 17032204 DOI: 10.1111/j.1572-0241.2006.00856.x]
- Working Party of the British Society of Gastroenterology; Association of Surgeons of Great Britain and Ireland; Pancreatic Society of Great Britain and Ireland; Association of Upper GI Surgeons of Great Britain and Ireland. UK guidelines for the management of acute pancreatitis. *Gut* 2005; **54** Suppl 3: iii1-iii9 [PMID: 15831893 DOI: 10.1136/gut.2004.057026]
- Neoptolemos JP, Raraty M, Finch M, Sutton R. Acute pancreatitis: the substantial human and financial costs. *Gut* 1998; **42**: 886-891 [PMID: 9691932 DOI: 10.1136/gut.42.6.886]
- Göttinger P, Sautner T, Kriwanek S, Beckerhinn P, Barlan M, Armbruster C, Wamser P, Függer R. Surgical treatment for severe acute pancreatitis: extent and surgical control of necrosis determine outcome. *World J Surg* 2002; **26**: 474-478 [PMID: 11910483 DOI: 10.1007/s00268-001-0252-8]
- Carter CR, McKay CJ, Imrie CW. Percutaneous necrosectomy and sinus tract endoscopy in the management of infected pancreatic necrosis: an initial experience. *Ann Surg* 2000; **232**: 175-180 [PMID: 10903593 DOI: 10.1097/0000658-200008000-00004]
- Connor S, Ghaneh P, Raraty M, Sutton R, Rosso E, Garvey CJ, Hughes ML, Evans JC, Rowlands P, Neoptolemos JP. Minimally invasive retroperitoneal pancreatic necrosectomy. *Dig Surg* 2003; **20**: 270-277 [PMID: 12748429 DOI: 10.1159/000071184]
- van Santvoort HC, Bakker OJ, Bollen TL, Besselink MG, Ahmed Ali U, Schrijver AM, Boermeester MA, van Goor H, Dejong CH, van Eijck CH, van Ramshorst B, Schaapherder AF, van der Harst E, Hofker S, Nieuwenhuijs VB, Brink MA, Kruij PM, Manusama ER, van der Schelling GP, Karsten T, Hesselink EJ, van Laarhoven CJ, Rosman C, Bosscha K, de Wit RJ, Houdijk AP, Cuesta MA, Wahab PJ, Gooszen HG; Dutch Pancreatitis Study Group. A conservative and minimally invasive approach to necrotizing pancreatitis improves outcome. *Gastroenterology* 2011; **141**: 1254-1263 [PMID: 21741922 DOI: 10.1053/j.gastro.2011.06.073]
- Babu RY, Gupta R, Kang M, Bhasin DK, Rana SS, Singh R. Predictors of surgery in patients with severe acute pancreatitis managed by the step-up approach. *Ann Surg* 2013; **257**: 737-750 [PMID: 22968079 DOI: 10.1097/SLA.0b013e318269d25d]
- van Santvoort HC, Besselink MG, Bakker OJ, Hofker HS, Boermeester MA, Dejong CH, van Goor H, Schaapherder AF, van Eijck CH, Bollen TL, van Ramshorst B, Nieuwenhuijs VB, Timmer R, Laméris JS, Kruij PM, Manusama ER, van der Harst E, van der Schelling GP, Karsten T, Hesselink EJ, van Laarhoven CJ, Rosman C, Bosscha K, de Wit RJ, Houdijk AP, van Leeuwen MS, Buskens E, Gooszen HG; Dutch Pancreatitis Study Group. A step-up approach or open necrosectomy for necrotizing pancreatitis. *N Engl J Med* 2010; **362**: 1491-1502 [PMID: 20410514 DOI: 10.1056/NEJMoa0908821]
- Gomatos IP, Halloran CM, Ghaneh P, Raraty MG, Polydoros F, Evans JC, Smart HL, Yagati-Satchidanand R, Garry JM, Whelan PA, Hughes FE, Sutton R, Neoptolemos JP. Outcomes From Minimal Access Retroperitoneal and Open Pancreatic Necrosectomy in 394 Patients With Necrotizing Pancreatitis. *Ann Surg* 2016; **263**: 992-1001 [PMID: 26501713 DOI: 10.1097/SLA.0000000000001407]

- 20 **Segal D**, Morteale KJ, Banks PA, Silverman SG. Acute necrotizing pancreatitis: role of CT-guided percutaneous catheter drainage. *Abdom Imaging* 2007; **32**: 351-361 [PMID: 17502982 DOI: 10.1007/s00261-007-9221-5]
- 21 **Rocha FG**, Benoit E, Zinner MJ, Whang EE, Banks PA, Ashley SW, Morteale KJ. Impact of radiologic intervention on mortality in necrotizing pancreatitis: the role of organ failure. *Arch Surg* 2009; **144**: 261-265 [PMID: 19289666 DOI: 10.1001/archsurg.2008.587]
- 22 **Cai SW**, Wang PF, Liu ZW, He L, Liu H, Kang HJ, Xiao YY, Song Q, Gu WQ, Dong JH, Huang ZQ. Improvement and effect of retroperitoneoscopic necrosectomy for infected necrotizing pancreatitis. *Zhonghua Gandan Waike Zazhi* 2012; **18**: 439-441 [DOI: 10.3760/cma.j.issn.1007-8118.2012.06.013]
- P- Reviewer:** Ominami M, Park SJ, Queiroz DM **S- Editor:** Gong ZM
L- Editor: Filipodia **E- Editor:** Huang Y





Published by **Baishideng Publishing Group Inc**
7901 Stoneridge Drive, Suite 501, Pleasanton, CA 94588, USA
Telephone: +1-925-223-8242
Fax: +1-925-223-8243
E-mail: bpgoffice@wjgnet.com
Help Desk: <http://www.f6publishing.com/helpdesk>
<http://www.wjgnet.com>



ISSN 1007-9327

