

# World Journal of *Gastroenterology*

*World J Gastroenterol* 2018 October 21; 24(39): 4419-4518



**EDITORIAL**

- 4419 Portal vein thrombosis in cirrhotic patients - it is always the small pieces that make the big picture  
*Gîrleanu I, Trifan A, Stanciu C, Sfarti C*
- 4428 Novel targeting approaches and signaling pathways of colorectal cancer: An insight  
*Tiwari A, Saraf S, Verma A, Panda PK, Jain SK*

**MINIREVIEWS**

- 4436 Carcinogenesis on the background of liver fibrosis: Implications for the management of hepatocellular cancer  
*O'Rourke JM, Sagar VM, Shah T, Shetty S*

**ORIGINAL ARTICLE****Basic Study**

- 4448 Sheng-jiang powder ameliorates obesity-induced pancreatic inflammatory injury *via* stimulating activation of the AMPK signalling pathway in rats  
*Miao YF, Li J, Zhang YM, Zhu L, Chen H, Yuan L, Hu J, Yi XL, Wu QT, Wan MH, Tang WF*

**Case Control Study**

- 4462 Molecular evaluation of glutathione S transferase family genes in patients with sporadic colorectal cancer  
*Rodrigues-Fleming GH, Fernandes GMM, Russo A, Biselli-Chicote PM, Netinho JG, Pavarino ÉC, Goloni-Bertollo EM*

**Retrospective Cohort Study**

- 4472 Barrett's esophagus with high grade dysplasia is associated with non-esophageal cancer  
*Bar N, Schwartz N, Nissim M, Fliss-Isacov N, Zelber-Sagi S, Kariv R*

**Retrospective Study**

- 4482 Agitation thrombolysis combined with catheter-directed thrombolysis for the treatment of non-cirrhotic acute portal vein thrombosis  
*Wang CY, Wei LQ, Niu HZ, Gao WQ, Wang T, Chen SJ*
- 4489 Ursodeoxycholic acid combined with percutaneous transhepatic balloon dilation for management of gallstones after elimination of common bile duct stones  
*Chang HY, Wang CJ, Liu B, Wang YZ, Wang WJ, Wang W, Li D, Li YL*
- 4499 Postoperative survival analysis and prognostic nomogram model for patients with portal hypertension  
*Zhang YF, Ji H, Lu HW, Lu L, Wang L, Wang JL, Li YM*

**Observational Study**

- 4510 Fungal dysbiosis predicts the diagnosis of pediatric Crohn's disease  
*El Mouzan MI, Korolev KS, Al Mofarreh MA, Menon R, Winter HS, Al Sarkhy AA, Dowd SE, Al Barrag AM, Assiri AA*

**CORRECTION**

- 4517 Correction to "Maturity of associating liver partition and portal vein ligation for staged hepatectomy-derived liver regeneration in a rat model [*World J Gastroenterol* 2018 March 14; 24(10): 1107-1119]"  
*Tong YF, Cai XJ*

## Contents

*World Journal of Gastroenterology*  
Volume 24 Number 39 October 21, 2018

### ABOUT COVER

Editorial board member of *World Journal of Gastroenterology*, Saadi Berkane, MD, PhD, Chief Doctor, Professor, Internal Medicine, Hepatology and Gastroenterology, Bologhine Hospital, Algiers 16000, Algeria

### AIMS AND SCOPE

*World Journal of Gastroenterology* (*World J Gastroenterol*, *WJG*, print ISSN 1007-9327, online ISSN 2219-2840, DOI: 10.3748) is a peer-reviewed open access journal. *WJG* was established on October 1, 1995. It is published weekly on the 7<sup>th</sup>, 14<sup>th</sup>, 21<sup>st</sup>, and 28<sup>th</sup> each month. The *WJG* Editorial Board consists of 642 experts in gastroenterology and hepatology from 59 countries.

The primary task of *WJG* is to rapidly publish high-quality original articles, reviews, and commentaries in the fields of gastroenterology, hepatology, gastrointestinal endoscopy, gastrointestinal surgery, hepatobiliary surgery, gastrointestinal oncology, gastrointestinal radiation oncology, gastrointestinal imaging, gastrointestinal interventional therapy, gastrointestinal infectious diseases, gastrointestinal pharmacology, gastrointestinal pathophysiology, gastrointestinal pathology, evidence-based medicine in gastroenterology, pancreatology, gastrointestinal laboratory medicine, gastrointestinal molecular biology, gastrointestinal immunology, gastrointestinal microbiology, gastrointestinal genetics, gastrointestinal translational medicine, gastrointestinal diagnostics, and gastrointestinal therapeutics. *WJG* is dedicated to become an influential and prestigious journal in gastroenterology and hepatology, to promote the development of above disciplines, and to improve the diagnostic and therapeutic skill and expertise of clinicians.

### INDEXING/ABSTRACTING

*World Journal of Gastroenterology* (*WJG*) is now indexed in Current Contents<sup>®</sup>/Clinical Medicine, Science Citation Index Expanded (also known as SciSearch<sup>®</sup>), Journal Citation Reports<sup>®</sup>, Index Medicus, MEDLINE, PubMed, PubMed Central and Directory of Open Access Journals. The 2018 edition of Journal Citation Reports<sup>®</sup> cites the 2017 impact factor for *WJG* as 3.300 (5-year impact factor: 3.387), ranking *WJG* as 35<sup>th</sup> among 80 journals in gastroenterology and hepatology (quartile in category Q2).

### EDITORS FOR THIS ISSUE

Responsible Assistant Editor: Xiang Li  
Responsible Electronic Editor: Yan Huang  
Proofing Editor-in-Chief: Lian-Sheng Ma

Responsible Science Editor: Xue-Jiao Wang  
Proofing Editorial Office Director: Ze-Mao Gong

#### NAME OF JOURNAL

*World Journal of Gastroenterology*

#### ISSN

ISSN 1007-9327 (print)  
ISSN 2219-2840 (online)

#### LAUNCH DATE

October 1, 1995

#### FREQUENCY

Weekly

#### EDITORS-IN-CHIEF

Andrzej S Tarnawski, MD, PhD, DSc (Med),  
Professor of Medicine, Chief Gastroenterology, VA  
Long Beach Health Care System, University of California, Irvine, CA, 5901 E. Seventh Str., Long Beach, CA 90822, United States

#### EDITORIAL BOARD MEMBERS

All editorial board members resources online at <http://www.wjgnet.com/1007-9327/editorialboard.htm>

#### EDITORIAL OFFICE

Ze-Mao Gong, Director  
*World Journal of Gastroenterology*  
Baishideng Publishing Group Inc  
7901 Stoneridge Drive, Suite 501,  
Pleasanton, CA 94588, USA  
Telephone: +1-925-2238242  
Fax: +1-925-2238243  
E-mail: [editorialoffice@wjgnet.com](mailto:editorialoffice@wjgnet.com)  
Help Desk: <http://www.f6publishing.com/helpdesk>  
<http://www.wjgnet.com>

#### PUBLISHER

Baishideng Publishing Group Inc  
7901 Stoneridge Drive, Suite 501,  
Pleasanton, CA 94588, USA  
Telephone: +1-925-2238242  
Fax: +1-925-2238243  
E-mail: [bpgoffice@wjgnet.com](mailto:bpgoffice@wjgnet.com)  
Help Desk: <http://www.f6publishing.com/helpdesk>  
<http://www.wjgnet.com>

#### PUBLICATION DATE

October 21, 2018

#### COPYRIGHT

© 2018 Baishideng Publishing Group Inc. Articles published by this Open-Access journal are distributed under the terms of the Creative Commons Attribution Non-commercial License, which permits use, distribution, and reproduction in any medium, provided the original work is properly cited, the use is non commercial and is otherwise in compliance with the license.

#### SPECIAL STATEMENT

All articles published in journals owned by the Baishideng Publishing Group (BPG) represent the views and opinions of their authors, and not the views, opinions or policies of the BPG, except where otherwise explicitly indicated.

#### INSTRUCTIONS TO AUTHORS

Full instructions are available online at <http://www.wjgnet.com/bpg/gerinfo/204>

#### ONLINE SUBMISSION

<http://www.f6publishing.com>

## Retrospective Study

# Agitation thrombolysis combined with catheter-directed thrombolysis for the treatment of non-cirrhotic acute portal vein thrombosis

Chao-Yang Wang, Le-Qun Wei, Huan-Zhang Niu, Wan-Qin Gao, Tong Wang, Shun-Jun Chen

Chao-Yang Wang, Le-Qun Wei, Huan-Zhang Niu, Wan-Qin Gao, Tong Wang, Shun-Jun Chen, Department of Interventional Radiology, The First Affiliated Hospital, and College of Clinical Medicine of Henan University of Science and Technology, Luoyang 471000, Henan Province, China

ORCID number: Chao-Yang Wang (0000-0002-9740-2158); Le-Qun Wei (0000-0002-0213-3216); Huan-Zhang Niu (0000-0001-9844-9778); Wan-Qin Gao (0000-0002-7450-2914); Tong Wang (0000-0003-3573-1148); Shun-Jun Chen (0000-0002-4597-9131).

**Author contributions:** All authors helped to performed the research; Wang CY contributed to manuscript writing, performing procedures and data analysis; Wei LQ contributed to drafting conception and design, and data analysis; Niu HZ contributed to writing the manuscript, drafting conception and design; Gao WQ, Wang T and Chen SJ contributed to drafting conception and design.

**Institutional review board statement:** This study was reviewed and approved by the Ethics Committee of The First Affiliated Hospital, and College of Clinical Medicine of Henan University of Science and Technology.

**Informed consent statement:** Patients were not required to give informed consent to the study because the analysis used anonymous clinical data that were obtained after each patient agreed to treatment by written consent.

**Conflict-of-interest statement:** All authors declare no conflict-of interest related to this article.

**Data sharing statement:** No additional data are available.

**Open-Access:** This article is an open-access article which was selected by an in-house editor and fully peer-reviewed by external reviewers. It is distributed in accordance with the Creative Commons Attribution Non Commercial (CC BY-NC 4.0) license, which permits others to distribute, remix, adapt, build upon this work non-commercially, and license their derivative works on different terms, provided the original work is properly cited and

the use is non-commercial. See: <http://creativecommons.org/licenses/by-nc/4.0/>

**Manuscript source:** Unsolicited manuscript

**Correspondence to:** Huan-Zhang Niu, MD, Chief Doctor, Department of Interventional Radiology, The First Affiliated Hospital, and College of Clinical Medicine of Henan University of Science and Technology, No. 24 Jing Hua Road, Luoyang 471000, Henan Province, China. [niuhezhangsci@sina.com](mailto:niuhezhangsci@sina.com)  
Telephone: +86-379-64830771

**Received:** July 23, 2018

**Peer-review started:** July 23, 2018

**First decision:** August 30, 2018

**Revised:** September 13, 2018

**Accepted:** October 5, 2018

**Article in press:** October 5, 2018

**Published online:** October 21, 2018

## Abstract

### AIM

To evaluate the safety and efficacy of agitation thrombolysis (AT) combined with catheter-directed thrombolysis (CDT) for the treatment of non-cirrhotic acute portal vein thrombosis (PVT).

### METHODS

Nine patients with non-cirrhotic acute PVT who underwent AT combined with CDT were analyzed retrospectively. Portography was carried out *via* the transjugular intrahepatic portosystemic (commonly known as TIP) or percutaneous transhepatic (commonly known as PT) route, followed by AT combined with CDT. Complications of the procedure, and the changes in clinical symptoms, hemodynamics of the portal vein and liver function were recorded. Follow-up was scheduled at



1, 3 and 6 mo after treatment, and every 6 mo thereafter, or when the patients developed clinical symptoms related to PVT. Color Doppler ultrasound and contrast-enhanced computed tomography/magnetic resonance imaging were performed during the follow-up period to determine the condition of the portal vein.

## RESULTS

AT combined with CDT was successfully performed. The portal vein was reached *via* the TIP route in 6 patients, and *via* the PT route in 3 patients. All clinical symptoms were relieved or disappeared, with the exception of 1 patient who died of intestinal necrosis 9 d after treatment. Significant differences in the changes in portal vein hemodynamics were observed, including the maximum lumen occupancy of PVT, portal vein pressure and flow velocity between pre- and post-treatment ( $P < 0.05$ ). During the follow-up period, recurrence was observed in 1 patient at 19 mo after the procedure, and the portal vein was patent in the remaining patients.

## CONCLUSION

AT combined with CDT is a safe and effective method for the treatment of non-cirrhotic acute PVT.

**Key words:** Agitation thrombolysis; Catheter-directed thrombolysis; Portal vein thrombosis

© The Author(s) 2018. Published by Baishideng Publishing Group Inc. All rights reserved.

**Core tip:** Agitation is a common phenomenon in daily life, and can accelerate the rate of solute dissolution in a solvent. As the thrombus is porous in the acute stage, it can easily be broken into smaller fragments by agitation, which increases the contact area between the thrombus and thrombolytics, and increases the speed of thrombus dissolution. According to our research, agitation thrombolysis combined with catheter-directed thrombolysis is a safe and effective method for the treatment of non-cirrhotic acute portal vein thrombosis, with a good short- to middle-term efficacy. However, the long-term efficacy of agitation thrombolysis combined with catheter-directed thrombolysis in a large population requires further investigation.

Wang CY, Wei LQ, Niu HZ, Gao WQ, Wang T, Chen SJ. Agitation thrombolysis combined with catheter-directed thrombolysis for the treatment of non-cirrhotic acute portal vein thrombosis. *World J Gastroenterol* 2018; 24(39): 4482-4488 Available from: URL: <http://www.wjgnet.com/1007-9327/full/v24/i39/4482.htm> DOI: <http://dx.doi.org/10.3748/wjg.v24.i39.4482>

## INTRODUCTION

Non-cirrhotic portal vein thrombosis (PVT) has a low

incidence with a prevalence of approximately 1%, and partial obstruction of the portal vein is often clinically imperceptible<sup>[1]</sup>. However, complete obstruction due to acute thrombus can lead to a series of clinical symptoms, such as abdominal pain, ascites, and even intestinal necrosis. Common treatment options, including anticoagulation or indirect thrombolysis, are useful for relieving symptoms, but the outcome is unsatisfactory as most patients developed cavernous transformation of the portal vein due to incomplete recanalization<sup>[2,3]</sup>. Catheter-directed thrombolysis (CDT) *via* the transjugular intrahepatic portosystemic (TIP) or percutaneous transhepatic (PT) route is a minimally invasive method, which can dissolve the thrombus and relieve symptoms rapidly with a lower dose of thrombolytics<sup>[4]</sup>. In addition, agitation thrombolysis (AT) can break the thrombus into smaller fragments and accelerate the speed of thrombolysis<sup>[5]</sup>. The objective of this study was to evaluate the safety and efficacy of AT combined with CDT for the treatment of non-cirrhotic acute PVT.

## MATERIALS AND METHODS

### Patients

The data from 9 patients with non-cirrhotic acute PVT who underwent AT combined with CDT in our hospital between September 2015 and December 2017 were analyzed retrospectively. The patients consisted of 3 men and 6 women, with a mean age of  $47.9 \pm 10.6$  years. All patients met the following eligibility criteria: (1) the PVT was diagnosed definitively by color Doppler ultrasound (CDUS) and enhanced-contrast computed tomography (CT) or magnetic resonance imaging (MRI) (Figures 1A and 2A); (2) absence of massive periportal collaterals and features of liver cirrhosis in the imaging findings; and (3) excluded malignant tumor. In addition, the following information was collected for each patient before treatment: clinical symptoms, days from onset to operation, routine blood examination, liver function, etiology, the maximum lumen occupancy of PVT and the flow velocity of the portal vein measured by CDUS (Table 1).

### Treatment

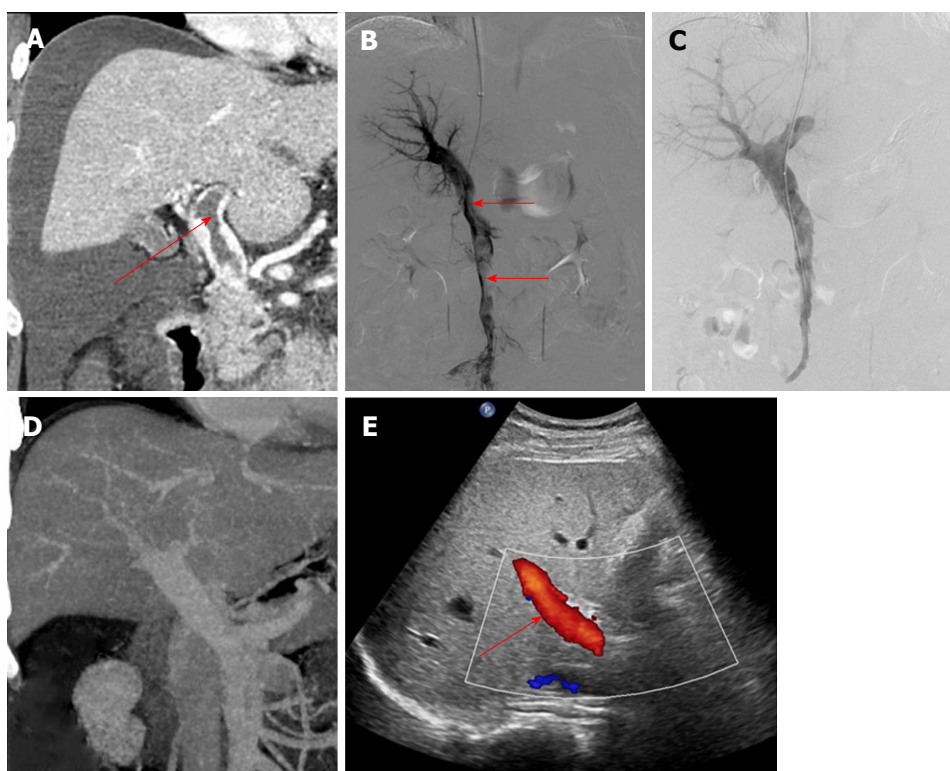
The procedures were performed under digital subtraction angiographic guidance (Artis zeego; Siemens, Munich, Germany). The choice of TIP or PT route depended on if the patients had ascites.

The portal vein was reached *via* the TIP route in 6 patients with ascites. A Rosch-Uchida set (Cook, Bloomington, IN, United States) was used to gain access to the portal vein branch from the hepatic vein under fluoroscopic guidance. When a 0.035-in hydrophilic guidewire (Terumo, Tokyo, Japan) reached the superior mesenteric vein or splenic vein in cooperation with a Cobra catheter (Cook), a pigtail catheter (Cook) was exchanged to perform portography (Figure 1B) and measure the portal pressure. The Rosch-Uchida sheath

**Table 1** Characteristics of the included patients

| Patient No. | Age (yr) | Sex | Etiology                  | Symptoms                                       | Time from onset to treatment (d) |
|-------------|----------|-----|---------------------------|--|----------------------------------|
| 1           | 29       | M   | Myelodysplastic syndromes | Abdominal pain, abdominal distension           | 4                                |
| 2           | 39       | F   | Protein S deficiency      | Abdominal pain, abdominal distension, vomiting | 11                               |
| 3           | 43       | M   | Myelodysplastic syndromes | Abdominal pain, vomiting                       | 14                               |
| 4           | 48       | F   | Protein C deficiency      | Abdominal pain, abdominal distension           | 5                                |
| 5           | 40       | F   | Nephrotic syndrome        | Abdominal pain, vomiting                       | 8                                |
| 6           | 53       | M   | Protein S deficiency      | Abdominal pain, diarrhea                       | 2                                |
| 7           | 61       | F   | Splenectomy after trauma  | Abdominal pain, abdominal distension, vomiting | 10                               |
| 8           | 36       | F   | Myelodysplastic syndromes | Abdominal pain, abdominal distension           | 5                                |
| 9           | 57       | F   | Unknown                   | Abdominal pain                                 | 16                               |

F: Female; M: Male.

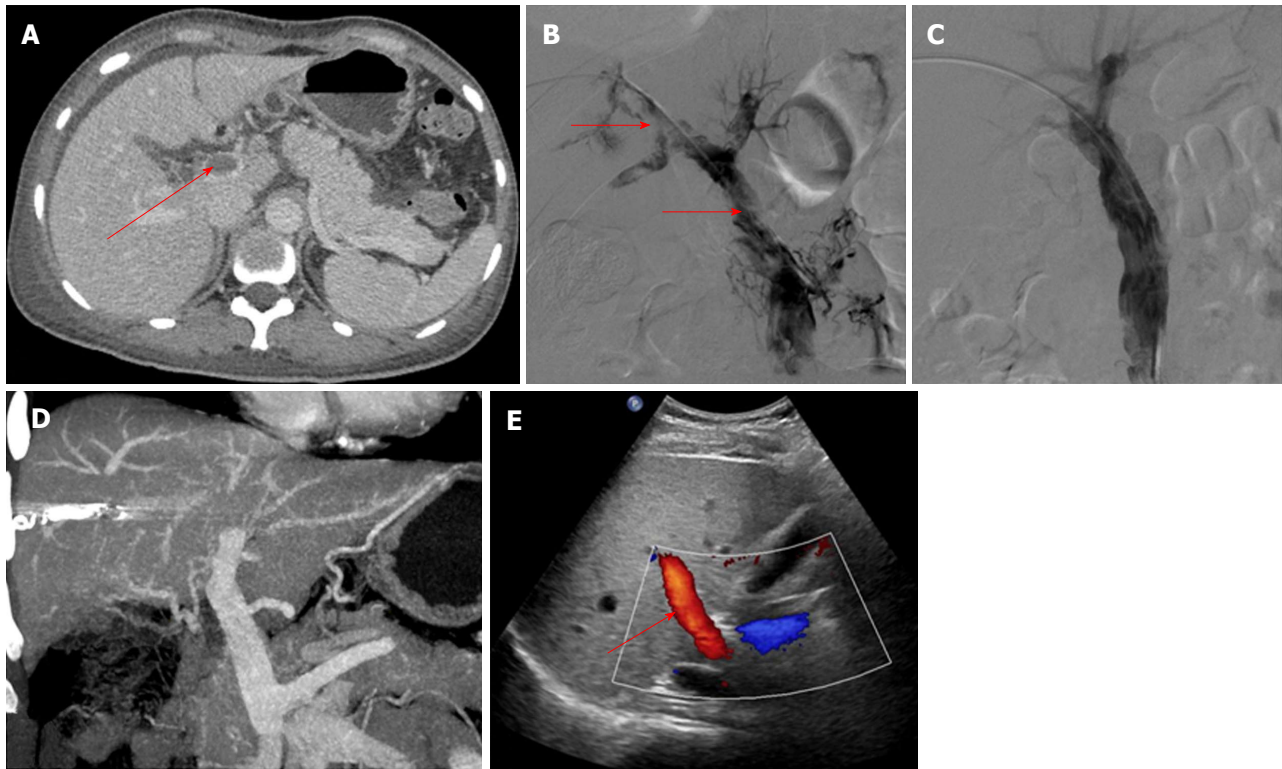


**Figure 1** A 29-year-old man had acute abdominal pain and distension for 4 d. A and B: Contrast-enhanced computed tomography (CT) and portography via the transjugular intrahepatic portosystemic route showed thrombus formation in the portal vein and superior mesenteric vein (arrow) with massive ascites; C: Portography after agitation thrombolysis and catheter-directed thrombolysis showed that the filling defect in the portal vein had decreased; D: Contrast-enhanced CT after surgery showed that the thrombus had disappeared completely; E: At 6 mo after treatment, color Doppler ultrasound showed smooth blood flow in the portal vein (arrow).

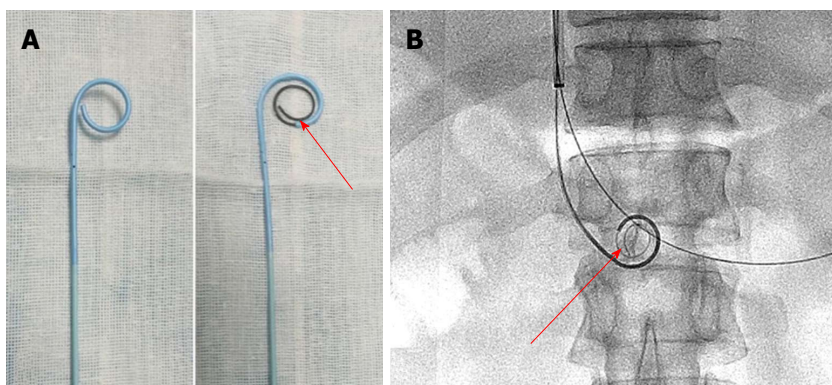
was then introduced into the portal vein following intrahepatic dilatation by a 6-mm balloon catheter (Boston Scientific, Natick, MA, United States). A pigtail catheter was inserted into the thrombus through the sheath, and a guidewire with a helical tip molded *in vitro* was advanced through the catheter (Figure 3). The guidewire and pigtail catheter were pushed and drawn together, and then rotated clockwise and anticlockwise alternatively, to agitate the thrombus into smaller fragments. In addition,  $2 \times 10^5$  IU urokinase (Tianjin Biochemical Pharmaceutical Co., Ltd., Tianjin,

China) was injected through the catheter by intermittent pulsatile delivery. The AT procedure was continued for approximately 10 min. The Rosch-Uchida sheath was then removed and the indwelling pigtail catheter was left in the PVT.

The portal vein was reached *via* the PT route in 3 patients without ascites. After successful puncture of a portal vein branch using a 22-gauge Chiba needle (Cook), a 6F coaxial dilator (Cook) was inserted into the portal vein. Then, a 5F sheath (Cook) and a pigtail catheter were exchanged. AT was performed after



**Figure 2** A 57-year-old woman had acute abdominal pain for 16 d. A and B: Contrast-enhanced computed tomography (CT) and portography via the percutaneous transhepatic route showed thrombus formation in the portal vein and superior mesenteric vein (arrow); C: Portography after agitation thrombolysis and catheter-directed thrombolysis showed that the filling defect in the portal vein had decreased; D: Contrast-enhanced CT after treatment showed that the thrombus had disappeared completely; E: At 12 mo after treatment, color Doppler ultrasound showed smooth blood flow in the portal vein (arrow).



**Figure 3** Pigtail catheter was inserted into the thrombus through the sheath, and a guidewire with a helical tip molded *in vitro* was advanced through the catheter. A: A pigtail catheter, and a guidewire with a helical tip (arrow) through the catheter *in vitro*; B: The catheter and guidewire in the portal vein (arrow) during agitation thrombolysis via the transjugular intrahepatic portosystemic route.

portography (Figure 2B), and the AT procedures were similar to those carried out *via* the TIP route. The indwelling pigtail catheter was left in the PVT.

Six hundred thousand IU of urokinase was infused continuously *via* the pigtail catheter each day, unless complications developed. In addition, 5000 IU of low molecular weight heparin was injected twice a day, and warfarin was administered after treatment at an initial dose of 5 mg. The low molecular weight heparin was discontinued when the international normalized ratio was maintained at 2.0-3.0, and warfarin was continued

for at least 12 mo. Portography was repeated every 24 h, and termination of CDT was based on the patency of the portal vein assessed by imaging and an obvious improvement in clinical symptoms. The portal vein pressure was measured again before the pigtail catheter was removed.

#### Follow-up study

Follow-up was scheduled at 1, 3 and 6 mo after treatment, and every 6 mo thereafter, or when the patients developed clinical symptoms related to PVT.



**Table 2 Results of treatment and follow-up**

| Patient No. | Treatment route | Duration of CDT (d) | Dose of urokinase ( $\times 10^6$ IU) | Complications                      | Follow-up time (mo) and results |
|-------------|-----------------|---------------------|---------------------------------------|------------------------------------|---------------------------------|
| 1           | TIP             | 2                   | 1.0                                   | Hematuria                          | 27/patent                       |
| 2           | PT              | 2                   | 1.4                                   | None                               | 23/patent                       |
| 3           | TIP             | -                   | -                                     | Death                              | Death                           |
| 4           | TIP             | 1                   | 0.8                                   | None                               | 31/patent                       |
| 5           | PT              | 3                   | 2.0                                   | Hemorrhage from the puncture tract | 5/patent                        |
| 6           | TIP             | 4                   | 2.6                                   | Subcapsular hematoma               | 22/reappearance                 |
| 7           | TIP             | 1                   | 0.8                                   | None                               | 9/patent                        |
| 8           | TIP             | 1                   | 0.8                                   | None                               | 12/patent                       |
| 9           | PT              | 3                   | 2.0                                   | Hemorrhage from the puncture tract | 18/patent                       |

PT: Percutaneous transhepatic; TIP: Transjugular intrahepatic portosystemic.

**Table 3 Changes in liver function and portal vein hemodynamics**

|  | Pre-treatment | Post-treatment | P value |
|--|---------------|----------------|---------|
| Albumin, g/L                           | 34.9 min      | 36.7 min       | 0.872   |
| Alanine aminotransferase, U/L          | 38.2 inea     | 33.6 inea      | 0.934   |
| Total bilirubin, sferase               | 17.9 lbi      | 17.4 lbi       | 0.991   |
| Flow velocity of the portal vein, cm/s | 4.2 tal       | 16.3 alv       | < 0.05  |
| Maximum lumen occupancy of PVT, %      | 78.2 occ      | 14.1 occ       | < 0.01  |
| Portal pressure, mmHg                  | 31.0 alp      | 14.1 alp       | < 0.05  |

PVT: Portal vein thrombosis.

Observations during follow-up mainly included clinical symptoms, routine blood examination, liver function and the condition of the portal vein evaluated by CDUS and contrast-enhanced CT/MRI. The end of follow-up was April 30, 2018.

### Statistical analysis

Data are shown as mean  $\pm$  standard deviation (SD). Paired Student's *t*-test was used to determine statistically significant differences between pre- and post-treatment values. Significance was set at  $P < 0.05$ . Statistical analysis was performed using SPSS (version 19.0; IBM, Armonk, NY, United States) software.

## RESULTS

### Treatment outcome

AT combined with CDT was successful in all patients. Immediate portography after AT showed greater blood flow than pre-AT. One patient treated *via* the TIP route underwent intestinal resection as a result of congestive necrosis 5 d after the procedure; however, this patient died 9 d later. In the remaining patients, CDT was continued for  $2.1 \pm 1.1$  d with a total dose of urokinase of  $0.8\text{--}2.6 \times 10^6$  IU (Table 2). All clinical symptoms were relieved or disappeared, except in 1 patient who continued to experience abdominal distension after meals. There was a significant difference in the maximum lumen occupancy of PVT (Figures 1C and 2C), portal vein pressure and flow velocity between pre- and

post-treatment ( $P < 0.05$ ). No significant differences in the changes in liver function, such as alanine aminotransferase, albumin and bilirubin were observed ( $P > 0.05$ ) (Table 3).

### Complications

One patient developed subcapsular hemorrhage during puncture of the portal vein *via* the TIP route and experienced a rapid heartbeat. The patient's vital signs were stable after erythrocyte transfusion, and CDT was started 3 d later. One patient *via* PT route had hematuria during CDT. These symptoms disappeared when urokinase was discontinued (Table 2).

### Follow-up

The follow-up period ranged from 5 mo to 31 mo. During this period, 1 patient who had been taking warfarin for 12 mo had an irregular poor appetite at 19 months after treatment, and contrast-enhanced CT showed that cavernous transformation of the portal vein had developed in the right portal vein. In the remaining patients, the portal vein was patent and none of the clinical symptoms related to PVT reappeared (Table 2). Liver function and routine blood examination were normal in all patients during follow-up (Figures 1D and E, 2D and E).

## DISCUSSION

PVT is mostly seen in liver cirrhosis, with a prevalence



ranging from 10% to 23%<sup>[6]</sup>. Non-cirrhotic PVT rarely occurs, with a prevalence of approximately 1%, and has an intimate relationship with inherited or acquired coagulation diseases, such as primary myeloproliferative disorders, Protein C/S deficiency, and abdominal surgery<sup>[7]</sup>. In addition to the etiology of PVT, it is particularly important to distinguish acute PVT from chronic PVT as the treatment is different. The American Association for the Study of Liver Diseases (commonly known as AASLD) describes acute PVT as the sudden formation of thrombus in the portal vein, and chronic PVT occurs when the obstructed portal vein is replaced by periportal collaterals bypassing the PVT<sup>[8]</sup>. However, the time boundary is not mentioned. In our study, acute PVT was diagnosed by clinical symptoms and the absence of massive periportal collaterals on imaging.

For non-cirrhotic acute PVT with obvious symptoms, the aim of treatment is recanalization of the obstructed portal vein and the prevention of complications. Common treatment methods including anticoagulation or indirect thrombolysis can be useful for relieving symptoms and recanalizing the portal vein. A meta-analysis involving 353 patients showed a significantly higher rate of recanalization following anticoagulation compared with the control group, which did not receive anticoagulation (71% vs 42%;  $P < 0.01$ )<sup>[2]</sup>. However, less than 20% of the patients achieved complete recanalization, and the others developed cavernous transformation of the portal vein due to incomplete recanalization, which can lead to chronic portal hypertension. Indirect thrombolysis *via* a peripheral vein or the superior mesenteric artery is less technically demanding, whereas the effect is limited as the thrombolytics are diverted from the patent branches or collaterals<sup>[3]</sup>. In addition, a high dose of thrombolytics may increase the risk of gastrointestinal hemorrhage.

CDT is an effective treatment for acute thrombus, which can enhance the efficacy of thrombolytics at a lower dose compared to indirect thrombolysis<sup>[4]</sup>. CDT *via* the PT route is relatively simple to perform, but it is not suitable for patients with massive ascites as it may cause hemorrhage through the PT tract during subsequent anticoagulation or thrombolysis. In addition, patients often felt pain when breathing as the indwelling catheter traversed the hepatic capsule. CDT *via* the TIP route can avoid these complications, but puncturing the portal vein from the hepatic vein is more difficult than using the PT route. Chen *et al*<sup>[9]</sup> reported that direct portography *via* the PT route, then a balloon catheter inflated with contrast medium to 80% of its volume positioned at the site of the bifurcation of the right and left portal veins can improve the success rate. Wang *et al*<sup>[10]</sup> reported the successful treatment of 12 patients with acute PVT treated with aspiration combined with CDT *via* the TIP route. The CDT time was 7.6 h. Eight patients achieved complete recanalization and four patients had partial recanalization, and AT combined with CDT was more effective than anticoagulation or indirect thrombolysis.

Agitation is a common phenomenon in daily life,

and can accelerate the rate of solute dissolution in a solvent. AT was first reported by Ding *et al*<sup>[5]</sup> following the successful treatment of acute inferior vein thrombus in Budd-Chiari syndrome, which showed a good long-term efficacy<sup>[11]</sup>, but has not yet been reported in the treatment of PVT. As the thrombus is porous in the acute stage, it can easily be broken into smaller fragments by agitation, which increases the contact area between the thrombus and thrombolytics, and increases the speed of thrombus dissolution. The shape of the catheter tip is important. In this study, the pigtail catheter was chosen as an agitator, as it did not injure the vessel wall and resulted in greater fragmentation of the thrombus during rotation. In addition, a guidewire with a helical tip can enhance the fracture resistance of the pigtail catheter, and increase the range of agitation. Compared with other methods, such as endovascular aspiration or mechanical thrombectomy<sup>[12]</sup>, AT is simpler and safer, with less blood loss. In our study, all the patients had a smoother blood flow after treatment than before treatment, and the duration of CDT was shorter and the rate of recanalization was higher than those reported by Wang *et al*<sup>[10]</sup>.

There are some limitations in this study. Firstly, the study was retrospective, with a limited number of cases; therefore, the data may have been affected by various potential biases. Secondly, puncture of the portal vein is difficult to perform under fluoroscopic guidance, and required extensive experience and a good understanding of imaging data including contrast-enhanced CT/MRI; thus, the treatment is restricted to University Hospitals.

In conclusion, AT combined with CDT is a safe and effective method for the treatment of non-cirrhotic acute PVT, with a good short- to middle-term efficacy. However, the long-term efficacy of AT combined with CDT in a large population requires further investigation.

## ARTICLE HIGHLIGHTS

### Research background

Non-cirrhotic portal vein thrombosis (PVT) has a low incidence, with a prevalence of approximately 1%, and partial obstruction of the portal vein is often clinically imperceptible. However, complete obstruction due to acute thrombus can lead to a series of clinical symptoms, such as abdominal pain, ascites, and even intestinal necrosis. Common treatment opinions including anticoagulation or indirect thrombolysis are useful for relieving symptoms, but the outcome is unsatisfactory as most patients develop into cavernous transformation of the portal vein due to incomplete recanalization.

### Research motivation

Catheter-directed thrombolysis (CDT) *via* the transjugular intrahepatic portosystemic (commonly known as TIP) or percutaneous transhepatic (PT) route is a minimally invasive method, which can dissolve the thrombus and relieve symptoms rapidly with a lower dose of thrombolytics. In addition, agitation thrombolysis (AT) can break the thrombus into smaller fragments and accelerate the speed of thrombolysis.

### Research objectives

The objective of this study was to evaluate the safety and efficacy of AT combined with CDT for the treatment of non-cirrhotic acute PVT.

## Research methods

Nine patients with non-cirrhotic acute PVT who underwent AT combined with CDT via TIP or percutaneous transhepatic route were analyzed retrospectively. AT had not been reported for the treatment of PVT so far. The changes in clinical symptoms, hemodynamics of the portal vein and liver function were recorded and followed up to evaluate the safety and efficacy.

## Research results

According to our research, AT combined with CDT is a safe and effective method for the treatment of non-cirrhotic acute PVT, with a good short- to middle-term efficacy. However, the long-term efficacy of AT combined with CDT in a large population requires further investigation.

## Research conclusions

Agitation is a common phenomenon in daily life, and can accelerate the rate of solute dissolution in a solvent. AT was first reported for the treatment of acute inferior vein thrombus in Budd-Chiari syndrome, which showed good long-term efficacy, but has not yet been reported in the treatment of PVT. As the thrombus is porous in the acute stage, it can easily be broken into smaller fragments by agitation, which increases the contact area between the thrombus and thrombolytics, and increases the speed of thrombus dissolution. Compared with other methods, such as endovascular aspiration or mechanical thrombectomy, AT is simpler and safer, with less blood loss.

## Research perspectives

The shape of the catheter tip is important. In this study, the pigtail catheter was chosen as an agitator, as it did not injure the vessel wall and resulted in greater fragmentation of the thrombus during rotation. In addition, a guidewire with a helical tip can enhance the fracture resistance of the pigtail catheter, and increase the range of agitation. The future research we will focus on involves the long-term efficacy of AT combined with CDT in a large population.

## REFERENCES

- 1 **Basit SA**, Stone CD, Gish R. Portal vein thrombosis. *Clin Liver Dis* 2015; **19**: 199-221 [PMID: 25454305 DOI: 10.1016/j.cld.2014.09.012]
- 2 **Loffredo L**, Pastori D, Farcomeni A, Violi F. Effects of Anticoagulants in Patients With Cirrhosis and Portal Vein Thrombosis: A Systematic Review and Meta-analysis. *Gastroenterology* 2017; **153**: 480-487.e1 [PMID: 28479379 DOI: 10.1053/j.gastro.2017.04.042]
- 3 **Liu K**, Li WD, Du XL, Li CL, Li XQ. Comparison of Systemic Thrombolysis Versus Indirect Thrombolysis via the Superior

- Mesenteric Artery in Patients with Acute Portal Vein Thrombosis. *Ann Vasc Surg* 2017; **39**: 264-269 [PMID: 27671456 DOI: 10.1016/j.avsg.2016.06.029]
- 4 **Avgerinos ED**, Chaer RA. The ATTRACTiveness of catheter-directed thrombolysis. *J Vasc Surg Venous Lymphat Disord* 2018; **6**: 303 [PMID: 29661361 DOI: 10.1016/j.jvsv.2018.02.002]
- 5 **Ding PX**, Li YD, Han XW, Wu G. Agitation thrombolysis for fresh iatrogenic IVC thrombosis in patients with Budd-Chiari syndrome. *J Vasc Surg* 2010; **52**: 782-784 [PMID: 20471769 DOI: 10.1016/j.jvs.2010.02.016]
- 6 **Harding DJ**, Perera MT, Chen F, Olliff S, Tripathi D. Portal vein thrombosis in cirrhosis: Controversies and latest developments. *World J Gastroenterol* 2015; **21**: 6769-6784 [PMID: 26078553 DOI: 10.3748/wjg.v21.i22.6769]
- 7 **Cruz-Ramón V**, Chinchilla-López P, Ramírez-Pérez O, Aguilar-Olivos NE, Alva-López LF, Fajardo-Ordoñez E, Ponciano-Rodríguez G, Northup PG, Intagliata N, Caldwell SH, Qi X, Méndez-Sánchez N. Thrombosis of the Portal Venous System in Cirrhotic vs. Non-Cirrhotic Patients. *Ann Hepatol* 2018; **17**: 476-481 [PMID: 29735798 DOI: 10.5604/013001.0011.7392]
- 8 **DeLeve LD**, Valla DC, Garcia-Tsao G; American Association for the Study Liver Diseases. Vascular disorders of the liver. *Hepatology* 2009; **49**: 1729-1764 [PMID: 19399912 DOI: 10.1002/hep.22772]
- 9 **Chen Y**, Ye P, Li Y, Ma S, Zhao J, Zeng Q. Percutaneous transhepatic balloon-assisted transjugular intrahepatic portosystemic shunt for chronic, totally occluded, portal vein thrombosis with symptomatic portal hypertension: procedure technique, safety, and clinical applications. *Eur Radiol* 2015; **25**: 3431-3437 [PMID: 25903717 DOI: 10.1007/s00330-015-3777-1]
- 10 **Wang MQ**, Liu FY, Duan F, Wang ZJ, Song P, Fan QS. Acute symptomatic mesenteric venous thrombosis: treatment by catheter-directed thrombolysis with transjugular intrahepatic route. *Abdom Imaging* 2011; **36**: 390-398 [PMID: 20652243 DOI: 10.1007/s00261-010-9637-1]
- 11 **Ding PX**, He X, Han XW, Zhang Y, Wu Y, Liang XX, Liu C. An Individualised Strategy and Long-Term Outcomes of Endovascular Treatment of Budd-Chiari Syndrome Complicated by Inferior Vena Cava Thrombosis. *Eur J Vasc Endovasc Surg* 2018; **55**: 545-553 [PMID: 29478911 DOI: 10.1016/j.ejvs.2017.12.016]
- 12 **Jun KW**, Kim MH, Park KM, Chun HJ, Hong KC, Jeon YS, Cho SG, Kim JY. Mechanical thrombectomy-assisted thrombolysis for acute symptomatic portal and superior mesenteric venous thrombosis. *Ann Surg Treat Res* 2014; **86**: 334-341 [PMID: 24949327 DOI: 10.4174/astr.2014.86.6.334]

**P- Reviewer:** Eleftheriadis NP **S- Editor:** Ma RY  
**L- Editor:** Filipodia **E- Editor:** Huang Y





Published by **Baishideng Publishing Group Inc**  
7901 Stoneridge Drive, Suite 501, Pleasanton, CA 94588, USA  
Telephone: +1-925-223-8242  
Fax: +1-925-223-8243  
E-mail: [bpgoffice@wjgnet.com](mailto:bpgoffice@wjgnet.com)  
Help Desk: <http://www.f6publishing.com/helpdesk>  
<http://www.wjgnet.com>



ISSN 1007-9327

