

World Journal of *Gastroenterology*

World J Gastroenterol 2019 June 14; 25(22): 2699-2832



**OPINION REVIEW**

- 2699** Which factors determine exocrine pancreatic dysfunction in diabetes mellitus?
Altay M

REVIEW

- 2706** Proton pump inhibitors and dysbiosis: Current knowledge and aspects to be clarified
Bruno G, Zaccari P, Rocco G, Scalese G, Panetta C, Porowska B, Pontone S, Severi C
- 2720** Diagnosis and therapeutic strategies for small bowel vascular lesions
Sakai E, Ohata K, Nakajima A, Matsuhashi N

MINIREVIEWS

- 2734** Advanced diagnostics for pancreatic cysts: Confocal endomicroscopy and molecular analysis
Durkin C, Krishna SG
- 2743** Long-lasting discussion: Adverse effects of intraoperative blood loss and allogeneic transfusion on prognosis of patients with gastric cancer
Nakanishi K, Kanda M, Kodera Y

ORIGINAL ARTICLE**Basic Study**

- 2752** MiR-34a overexpression enhances the inhibitory effect of doxorubicin on HepG2 cells
Zheng SZ, Sun P, Wang JP, Liu Y, Gong W, Liu J
- 2763** Long noncoding RNA HOXA11-AS promotes gastric cancer cell proliferation and invasion *via* SRSF1 and functions as a biomarker in gastric cancer
Liu Y, Zhang YM, Ma FB, Pan SR, Liu BZ
- 2776** Sp1 contributes to overexpression of stanniocalcin 2 through regulation of promoter activity in colon adenocarcinoma
Li JB, Liu ZX, Zhang R, Ma SP, Lin T, Li YX, Yang SH, Zhang WC, Wang YP

Retrospective Study

- 2788** Increased risk of atrial fibrillation in patients with inflammatory bowel disease: A nationwide population-based study
Choi YJ, Choi EK, Han KD, Park J, Moon I, Lee E, Choe WS, Lee SR, Cha MJ, Lim WH, Oh S

Clinical Trials Study

- 2799** Effects of early enteral nutrition on Th17/Treg cells and IL-23/IL-17 in septic patients
Sun JK, Zhang WH, Chen WX, Wang X, Mu XW

SYSTEMATIC REVIEWS

- 2809** Autoimmune hepatitis treatment in the elderly: A systematic review
Durazzo M, Lupi G, Scandella M, Ferro A, Gruden G

META-ANALYSIS

- 2819** Mini-invasive *vs* open resection of colorectal cancer and liver metastases: A meta-analysis
Ye SP, Qiu H, Liao SJ, Ai JH, Shi J

ABOUT COVER

Editorial board member of *World Journal of Gastroenterology*, Andrew Stewart Day, MD, Professor, Paediatrics Department, University of Otago, Christchurch 8041, New Zealand

AIMS AND SCOPE

World Journal of Gastroenterology (*World J Gastroenterol*, *WJG*, print ISSN 1007-9327, online ISSN 2219-2840, DOI: 10.3748) is a peer-reviewed open access journal. The *WJG* Editorial Board consists of 642 experts in gastroenterology and hepatology from 59 countries.

The primary task of *WJG* is to rapidly publish high-quality original articles, reviews, and commentaries in the fields of gastroenterology, hepatology, gastrointestinal endoscopy, gastrointestinal surgery, hepatobiliary surgery, gastrointestinal oncology, gastrointestinal radiation oncology, etc. The *WJG* is dedicated to become an influential and prestigious journal in gastroenterology and hepatology, to promote the development of above disciplines, and to improve the diagnostic and therapeutic skill and expertise of clinicians.

INDEXING/ABSTRACTING

The *WJG* is now indexed in Current Contents®/Clinical Medicine, Science Citation Index Expanded (also known as SciSearch®), Journal Citation Reports®, Index Medicus, MEDLINE, PubMed, PubMed Central, Scopus and Directory of Open Access Journals. The 2018 edition of Journal Citation Report® cites the 2017 impact factor for *WJG* as 3.300 (5-year impact factor: 3.387), ranking *WJG* as 35th among 80 journals in gastroenterology and hepatology (quartile in category Q2).

RESPONSIBLE EDITORS FOR THIS ISSUE

Responsible Electronic Editor: Yan-Liang Zhang

Proofing Production Department Director: Yun-Xiaojian Wu

NAME OF JOURNAL

World Journal of Gastroenterology

ISSN

ISSN 1007-9327 (print) ISSN 2219-2840 (online)

LAUNCH DATE

October 1, 1995

FREQUENCY

Weekly

EDITORS-IN-CHIEF

Subrata Ghosh, Andrzej S Tarnawski

EDITORIAL BOARD MEMBERS

<http://www.wjgnet.com/1007-9327/editorialboard.htm>

EDITORIAL OFFICE

Ze-Mao Gong, Director

PUBLICATION DATE

June 14, 2019

COPYRIGHT

© 2019 Baishideng Publishing Group Inc

INSTRUCTIONS TO AUTHORS

<https://www.wjgnet.com/bpg/gerinfo/204>

GUIDELINES FOR ETHICS DOCUMENTS

<https://www.wjgnet.com/bpg/GerInfo/287>

GUIDELINES FOR NON-NATIVE SPEAKERS OF ENGLISH

<https://www.wjgnet.com/bpg/gerinfo/240>

PUBLICATION MISCONDUCT

<https://www.wjgnet.com/bpg/gerinfo/208>

ARTICLE PROCESSING CHARGE

<https://www.wjgnet.com/bpg/gerinfo/242>

STEPS FOR SUBMITTING MANUSCRIPTS

<https://www.wjgnet.com/bpg/GerInfo/239>

ONLINE SUBMISSION

<https://www.f6publishing.com>



Advanced diagnostics for pancreatic cysts: Confocal endomicroscopy and molecular analysis

Claire Durkin, Somashekar G Krishna

ORCID number: Claire Durkin (0000-0002-9532-0765); Somashekar G Krishna (0000-0001-5748-7890).

Author contributions: Durkin C performed research and wrote the review article. Krishna SG performed research, wrote the review article, and finalized the paper.

Conflict-of-interest statement: The authors disclose no conflicts of interest.

Open-Access: This is an open-access article that was selected by an in-house editor and fully peer-reviewed by external reviewers. It is distributed in accordance with the Creative Commons Attribution Non Commercial (CC BY-NC 4.0) license, which permits others to distribute, remix, adapt, build upon this work non-commercially, and license their derivative works on different terms, provided the original work is properly cited and the use is non-commercial. See: <http://creativecommons.org/licenses/by-nc/4.0/>

Manuscript source: Invited manuscript

Received: February 6, 2019

Peer-review started: February 6, 2019

First decision: February 26, 2019

Revised: April 29, 2019

Accepted: May 8, 2019

Article in press: May 8, 2019

Published online: June 14, 2019

P-Reviewer: Chiu CC, Ghiorzo P, Mastoraki A

S-Editor: Ma RY

Claire Durkin, Somashekar G Krishna, Division of Gastroenterology, Hepatology, and Nutrition, The Ohio State University College of Medicine, Columbus, OH 43210, United States

Corresponding author: Somashekar G Krishna, MD, Associate Professor, Doctor, Sections of Pancreatic Disorders and Advanced Endoscopy, Division of Gastroenterology, Hepatology and Nutrition, The Ohio State University College of Medicine, 395 W. 12th Avenue, Suite 262, Columbus, OH 43210, United States. somashekar.krishna@osumc.edu

Telephone: +1-614-2936255

Fax: +1-614-2938518

Abstract

Technological advances and the widespread use of medical imaging have led to an increase in the identification of pancreatic cysts in patients who undergo cross-sectional imaging. Current methods for the diagnosis and risk-stratification of pancreatic cysts are suboptimal, resulting in both unnecessary surgical resection and overlooked cases of neoplasia. Accurate diagnosis is crucial for guiding how a pancreatic cyst is managed, whether with surveillance for low-risk lesions or surgical resection for high-risk lesions. This review aims to summarize the current literature on confocal endomicroscopy and cyst fluid molecular analysis for the evaluation of pancreatic cysts. These recent technologies are promising adjuncts to existing approaches with the potential to improve diagnostic accuracy and ultimately patient outcomes.

Key words: Pancreatic cysts; Confocal endomicroscopy; Molecular analysis; Molecular biomarkers; Pancreatic cancer

©The Author(s) 2019. Published by Baishideng Publishing Group Inc. All rights reserved.

Core tip: Current methods for the diagnosis and risk-stratification of pancreatic cysts are suboptimal, resulting in both unnecessary surgical resection and overlooked cases of neoplasia. Novel technologies such as confocal endomicroscopy and cyst fluid molecular analysis are promising adjuncts to the existing standard of care for the management of pancreatic cysts with the potential to improve diagnostic accuracy and ultimately patient outcomes.

Citation: Durkin C, Krishna SG. Advanced diagnostics for pancreatic cysts: Confocal endomicroscopy and molecular analysis. *World J Gastroenterol* 2019; 25(22): 2734-2742
URL: <https://www.wjgnet.com/1007-9327/full/v25/i22/2734.htm>

L-Editor: A
E-Editor: Zhang YL



DOI: <https://dx.doi.org/10.3748/wjg.v25.i22.2734>

INTRODUCTION

Diagnosing and managing pancreatic cysts is a common problem within gastroenterology. The number of pancreatic cysts identified has grown over the last several decades, largely due to improved detection during imaging studies. Studies show that the prevalence of pancreatic cysts may be even higher than previously thought with about 2.4%-19.6% of all patients who undergo abdominal magnetic resonance imaging (MRI) and 2.6% who undergo computed tomography (CT) having detectable pancreatic cysts^[1-4].

Pancreatic cysts can be classified as either mucinous or non-mucinous lesions, each with distinct characteristics and potential for malignancy (Table 1). Mucinous cysts include intraductal papillary mucinous neoplasms (IPMN) and mucinous cystic neoplasms (MCN), while non-mucinous cysts include serous cystadenoma (SCA), pseudocysts, cystic neuroendocrine tumors (cystic-NETs), and solid pseudopapillary neoplasm (SPN).

In general, mucinous pancreatic cysts have the potential for malignant transformation, while non-mucinous SCAs are typically benign neoplasms. Therefore, it is crucial to accurately diagnose and differentiate pancreatic lesions, as it will impact future prognosis and treatment plans. The evaluation of pancreatic cysts is a multimodality approach, utilizing a combination of clinical history, demographics, radiographic and endoscopic ultrasound (EUS) features, cytology, and cyst fluid analysis [*i.e.*, carcinoembryonic antigen (CEA) and amylase]^[5]. Despite these multidisciplinary techniques, distinguishing pancreatic cyst type prior to surgical intervention remains difficult and there is a need for improved diagnostic strategies.

Summary of current guidelines

Multiple guidelines have been developed to aid the diagnosis and treatment of pancreatic cysts, including the International Consensus Guidelines (Sendai 2006, Fukuoka 2012, and Fukuoka 2017), the American Gastroenterological Association (AGA) 2015 guidelines, and clinical guidelines from the American College of Gastroenterology^[6-10]. Current guidelines recommend surgical resection of all large cysts (> 4 cm), MCNs (malignancy risk: 17.5%), main duct (MD)-IPMNs (malignancy risk: 61%) and branch duct (BD)-IPMNs with high-risk features (obstructive jaundice, dilated main pancreatic duct > 1 cm, solid enhancing intracystic nodule; malignancy risk: 25%)^[7]. A summary of these guidelines can be found in Table 2.

In a systemic review of the clinical utility of Sendai and Fukuoka Guidelines, both had lower positive predictive value (PPV) (Sendai: 11%-52%; Fukuoka 27%-100%) for worrisome and/or high-risk criteria to predict malignancy in surgical resected IPMNs. While further enhancements are needed to the current consensus guidelines to improve the management of patients with mucinous cysts, additional imaging modalities, such as endoscopic ultrasound needle-based confocal endomicroscopy (EUS-nCLE), and novel pancreatic molecular biomarkers are promising new technologies that may prove crucial in how pancreatic cysts are differentiated and treated. This review aims to summarize the current literature on confocal endomicroscopy and cyst fluid molecular analysis for the evaluation of pancreatic cysts.

NOVEL DIAGNOSTICS

Imaging of pancreatic cysts

Confocal laser endomicroscopy is a novel technology that allows for real-time microscopic imaging of intracystic epithelium *in vivo*. An endoscopic and mini probe-based modality, CLE probes can be introduced into pancreatic cysts through a 19-gauge FNA needle to allow for high magnification and resolution imaging of cyst epithelium during EUS. Intravenous fluorescein is used during EUS-nCLE to further enhance blood vessels and other structures within the pancreatic cysts. The indication for EUS-nCLE is the evaluation of pancreatic cysts where fine needle aspiration is being considered, typically for lesions measuring ≥ 2 cm in size. EUS-nCLE is contraindicated in patients with allergic reactions to fluorescein.

Pancreatic cysts have characteristic patterns on EUS-nCLE imaging that aid in their

Table 1 Classification of pancreatic cysts**(A) Mucinous Cysts**

1 Intraductal Papillary Mucinous Neoplasm (IPMN)

Branch Duct IPMN

Mixed Duct IPMN

2 Mucinous Cystic Neoplasm (MCN)

(B) Non-mucinous Cysts

Serosus Cystadenoma (SCA)

Solid Pseudopapillary Tumor (SPT)

Cystic Neuroendocrine Tumor (Cystic-NET)

Squamous-Lined Cysts

Epidermoid Cysts

Lymphoepithelial Cysts

Pseudocysts

(C) Other malignant Cysts

Ductal Adenocarcinoma with Cystic Degeneration

Acinar Cell Cystadenocarcinoma

Cystic Degeneration of Metastatic Lesions to the Pancreas

IPMN: Intraductal papillary mucinous neoplasm.

identification and classification. Figure 1 summarizes pancreatic cysts types and their associated imaging patterns on EUS-nCLE. These images are broadly classified into epithelial and vascular patterns^[11,12]. IPMNs are characterized by their finger-like papillae, while MCNs can be identified by their singular or layered epithelial bands^[11,13,14]. SCAs have fern-like patterns with a superficial dense network of vessels^[14,15]. Pseudocysts appear as bright particles against a dark background, corresponding to inflammatory cells without the presence of a true cysts wall or vascularity^[11]. Cystic-NETs and SPNs have a trabecular pattern with high cellularity, appearing as nests or cords of cells separated by fibrous bands^[16]. Rarer pancreatic cyst types, for example, lymphoepithelial cysts, have also been described in case reports^[17]. Both *in vivo* and *ex vivo* nCLE images have been validated and compared with histopathology for IPMNs, MCNs, SCAs, and Cystic-NETs^[16,18].

Several innovative studies have established the safety, feasibility, and ability of nCLE to differentiate pancreatic cyst types. These include the INSPECT, DETECT, CONTACT-1 and -2, and INDEX trials. The INSPECT study (2013) established the safety and demonstrated feasibility of nCLE in differentiating mucinous pancreatic cysts. This study also identified IPMNs as having papillary structures on nCLE^[13]. The DETECT study (2015) evaluated the technical feasibility, safety, and diagnostic capabilities of cystoscopy and nCLE for diagnosing pancreatic cysts, showing that this combination of novel imaging modalities has a strong concordance with the definitive diagnosis of pancreatic cystic neoplasms^[19]. The CONTACT-1 study (2015) evaluated solitary pancreatic cysts in 31 patients using EUS-nCLE. They found that SCAs had a characteristic pattern of superficial vascular networks on nCLE, which correlated microscopically to dense networks of subepithelial capillaries^[15]. The CONTACT-2 study (2016) described nCLE patterns for MCNs, pseudocysts, and cystic-NETs that correlated with histology. These cysts appeared as epithelial bands, bright particles on a dark background, and black nests of cells separated by white fibrous bands under nCLE, respectively^[11]. The INDEX study (2016) validated previously described nCLE findings for pancreatic cysts, comparing *in vivo* and *ex vivo* CLE to surgical histopathology, and showed substantial interobserver agreement and intraobserver reliability for differentiating mucinous pancreatic cyst types in blinded nCLE observers^[12,16,20].

In the most recent update of the multicenter CONTACT-2 study (2018), among 78 subjects with reference diagnoses, the sensitivity, specificity, PPV, negative predictive value (NPV) for EUS-nCLE to diagnose premalignant pancreatic cysts (MCNs, BD-IPMNs, cystic-NETs, SPNs, and cystic lymphoma) from benign lesions were 96%, 95%, 98%, and 91%, respectively. To differentiate mucinous from non-mucinous lesions, the sensitivity, specificity, PPV, and NPV were 95%, 100%, 100% and 94% respectively^[21].

Procedural expertise for optimal image acquisition during EUS-nCLE can be obtained by directly observing an expert EUS-nCLE in dedicated workshops and

Table 2 Treatment and surveillance guidelines for pancreatic cysts

Guideline	Recommendations
Sendai 2006 ^[8]	<p>Recommended surgical resection if any of the following lesions were suspected:</p> <p>MCNs</p> <p>Main duct IPMNs</p> <p>Mixed duct IPMNs</p> <p>Also recommended surgical resection also based on:</p> <p>Clinical symptoms</p> <p>Dilated pancreatic duct (≥ 6mm)</p> <p>Intracystic mural nodules</p> <p>Positive cytology ^[8]</p>
Fukuoka 2012 ^[6]	<p>Recommended surgical resection for high-risk criteria:</p> <p>Dilated pancreatic duct (≥ 10mm)</p> <p>Presence of an enhancing solid component</p> <p>Obstructive jaundice ^[6]</p>
American Gastroenterological Association (AGA) 2015 ^[9]	<p>Recommended EUS-FNA if 2 out of 3 of the following high-risk features were present:</p> <p>Size ≥ 3 cm</p> <p>Dilated main pancreatic duct</p> <p>Solid component</p> <p>Recommended surgical resection if a cyst had both of the following:</p> <p>Solid component</p> <p>Dilated pancreatic duct and/or concerning features on EUS-FNA ^[9]</p>
Fukuoka 2017 ^[7]	<p>Enhancing mural nodule is a high risk feature if measuring ≥ 5 mm</p> <p>Added surveillance guidelines for BD-IPMN, noting presence of lymphadenopathy, increased serum CA19-9 and cyst growth rate >5 mm in diameter over 2 years as “worrisome features” ^[7]</p>

MCN: Mucinous cystic neoplasm; IPMN: Intraductal papillary mucinous neoplasm; BD-IPMN: Branched duct intraductal papillary mucinous neoplasm; EUS: Endoscopic ultrasound; FNA: Fine needle aspiration.

subsequently performing at least 10 cases. Since there are no formal studies to address high-quality image acquisition, the limited case requirement is only an opinion among experts.

Molecular biomarkers for pancreatic cysts

In addition to recent imaging technologies, DNA-based molecular analysis of cyst fluid has also become a useful tool for diagnosing pancreatic cysts. Epithelial cells that line pancreatic cysts shed DNA into cyst fluid through cell lysis or exfoliation. This DNA can be analyzed for genetic alterations associated with a particular diagnosis and prognosis^[22,23]. Multiple studies have identified molecular markers associated with each of the major types of pancreatic cysts and genetic profiles that predict progression into adenocarcinoma^[22,24,25]. Several aspects of molecular analysis are important for diagnosis and prognostication: DNA quantity and quality, genetic mutations, and tumor suppressor genes or loss of heterozygosity (LOH).

The amount of DNA contained in pancreatic cysts fluid can be determined through spectrophotometry. When a sample is exposed to ultraviolet light in a spectrophotometer, a photo-detector measures the quantity of nucleic acid in the sample and calculates its DNA concentration using the optical density ratio at certain wavelengths (260 nm:280 nm). In a prospective, multicenter study of 113 patients, elevated concentrations of DNA within pancreatic cysts were associated with a diagnosis of malignancy^[26]. Furthermore, while traditional techniques used to analyze pancreatic cyst fluid, such as cytopathology and carcinoembryonic antigen (CEA), cannot be optimally performed due to the inadequate volume of cells or fluid, pancreatic cysts typically contain enough DNA to evaluate for mutations^[26,27].

LOH is when there is a loss of one of the copies of a gene and its surrounding chromosomal region. When there is LOH of a tumor suppressor gene, it can result in loss of tumor suppressor activity and subsequent development of unregulated growth. This can be detected using microsatellite markers linked to tumor suppressor genes and correlates to malignancy^[28].

A summary of endoscopic ultrasound needle-base confocal laser endomicroscopy image patterns for pancreatic cysts types

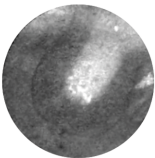
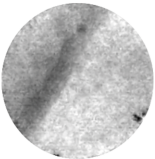
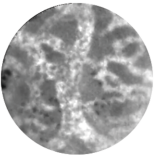
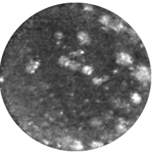
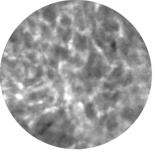
Pancreatic cyst type	Figure	Pattern
Intraductal papillary mucinous neoplasm		Papillary: Finger-like projections of varying length ^[11,20] . Rope-ladder or branched vascularity ^[12] .
Mucinous cystic neoplasm		Epithelial bands: Single or multiple layers of epithelium arranged in layers ^[11] . Rope-ladder or branched vascularity ^[12] .
Serious cystadenoma		Fern pattern: A densely-arranged, superficial network of vessels ^[11,15] .
Pseudocyst		Bright particles on a dark background: Lightly colored inflammatory cells against a dark background due to lack of vascularity ^[11] .
Cystic neuroendocrine tumor and solid-pseudopapillary neoplasm		Trabecular pattern: Nests of dark cells separated by blood vessels or fibrous bands ^[11] .

Figure 1 A summary of endoscopic ultrasound needle-base confocal laser endomicroscopy image patterns for pancreatic cysts types.

Next-generation sequencing (NGS) has been crucial in the recent identification of molecular markers for specific pancreatic cyst types. NGS encompasses a number of high-throughput technologies that allow for millions or billions of DNA strands to be sequenced in parallel. It has enabled the rapid sequencing of entire genomes and exomes, as well as more targeted sequencing studies. Prior to NGS, Sanger sequencing was the most widely used method of determining genetic sequences. It was based on selective incorporation of chain-terminating dideoxynucleotides (dATP, dTTP, dGTP, dCTP) by DNA polymerase during *in vivo* DNA replication. Table 3 contains a summary of the genetic mutations associated with each major pancreatic cyst type.

Of note, *KRAS* mutations are common in both IPMNs and MCNs, while *GNAS* mutations are typically found in IPMNs but not MCNs^[22,24,28,29]. Both IPMNs and MCNs are also frequently found to have *RNF43* mutations^[22,24]. Malignant and high-grade IPMNs have been found to have *TP53*, *SMAD4*, *PIK3CA*, *PTEN*, *CDKN2A*, and *AKT1* mutations^[30-34]. Additionally, *VHL* mutations are highly specific for SCAs^[22,24,28] and B-catenin gene (*CTNNB1*) mutations are associated with solid-pseudopapillary neoplasms^[22,24].

A recent prospective study of 626 pancreatic cyst fluid specimens showed that *KRAS*/*GNAS* mutations were associated with an 89% sensitivity and 100% specificity for mucinous pancreatic cysts and that NGS had improved sensitivity over Sanger sequencing. It also showed that the combination of *KRAS*/*GNAS* mutations and alterations in *TP53*/*PIK3CA*/*PTEN* had an 89% sensitivity and 100% specificity for advanced neoplasia, which was better than the presence of ductal dilation, a mural nodule, and malignant cytopathology in identifying high-grade cysts^[34].

Table 4 compares the key benefits and drawbacks of EUS-nCLE and molecular analysis of cyst fluid. NGS is not without limitations. Certain pancreatic cyst types are currently poorly identified using molecular analysis, suggesting the need for further exploration of molecular biomarkers. Although MCNs are readily associated with several genetic changes (*e.g.*, *KRAS*, *RNF3*), these mutations have low sensitivity (33% for *KRAS* and 8%-35% for *RNF3* in MCNs), which could result in under-

Table 3 A summary of molecular biomarkers for pancreatic cysts types

Pancreatic cyst type	Molecular biomarkers
Intraductal papillary mucinous neoplasm	<i>KRAS</i> , <i>GNAS</i> , <i>RNF43</i> positive ^[22,24,29,34,37] Advanced neoplasia: <i>TP53</i> , <i>SMAD4</i> , <i>PIK3CA</i> , <i>PTEN</i> , <i>CDKN2A</i> , <i>AKT1</i> , <i>p16</i> , <i>p53</i> positive ^[30-34,38,39]
Mucinous cystic neoplasm	<i>KRAS</i> , <i>RNF3</i> positive ^[22,24,29,34,37] <i>GNAS</i> negative ^[24,28,29] Advanced neoplasia: <i>TP53</i> , <i>SMAD4</i> , <i>PIK3CA</i> , <i>PTEN</i> , <i>CDKN2A</i> , <i>AKT1</i> positive ^[30-34]
Serious cystadenoma	<i>VHL</i> positive ^[22,24,28]
Solid papillary neoplasm	<i>CTNNB1</i> positive ^[22,24]
Pseudocyst	Negative for DNA
Cystic neuroendocrine tumor	Not well described

detection^[28,33-35]. The Sanger sequencing technique is not able to detect the entire loss of the *VHL* gene but can detect deletions and insertions within exons or complete loss of an exon. Hence Sanger sequencing has low sensitivity for the detection of *VHL* mutation which is otherwise commonly observed in SCAs^[34,36]. Additionally, molecular markers in cystic-NETs are poorly characterized in current literature.

CONCLUSION

This review summarizes recent technological advances in the evaluation of pancreatic cysts: confocal endomicroscopy and molecular biomarkers. Both EUS-nCLE and cyst fluid analysis have demonstrated their ability to help diagnose and differentiate pancreatic cysts with high accuracy. Current methods for diagnosing pancreatic cysts, such as imaging (MRI/CT), endoscopy (EUS), cytology, CEA, and amylase, often yield suboptimal or indeterminate results. Given the limitations of existing diagnostic strategies, these minimally invasive technologies, therefore, have the potential to increase diagnostic accuracy, improve risk stratification, and serve as useful adjuncts to current management protocols. As emerging technologies, both confocal endomicroscopy and DNA analysis currently are utilized predominantly in academic settings and are not yet widely used in clinical practice. Thus, additional studies and clinician training will be needed to incorporate them into routine use. Because the number of large (> 2 cm) pancreatic cysts found on abdominal imaging continues to grow each year, diagnostics like confocal endomicroscopy and molecular analysis are more important than ever for accurately diagnosing pancreatic lesions and guiding the next steps in their management.

Table 4 Benefits and drawbacks of molecular analysis of cyst fluid and confocal endomicroscopy^[11 12 15 29 34]

Molecular analysis of PCL fluid (DNA analysis)	EUS-nCLE of PCLs
High sensitivity and specificity for the diagnosis of mucinous PCLs	High sensitivity and specificity for the diagnosis of mucinous PCLs
Markers can detect advanced neoplasia in IPMNs; need validation in multicenter studies	Need further studies to address role of EUS-nCLE in the identification of advanced neoplasia in PCLs
Lower sensitivity for the detection of KRAS mutations in MCNs	Detection of flat epithelium in MCNs can be difficult for early adapters of EUS-nCLE
Need large multicenter prospective studies with confirmed histopathology to replicate single center results	Need large multicenter prospective studies with confirmed histopathology to replicate single center results
Lack of established markers for cystic-NET and squamous lined cysts	EUS-nCLE reveals specific image patterns for different PCL types. Unable to differentiate between cystic-NET and SPN
During EUS-FNA, 5%-10% of PCLs may not yield DNA for molecular analysis	There is a 2%-5% risk of technical and procedural issues with failure of image acquisition during EUS-nCLE
Low sensitivity for the detection of VHL mutations in SCAs	EUS-nCLE identifies characteristic 'fern-pattern' of vascularity for diagnosing SCAs

PCL: Pancreatic cystic lesions; MCN: Mucinous cystic neoplasm; EUS: Endoscopic ultrasound; nCLE: Needle based confocal laser endomicroscopy; FNA: Fine needle aspiration; Cystic-NET: Cystic neuroendocrine tumor; SPN: Solid pseudopapillary neoplasm.

REFERENCES

- 1 **Lee KS**, Sekhar A, Rofsky NM, Pedrosa I. Prevalence of incidental pancreatic cysts in the adult population on MR imaging. *Am J Gastroenterol* 2010; **105**: 2079-2084 [PMID: [20354507](#) DOI: [10.1038/ajg.2010.122](#)]
- 2 **Laffan TA**, Horton KM, Klein AP, Berlanstein B, Siegelman SS, Kawamoto S, Johnson PT, Fishman EK, Hruban RH. Prevalence of unsuspected pancreatic cysts on MDCT. *AJR Am J Roentgenol* 2008; **191**: 802-807 [PMID: [18716113](#) DOI: [10.2214/AJR.07.3340](#)]
- 3 **Zhang XM**, Mitchell DG, Dohke M, Holland GA, Parker L. Pancreatic cysts: depiction on single-shot fast spin-echo MR images. *Radiology* 2002; **223**: 547-553 [PMID: [11997566](#) DOI: [10.1148/radiol.2232010815](#)]
- 4 **de Jong K**, Nio CY, Hermans JJ, Dijkgraaf MG, Gouma DJ, van Eijck CH, van Heel E, Klass G, Fockens P, Bruno MJ. High prevalence of pancreatic cysts detected by screening magnetic resonance imaging examinations. *Clin Gastroenterol Hepatol* 2010; **8**: 806-811 [PMID: [20621679](#) DOI: [10.1016/j.cgh.2010.05.017](#)]
- 5 **Brugge WR**, Lewandrowski K, Lee-Lewandrowski E, Centeno BA, Szydlot T, Regan S, del Castillo CF, Warshaw AL. Diagnosis of pancreatic cystic neoplasms: a report of the cooperative pancreatic cyst study. *Gastroenterology* 2004; **126**: 1330-1336 [PMID: [15131794](#) DOI: [10.1053/j.gastro.2004.02.013](#)]
- 6 **Tanaka M**, Fernández-del Castillo C, Adsay V, Chari S, Falconi M, Jang JY, Kimura W, Levy P, Pitman MB, Schmidt CM, Shimizu M, Wolfgang CL, Yamaguchi K, Yamao K; International Association of Pancreatology. International consensus guidelines 2012 for the management of IPMN and MCN of the pancreas. *Pancreatol* 2012; **12**: 183-197 [PMID: [22687371](#) DOI: [10.1016/j.pan.2012.04.004](#)]
- 7 **Tanaka M**, Fernández-Del Castillo C, Kamisawa T, Jang JY, Levy P, Ohtsuka T, Salvia R, Shimizu Y, Tada M, Wolfgang CL. Revisions of international consensus Fukuoka guidelines for the management of IPMN of the pancreas. *Pancreatol* 2017; **17**: 738-753 [PMID: [28735806](#) DOI: [10.1016/j.pan.2017.07.007](#)]
- 8 **Tanaka M**, Chari S, Adsay V, Fernandez-del Castillo C, Falconi M, Shimizu M, Yamaguchi K, Yamao K, Matsuno S; International Association of Pancreatology. International consensus guidelines for management of intraductal papillary mucinous neoplasms and mucinous cystic neoplasms of the pancreas. *Pancreatol* 2006; **6**: 17-32 [PMID: [16327281](#) DOI: [10.1159/000090023](#)]
- 9 **Vege SS**, Ziring B, Jain R, Moayyedi P; Clinical Guidelines Committee; American Gastroenterology Association. American gastroenterological association institute guideline on the diagnosis and management of asymptomatic neoplastic pancreatic cysts. *Gastroenterology* 2015; **148**: 819-822; quiz 12-13 [PMID: [25805375](#) DOI: [10.1053/j.gastro.2015.01.015](#)]
- 10 **Elta GH**, Enestvedt BK, Sauer BG, Lennon AM. ACG Clinical Guideline: Diagnosis and Management of Pancreatic Cysts. *Am J Gastroenterol* 2018; **113**: 464-479 [PMID: [29485131](#) DOI: [10.1038/ajg.2018.14](#)]
- 11 **Napoleon B**, Lemaistre AI, Pujol B, Caillol F, Lucidarme D, Bourdariat R, Morellon-Mialhe B, Fumex F, Lefort C, Lepilliez V, Palazzo L, Monges G, Poizat F, Giovannini M. In vivo characterization of pancreatic cystic lesions by needle-based confocal laser endomicroscopy (nCLE): proposition of a comprehensive nCLE classification confirmed by an external retrospective evaluation. *Surg Endosc* 2016; **30**: 2603-2612 [PMID: [26428198](#) DOI: [10.1007/s00464-015-4510-5](#)]
- 12 **Krishna SG**, Brugge WR, Dewitt JM, Kongkam P, Napoleon B, Robles-Medrande C, Tan D, El-Dika S, McCarthy S, Walker J, Dillhoff ME, Manilchuk A, Schmidt C, Swanson B, Shah ZK, Hart PA, Conwell DL. Needle-based confocal laser endomicroscopy for the diagnosis of pancreatic cystic lesions: an international external interobserver and intraobserver study (with videos). *Gastrointest Endosc* 2017; **86**: 644-654.e2 [PMID: [28286093](#) DOI: [10.1016/j.gie.2017.03.002](#)]
- 13 **Konda VJ**, Meining A, Jamil LH, Giovannini M, Hwang JH, Wallace MB, Chang KJ, Siddiqui UD, Hart J, Lo SK, Saunders MD, Aslanian HR, Wroblewski K, Waxman I. A pilot study of in vivo identification of pancreatic cystic neoplasms with needle-based confocal laser endomicroscopy under endosonographic guidance. *Endoscopy* 2013; **45**: 1006-1013 [PMID: [24163192](#) DOI: [10.1055/s-0033-1344714](#)]

- 14 **Modi RM**, Swanson B, Muscarella P 2nd, Conwell DL, Krishna SG. Novel techniques for diagnosis of serous cystadenoma: fern pattern of vascularity confirmed by in vivo and ex vivo confocal laser endomicroscopy. *Gastrointest Endosc* 2017; **85**: 258-259 [PMID: [27449195](#) DOI: [10.1016/j.gie.2016.07.015](#)]
- 15 **Napoléon B**, Lemaistre AI, Pujol B, Caillol F, Lucidarme D, Bourdariat R, Morellon-Mialhe B, Fumex F, Lefort C, Lepilliez V, Palazzo L, Monges G, Filoche B, Giovannini M. A novel approach to the diagnosis of pancreatic serous cystadenoma: needle-based confocal laser endomicroscopy. *Endoscopy* 2015; **47**: 26-32 [PMID: [25325684](#) DOI: [10.1055/s-0034-1390693](#)]
- 16 **Krishna SG**, Modi RM, Kamboj AK, Swanson BJ, Hart PA, Dillhoff ME, Manilchuk A, Schmidt CR, Conwell DL. In vivo and ex vivo confocal endomicroscopy of pancreatic cystic lesions: A prospective study. *World J Gastroenterol* 2017; **23**: 3338-3348 [PMID: [28566895](#) DOI: [10.3748/wjg.v23.i18.3338](#)]
- 17 **Modi RM**, Kamboj AK, Swanson B, Conwell DL, Krishna SG. Epidermoid cyst within an intrapancreatic accessory spleen: endosonography and confocal endomicroscopy of an unusual pancreatic cystic lesion. *Endoscopy* 2016; **48**: E332-E333 [PMID: [27741530](#) DOI: [10.1055/s-0042-117506](#)]
- 18 **Krishna SG**, Swanson B, Conwell DL, Muscarella P. In vivo and ex vivo needle-based confocal endomicroscopy of intraductal papillary mucinous neoplasm of the pancreas. *Gastrointest Endosc* 2015; **82**: 571-572
- 19 **Nakai Y**, Iwashita T, Park DH, Samarasena JB, Lee JG, Chang KJ. Diagnosis of pancreatic cysts: EUS-guided, through-the-needle confocal laser-induced endomicroscopy and cystoscopy trial: DETECT study. *Gastrointest Endosc* 2015; **81**: 1204-1214 [PMID: [25634486](#) DOI: [10.1016/j.gie.2014.10.025](#)]
- 20 **Krishna SG**, Swanson B, Hart PA, El-Dika S, Walker JP, McCarthy ST, Malli A, Shah ZK, Conwell DL. Validation of diagnostic characteristics of needle based confocal laser endomicroscopy in differentiation of pancreatic cystic lesions. *Endosc Int Open* 2016; **4**: E1124-E1135 [PMID: [27853737](#) DOI: [10.1055/s-0042-116491](#)]
- 21 **Napoleon B**, Pujol B, Palazzo M, Caillol F, Palazzo L, Aubert A, Maire F, Buscail L, Lemaistre A-I, Giovannini M. Needlebased confocal laser endomicroscopy of pancreatic cystic lesions: a prospective multicenter validation study in patients with definite diagnosis. *Gastroenterology* 2017; **152**: S132-S133 [DOI: [10.1016/S0016-5085\(17\)30776-X](#)]
- 22 **Springer S**, Wang Y, Dal Molin M, Masica DL, Jiao Y, Kinde I, Blackford A, Raman SP, Wolfgang CL, Tomita T, Niknafs N, Douville C, Ptak J, Dobbyn L, Allen PJ, Klimstra DS, Schattner MA, Schmidt CM, Yip-Schneider M, Cummings OW, Brand RE, Zeh HJ, Singhi AD, Scarpa A, Salvia R, Malleo G, Zamboni G, Falconi M, Jang JY, Kim SW, Kwon W, Hong SM, Song KB, Kim SC, Swan N, Murphy J, Geoghegan J, Brugge W, Fernandez-Del Castillo C, Mino-Kenudson M, Schulick R, Edil BH, Adsay V, Paulino J, van Hooft J, Yachida S, Nara S, Hiraoka N, Yamao K, Hijioka S, van der Merwe S, Goggins M, Canto MI, Ahuja N, Hirose K, Makary M, Weiss MJ, Cameron J, Pittman M, Eshleman JR, Diaz LA, Papadopoulos N, Kinzler KW, Karchin R, Hruban RH, Vogelstein B, Lennon AM. A combination of molecular markers and clinical features improve the classification of pancreatic cysts. *Gastroenterology* 2015; **149**: 1501-1510 [PMID: [26253305](#) DOI: [10.1053/j.gastro.2015.07.041](#)]
- 23 **Khalid A**, Brugge W. ACG practice guidelines for the diagnosis and management of neoplastic pancreatic cysts. *Am J Gastroenterol* 2007; **102**: 2339-2349 [PMID: [17764489](#) DOI: [10.1111/j.1572-0241.2007.01516.x](#)]
- 24 **Wu J**, Jiao Y, Dal Molin M, Maitra A, de Wilde RF, Wood LD, Eshleman JR, Goggins MG, Wolfgang CL, Canto MI, Schulick RD, Edil BH, Choti MA, Adsay V, Klimstra DS, Offerhaus GJ, Klein AP, Kopelovich L, Carter H, Karchin R, Allen PJ, Schmidt CM, Naito Y, Diaz LA, Kinzler KW, Papadopoulos N, Hruban RH, Vogelstein B. Whole-exome sequencing of neoplastic cysts of the pancreas reveals recurrent mutations in components of ubiquitin-dependent pathways. *Proc Natl Acad Sci USA* 2011; **108**: 21188-21193 [PMID: [22158988](#) DOI: [10.1073/pnas.1118046108](#)]
- 25 **Amato E**, Molin MD, Mafficini A, Yu J, Malleo G, Rusev B, Fassan M, Antonello D, Sadakari Y, Castelli P, Zamboni G, Maitra A, Salvia R, Hruban RH, Bassi C, Capelli P, Lawlor RT, Goggins M, Scarpa A. Targeted next-generation sequencing of cancer genes dissects the molecular profiles of intraductal papillary neoplasms of the pancreas. *J Pathol* 2014; **233**: 217-227 [PMID: [24604757](#) DOI: [10.1002/path.4344](#)]
- 26 **Khalid A**, Zahid M, Finkelstein SD, LeBlanc JK, Kaushik N, Ahmad N, Brugge WR, Edmundowicz SA, Hawes RH, McGrath KM. Pancreatic cyst fluid DNA analysis in evaluating pancreatic cysts: a report of the PANDA study. *Gastrointest Endosc* 2009; **69**: 1095-1102 [PMID: [19152896](#) DOI: [10.1016/j.gie.2008.07.033](#)]
- 27 **Khalid A**, McGrath KM, Zahid M, Wilson M, Brody D, Swalsky P, Moser AJ, Lee KK, Slivka A, Whitcomb DC, Finkelstein S. The role of pancreatic cyst fluid molecular analysis in predicting cyst pathology. *Clin Gastroenterol Hepatol* 2005; **3**: 967-973 [PMID: [16234041](#)]
- 28 **Wu J**, Matthaei H, Maitra A, Dal Molin M, Wood LD, Eshleman JR, Goggins M, Canto MI, Schulick RD, Edil BH, Wolfgang CL, Klein AP, Diaz LA, Allen PJ, Schmidt CM, Kinzler KW, Papadopoulos N, Hruban RH, Vogelstein B. Recurrent GNAS mutations define an unexpected pathway for pancreatic cyst development. *Sci Transl Med* 2011; **3**: 92ra66 [PMID: [21775669](#) DOI: [10.1126/scitranslmed.3002543](#)]
- 29 **Singhi AD**, Nikiforova MN, Fasanella KE, McGrath KM, Pai RK, Ohori NP, Bartholow TL, Brand RE, Chennat JS, Lu X, Papachristou GI, Slivka A, Zeh HJ, Zureikat AH, Lee KK, Tsung A, Mantha GS, Khalid A. Preoperative GNAS and KRAS testing in the diagnosis of pancreatic mucinous cysts. *Clin Cancer Res* 2014; **20**: 4381-4389 [PMID: [24938521](#) DOI: [10.1158/1078-0432.CCR-14-0513](#)]
- 30 **Kanda M**, Sadakari Y, Borges M, Topazian M, Farrell J, Syngal S, Lee J, Kamel I, Lennon AM, Knight S, Fujiwara S, Hruban RH, Canto MI, Goggins M. Mutant TP53 in duodenal samples of pancreatic juice from patients with pancreatic cancer or high-grade dysplasia. *Clin Gastroenterol Hepatol* 2013; **11**: 719-730.e5 [PMID: [23200980](#) DOI: [10.1016/j.cgh.2012.11.016](#)]
- 31 **Schönleben F**, Qiu W, Ciau NT, Ho DJ, Li X, Allendorf JD, Remotti HE, Su GH. PIK3CA mutations in intraductal papillary mucinous neoplasm/carcinoma of the pancreas. *Clin Cancer Res* 2006; **12**: 3851-3855 [PMID: [16778113](#) DOI: [10.1158/1078-0432.CCR-06-0292](#)]
- 32 **Garcia-Carracedo D**, Chen ZM, Qiu W, Huang AS, Tang SM, Hruban RH, Su GH. PIK3CA mutations in mucinous cystic neoplasms of the pancreas. *Pancreas* 2014; **43**: 245-249 [PMID: [24518503](#) DOI: [10.1097/MPA.0000000000000034](#)]
- 33 **Yu J**, Sadakari Y, Shindo K, Suenaga M, Brant A, Almario JAN, Borges M, Barkley T, Fesharakizadeh S, Ford M, Hruban RH, Shin EJ, Lennon AM, Canto MI, Goggins M. Digital next-generation sequencing identifies low-abundance mutations in pancreatic juice samples collected from the duodenum of patients with pancreatic cancer and intraductal papillary mucinous neoplasms. *Gut* 2017; **66**: 1677-1687 [PMID: [28566895](#) DOI: [10.3748/wjg.v23.i18.3338](#)]

- 27432539 DOI: [10.1136/gutjnl-2015-311166](https://doi.org/10.1136/gutjnl-2015-311166)
- 34 **Singhi AD**, McGrath K, Brand RE, Khalid A, Zeh HJ, Chennat JS, Fasanella KE, Papachristou GI, Slivka A, Bartlett DL, Dasyam AK, Hogg M, Lee KK, Marsh JW, Monaco SE, Ohori NP, Pingpank JF, Tsung A, Zureikat AH, Wald AI, Nikiforova MN. Preoperative next-generation sequencing of pancreatic cyst fluid is highly accurate in cyst classification and detection of advanced neoplasia. *Gut* 2018; **67**: 2131-2141 [PMID: [28970292](https://pubmed.ncbi.nlm.nih.gov/28970292/) DOI: [10.1136/gutjnl-2016-313586](https://doi.org/10.1136/gutjnl-2016-313586)]
- 35 **Mukewar S**, de Pretis N, Aryal-Khanal A, Ahmed N, Sah R, Enders F, Larson JJ, Levy MJ, Takahashi N, Topazian M, Pearson R, Vege SS, Chari ST. Fukuoka criteria accurately predict risk for adverse outcomes during follow-up of pancreatic cysts presumed to be intraductal papillary mucinous neoplasms. *Gut* 2017; **66**: 1811-1817 [PMID: [27390303](https://pubmed.ncbi.nlm.nih.gov/27390303/) DOI: [10.1136/gutjnl-2016-311615](https://doi.org/10.1136/gutjnl-2016-311615)]
- 36 **Tsiatis AC**, Norris-Kirby A, Rich RG, Hafez MJ, Gocke CD, Eshleman JR, Murphy KM. Comparison of Sanger sequencing, pyrosequencing, and melting curve analysis for the detection of KRAS mutations: diagnostic and clinical implications. *J Mol Diagn* 2010; **12**: 425-432 [PMID: [20431034](https://pubmed.ncbi.nlm.nih.gov/20431034/) DOI: [10.2353/jmoldx.2010.090188](https://doi.org/10.2353/jmoldx.2010.090188)]
- 37 **Nikiforova MN**, Khalid A, Fasanella KE, McGrath KM, Brand RE, Chennat JS, Slivka A, Zeh HJ, Zureikat AH, Krasinskas AM, Ohori NP, Schoedel KE, Navina S, Mantha GS, Pai RK, Singhi AD. Integration of KRAS testing in the diagnosis of pancreatic cystic lesions: a clinical experience of 618 pancreatic cysts. *Mod Pathol* 2013; **26**: 1478-1487 [PMID: [23743931](https://pubmed.ncbi.nlm.nih.gov/23743931/) DOI: [10.1038/modpathol.2013.91](https://doi.org/10.1038/modpathol.2013.91)]
- 38 **Sasaki S**, Yamamoto H, Kaneto H, Ozeki I, Adachi Y, Takagi H, Matsumoto T, Itoh H, Nagakawa T, Miyakawa H, Muraoka S, Fujinaga A, Suga T, Satoh M, Itoh F, Endo T, Imai K. Differential roles of alterations of p53, p16, and SMAD4 expression in the progression of intraductal papillary-mucinous tumors of the pancreas. *Oncol Rep* 2003; **10**: 21-25 [PMID: [12469138](https://pubmed.ncbi.nlm.nih.gov/12469138/)]
- 39 **Garcia-Carracedo D**, Turk AT, Fine SA, Akhavan N, Tweel BC, Parsons R, Chabot JA, Allendorf JD, Genkinger JM, Remotti HE, Su GH. Loss of PTEN expression is associated with poor prognosis in patients with intraductal papillary mucinous neoplasms of the pancreas. *Clin Cancer Res* 2013; **19**: 6830-6841 [PMID: [24132918](https://pubmed.ncbi.nlm.nih.gov/24132918/) DOI: [10.1158/1078-0432.CCR-13-0624](https://doi.org/10.1158/1078-0432.CCR-13-0624)]



Published By Baishideng Publishing Group Inc
7041 Koll Center Parkway, Suite 160, Pleasanton, CA 94566, USA
Telephone: +1-925-2238242
Fax: +1-925-2238243
E-mail: bpgoffice@wjgnet.com
Help Desk: <http://www.f6publishing.com/helpdesk>
<http://www.wjgnet.com>

