


# World Journal of *Gastroenterology*

*World J Gastroenterol* 2020 July 7; 26(25): 3517-3711



### GUIDELINES

- 3517** Chinese expert consensus and practice guideline of totally implantable access port for digestive tract carcinomas

*Zhang KC, Chen L, Chinese Research Hospital Association Digestive Tumor Committee; Chinese Association of Upper Gastrointestinal Surgeons; Chinese Gastric Cancer Association and Gastrointestinal Surgical Group of Chinese Surgical Society Affiliated to the Chinese Medical Association*

### OPINION REVIEW

- 3528** Management of nonalcoholic fatty liver disease in the Middle East

*Sanai FM, Abaalkhail F, Hasan F, Farooqi MH, Nahdi NA, Younossi ZM*

### REVIEW

- 3542** Practical review for diagnosis and clinical management of perihilar cholangiocarcinoma

*Dondossola D, Ghidini M, Grossi F, Rossi G, Foschi D*

- 3562** Development of innovative tools for investigation of nutrient-gut interaction

*Huang WK, Xie C, Young RL, Zhao JB, Ebendorff-Heidepriem H, Jones KL, Rayner CK, Wu TZ*

### MINIREVIEWS

- 3577** Monoacylglycerol lipase reprograms lipid precursors signaling in liver disease

*Tardelli M*

### ORIGINAL ARTICLE

#### Basic Study

- 3586** TBL1XR1 induces cell proliferation and inhibit cell apoptosis by the PI3K/AKT pathway in pancreatic ductal adenocarcinoma

*Gu JF, Fu W, Qian HX, Gu WX, Zong Y, Chen Q, Lu L*

- 3603** Retrievable puncture anchor traction method for endoscopic ultrasound-guided gastroenterostomy: A porcine study

*Wang GX, Zhang K, Sun SY*

#### Case Control Study

- 3611** Risk factors associated with inflammatory bowel disease: A multicenter case-control study in Brazil

*Salgado VCL, Luiz RR, Boéchat NLF, Leão IS, Schorr BDC, Parente JML, Lima DC, Silveira Júnior ES, Silva GOS, Almeida NP, Vieira A, de Bueno MLQ, Chebli JM, Bertges ÉR, Brugnara LMDC, Junqueira Neto C, Campbell SBG, Discacciati LL, César JPS, Nunes T, Kaplan GG, Zaltman C*

**Retrospective Cohort Study**

- 3625** Predictors of irreversible intestinal resection in patients with acute mesenteric venous thrombosis

*Sun SL, Wang XY, Chu CN, Liu BC, Li QR, Ding WW*

- 3638** Functionality is not an independent prognostic factor for pancreatic neuroendocrine tumors

*Chen HY, Zhou YL, Chen YH, Wang X, Zhang H, Ke NW, Liu XB, Tan CL*

**Retrospective Study**

- 3650** Chronic atrophic gastritis detection with a convolutional neural network considering stomach regions

*Kanai M, Togo R, Ogawa T, Haseyama M*

- 3660** Multiphase convolutional dense network for the classification of focal liver lesions on dynamic contrast-enhanced computed tomography

*Cao SE, Zhang LQ, Kuang SC, Shi WQ, Hu B, Xie SD, Chen YN, Liu H, Chen SM, Jiang T, Ye M, Zhang HX, Wang J*

**Observational Study**

- 3673** Type I and type II *Helicobacter pylori* infection status and their impact on gastrin and pepsinogen level in a gastric cancer prevalent area

*Yuan L, Zhao JB, Zhou YL, Qi YB, Guo QY, Zhang HH, Khan MN, Lan L, Jia CH, Zhang YR, Ding SZ*

**SYSTEMATIC REVIEWS**

- 3686** Quality of life in patients with gastroenteropancreatic tumours: A systematic literature review

*Watson C, Tallentire CW, Ramage JK, Srirajaskanthan R, Leeuwenkamp OR, Fountain D*

**ABOUT COVER**

Editorial board member of *World Journal of Gastroenterology*, Prof. Antonio Biondi is an Associate Editor of *Updates in Surgery*, the official journal of the Italian Society of Surgery, and a Full Professor of surgery at the School of Medicine, University of Catania, Italy. Prof. Biondi obtained his MD degree from the University of Catania in 1993, and his PhD degree in 2001. He was promoted to Full Professor in the School of Medicine, University of Catania, in 2018. His ongoing research interests are colorectal surgery and laparoscopic procedures. He is a member of the editorial boards and a reviewer of several scientific journals, and has published more than 150 peer-reviewed articles. Prof. Biondi served as elected member of the Italian National University Council (CUN). Currently, he is the Chief of the Laparoscopic Surgery Division, Department of General Surgery and Medical-Surgical Specialties, University Hospital Policlinico Vittorio Emanuele, Catania and Director of the Multidisciplinary Research Center for Diagnosis and Treatment of Rare Diseases, University of Catania.

**AIMS AND SCOPE**

The primary aim of *World Journal of Gastroenterology* (WJG, *World J Gastroenterol*) is to provide scholars and readers from various fields of gastroenterology and hepatology with a platform to publish high-quality basic and clinical research articles and communicate their research findings online. WJG mainly publishes articles reporting research results and findings obtained in the field of gastroenterology and hepatology and covering a wide range of topics including gastroenterology, hepatology, gastrointestinal endoscopy, gastrointestinal surgery, gastrointestinal oncology, and pediatric gastroenterology.

**INDEXING/ABSTRACTING**

The WJG is now indexed in Current Contents®/Clinical Medicine, Science Citation Index Expanded (also known as SciSearch®), Journal Citation Reports®, Index Medicus, MEDLINE, PubMed, PubMed Central, and Scopus. The 2020 edition of Journal Citation Report® cites the 2019 impact factor for WJG as 3.665 (5-year impact factor: 4.048), ranking WJG as 35 among 88 journals in gastroenterology and hepatology (quartile in category Q2).

**RESPONSIBLE EDITORS FOR THIS ISSUE**

Electronic Editor: *Yu-Jie Ma*; Production Department Director: *Xiang Li*; Editorial Office Director: *Ze-Mao Gong*.

**NAME OF JOURNAL**

*World Journal of Gastroenterology*

**ISSN**

ISSN 1007-9327 (print) ISSN 2219-2840 (online)

**LAUNCH DATE**

October 1, 1995

**FREQUENCY**

Weekly

**EDITORS-IN-CHIEF**

Andrzej S Tarnawski, Subrata Ghosh

**EDITORIAL BOARD MEMBERS**

<http://www.wjgnet.com/1007-9327/editorialboard.htm>

**PUBLICATION DATE**

July 7, 2020

**COPYRIGHT**

© 2020 Baishideng Publishing Group Inc

**INSTRUCTIONS TO AUTHORS**

<https://www.wjgnet.com/bpg/gerinfo/204>

**GUIDELINES FOR ETHICS DOCUMENTS**

<https://www.wjgnet.com/bpg/GerInfo/287>

**GUIDELINES FOR NON-NATIVE SPEAKERS OF ENGLISH**

<https://www.wjgnet.com/bpg/gerinfo/240>

**PUBLICATION ETHICS**

<https://www.wjgnet.com/bpg/GerInfo/288>

**PUBLICATION MISCONDUCT**

<https://www.wjgnet.com/bpg/gerinfo/208>

**ARTICLE PROCESSING CHARGE**

<https://www.wjgnet.com/bpg/gerinfo/242>

**STEPS FOR SUBMITTING MANUSCRIPTS**

<https://www.wjgnet.com/bpg/GerInfo/239>

**ONLINE SUBMISSION**

<https://www.f6publishing.com>



## Basic Study

# Retrievable puncture anchor traction method for endoscopic ultrasound-guided gastroenterostomy: A porcine study

Guo-Xin Wang, Kai Zhang, Si-Yu Sun

**ORCID number:** Guo-Xin Wang 0000-0002-5928-3370; Kai Zhang 0000-0002-0355-3415; Si-Yu Sun 0000-0002-7308-0473.

**Author contributions:** Wang GX and Zhang K contributed to the work equally and should be regarded as co-first authors; Wang GX, Zhang K and Sun SY conceived and designed the study; Wang GX and Zhang K analyzed and interpreted the data, drafted the article, revised the article for important intellectual content; Sun SY approved the final version of the article.

**Supported by** the China Postdoctoral Science Foundation, No. 2019M661174; National Natural Science Foundation of China, No. 81770655; and the Natural Science Foundation of Liaoning Province, No. 2019-MS-359.

**Institutional animal care and use committee statement:** The study was reviewed and approved by the Ethics Review Committee and Ethics Committee of Shengjing Hospital of China Medical University (No. 2018PS482K). All animal experiments conformed to the internationally accepted principles for the care and use of laboratory animals.

**Guo-Xin Wang, Kai Zhang, Si-Yu Sun**, Department of Gastroenterology, Endoscopic Center, Shengjing Hospital of China Medical University, Shenyang 110001, Liaoning Province, China

**Corresponding author:** Si-Yu Sun, MD, PhD, Chief Doctor, Director, Professor, Department of Gastroenterology, Endoscopic Center, Shengjing Hospital of China Medical University, No. 36, Sanhao Street, Shenyang 110004, Liaoning Province, China. [sun-siyu@163.com](mailto:sun-siyu@163.com)

## Abstract

### BACKGROUND

Endoscopic ultrasound-guided gastroenterostomy (EUS-GE) is an alternative method for the surgical treatment of gastric outlet obstruction, but it is regarded as a challenging technique for endoscopists as the bowel is highly mobile and can tent away. Thus, the technique requires superb skill. In order to improve EUS-GE, we have developed a retrievable puncture anchor traction (RPAT) device for EUS-GE to address the issue of bowel tenting.

### AIM

To evaluate the feasibility of RPAT-assisted EUS-GE using an animal model.

### METHODS

Six Bama mini pigs each weighing between 15 and 20 kg underwent the RPAT-assisted EUS-GE procedure. Care was taken to ensure that the animals experienced minimal pain and discomfort. Two days prior to the procedure the animals were limited to a liquid diet. No oral intake was allowed on the day before the procedure. A fully covered metal stent was placed between the stomach and the intestine using the RPAT-assisted EUS-GE method. Infection in the animals was determined. Four weeks after the procedure, a standard gastroscope was inserted into the pig's intestine through a previously created fistula in order to check the status of the stents under anesthesia. The pig was euthanized after examination.

### RESULTS

The RPAT-assisted EUS-GE method allowed placement of the stents with no complications in all six animals. All the pigs tolerated a regular diet within hours of the procedure. The animals were monitored for four weeks after the RPAT-assisted EUS-GE, during which time all of the animals exhibited normal eating behavior and no signs of infection were observed. Endoscopic imaging performed

**Conflict-of-interest statement:** Sun SY is a consultant for the Vedkang Company and Nanjing Microtech company. The other authors have no conflicts of interests to declare.

**Data sharing statement:** No additional data are available.

**ARRIVE guidelines statement:** The authors have read the ARRIVE guidelines, and the manuscript was prepared and revised according to the ARRIVE guidelines.

**Open-Access:** This article is an open-access article that was selected by an in-house editor and fully peer-reviewed by external reviewers. It is distributed in accordance with the Creative Commons Attribution NonCommercial (CC BY-NC 4.0) license, which permits others to distribute, remix, adapt, build upon this work non-commercially, and license their derivative works on different terms, provided the original work is properly cited and the use is non-commercial. See: <http://creativecommons.org/licenses/by-nc/4.0/>

**Manuscript source:** Unsolicited manuscript

**Received:** March 3, 2020

**Peer-review started:** March 3, 2020

**First decision:** March 24, 2020

**Revised:** April 30, 2020

**Accepted:** May 27, 2020

**Article in press:** May 27, 2020

**Published online:** July 7, 2020

**P-Reviewer:** Altonbary Y, Kanno Y, Kozarek RA, Minaga K, Yoshinaga S

**S-Editor:** Dou Y

**L-Editor:** Webster JR

**E-Editor:** Zhang YL



four weeks after the RPAT-assisted EUS-GE showed that the stents remained patent and stable in all the animals. No tissue overgrowth or ingrowth was observed in any case. Each animal had a mature fistula, and the stents were removed without significant bleeding. Autopsies of all six pigs revealed complete adhesion between the intestine and the stomach wall.

## CONCLUSION

The RPAT method helps reduce mobility of the bowel. Therefore, the RPAT-assisted EUS-GE method is a minimally invasive treatment modality.

**Key words:** Retrievable puncture anchor; Endoscopic ultrasound; Endoscopic ultrasound-guided gastroenterostomy; Gastric outlet obstruction; Gastroenterostomy; Electrocautery-enhanced delivery of lumen-apposing metal stents

©The Author(s) 2020. Published by Baishideng Publishing Group Inc. All rights reserved.

**Core tip:** To evaluate the feasibility of retrievable puncture anchor traction (RPAT)-assisted endoscopic ultrasound-guided gastroenterostomy (EUS-GE), six Bama mini pigs underwent the RPAT-assisted EUS-GE procedure. Four weeks later, a standard gastroscope was inserted into the pig's intestine through a previously created fistula in order to check the status of the stents under anesthesia. The pigs were euthanized after examination. The results showed that the RPAT-assisted EUS-GE method allowed placement of the stents with no complications in all six animals. This study proved that the RPAT method helps reduce mobility of the bowel. Therefore, the RPAT-assisted EUS-GE method is a minimally invasive treatment modality.

**Citation:** Wang GX, Zhang K, Sun SY. Retrievable puncture anchor traction method for endoscopic ultrasound-guided gastroenterostomy: A porcine study. *World J Gastroenterol* 2020; 26(25): 3603-3610

**URL:** <https://www.wjgnet.com/1007-9327/full/v26/i25/3603.htm>

**DOI:** <https://dx.doi.org/10.3748/wjg.v26.i25.3603>

## INTRODUCTION

Endoscopic ultrasound-guided gastroenterostomy (EUS-GE) has become an alternative to the surgical or standard endoscopic treatment methods for gastric outlet obstruction (GOO) when endoscopic stents cannot be placed. However, EUS-GE presents certain challenges and the current procedural methods have limitations. One source of difficulty during EUS-GE is the high mobility of the intestine, which can tent away during puncture with a needle or electrocautery-enhanced delivery of lumen-apposing metal stents (ECE-LAMS). In order to improve EUS-GE, we developed a retrieval puncture anchor traction (RPAT) method for EUS-GE. We evaluated the feasibility of the RPAT method using a pig model.

## MATERIALS AND METHODS

### Animals

Six Bama mini pigs (15-20 kg) were selected to undergo the RPAT method of EUS-GE, which consisted of placing fully covered metal stents between the animals' stomach and bowel walls. This pig model study was approved by the Ethics Review Committee and Ethics Committee of Shengjing Hospital of China Medical University (No. 2018PS482K).

### Preoperative preparation

Each pig received a full liquid diet two days before the operation, and drinking water was forbidden the day before surgery. Based on the weight of each animal, propofol was intramuscularly injected for the induction of anesthesia. The pigs were placed on their left side. Venous access was established through the ear vein. The animals'

breathing was maintained by the insertion of a tracheal tube. The animals were monitored with continuous cardiopulmonary monitoring.

### RPA

The RPA (Vedkang Inc., Changzhou, Jiangsu, China) is made up of two wires (Figure 1A). The direction of the anchor head can be altered by pulling the retrieval wire (Figure 1B). The anchor can be sent through the needle (Figure 1C and D)<sup>[1]</sup>.

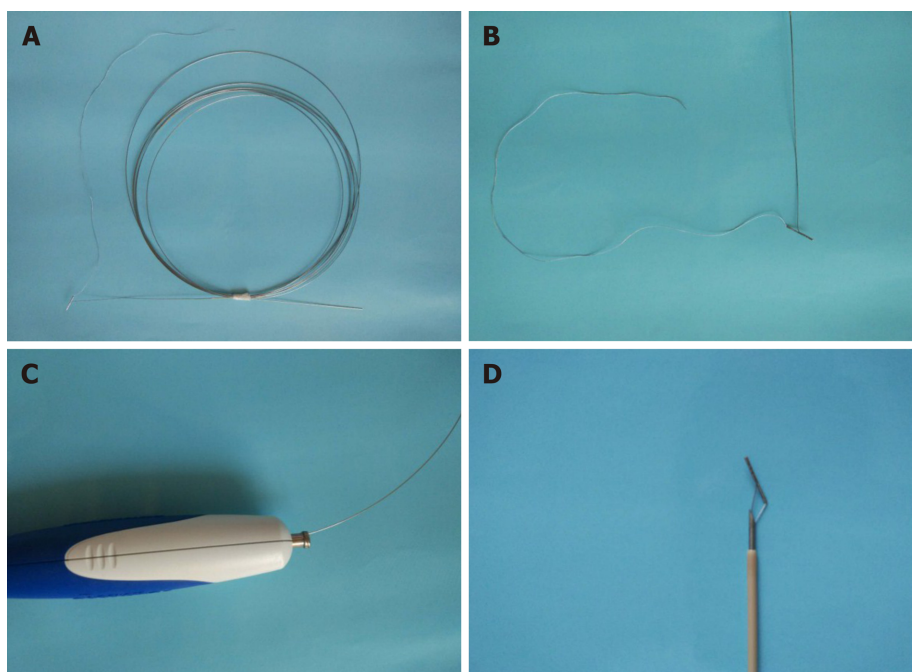
### Operative procedure

**RPAT method of EUS-GE:** First, a gastroscope was advanced into the duodenum. A guidewire (0.035 inch/480 mm; Cook Medical Inc., Bloomington, IN, United States) was sent through the working channel of the gastroscope. A nasal biliary drainage catheter (NBDC) (7Fr; Cook Medical Inc., Limerick, Ireland) was then inserted along the guidewire. Next, the gastroscope and guidewire were removed, leaving the NBDC in place. Approximately 200 mL of saline solution containing methylene blue was injected into the bowel through the NBDC to optimally dilate the bowel and facilitate the subsequent EUS-guided puncture. Methylene blue was added to confirm bowel placement by aspirating the blue saline solution with a needle (described below) before the ECE-LAMS insertion. A longitudinal (linear) ultrasound endoscope (EG-3830-UT; Pentax Japan) was inserted into the stomach and the puncture area (*i.e.*, the closest area between the intestine and the stomach) was marked. We used color Doppler to prevent vascular damage during the puncture. A needle (19-G, Boston Scientific Corp., Massachusetts, United States) was then passed through the working channel, and the intestine was punctured under EUS guidance (Figure 2A and B). After removal of the stylet, saline solution with methylene blue was drawn out and a contrast agent was injected for endoscopy. The RPAT was then passed through the needle (Figure 2C and D) and inserted into the small intestine. The needle and the echoendoscope were removed over the wire of the RPAT. The small bowel was pulled with the anchor (Figure 2E and F). RPAT only pulls the intestinal canal during stent implantation to prevent free action, so the pulling action is gentle rather than violent. During the procedure, we did not observe the angle of the digestive tract wall due to stretching. The echoendoscope was reinserted into the stomach and the 19-G needle was advanced through the working channel. Additional saline solution with methylene blue was injected through the NBDC using multiple 50-mL syringes if the bowel expansion was insufficient. The identified small-bowel loop was punctured under EUS guidance followed by aspiration of the methylene blue solution to confirm the correct puncture site when the small bowel was pulled with the anchor. The guidewire was inserted through the needle. Next, the needle was removed, and ECE-LAMS (16 mm/30 mm; Micro-Tech/Nan Jing Co., Ltd. Nanjing, Jiangsu, China) was inserted over the guidewire and released into the small intestine until the distal flares were fully open under EUS guidance (Figure 2G and Figure H). Through endoscope monitoring, while keeping the proximal section in the field of vision, the rest of the stent was released. Finally, the stent was confirmed and leakages were excluded by EUS (Figure 3A and B). After the operation, the retrieval cord was pulled using a pair of forceps (Figure 2I and J). This changed the direction of the anchor and made it easy to remove (Figure 2K and L).

**Postoperative care:** Postoperatively, the pigs were observed for signs of peritonitis. Four weeks after surgery, the pigs underwent anesthesia, and a standard gastroscope was used to examine the pigs' intestines. After removing the metal stent using a pair of forceps, the gastroscope was advanced into the afferent and efferent bowel loops (Figure 3C and D). X-ray examination was performed to check for the presence of free gas. All pigs were then euthanized (Figure 4).

## RESULTS

All six operations were successfully performed. Each metal stent was placed successfully, and the EUS-GEs selected the body of the stomach as the puncture site in each case. All RPAs were able to be removed with no complications. No animal showed signs of peritonitis or any other complications after the procedure. Within a few hours after anesthesia, the pigs were able to tolerate a regular diet. No clinically significant adverse reactions were observed in the following weeks. Four weeks after EUS-GE, it was confirmed that the stents remained intact, in their original positions, with no hyperplastic tissue overgrowth or ingrowth in any animal. The fistulas were



**Figure 1** The retrievable puncture anchor. A: The retrievable puncture anchor (Vedkang Inc., Changzhou, Jiangsu, China) in its entirety; B: The head of the anchor; C and D: A view of the passage of the anchor along the shaft of the puncture needle.

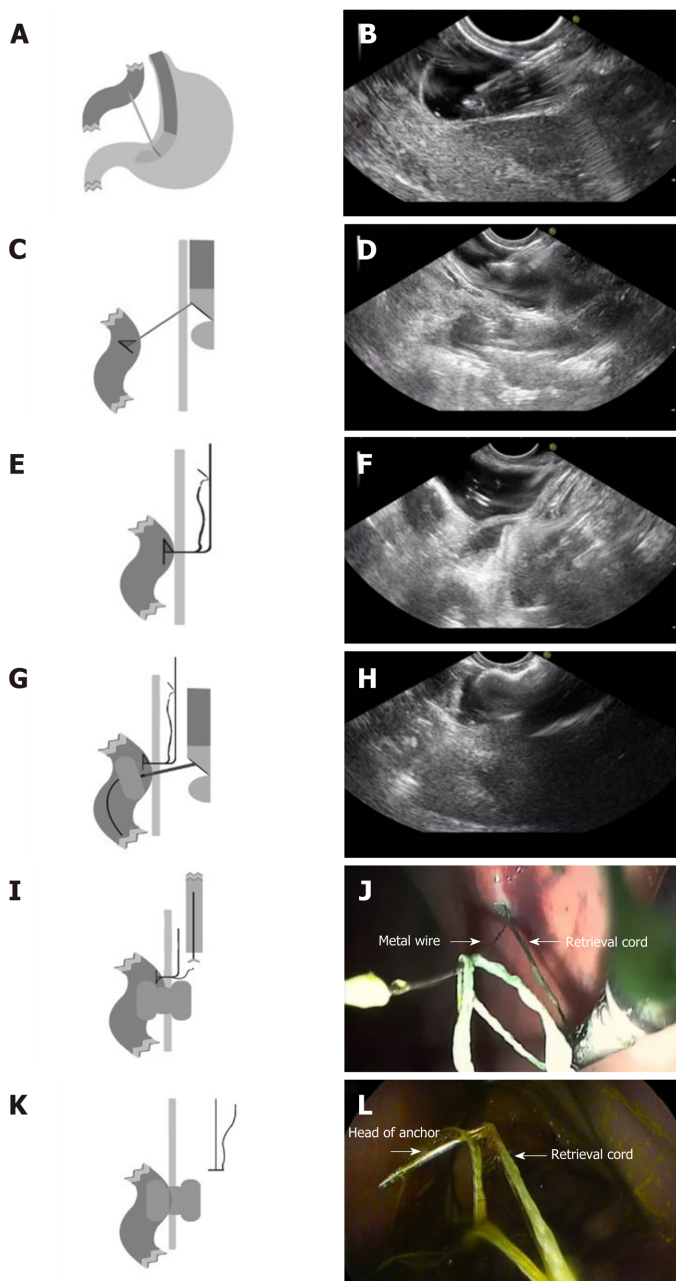
mature in all six pigs and all the stents were easily removed using forceps without significant bleeding. On autopsy, there were no signs of bleeding, organ damage, or peritonitis, and complete adhesions of the intestines to the stomach wall were seen.

## DISCUSSION

Surgical GE is a traditional choice for patients with malignant GOO. Intraluminal self-expanding metal stents (SEMS) placed through the endoscope is another method to relieve GOO<sup>[2-4]</sup>. Surgical GE is superior to endoscopic SEMS placement in terms of lumen patency<sup>[4]</sup>; however, adverse events including delayed gastric emptying, extended hospital stay, increased cost of hospitalization, and delayed treatment of cancer are not uncommon<sup>[4,5]</sup>. The main limitation of placing SEMS endoscopically is repeated occlusion of the lumen, which is mainly due to tumor ingrowth, overgrowth, or both<sup>[4]</sup>. In general, EUS-GE can provide durable lumen patency, avoid the risk of tumor overgrowth and ingrowth, and avoids the need for surgery in patients with end-stage disease<sup>[6]</sup>. In 2002, Fritscher-Ravens *et al*<sup>[7]</sup> reported the results of EUS-GE using special compression buttons in pigs. In 2012, Binmoeller *et al*<sup>[8]</sup> described the use of a new intraluminal metal stent in a porcine model that was used to invent an EUS-GE anastomosis. Recently, Itoi *et al*<sup>[9]</sup> used another endoluminal stent for EUS-GE.

The emergence of stents allows easier creation of anastomoses between the small intestine and the stomach wall. These stents are fully covered with flanges at either end to prevent leakage and migration. The EUS-GE technique using an echoendoscope is an excellent means of providing endoscopic access to the duodenal or jejunal lumen distal to obstructed intestinal segments. Various techniques have been used with EUS-GE<sup>[10]</sup>, including antegrade EUS-GE (the “traditional/downstream” method and the “rendezvous method”), retrograde EUS-GE, EUS-guided double-balloon-occluded GE, and direct EUS-GE<sup>[9,11-13]</sup>.

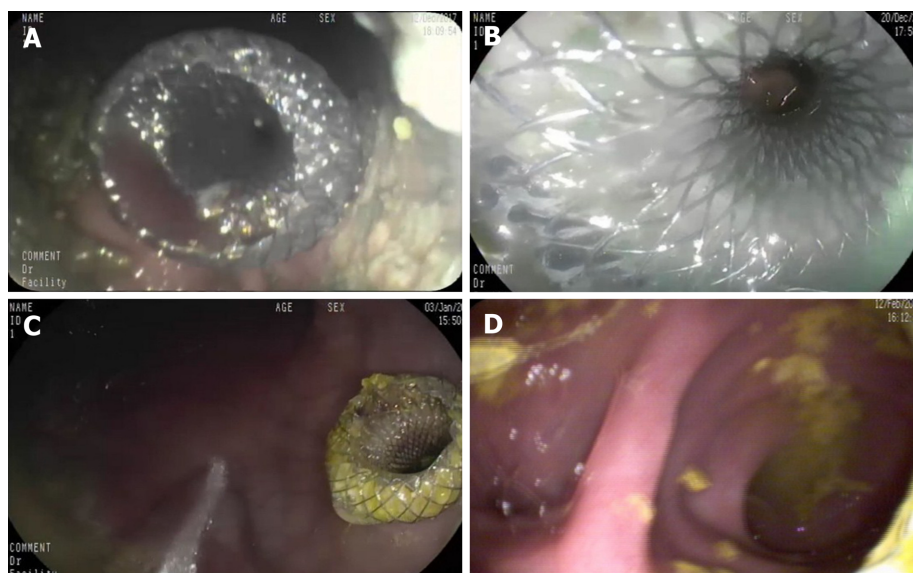
One of the challenges associated with direct EUS-GE is the inability to puncture the small bowel, despite the use of an ECE-LAMS, resulting in it being pushed away rather than punctured<sup>[11]</sup>. Inadequate expansion of the small bowel or rapid dissipation of the infused contrast and methylene blue (due to peristalsis) can also be limiting factors<sup>[11]</sup>. The RPAT method for EUS-GE did not use glucagon or other antispasmodic drugs to reduce the mobility of the bowel. The RPA can pull the intestine closer to the stomach wall to reduce intestinal mobility. Compared with traditional EUS-GE, RPAT reduces the distance between the stomach and the bowel, and provides sufficient reverse tension during ECE-LAMS implantation. With sufficient opposite pulling



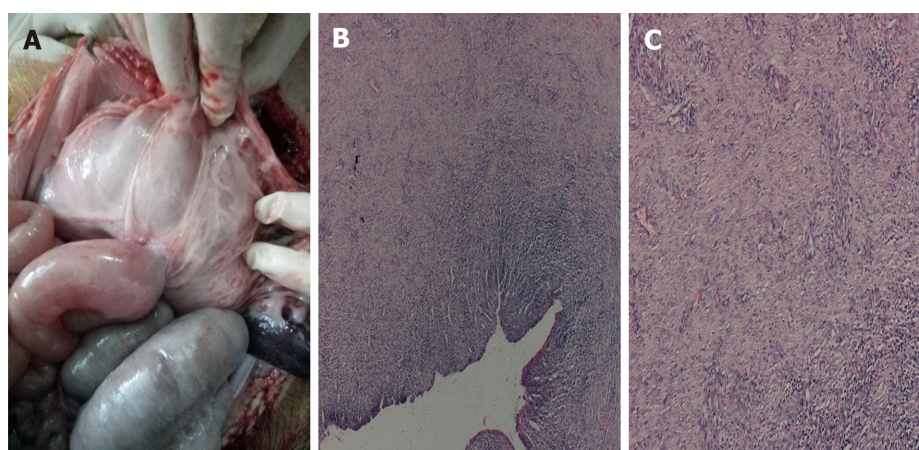
**Figure 2 The retrievable puncture anchor traction method.** A: Schematic diagram: The bowel is punctured under endoscopic ultrasound (EUS) guidance; B: Endoscopic ultrasound image: The bowel is punctured under EUS guidance; C: Schematic diagram: The retrievable puncture anchor is passed through the needle; D: Endoscopic ultrasound image: The anchor is inserted into the bowel; E: Schematic diagram: After pulling out the needle, the anchor attaches to the bowel; F: Endoscopic ultrasound image: After pulling out the needle, the anchor attaches to the bowel; G: Schematic diagram: The identified small-bowel loop is punctured again under EUS guidance. A guidewire is inserted through the needle. The small bowel is shown being punctured and drained using electrocautery-enhanced delivery of lumen-apposing metal stents over the guidewire; H: Endoscopic ultrasound image: The anchor-grasped bowel is shown under traction for stent implantation; I: Schematic diagram: The retrieval cord is pulled using a pair of forceps; J: Endoscopy image: The retrieval cord is pulled using a pair of forceps; K: Schematic diagram: The retrievable puncture anchor is easily removed; L: Endoscopy image: The retrievable puncture anchor is easily removed.

force, the ECE-LAMS is relatively easy to implant. The stomach wall and intestine of six experimental animals were clearly visible in the ultrasound field of view during the entire surgical procedure. We used an NBDC in the RPAT method to reduce the procedure time for EUS-GE, while avoiding the infusion of large amounts of saline into the intestine to prevent colon swelling. Prior to puncturing and guidewire insertion, a saline solution containing methylene blue was added in order to maintain the expansion of the bowel, provide a better field of view, and improve the safety of the operation.

In contrast to other techniques used with EUS-GE, the RPAT method for EUS-GE does not use a balloon, which reduces the difficulty of performing the operation as the advancement of the dilated balloon over the guidewire under fluoroscopic guidance



**Figure 3 Endoscopic imaging of stent placement and anastomoses.** A and B: Endoscopic imaging shows the well-reflected proximal flange of the stent immediately after deployment in the initial session; C: The stents were still in the same position 4 wk later and no traumatic changes were observed; D: A standard gastroscope was easily advanced through the anastomosis to observe the afferent and efferent bowel loops.



**Figure 4 Autopsy and histological findings.** A-C: Necropsy and histological evidence shows complete adhesion between the bowel and the stomach wall (20 ×).

can be quite challenging. Moreover, the RPAT method for EUS-GE is suitable for cases where the digestive tract is severely stenotic, allowing only the passage of liquid solution. The RPAT method for EUS-GE can help pull the intestine by pulling the anchor and can inflate the intestine by allowing the injection of saline solution through the NBDC at any time.

Although advanced EUS techniques and the availability of the proper equipment allow EUS-GE to be performed, the procedure is still in its early stages of development. This new technique is accompanied by technical issues requiring instrument modification that must be addressed prior to its clinical application<sup>[10,14-21]</sup>. Interventional EUS treatment is a newly developed method for the treatment of many diseases<sup>[9,19-22]</sup>. The small bowel has variable motility and thus tents away from the puncturing needle or the cautery tip of the ECE-LAMS. Hence, we have developed the RPAT method to improve the current EUS-GE method.

The success rate of EUS-GE using the RPAT method was 100% in our study. Remarkably, the retrievable puncture devices anchor to the bowel without causing tissue injury, and the RPA can also be removed without complications. Four weeks after the EUS-GE, it was found that all the stents remained in their original positions. Necropsy revealed complete adhesion between the intestinal wall and the stomach wall.

There are a few limitations in this study. First, the study consisted of a small

number of animals. Second, the follow-up period was four weeks, limiting the evaluation of long-term observations and results. Lastly, the procedure outcomes and findings were not compared to those of other non-EUS-guided gastrojejunostomy techniques<sup>[8]</sup>. A larger study with a longer follow-up period that compares several gastrojejunostomy techniques is needed.

In general, we proved the technical success of the RPAT method used with EUS-GE in a pig model. The RPAT method for EUS-GE is promising as a minimally invasive treatment. Clinical prospective trials are warranted to verify the efficacy of this treatment method. We are convinced that this treatment method can be widely used in EUS-GE in the future.

## ARTICLE HIGHLIGHTS

### **Research background**

Endoscopic ultrasound-guided gastroenterostomy (EUS-GE) is an alternative method for the surgical treatment of gastric outlet obstruction (GOO), but it is regarded as a challenging technique for endoscopists as the bowel is highly mobile and can tent away. Thus, the technique requires superb skill. In order to improve EUS-GE, we have developed a retrievable puncture anchor traction (RPAT) device for EUS-GE to address the issue of bowel tenting.

### **Research motivation**

One source of difficulty in EUS-GE is the high mobility of the intestine, which can tent away during puncture with a needle or electrocautery-enhanced delivery of lumen-apposing metal stents. In order to improve EUS-GE, we developed a RPAT method for EUS-GE. We evaluated the feasibility of the RPAT method using a pig model.

### **Research objectives**

The present study aimed to use an animal model to evaluate the feasibility of RPAT-assisted EUS-GE.

### **Research methods**

Six Bama mini pigs each weighing between 15 and 20 kg underwent the RPAT-assisted EUS-GE procedure. Care was taken to ensure that the animals experienced minimal pain and discomfort. Two days prior to the procedure the animals were limited to a liquid diet. No oral intake was allowed on the day before the procedure. A fully covered metal stent was placed between the stomach and the intestine using the RPAT-assisted EUS-GE method. Infection in the animals was determined. Four weeks after the procedure, a standard gastroscope was inserted into the pig's intestine through a previously created fistula in order to check the status of the stents under anesthesia. The pigs were euthanized after examination.

### **Research results**

The RPAT-assisted EUS-GE method allowed placement of the stents with no complications in all six animals. All the pigs tolerated a regular diet within hours of the procedure. The animals were monitored for four weeks after the RPAT-assisted EUS-GE, during which time all of the animals exhibited normal eating behavior and no signs of infection were observed. Endoscopic imaging performed four weeks after RPAT-assisted EUS-GE showed that the stents remained patent and stable in all the animals. No tissue overgrowth or ingrowth was observed. Each animal had a mature fistula, and the stents were removed without significant bleeding. Autopsies of all six pigs revealed complete adhesion between the intestine and the stomach wall.

### **Research conclusions**

The RPAT method helps reduce mobility of the bowel. Therefore, the RPAT-assisted EUS-GE method is a minimally invasive treatment modality.

### **Research perspectives**

We proved the technical success of the RPAT method used with EUS-GE in a pig model. The RPAT method for EUS-GE is promising as a minimally invasive treatment. Clinical prospective trials are warranted to verify the efficacy of this treatment method. We are convinced that this treatment method can be widely used in EUS-GE in the future.

## REFERENCES

- 1 **Zhang K**, Sun S, Guo J, Wang S, Ge N, Liu X, Wang G. Retrievable puncture anchor traction method for EUS-guided gallbladder drainage: a porcine study. *Gastrointest Endosc* 2018; **88**: 957-963 [PMID: 30048650 DOI: 10.1016/j.gie.2018.07.019]
- 2 **van Hooft JE**, Uitdehaag MJ, Bruno MJ, Timmer R, Siersema PD, Dijkgraaf MG, Fockens P. Efficacy and safety of the new WallFlex enteral stent in palliative treatment of malignant gastric outlet obstruction (DUOFLEX study): a prospective multicenter study. *Gastrointest Endosc* 2009; **69**: 1059-1066 [PMID: 19152912 DOI: 10.1016/j.gie.2008.07.026]
- 3 **Telford JJ**, Carr-Locke DL, Baron TH, Tringali A, Parsons WG, Gabbriellini A, Costamagna G. Palliation of patients with malignant gastric outlet obstruction with the enteral Wallstent: outcomes from a multicenter study. *Gastrointest Endosc* 2004; **60**: 916-920 [PMID: 15605006 DOI: 10.1016/s0016-5107(04)02228-x]
- 4 **Khashab M**, Alawad AS, Shin EJ, Kim K, Bourdel N, Singh VK, Lennon AM, Hutfless S, Sharaiha RZ, Amateau S, Okolo PI, Makary MA, Wolfgang C, Canto MI, Kalloo AN. Enteral stenting versus gastrojejunostomy for palliation of malignant gastric outlet obstruction. *Surg Endosc* 2013; **27**: 2068-2075 [PMID: 23299137 DOI: 10.1007/s00464-012-2712-7]
- 5 **Doberneck RC**, Berndt GA. Delayed gastric emptying after palliative gastrojejunostomy for carcinoma of the pancreas. *Arch Surg* 1987; **122**: 827-829 [PMID: 2439057 DOI: 10.1001/archsurg.1987.01400190093020]
- 6 **Itoi T**, Ishii K, Tanaka R, Umeda J, Tonozuka R. Current status and perspective of endoscopic ultrasonography-guided gastrojejunostomy: endoscopic ultrasonography-guided double-balloon-occluded gastrojejunostomy (with videos). *J Hepatobiliary Pancreat Sci* 2015; **22**: 3-11 [PMID: 25155270 DOI: 10.1002/jhbp.148]
- 7 **Fritscher-Ravens A**, Mosse CA, Mills TN, Mukherjee D, Park PO, Swain P. A through-the-scope device for suturing and tissue approximation under EUS control. *Gastrointest Endosc* 2002; **56**: 737-742 [PMID: 12397289 DOI: 10.1067/mge.2002.129084]
- 8 **Binmoeller KF**, Shah JN. Endoscopic ultrasound-guided gastroenterostomy using novel tools designed for transluminal therapy: a porcine study. *Endoscopy* 2012; **44**: 499-503 [PMID: 22531985 DOI: 10.1055/s-0032-1309382]
- 9 **Itoi T**, Itokawa F, Uraoka T, Gotoda T, Horii J, Goto O, Moriyasu F, Moon JH, Kitagawa Y, Yahagi N. Novel EUS-guided gastrojejunostomy technique using a new double-balloon enteric tube and lumen-apposing metal stent (with videos). *Gastrointest Endosc* 2013; **78**: 934-939 [PMID: 24237949 DOI: 10.1016/j.gie.2013.09.025]
- 10 **Rimbas M**, Larghi A, Costamagna G. Endoscopic ultrasound-guided gastroenterostomy: Are we ready for prime time? *Endosc Ultrasound* 2017; **6**: 235-240 [PMID: 28820145 DOI: 10.4103/eus.eus\_47\_17]
- 11 **Irani S**, Baron TH, Itoi T, Khashab MA. Endoscopic gastroenterostomy: techniques and review. *Curr Opin Gastroenterol* 2017; **33**: 320-329 [PMID: 28767501 DOI: 10.1097/MOG.0000000000000389]
- 12 **Chen YI**, James TW, Agarwal A, Baron TH, Itoi T, Kunda R, Nieto J, Bukhari M, Gutierrez OB, Sanaei O, Moran R, Fayad L, Khashab MA. EUS-guided gastroenterostomy in management of benign gastric outlet obstruction. *Endosc Int Open* 2018; **6**: E363-E368 [PMID: 29527559 DOI: 10.1055/s-0043-123468]
- 13 **Itoi T**, Ishii K, Ikeuchi N, Sofuni A, Gotoda T, Moriyasu F, Dhir V, Teoh AY, Binmoeller KF. Prospective evaluation of endoscopic ultrasonography-guided double-balloon-occluded gastrojejunostomy bypass (EPASS) for malignant gastric outlet obstruction. *Gut* 2016; **65**: 193-195 [PMID: 26282674 DOI: 10.1136/gutjnl-2015-310348]
- 14 **Manvar A**, Karia K, Ho S. Endoscopic ultrasound-guided drainage of pelvic abscesses with lumen-apposing metal stents. *Endosc Ultrasound* 2017; **6**: 217-218 [PMID: 28820143 DOI: 10.4103/eus.eus\_46\_17]
- 15 **Adler DG**, Taylor LJ, Hasan R, Siddiqui AA. A retrospective study evaluating endoscopic ultrasound-guided drainage of pancreatic fluid collections using a novel lumen-apposing metal stent on an electrocautery enhanced delivery system. *Endosc Ultrasound* 2017; **6**: 389-393 [PMID: 29251273 DOI: 10.4103/eus.eus\_4\_17]
- 16 **De Cobelli F**, Marra P, Diana P, Brembilla G, Venturini M. Therapeutic EUS: Biliary drainage - The interventional radiologist's perspective. *Endosc Ultrasound* 2017; **6**: S127-S131 [PMID: 29387709 DOI: 10.4103/eus.eus\_77\_17]
- 17 **Rimbas M**, Larghi A. Endoscopic Ultrasonography-Guided Techniques for Accessing and Draining the Biliary System and the Pancreatic Duct. *Gastrointest Endosc Clin N Am* 2017; **27**: 681-705 [PMID: 28918805 DOI: 10.1016/j.giec.2017.06.006]
- 18 **Saumoy M**, Arvanitakis M, Kahaleh M. Pancreatic fluid collections and necrosectomy with plastic stents versus lumen-apposing stents. *Endosc Ultrasound* 2017; **6**: S132-S137 [PMID: 29387710 DOI: 10.4103/eus.eus\_80\_17]
- 19 **Giovannini M**. Endoscopic ultrasound-guided pancreatic duct drainage: Ready for the prime time? *Endosc Ultrasound* 2017; **6**: 281-284 [PMID: 29063870 DOI: 10.4103/eus.eus\_86\_17]
- 20 **Itoi T**, Binmoeller KF, Shah J, Sofuni A, Itokawa F, Kurihara T, Tsuchiya T, Ishii K, Tsuji S, Ikeuchi N, Moriyasu F. Clinical evaluation of a novel lumen-apposing metal stent for endosonography-guided pancreatic pseudocyst and gallbladder drainage (with videos). *Gastrointest Endosc* 2012; **75**: 870-876 [PMID: 22301347 DOI: 10.1016/j.gie.2011.10.020]
- 21 **Teoh AY**, Binmoeller KF, Lau JY. Single-step EUS-guided puncture and delivery of a lumen-apposing stent for gallbladder drainage using a novel cautery-tipped stent delivery system. *Gastrointest Endosc* 2014; **80**: 1171 [PMID: 24830582 DOI: 10.1016/j.gie.2014.03.038]
- 22 **Binmoeller KF**, Shah J. A novel lumen-apposing stent for transluminal drainage of nonadherent extraintestinal fluid collections. *Endoscopy* 2011; **43**: 337-342 [PMID: 21264800 DOI: 10.1055/s-0030-1256127]



Published by **Baishideng Publishing Group Inc**  
7041 Koll Center Parkway, Suite 160, Pleasanton, CA 94566, USA

**Telephone:** +1-925-3991568

**E-mail:** [bpgoffice@wjgnet.com](mailto:bpgoffice@wjgnet.com)

**Help Desk:** <https://www.f6publishing.com/helpdesk>

<https://www.wjgnet.com>

