


World Journal of *Gastroenterology*

World J Gastroenterol 2020 August 7; 26(29): 4182-4377



REVIEW

- 4182** Impact of mobile health and medical applications on clinical practice in gastroenterology
Kernebeck S, Busse TS, Böttcher MD, Weitz J, Ehlers J, Bork U
- 4198** Endoscopic management of gastrointestinal leaks and fistulae: What option do we have?
Cereatti F, Grassia R, Drago A, Conti CB, Donatelli G
- 4218** Watch and wait approach in rectal cancer: Current controversies and future directions
López-Campos F, Martín-Martín M, Fornell-Pérez R, García-Pérez JC, Die-Trill J, Fuentes-Mateos R, López-Durán S, Domínguez-Rullán J, Ferreira R, Riquelme-Oliveira A, Hervás-Morón A, Couñago F
- 4240** Role of long noncoding RNA-mediated competing endogenous RNA regulatory network in hepatocellular carcinoma
Niu ZS, Wang WH, Dong XN, Tian LML

MINIREVIEWS

- 4261** Gadoteric acid magnetic-enhanced resonance imaging in the diagnosis of cholangiocarcinoma
Inchingolo R, Maino C, Gatti M, Tricarico E, Nardella M, Grazioli L, Sironi S, Ippolito D, Faletti R

ORIGINAL ARTICLE

Basic Study

- 4272** Rno_circ_0005139 regulates apoptosis by targeting *Wnt5a* in rat anorectal malformations
Liu D, Qu Y, Cao ZN, Jia HM

Clinical and Translational Research

- 4288** Role of nutritional status and nutritional support in outcome of hepatitis B virus-associated acute-on-chronic liver failure
Chang Y, Liu QY, Zhang Q, Rong YM, Lu CZ, Li H

Retrospective Cohort Study

- 4302** Evaluation of intrahepatic manifestation and distant extrahepatic disease in alveolar echinococcosis
Graeter T, Bao HH, Shi R, Liu WY, Li WX, Jiang Y, Schmidberger J, Brumpt E, Delabrousse E, Kratzer W, the XUUB Consortium

Retrospective Study

- 4316** Multivariate predictive model for asymptomatic spontaneous bacterial peritonitis in patients with liver cirrhosis
Tu B, Zhang YN, Bi JF, Xu Z, Zhao P, Shi L, Zhang X, Yang G, Qin EQ

- 4327 Clinicopathological characteristics and surgical outcomes of sarcomatoid hepatocellular carcinoma
Wang JP, Yao ZG, Sun YW, Liu XH, Sun FK, Lin CH, Ren FX, Lv BB, Zhang SJ, Wang Y, Meng FY, Zheng SZ, Gong W, Liu J

Observational Study

- 4343 Patients' perspectives on smoking and inflammatory bowel disease: An online survey in collaboration with European Federation of Crohn's and Ulcerative Colitis Associations
Le Berre C, Loy L, Lönnfors S, Avedano L, Piovani D

META-ANALYSIS

- 4356 Dysregulation of microRNA in cholangiocarcinoma identified through a meta-analysis of microRNA profiling
Likhitrattanapisal S, Kumkate S, Ajawatanawong P, Wongprasert K, Tohtong R, Janvilisri T

CASE REPORT

- 4372 Multifocal gastrointestinal epithelioid angiosarcomas diagnosed by endoscopic mucosal resection: A case report
Chen YW, Dong J, Chen WY, Dai YN

ABOUT COVER

Editorial board member of *World Journal of Gastroenterology*, Dr. Feng Yang is a distinguished Associate Professor at the Shanghai Medical College Affiliated to Fudan University in Shanghai, China. Having received his Bachelor's degree from Fudan University in 2003, Dr. Yang undertook his postgraduate study and surgical resident training at the Department of Surgery in Huashan Hospital Affiliated to Fudan University, receiving his PhD in 2008. He became Associate Chief Physician at the Division of Pancreatic Surgery in Huashan Hospital Affiliated to Fudan University in 2015 and has held the position since. His ongoing research interests involve basic and clinical study of metastasis and recurrence of pancreatic neoplasms, including pancreatic carcinomas, neuroendocrine tumors and solid pseudopapillary tumors. Currently, he serves as a Young Member of the Pancreatic Cancer Committee, Chinese Anti-cancer Association. He also serves as a peer reviewer for many international academic journals.

AIMS AND SCOPE

The primary aim of *World Journal of Gastroenterology* (WJG, *World J Gastroenterol*) is to provide scholars and readers from various fields of gastroenterology and hepatology with a platform to publish high-quality basic and clinical research articles and communicate their research findings online. WJG mainly publishes articles reporting research results and findings obtained in the field of gastroenterology and hepatology and covering a wide range of topics including gastroenterology, hepatology, gastrointestinal endoscopy, gastrointestinal surgery, gastrointestinal oncology, and pediatric gastroenterology.

INDEXING/ABSTRACTING

The WJG is now indexed in Current Contents®/Clinical Medicine, Science Citation Index Expanded (also known as SciSearch®), Journal Citation Reports®, Index Medicus, MEDLINE, PubMed, PubMed Central, and Scopus. The 2020 edition of Journal Citation Report® cites the 2019 impact factor (IF) for WJG as 3.665; IF without journal self cites: 3.534; 5-year IF: 4.048; Ranking: 35 among 88 journals in gastroenterology and hepatology; and Quartile category: Q2.

RESPONSIBLE EDITORS FOR THIS ISSUE

Electronic Editor: *Yun-Jie Ma*; Production Department Director: *Xiang Li*; Editorial Office Director: *Ze-Mao Gong*.

NAME OF JOURNAL

World Journal of Gastroenterology

ISSN

ISSN 1007-9327 (print) ISSN 2219-2840 (online)

LAUNCH DATE

October 1, 1995

FREQUENCY

Weekly

EDITORS-IN-CHIEF

Andrzej S Tarnawski, Subrata Ghosh

EDITORIAL BOARD MEMBERS

<http://www.wjgnet.com/1007-9327/editorialboard.htm>

PUBLICATION DATE

August 7, 2020

COPYRIGHT

© 2020 Baishideng Publishing Group Inc

INSTRUCTIONS TO AUTHORS

<https://www.wjgnet.com/bpg/gerinfo/204>

GUIDELINES FOR ETHICS DOCUMENTS

<https://www.wjgnet.com/bpg/GerInfo/287>

GUIDELINES FOR NON-NATIVE SPEAKERS OF ENGLISH

<https://www.wjgnet.com/bpg/gerinfo/240>

PUBLICATION ETHICS

<https://www.wjgnet.com/bpg/GerInfo/288>

PUBLICATION MISCONDUCT

<https://www.wjgnet.com/bpg/gerinfo/208>

ARTICLE PROCESSING CHARGE

<https://www.wjgnet.com/bpg/gerinfo/242>

STEPS FOR SUBMITTING MANUSCRIPTS

<https://www.wjgnet.com/bpg/GerInfo/239>

ONLINE SUBMISSION

<https://www.f6publishing.com>



Multifocal gastrointestinal epithelioid angiosarcomas diagnosed by endoscopic mucosal resection: A case report

You-Wei Chen, Jie Dong, Wan-Yuan Chen, Yi-Ning Dai

ORCID number: You-Wei Chen 0000-0002-5663-6118; Jie Dong 0000-0002-2338-8955; Wan-Yuan Chen 0000-0002-8216-9568; Yi-Ning Dai 0000-0002-7735-1381.

Author contributions: Chen YW was the patient's doctor, who performed the gastroscopy, colonoscopy and endoscopic mucosal resection; Dong J was responsible for collecting medical history of the patient and drafting the paper; Chen WY was a pathologist who provided the pathological results; Dai YN reviewed the literature and revised the manuscript; all authors issued final approval for the version to be submitted.

Informed consent statement: Informed written consent was obtained from the patient for publication of this report and any accompanying images.

Conflict-of-interest statement: The authors have declared that no conflict of interests exists.

CARE Checklist (2016) statement: The authors have read the CARE Checklist (2016), and the manuscript was prepared and revised according to the CARE Checklist (2016).

Open-Access: This article is an open-access article that was

You-Wei Chen, Jie Dong, Department of Gastroenterology, Zhejiang Provincial People's Hospital, People's Hospital of Hangzhou Medical College, Hangzhou 310014, Zhejiang Province, China

Wan-Yuan Chen, Department of Pathology, Zhejiang Provincial People's Hospital, People's Hospital of Hangzhou Medical College, Hangzhou 310014, Zhejiang Province, China

Yi-Ning Dai, Department of Infectious Diseases, Zhejiang Provincial People's Hospital, Hangzhou 310014, Zhejiang Province, China

Corresponding author: Yi-Ning Dai, MD, Chief Physician, Department of Infectious Diseases, Zhejiang Provincial People's Hospital, No. 158, Shangtang Road, Hangzhou 310014, Zhejiang Province, China. daiyn@zju.edu.cn

Abstract

BACKGROUND

Epithelioid angiosarcoma is a vascular neoplasm that is among the most aggressive subtypes of sarcomas. Its involvement in the gastrointestinal tract is rare. We here report a case of multifocal gastrointestinal epithelioid angiosarcomas presenting with gastrointestinal bleeding.

CASE SUMMARY

A 77-year-old woman was admitted because of melena and dizziness for three months. Gastroscopy and colonoscopy were performed, revealing a centrally ulcerated hemorrhagic polypoid lesion in the gastric body and multiple polypoid lesions with blood clots and hemorrhagic tendency in the colon. Histopathological examination of routine endoscopic biopsy samples showed inflammation in the gastric mucosa and tubular adenomas in the colon. The polypoid lesions were removed by endoscopic mucosal resection. Immunohistochemistry suggested a final diagnosis of epithelioid angiosarcomas. The patient refused chemotherapy and died after three months.

CONCLUSION

Epithelioid angiosarcomas are characterized by highly vascular nature and tendency to cause gastrointestinal bleeding. Efforts to obtain histological findings using endoscopic mucosal resection are of great importance.

Key words: Epithelioid angiosarcoma; Gastrointestinal tract; Endoscopic mucosal

selected by an in-house editor and fully peer-reviewed by external reviewers. It is distributed in accordance with the Creative Commons Attribution NonCommercial (CC BY-NC 4.0) license, which permits others to distribute, remix, adapt, build upon this work non-commercially, and license their derivative works on different terms, provided the original work is properly cited and the use is non-commercial. See: <http://creativecommons.org/licenses/by-nc/4.0/>

Manuscript source: Unsolicited manuscript

Received: April 7, 2020

Peer-review started: April 7, 2020

First decision: April 29, 2020

Revised: May 9, 2020

Accepted: July 15, 2020

Article in press: July 15, 2020

Published online: August 7, 2020

P-Reviewer: Perrotti S, Zhang YX

S-Editor: Zhang L

L-Editor: MedE-Ma JY

E-Editor: Li JH



resection; Polypoid lesion; Immunohistochemistry; Case report

©The Author(s) 2020. Published by Baishideng Publishing Group Inc. All rights reserved.

Core tip: Gastrointestinal epithelioid angiosarcoma is extremely rare, which is only described in individual case reports and case series. Most reported cases appeared as centrally ulcerated, hemorrhagic, highly erythematous or purpuric nodules. Histopathology is the golden standard for diagnosis. Endoscopic biopsy often obtains insufficient specimens, while endoscopic mucosal resection of suspected lesions is satisfactory for histopathological examination. We here report a case of gastrointestinal bleeding which was finally diagnosed as multifocal epithelioid angiosarcomas in the gastrointestinal tract.

Citation: Chen YW, Dong J, Chen WY, Dai YN. Multifocal gastrointestinal epithelioid angiosarcomas diagnosed by endoscopic mucosal resection: A case report. *World J Gastroenterol* 2020; 26(29): 4372-4377

URL: <https://www.wjgnet.com/1007-9327/full/v26/i29/4372.htm>

DOI: <https://dx.doi.org/10.3748/wjg.v26.i29.4372>

INTRODUCTION

Epithelioid angiosarcoma is a sporadic, highly aggressive malignancy that originates from a variety of locations, most commonly from the skin and soft tissue^[1]. This type of tumor occasionally occurs in the liver, spleen, ovary, breast and adrenal gland^[2]. Primary gastrointestinal angiosarcoma is extremely rare^[3,4]. Here, we present a case of multifocal epithelioid angiosarcomas involved in the gastrointestinal tract.

CASE PRESENTATION

Chief complaints

A previous healthy 77-year-old woman presented with a 3-mo history of melena and dizziness and was admitted to our hospital.

Physical and accessory examinations

The physical examination was unremarkable except for pale conjunctiva. Her hemoglobin level was 65 g/L. The platelet count, coagulation function, and blood biochemistry were within normal limits. The antinuclear antibody titre was 1:1000, while the anti-SSA (Ro60) antibodies were weakly positive. Autoimmune diseases were ruled out by rheumatologists because there were no related symptoms. Abdominal computed tomography angiography revealed nothing remarkable.

Endoscopy and histopathology

Gastroscopy demonstrated a centrally ulcerated haemorrhagic polypoid lesion in the gastric body (Figure 1A). Colonoscopy revealed multiple polypoid lesions with blood clots and hemorrhagic tendency in the ileocecum, ascending colon, transverse colon and sigmoid colon (Figure 1B-D). Routine endoscopic biopsies showed inflammatory infiltration in the gastric mucosa and tubular adenomas with low-grade intraepithelial neoplasia and local eosinophilic changes in the colon. Nevertheless, the pathologic findings did not conform to the endoscopic appearance of the foci. Subsequently, the lesions were resected *en bloc* by endoscopic mucosal resection for further diagnosis.

Microscopically, hematoxylin and eosin staining showed areas of epithelioid cells with abundant eosinophilic cytoplasm, which was morphologically similar to undifferentiated carcinoma or poorly differentiated adenocarcinoma (Figure 2). Immunohistochemical staining (Figure 3) demonstrated that the tumor cells were positive for pan-cytokeratin (AE1/AE3), CD31, CD34, EMA, vimentin and Ki67 (60% positive) and negative for hepatocytes, S100, CD117, DOG1, CD56, SYN, CgA, LCA, desmin or ALK. The final pathological diagnosis was epithelioid angiosarcoma.

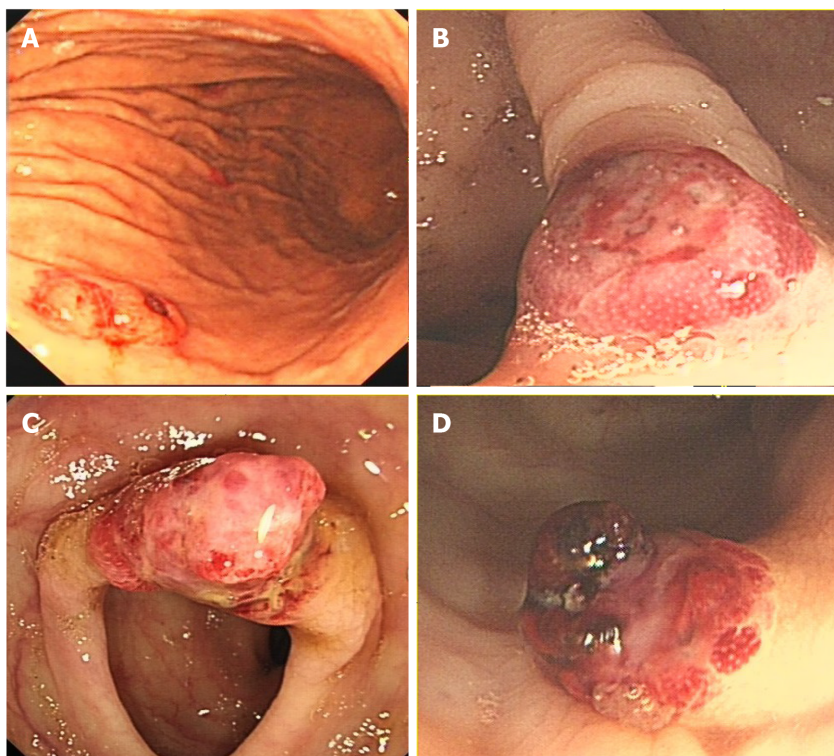


Figure 1 Endoscopy. A: Gastroscope revealed a 0.5 cm × 0.6 cm centrally ulcerated polypoid lesion in the gastric body; B: A 0.8 cm × 0.8 cm polypoid lesion in the ascending colon; C: A 1.2 cm × 1.0 cm hyperaemic mass in the transverse colon; and D: A 0.8 cm × 0.8 cm polypoid nodule with hemorrhagic tendency and blood clots in the sigmoid colon.

Positron emission tomography/computed tomography

To determine whether distant metastasis occurred, additional F-18 fluorodeoxyglucose positron emission tomography/computed tomography (PET/CT) was performed. PET/CT showed tubular hypermetabolic lesions in the colon, suggesting malignancy. Furthermore, numerous hypermetabolic hilar and mediastinal lymph nodes, as well as multiple node-like foci with active F-18 fluorodeoxyglucose metabolism in the bones, were observed, revealing lymphatic and osseous metastasis (Figure 4).

FINAL DIAGNOSIS

Multifocal gastrointestinal epithelioid angiosarcomas with lymphatic and osseous metastasis.

OUTCOME AND FOLLOW-UP

The patient refused chemotherapy and died after three months due to gastrointestinal bleeding.

DISCUSSION

Angiosarcomas may arise in any part of the body, but commonly occur in skin and superficial soft tissues, with its predilection sites in the head and neck^[5]. Epithelioid angiosarcoma of the gastrointestinal tract is an extremely rare neoplasm, which is only described in individual case reports and case series^[6-9], with a lack of demographic morbidity data. According to literatures, vascular tumors of the stomach constitute only 0.9%-3.3% of all gastric cancers^[10], while colorectal angiosarcomas represent less than 0.001% of all colorectal neoplasms^[11].

Epithelioid angiosarcoma is characterized by an extremely aggressive course, leading to a very poor prognosis^[12]. Even for localized disease, patients without any

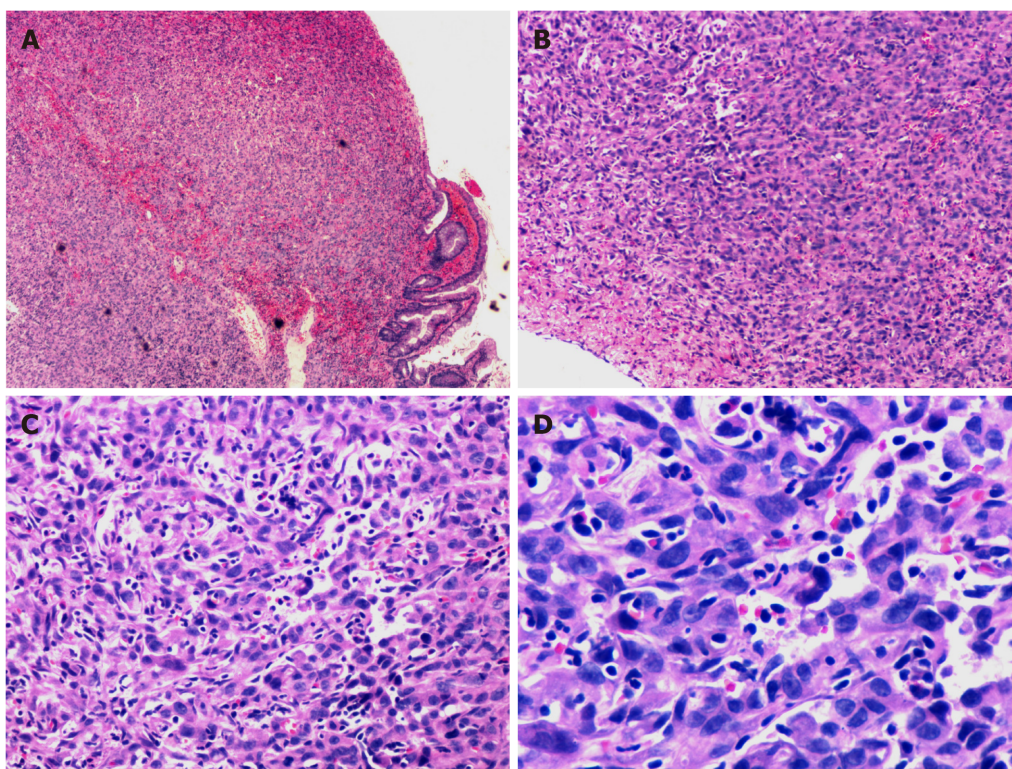


Figure 2 Histopathological findings. Poorly differentiated neoplasms consisting of large cells with pleomorphic nuclei and abundant eosinophilic cytoplasm were observed. A: Haematoxylin and eosin (HE) staining section $\times 40$; B: HE staining section ($\times 100$); C: HE staining section ($\times 200$); and D: HE staining section ($\times 400$).

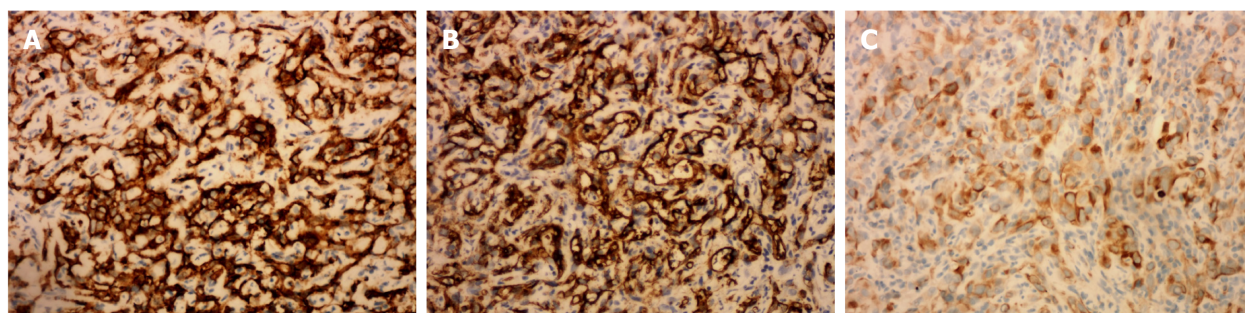


Figure 3 Immunohistochemical staining. A: Immunostaining for CD31; B: Immunostaining for CD34; and C: Immunostaining for pan-cytokeratin.

therapy had a 0% survival rate at 2 years^[5]. Due to the infiltrative nature of this neoplasm, recurrence and metastasis are frequent after surgical resection, even for localized disease. Cytotoxic chemotherapy can be effective in a subset of patients for a limited period, but metastatic angiosarcomas remain incurable and even fatal^[5]. Targeted therapy with tyrosine kinase inhibitors usually resulted in significant responses, but these tumors are prone to developing resistance^[6].

In most cases of gastrointestinal angiosarcoma, the symptoms are nonspecific, including abdominal pain, weight loss and anorexia. Overt bleeding with melena or hematochezia is less common. The patient in the present report had positive antinuclear antibody and anti-SSA, which might be secondary to the tumor. Nevertheless, until now, there is no evidence that the positivity of autoimmune antibodies has association with angiosarcomas. Further studies are needed to clarify their relationships.

Almost all reported lesions that occurred in the gastrointestinal tract appeared endoscopically as centrally ulcerated, hemorrhagic, highly erythematous or purpuric nodules/masses^[13]. Endoscopy with direct visualization and biopsy is crucial for diagnosis. However, endoscopic biopsy often obtains insufficient specimens and leads to the possibility of a missed diagnosis^[14], similar to this case. It is well known that

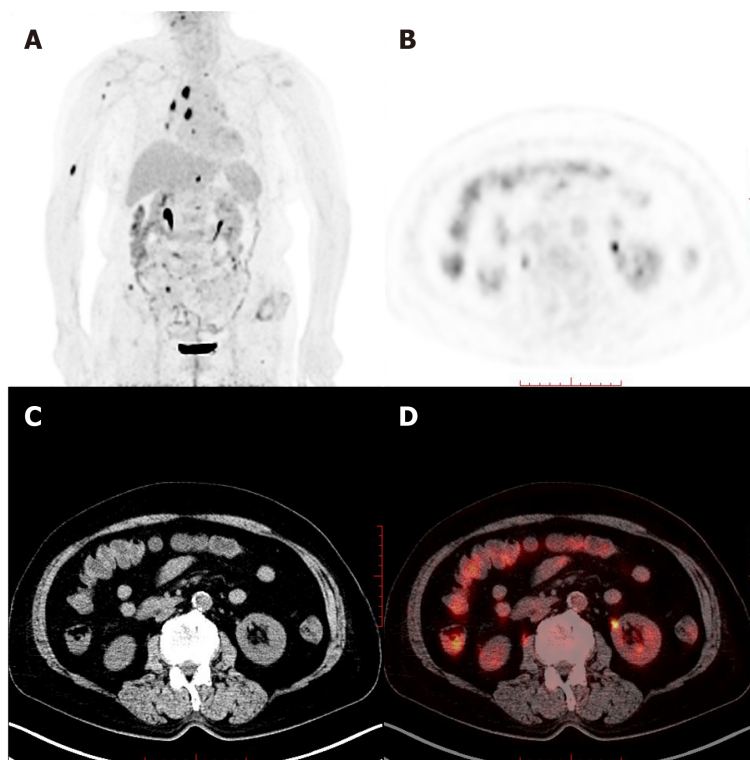


Figure 4 Whole-body maximum intensity projection 18F-fluorodeoxyglucose and positron emission tomography image. A: Remarkably increased fluorodeoxyglucose metabolism in the colon and mediastinal lymph nodes, as well as the right humerus; B: Positron emission tomography; C: Computed tomography; and D: Positron emission tomography/computed tomography in axial projection showed multiple tubular hypermetabolic lesions in the colon.

invasive carcinomas are likely to be covered by normal epithelium or intraepithelial neoplasm. Consequently, findings of the biopsy on their surface usually do not reflect the invasive components. Possible efforts to obtain additional histopathological findings must be made. In the present case, *en bloc* endoscopic mucosal resection of the suspected lesions in the colon was satisfactory for the histopathological examination. Due to the confirmation of malignant angiosarcomas, the patient refused to have another large-scale biopsy of the gastric lesion, in which the endoscopic performance was similar and typical.

Epithelioid angiosarcoma mimics carcinoma morphologically and contains numerous vasoformative structures. Because of the high architectural and cytological variability, pathological diagnosis is difficult. Immunoreactivity for endothelial and epithelial cell markers can confirm the diagnosis. This innate characteristic of epithelioid angiosarcoma corresponds to the tendency of gastrointestinal bleeding. PET/CT has been reported to detect primary uterine and pulmonary epithelioid angiosarcoma^[15,16] and is of great value in identifying metastases.

CONCLUSION

We report a case of gastrointestinal bleeding that was finally diagnosed as multifocal epithelioid angiosarcomas involved in the gastrointestinal tract. The endoscopic characteristics of the lesions were highlighted and corresponded to the propensity of gastrointestinal bleeding. *En bloc* endoscopic mucosal resection contributed to the final histopathological diagnosis.

REFERENCES

- 1 Young RJ, Brown NJ, Reed MW, Hughes D, Woll PJ. Angiosarcoma. *Lancet Oncol* 2010; **11**: 983-991 [PMID: 20537949 DOI: 10.1016/S1470-2045(10)70023-1]
- 2 Chou JW, Cheng KS, Chen SF. Primary hepatic angiosarcoma with multifocal metastases in the gastrointestinal tract. *Endoscopy* 2013; **45** Suppl 2 UCTN: E319-E320 [PMID: 24008486 DOI: 10.1055/s-0033-1344574]

- 3 **Zhai ZZ**, Wang L, Zuo XL. A Rare Cause of Gastrointestinal Bleeding in a Patient With a History of Alcoholic Cirrhosis. *Gastroenterology* 2019; **156**: e6-e8 [PMID: [30240671](#) DOI: [10.1053/j.gastro.2018.09.030](#)]
- 4 **Louie J**, Tejaswi S, Matsukuma K. Colonic Angiosarcoma: A Rare Gastrointestinal Malignancy. *Clin Gastroenterol Hepatol* 2020; **18**: e75 [PMID: [30981006](#) DOI: [10.1016/j.cgh.2019.04.019](#)]
- 5 **Florou V**, Wilky BA. Current and Future Directions for Angiosarcoma Therapy. *Curr Treat Options Oncol* 2018; **19**: 14 [PMID: [29520447](#) DOI: [10.1007/s11864-018-0531-3](#)]
- 6 **Jayaraman V**, Wilkinson MN, Nagula S, Siebel M, Bucobo JC, Zee S, Buscaglia JM. Primary jejunal angiosarcoma: an extremely rare tumor diagnosed by means of anterograde spiral enteroscopy. *Endoscopy* 2011; **43** Suppl 2 UCTN: E219-E220 [PMID: [21590614](#) DOI: [10.1055/s-0030-1256397](#)]
- 7 **Leong J**, Rascon MA, Kaushik N. Multifocal angiosarcoma of the gastrointestinal tract. *Endoscopy* 2008; **40** Suppl 2: E252-E253 [PMID: [18991227](#) DOI: [10.1055/s-2008-1077645](#)]
- 8 **Coumaros D**, Tsesmeli N. Epithelioid angiosarcoma in the duodenal bulb. *Endoscopy* 2009; **41** Suppl 2: E232 [PMID: [19757369](#) DOI: [10.1055/s-0029-1214480](#)]
- 9 **Al Ali J**, Ko HH, Owen D, Steinbrecher UP. Epithelioid angiosarcoma of the small bowel. *Gastrointest Endosc* 2006; **64**: 1018-1021 [PMID: [17140922](#) DOI: [10.1016/j.gie.2006.04.020](#)]
- 10 **Tai CM**, Hung CM, Lee TC, Chang HC, Wang HP. Primary gastric angiosarcoma presenting as an asymptomatic gastric submucosal tumor. *J Formos Med Assoc* 2007; **106**: 961-964 [PMID: [18063519](#) DOI: [10.1016/S0929-6646\(08\)60068-6](#)]
- 11 **Al Betedini OS**, Brenez D, Firket C, Algaba R, Tabeach A. Colonic angiosarcoma: A case report and review of literature. *Int J Surg Case Rep* 2013; **4**: 208-211 [PMID: [23279809](#) DOI: [10.1016/j.ijscr.2012.11.021](#)]
- 12 **Grewal JS**, Daniel AR, Carson EJ, Catanzaro AT, Shehab TM, Tworek JA. Rapidly progressive metastatic multicentric epithelioid angiosarcoma of the small bowel: a case report and a review of literature. *Int J Colorectal Dis* 2008; **23**: 745-756 [PMID: [18080128](#) DOI: [10.1007/s00384-007-0420-x](#)]
- 13 **Saad A**, Cappell MS, Amin M. Endoscopic findings with GI angiosarcoma correspond with the propensity of these vascular tumors to cause GI bleeding: two case reports and review of the literature. *Dig Dis Sci* 2013; **58**: 1797-1801 [PMID: [23400736](#) DOI: [10.1007/s10620-013-2582-4](#)]
- 14 **Lee CK**, Chung IK, Lee SH, Kim SP, Lee SH, Lee TH, Kim HS, Park SH, Kim SJ, Lee JH, Cho HD, Oh MH. Is endoscopic forceps biopsy enough for a definitive diagnosis of gastric epithelial neoplasia? *J Gastroenterol Hepatol* 2010; **25**: 1507-1513 [PMID: [20796147](#) DOI: [10.1111/j.1440-1746.2010.006367.x](#)]
- 15 **Treglia G**, Cardillo G, Graziano P. A rare case of primary pulmonary epithelioid angiosarcoma detected by (18)F-FDG PET/CT. *Clin Nucl Med* 2014; **39**: 450-452 [PMID: [23657141](#) DOI: [10.1097/RLU.0b013e318292f3b3](#)]
- 16 **Hwang JP**, Lim SM. Uterine Epithelioid Angiosarcoma on F-18 FDG PET/CT. *Nucl Med Mol Imaging* 2013; **47**: 134-137 [PMID: [24900095](#) DOI: [10.1007/s13139-013-0191-y](#)]



Published by **Baishideng Publishing Group Inc**
7041 Koll Center Parkway, Suite 160, Pleasanton, CA 94566, USA

Telephone: +1-925-3991568

E-mail: bpgoffice@wjgnet.com

Help Desk: <https://www.f6publishing.com/helpdesk>

<https://www.wjgnet.com>

