

World Journal of *Gastroenterology*

World J Gastroenterol 2020 October 28; 26(40): 6111-6303



REVIEW

- 6111** Cirrhotic portal hypertension: From pathophysiology to novel therapeutics

Gunarathe LS, Rajapaksha H, Shackel N, Angus PW, Herath CB

- 6141** Role of gut microbiota *via* the gut-liver-brain axis in digestive diseases

Ding JH, Jin Z, Yang XX, Lou J, Shan WX, Hu YX, Du Q, Liao QS, Xie R, Xu JY

MINIREVIEWS

- 6163** Imaging-based algorithmic approach to gallbladder wall thickening

Gupta P, Marodia Y, Bansal A, Kalra N, Kumar-M P, Sharma V, Dutta U, Sandhu MS

- 6182** Overlooked risk for needle tract seeding following endoscopic ultrasound-guided minimally invasive tissue acquisition

Gao RY, Wu BH, Shen XY, Peng TL, Li DF, Wei C, Yu ZC, Luo MH, Xiong F, Wang LS, Yao J

- 6195** Prevalence, diagnosis, and treatment of primary hepatic gastrointestinal stromal tumors

Qian XH, Yan YC, Gao BQ, Wang WL

ORIGINAL ARTICLE

Basic Study

- 6207** Prediction of clinically actionable genetic alterations from colorectal cancer histopathology images using deep learning

Jang HJ, Lee A, Kang J, Song IH, Lee SH

- 6224** New strain of *Pediococcus pentosaceus* alleviates ethanol-induced liver injury by modulating the gut microbiota and short-chain fatty acid metabolism

Jiang XW, Li YT, Ye JZ, Lv LX, Yang LY, Bian XY, Wu WR, Wu JJ, Shi D, Wang Q, Fang DQ, Wang KC, Wang QQ, Lu YM, Xie JJ, Li LJ

Retrospective Cohort Study

- 6241** Predicting cholecystocholedochal fistulas in patients with Mirizzi syndrome undergoing endoscopic retrograde cholangiopancreatography

Wu CH, Liu NJ, Yeh CN, Wang SY, Jan YY

Retrospective Study

- 6250** Novel endoscopic papillectomy for reducing postoperative adverse events (with videos)

Jiang L, Ling-Hu EQ, Chai NL, Li W, Cai FC, Li MY, Guo X, Meng JY, Wang XD, Tang P, Zhu J, Du H, Wang HB

Clinical Trials Study

- 6260** Pediatric bowel preparation: Sodium picosulfate, magnesium oxide, citric acid *vs* polyethylene glycol, a randomized trial

Cuffari C, Ciciora SL, Ando M, Boules M, Croffie JM

SYSTEMATIC REVIEWS

- 6270** Insufficient etiological workup of COVID-19-associated acute pancreatitis: A systematic review

Juhász MF, Ocskay K, Kiss S, Hegyi P, Párnitzky A

META-ANALYSIS

- 6279** Diagnostic efficacy of the Japan Narrow-band-imaging Expert Team and Pit pattern classifications for colorectal lesions: A meta-analysis

Zhang Y, Chen HY, Zhou XL, Pan WS, Zhou XX, Pan HH

CASE REPORT

- 6295** Compromised therapeutic value of pediatric liver transplantation in ethylmalonic encephalopathy: A case report

Zhou GP, Qu W, Zhu ZJ, Sun LY, Wei L, Zeng ZG, Liu Y

ABOUT COVER

Editorial Board Member of *World Journal of Gastroenterology*, Dr. Rakesh Kochhar is a Professor in and Head of the Department of Gastroenterology at the Postgraduate Institute of Medical Education and Research, Chandigarh, India. Having completed his MBBS from J N Medical College (Aligarh, India), he performed postgraduate training in Medicine and undertook a fellowship in Gastroenterology at the Postgraduate Institute of Medical Education and Research. He then joined his alma mater as faculty and became a professor in 2003. Widely travelled, he worked as a World Health Organization Fellow at Mayo Clinic (Rochester, USA) and St Bart's Hospital (London, UK). His ongoing research interests include corrosive injuries to the gastrointestinal tract, stricture dilatation, acute pancreatitis, and celiac disease. He has served as President of the Society of Gastrointestinal Endoscopy of India and is currently the President-elect of the Indian Society of Gastroenterology. (L-Editor: Filipodia)

AIMS AND SCOPE

The primary aim of *World Journal of Gastroenterology* (WJG, *World J Gastroenterol*) is to provide scholars and readers from various fields of gastroenterology and hepatology with a platform to publish high-quality basic and clinical research articles and communicate their research findings online. WJG mainly publishes articles reporting research results and findings obtained in the field of gastroenterology and hepatology and covering a wide range of topics including gastroenterology, hepatology, gastrointestinal endoscopy, gastrointestinal surgery, gastrointestinal oncology, and pediatric gastroenterology.

INDEXING/ABSTRACTING

The WJG is now indexed in Current Contents®/Clinical Medicine, Science Citation Index Expanded (also known as SciSearch®), Journal Citation Reports®, Index Medicus, MEDLINE, PubMed, PubMed Central, and Scopus. The 2020 edition of Journal Citation Report® cites the 2019 impact factor (IF) for WJG as 3.665; IF without journal self cites: 3.534; 5-year IF: 4.048; Ranking: 35 among 88 journals in gastroenterology and hepatology; and Quartile category: Q2.

RESPONSIBLE EDITORS FOR THIS ISSUE

Production Editor: Ji-Hong Liu; Production Department Director: Yun-Xiaojuan Wu; Editorial Office Director: Ze-Mao Gong.

NAME OF JOURNAL

World Journal of Gastroenterology

ISSN

ISSN 1007-9327 (print) ISSN 2219-2840 (online)

LAUNCH DATE

October 1, 1995

FREQUENCY

Weekly

EDITORS-IN-CHIEF

Andrzej S Tarnawski, Subrata Ghosh

EDITORIAL BOARD MEMBERS

<http://www.wjgnet.com/1007-9327/editorialboard.htm>

PUBLICATION DATE

October 28, 2020

COPYRIGHT

© 2020 Baishideng Publishing Group Inc

INSTRUCTIONS TO AUTHORS

<https://www.wjgnet.com/bpg/gerinfo/204>

GUIDELINES FOR ETHICS DOCUMENTS

<https://www.wjgnet.com/bpg/GerInfo/287>

GUIDELINES FOR NON-NATIVE SPEAKERS OF ENGLISH

<https://www.wjgnet.com/bpg/gerinfo/240>

PUBLICATION ETHICS

<https://www.wjgnet.com/bpg/GerInfo/288>

PUBLICATION MISCONDUCT

<https://www.wjgnet.com/bpg/gerinfo/208>

ARTICLE PROCESSING CHARGE

<https://www.wjgnet.com/bpg/gerinfo/242>

STEPS FOR SUBMITTING MANUSCRIPTS

<https://www.wjgnet.com/bpg/GerInfo/239>

ONLINE SUBMISSION

<https://www.f6publishing.com>



Retrospective Study

Novel endoscopic papillectomy for reducing postoperative adverse events (with videos)

Lei Jiang, En-Qiang Ling-Hu, Ning-Li Chai, Wen Li, Feng-Chun Cai, Ming-Yang Li, Xu Guo, Jiang-Yun Meng, Xiang-Dong Wang, Ping Tang, Jing Zhu, Hong Du, Hong-Bin Wang

ORCID number: Lei Jiang 0000-0003-2895-5004; En-Qiang Ling-Hu 0000-0003-4028-1508; Ning-Li Chai 0000-0002-6791-5817; Wen Li 0000-0001-7776-949X; Feng-Chun Cai 0000-0002-2351-1028; Ming-Yang Li 0000-0003-2121-1205; Xu Guo 0000-0003-2532-6579; Jiang-Yun Meng 0000-0002-6531-1673; Xiang-Dong Wang 0000-0002-7445-9274; Ping Tang 0000-0002-7401-1330; Jing Zhu 0000-0002-9220-833X; Hong Du 0000-0001-8040-3317; Hong-Bin Wang 0000-0002-1925-7549.

Author contributions: Ling-Hu EQ contributed to study conception and design; Jiang L, Ling-Hu EQ, and Chai NL should be considered as joint first authors; Ling-Hu EQ, Chai NL, Li W, Cai FC, Li MY, and Guo X performed the operations; Meng JY, Wang XD, Tang P, Zhu J, Du H, and Wang HB assisted in operations; Jiang L contributed to data acquisition, analysis, and interpretation and drafted the manuscript; Ling-Hu EQ critically revised the article for important intellectual content; all authors read and approved the manuscript.

Supported by National Key R and D Program of China, No. 2016YFC1303601.

Institutional review board statement: No specific IRB

Lei Jiang, En-Qiang Ling-Hu, Ning-Li Chai, School of Medicine, Nankai University, Tianjin 300071, China

En-Qiang Ling-Hu, Ning-Li Chai, Wen Li, Feng-Chun Cai, Ming-Yang Li, Xu Guo, Jiang-Yun Meng, Xiang-Dong Wang, Ping Tang, Jing Zhu, Hong Du, Hong-Bin Wang, Department of Gastroenterology and Hepatology, Chinese People's Liberation Army General Hospital, Beijing 100853, China

Corresponding author: En-Qiang Ling-Hu, MD, PhD, Chief Doctor, Chief Physician, Director, Professor, Department of Gastroenterology and Hepatology, Chinese People's Liberation Army General Hospital, No. 28 Fuxing Road, Haidian District, Beijing 100853, China. linghuenqiang@vip.sina.com

Abstract

BACKGROUND

Pancreatic adenoma can potentially transform into adenocarcinoma, so it is recommended to be resected surgically or endoscopically. Endoscopic papillectomy is one of the main treatments for papillary adenoma, and bleeding, perforation, and pancreatitis are the most frequent and critical adverse events that restrict its wider use. There is no standard procedure for endoscopic papillectomy yet. The procedure is relevant to postoperative adverse events.

AIM

To reduce the postoperative adverse event rates and improve patients' postoperative condition, we developed a standard novel procedure for endoscopic papillectomy.

METHODS

The novel endoscopic papillectomy had two main modifications based on the conventional method: The isolation of bile from pancreatic juice with a bile duct stent and wound surface protection with metal clips and fibrin glue. We performed a single-center retrospective comparison study on the novel and conventional methods to examine the feasibility of the novel method for reducing postoperative adverse events.

RESULTS

A total of 76 patients, of whom 23 underwent the novel procedure and 53

approval was required for this study according to the Ethics Committee of Chinese PLA General Hospital.

Informed consent statement:

Patients were not required to give informed consent to the study because the analysis used anonymous clinical data that were obtained after each patient agreed to treatment by written consent.

Conflict-of-interest statement:

Nothing to disclose.

Data sharing statement:

No additional data are available.

Open-Access:

This article is an open-access article that was selected by an in-house editor and fully peer-reviewed by external reviewers. It is distributed in accordance with the Creative Commons Attribution NonCommercial (CC BY-NC 4.0) license, which permits others to distribute, remix, adapt, build upon this work non-commercially, and license their derivative works on different terms, provided the original work is properly cited and the use is non-commercial. See: <http://creativecommons.org/licenses/by-nc/4.0/>

Manuscript source: Unsolicited manuscript

Received: May 14, 2020

Peer-review started: May 14, 2020

First decision: May 21, 2020

Revised: September 4, 2020

Accepted: September 17, 2020

Article in press: September 17, 2020

Published online: October 28, 2020

P-Reviewer: Ribeiro IB

S-Editor: Zhang L

L-Editor: Wang TQ

P-Editor: Liu JH



underwent the conventional procedure, were retrospectively evaluated in this study. The postoperative bleeding and pancreatitis rates of the novel method were significantly lower than those of the conventional method (0 *vs* 20.75%, $P = 0.028$, and 17.4% *vs* 41.5%, $P = 0.042$, respectively). After applying the novel method, the most critical adverse event, perforation, was entirely prevented, compared to a prevalence of 5.66% with the conventional method. Several postoperative symptoms, including fever, rapid pulse, and decrease in hemoglobin level, were significantly less frequent in the novel group ($P = 0.042$, 0.049, and 0.014, respectively). Overall, the total adverse event rate of the novel method was lower (0 *vs* 24.5%, $P = 0.007$) than that of the conventional method.

CONCLUSION

Patients who underwent the novel procedure had lower postoperative adverse event rates. This study demonstrates the potential efficacy and safety of the novel endoscopic papillectomy in reducing postoperative adverse events.

Key Words: Endoscopic papillectomy; Novel technique; Adverse events; Papillary adenoma; Endoscopic retrograde cholangiopancreatography; Bile duct stent

©The Author(s) 2020. Published by Baishideng Publishing Group Inc. All rights reserved.

Core Tip: The novel method of endoscopic papillectomy mainly includes two modifications: Isolating bile from pancreatic juice with a bile duct stent and closing the wound surface with metal clips and fibrin glue. Our retrospective comparison showed that postoperative adverse events, including bleeding, pancreatitis, and overall adverse events, were less frequent in the novel endoscopic papillectomy group than in the conventional endoscopic papillectomy group. Postoperative perforation was entirely prevented by this novel method. This study demonstrates that novel endoscopic papillectomy is a potentially effective and safe method for reducing postoperative adverse events.

Citation: Jiang L, Ling-Hu EQ, Chai NL, Li W, Cai FC, Li MY, Guo X, Meng JY, Wang XD, Tang P, Zhu J, Du H, Wang HB. Novel endoscopic papillectomy for reducing postoperative adverse events (with videos). *World J Gastroenterol* 2020; 26(40): 6250-6259

URL: <https://www.wjgnet.com/1007-9327/full/v26/i40/6250.htm>

DOI: <https://dx.doi.org/10.3748/wjg.v26.i40.6250>

INTRODUCTION

Tumors of the main duodenal papilla are rare, with a prevalence of only 0.04% to 0.12% in autopsy studies^[1]. Although the main pathologic diagnosis, papillary adenoma (PA), is benign, it can potentially develop into adenocarcinoma through the adenoma-adenocarcinoma sequence^[2]. Thus, the treatment of PA is essential and more critical than just follow-up. Pancreaticoduodenectomy and endoscopic papillectomy (EP) are the main treatments for PA, and EP is more recommended for benign papillary lesions because of its advantages over open surgery, including less trauma, satisfying treatment outcomes, fewer adverse events, and lower cost^[3-6]. With all of these aforementioned advantages, EP seemed to be a promising treatment for PA; however, surgeons also found intraoperative and postoperative adverse events. These included bleeding, operation-related pancreatitis, perforation, cholangitis, and papillary stricture, and some events, especially bleeding and perforation, are critical and even fatal.

These adverse events could lead to extremely difficult results that require invasive surgical intervention or even result in death. Although this is not common, it does limit the wide application of EP. Thus, a better standard procedure of EP with fewer adverse events is urgently needed for the endoscopic treatment of papillary lesions.

To decrease the postoperative adverse event rate of EP and improve patients' postoperative condition, we modified conventional endoscopic papillectomy and initiated a novel procedure for endoscopic papillectomy in 2016. To verify the safety

and feasibility of this novel method, we reviewed the outcomes of patients undergoing novel or conventional EP.

MATERIALS AND METHODS

We retrospectively studied patients who had PA and underwent novel or conventional EP at the endoscopy center of Chinese PLA General Hospital from January 2016 to September 2018. A total of 76 patients, of whom 23 underwent novel EP and 53 underwent conventional EP, were enrolled in this study. Sample size calculation with the adverse event rates of two groups (significance level of 5% and power of 80%) suggested a minimum sample size of 70. As a retrospective observational study, the study was not blindly randomized.

The standard procedure for novel EP was as follows (Figure 1, Video 1): (1) The patient was placed in a supine position under general anesthesia; (2) Duodenoscopy (TJF-240/TJF-260V; Olympus, Tokyo, Japan) was used to observe the papillary lesion; (3) A submucosal injection was performed to lift the lesion, or an injection was not performed; then, *en bloc* or blocking resection of the lesion was performed with an endoloop (SD-7P-1/SD-221L-25; Olympus, Tokyo, Japan). If the lesion was large, edge cutting could be performed before snaring; argon plasma coagulation was used for bleeding; (4) A guidewire was used to superselect the bile duct (BD), and the guidewire was retained in the BD; (5) Electric coagulation forceps and argon plasma coagulation were used for wound hemostasis, and then the wound was closed with metal clips; (6) A BD stent was implanted; (7) Fibrin glue (S201110020; Bioseal, Guangzhou, China) was sprayed on the closed wound; (8) Exhaust air in the stomach and stent placement were checked under X-ray; and (9) The sample was sent for pathology.

Postoperative treatment and observation

Patients were required to fast after the operation. At the same time, acid-inhibitory drugs, enzyme inhibitors (somatostatin), and total parenteral nutrition were given through intravenous infusion. Operation-related symptoms, including bleeding, abdominal pain, fever, and postoperative pancreatitis, were closely monitored. The BD stents were removed 3 to 4 wk after the operation.

Statistical methods

The enrolled patients were classified into two groups: Novel group and conventional group. The baseline features of the patients, the postoperative indexes, and the occurrence rates of adverse events were compared by the *t*-test, Fisher's test, chi-square test, or ANOVA, with $P < 0.05$ indicating statistical significance. All data were analyzed with SPSS statistics 19.0 (IBM, Armonk, NY, United States) and Prism 8.0 (GraphPad, San Diego, CA, United States).

No specific IRB approval was required for this study according to the Ethics Committee of PLA General Hospital.

RESULTS

A total of 76 patients who underwent EP from January 2016 to September 2018 were enrolled in the study, 23 of whom were randomly chosen by the surgeons for the novel EP, and the rest underwent the conventional EP. Table 1 shows the comparison of baseline features, including pre-, intra-, and postoperative characteristics, which are related to postoperative adverse events. No significant difference was found in the baseline characteristics between these two groups.

The blood test results and vital signs related to the postoperative condition are compared in Table 2. More patients in the conventional group than in the novel group had postoperative fever (17.4% *vs* 41.5%, $P = 0.042$), and the result was similar for postoperative rapid pulse (0 *vs* 15.1%, $P = 0.049$). No obvious decrease in hemoglobin (greater than 20 g/L) was observed in the novel group, while 22.6% of patients in the conventional group had a statistically significant ($P = 0.014$) decrease in hemoglobin. No significant differences were found in other indexes.

To further reveal the safety and effect of the novel procedure, we compared the rate of adverse events, as listed in Table 3. Postoperative bleeding was significantly more common in the conventional EP group than in the novel EP group (0 *vs* 20.75%, $P =$

Table 1 Baseline characteristics of the two groups

		N group (n = 23)	C group (n = 53)	P value
Age		59.30 ± 9.55	58.06 ± 13.09	0.682
Sex		9:14	27:26	0.343
Symptomatic		13/23	32/53	0.753
Intra-operation	BD dilation	2/23	10/53	0.327
	Resection size (cm ²)	3.668 ± 2.904	4.780 ± 6.536	0.582
Pathologic result	HGIN	8	20	0.703
	LGIN	3	8	
	Non-GIN	10	16	
	NT	1	1	
Postoperative hospital stay (d)		10.35 ± 4.23	10.08 ± 3.60	0.783
Total cost (Yuan)		45243.75 ± 11443.68	58158.77 ± 79290.51	0.473

N group: Novel group; C group: Conventional group. BD: Bile duct; HGIN: High-grade intraepithelial neoplasia; LGIN: Low-grade intraepithelial neoplasia; GIN: Glandular intraepithelial neoplasia; NT: Normal tissue.

Table 2 Comparison of blood and body indexes

		N group	C group	P value
Fever		17.4% (4/23)	41.5% (22/53)	0.042 ¹
Breathing rate ^a (/m)		18.09 ± 1.04	19.60 ± 7.43	0.335
Pulse (/m) ^a	Value	79.70 ± 7.62	84.68 ± 18.84	0.226
	> 90/m	0 (0/23)	15.1% (8/53)	0.049 ¹
Abdominal pain score ^b		2.09 ± 2.59	1.75 ± 1.93	0.585
Drop in hemoglobin ^c (g/L)		0 (0/23)	22.6% (12/53)	0.014 ¹
WBC (10 ⁹ /L)	Value	8.84 ± 3.05	9.54 ± 3.39	0.395
	Abnormal	13.0 (3/23)	30.2% (16/53)	0.113
C-RP (mg/L)	Value	1.43 ± 2.66	2.93 ± 5.62	0.252
	Abnormal	4.8% (1/21)	9.5% (4/42)	0.510
AMY (u/L)		354.20 ± 399.12	324.35 ± 320.12	0.731
LPS (u/L)		2052.68 ± 4220.83	1555.89 ± 2047.35	0.493
Hyperamylasemia		39.1% (9/23)	49.1% (26/53)	0.425

^aThe lowest value in 2 d after operation.

^bPain score: 0, no; 2, slight; 4, mild; 6, moderate; 8, serious; 10, severe.

^cCount those differences larger than 20g/L between pre- and post-operation and hemoglobin lower than 120 g/L post-operation at the same time.

¹ $P \leq 0.05$. N group: Novel group; C group: Conventional group; WBC: White blood count; C-RP: C-reactive protein; AMY: Serum amylase; LPS: Serum lipase.

0.028). The frequency of pancreatitis in the conventional group was also higher than that in the novel group (17.4% *vs* 41.5%, $P = 0.042$). Although no significant difference was observed in the prevalence of perforation, there was no single case of perforation in the novel EP group compared to three perforation cases in the conventional group. The incidences of cholangitis and multiple organ dysfunction were not significantly different between the groups, although the occurrence rates in the novel group were lower than those in the conventional group. The overall adverse event occurrence rate in the novel group was markedly lower than that in the conventional group (13.0% *vs* 41.5%, $P = 0.018$). All adverse events were cured or relieved after medical treatments or surgery with no mortality.

Table 3 Comparison of adverse events

		N group	C group	P value
Bleeding rate (%)		0 (0/23)	20.75 (11/53)	0.028 ¹
Perforation rate (%)		0 (0/23)	5.66 (3/53)	0.549
Pancreatitis	Non	21	36	0.043 ¹
	Mild ^a	1	12	
	Severe ^a	1	5	
Cholangitis rate (%)		0 (0/23)	1.89 (1/53)	1.000
MOD rate (%)		0 (0/23)	11.3 (6/53)	0.169
Total complication rate (%)		13.0 (3/23)	41.5 (22/53)	0.018 ¹

^aCount mild pancreatitis as 1 point and severe one as 2 points.

¹ $P \leq 0.05$. N group: Novel group; C group: Conventional group; MOD: Multiple organ dysfunction.

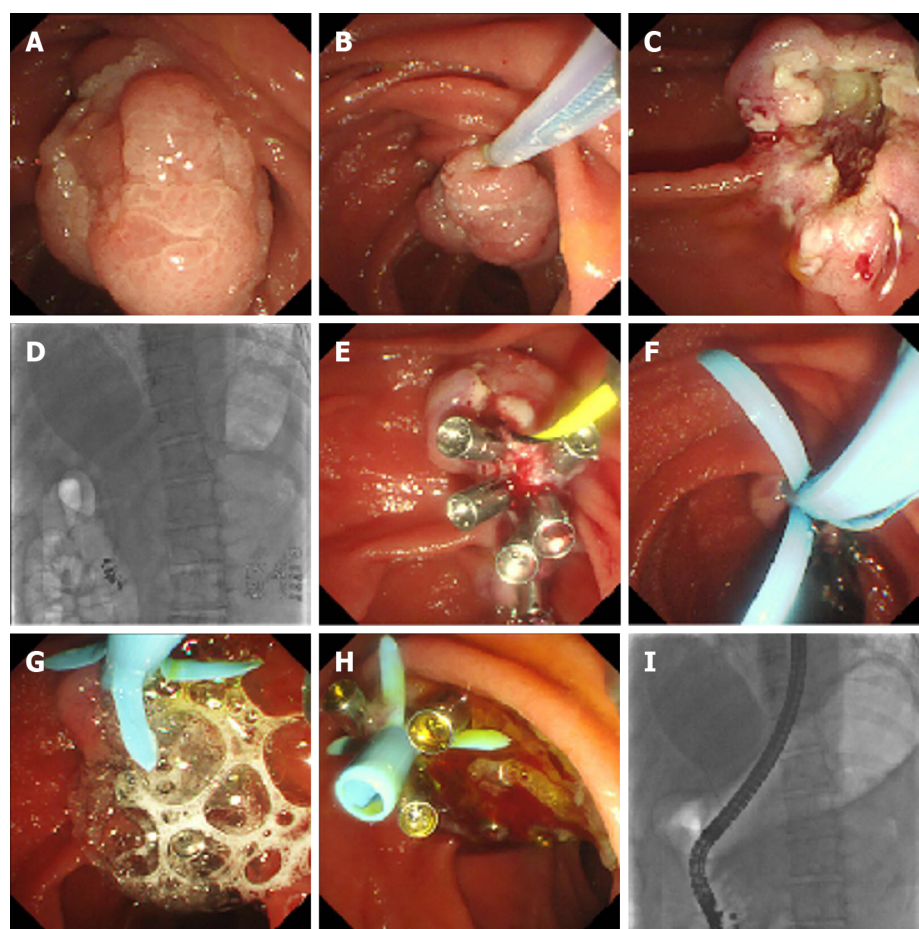


Figure 1 The procedure of novel endoscopic papillectomy. A: Observe the papillary lesion; B and C: *En bloc* resection of the lesion with endoloop; D: Use guidewire to superselct the bile duct, and remain the guidewire in the bile duct; E: Use electric coagulation forceps and aspirin phenacetin and caffeine to do hemostasis on the wound, then close the wound by metal clips; F: Implant bile duct stent; G: Spray fibrin glue on the closed wound; H: Bile flew on the glue; I: Check the place of stent under X-ray.

DISCUSSION

Unlike that of other gastrointestinal polyps, the resection of papillary lesions is far more complex and difficult for several reasons, including its complicated location in the duodenum, the extremely enriched vasculature, and the thin wall of the duodenum. Thus, for a long time, open or minimally invasive surgeries, such as pancreaticoduodenectomy, have been regarded as the only removal strategy for

PAs^[1]. The drawbacks of these invasive surgeries are obvious and include the high adverse event rate and mortality, long anesthesia duration, large operative trauma, high cost, *etc*^[1,7].

Compared with conventional papillary surgery, EP has merits in various aspects that have popularized its rapid worldwide use. The merits are as follows: (1) For benign lesions, EP can be a curative therapy by resecting the lesion completely with less invasion; (2) For malignant lesions, EP can offer abundant tissues for pathological tests, and the identified pathological diagnosis could guide next-step treatments; and (3) For patients who are not eligible for long surgery, EP can reduce the surgical risk^[8-10].

Although it was first performed in 1987^[11] and has been used by surgeons worldwide, there are still no standard procedures or guidelines for EP. Several details, such as pancreatic duct (PD) stenting and submucosal injection, are still controversial^[12-19].

Postoperative adverse events, which occur in approximately 29% of patients^[9,20-34], have been a difficult issue for endoscopists and have been the main cause of death from endoscopic papillectomy in clinical practice since the wide application of EP. The mortality of EP is reported to be approximately 0.4%^[35]. Bleeding and pancreatitis are the most common adverse events, with a reported prevalence of 4.5%-45% and 7%-20%, respectively^[9,20,23,26-29,36-39]. Based on our experience, we designed a novel papillectomy procedure to decrease adverse events, especially bleeding and pancreatitis. After applying this novel procedure, we found that patients who underwent novel EP had better physical conditions, including less occurrence of fever, rapid pulse, and blood loss, after the surgery. For postoperative adverse events, the novel method showed clear superiority for reducing bleeding, EP-related pancreatitis, and the overall adverse event rate. We also found a decreasing trend of other adverse events, including perforation, cholangitis, and multiple organ dysfunction, in the novel group, even though the differences were not statistically significant. Perforation is one of the most critical and dangerous adverse events of EP that may lead to severe intra-abdominal infection and even death. Addressing perforation is rather difficult and usually requires the cooperation of hepatological surgery, which increases the surgical risk and cost and reverses the superiority of endoscopic treatment. Thus, the novel method could prevent perforation, making it an important contribution to improving the prognosis of EP.

After examining relevant studies, we found that all the adverse event rates of the conventional group in our study were consistent with the results of previous studies^[9,12,13,20,23,26-29,37,38,40-42]. Accordingly, the adverse event rates of the novel method were significantly lower than those of previous studies^[9,12,13,20,23,26-29,37,38,40-42]. Therefore, novel EP can improve postoperative physical conditions and decrease surgical adverse events, making it a safe and effective method.

The occurrence of post-EP adverse events is relevant to two main processes: The incomplete healing of surgical wounds and the invasion of pathogenic microorganisms. In the novel procedure, timely closure of the wound with metal clips could help with wound healing and could prevent perforation. It could also prevent bacteria from invading the wound surface or into ducts^[43,44].

In conventional endoscopic papillectomy, the implantation of PD stents is usually recommended to release postoperative pancreatitis by promoting pancreatic drainage, while the efficacy of PD stents is controversial. Furthermore, the application of BD stents has not yet been clarified^[8,12,27,40,45].

With conventional EP, in which a PD stent is implanted solely or with BD stents simultaneously, pancreatic juice and bile can drain out, cover the resection wound, and mix with each other. In the mixture of bile and pancreatic juice, bile can activate trypsinogen to trypsin, which has a strong digestive capacity. Active trypsin, especially within the pancreatic duct activated by reflux bile, can induce pancreatitis^[46]. It can also produce new granulation tissue on the wound surface and inhibit the coagulation process, leading to postoperative bleeding^[47-51]. Hence, we presume that isolating the contact between bile and pancreatic juice can prevent trypsinogen from being activated by bile and can reduce the contribution of pancreatic juice to postoperative adverse events. The novel therapy promotes bile drainage into the cavity of the duodenum directly without covering the wound surface, prevents pancreatic juice and bile from mixing, and does not activate trypsinogen. In addition, as a protein substance, we presume that inactive trypsinogen that covers the wound surface can act as a kind of "nutrition cover" and, together with fibrin glue, can protect and promote the healing process. Furthermore, this protective cover can also prevent pathogenic microorganisms from invading into the PD and can reduce the risk of pancreatitis^[43]. Based on these results, the evidence for how novel EP prevents

postoperative adverse events is by preventing wound bleeding and infection and promoting wound healing.

We sprayed fibrin glue on the closed wound to protect the wound surface and found that it was effective in clinical practice^[52,53]. The fibrin glue kit consists of two main components, porcine fibrinogen with factor XIII (component 1) and porcine thrombin with calcium chloride (component 2). When these two components mix with each other, the mixture simulates the final stage of the clotting cascade. Thrombin proteolytically cleaves fibrinogen, which results in the formation of fibrin polymers. In the presence of calcium, thrombin catalyzes the conversion of factor XIII to activated factor XIII (factor XIIIa). Factor XIIIa crosslinks the fibrin polymers into a stable, insoluble fibrin clot. Mutignani *et al*^[54] used a modified injection of fibrin glue on six patients with post-endoscopic retrograde cholangiopancreatography bleeding. They verified the hemostatic effect of fibrin glue and confirmed that fibrin glue was an efficient endoscopic hemostatic agent, as all six patients were successfully stanching. At the same time, two patients had fibrin glue-related adverse events because the glue concreted in the BD and led to obstruction. In our novel method, bile duct stenting can prevent glue from blocking the bile ducts.

Another commonly used endoscopic hemostasis method is hemostatic powder, such as Hemospray, a mineral blend powder that can rapidly solidify and form an adhesive layer on contact with weak bases, such as water and blood^[55]. Several studies have shown that Hemospray was efficient in treating gastrointestinal tract bleeding endoscopically^[56-60]. EP was recommended as a favorable Hemospray indication^[58]. Although there are no comparative studies investigating the efficacy and safety of Hemospray and fibrin glue, both of these treatments are believed to be efficient in treating gastrointestinal tract bleeding. Hemospray is not commercially available in China now, but considering its efficacy, we still look forward to testing it in our novel EP procedure in the future.

In some cases, submucosal injection was performed before resection to lift the lesions and to help with electronic resection and snares, but whether it is necessary is still an open question^[4]. Hyun *et al*^[41] performed multicenter prospective research to investigate whether submucosal injection contributed to endoscopic papillary procedures. They found that submucosal injection did not improve the complete resection rate or reduce the adverse event rate compared to direct snare resection. Moreover, direct snare resection was faster than resection after submucosal injection. Therefore, direct snare resection is a simpler and more recommendable method. In our study, we did not find submucosal injection to be helpful in novel therapy; however, its effects need more clinical research and analysis for verification.

As a retrospective study, this study had some limitations: (1) It was not blindly randomized; and (2) The sample size was not large enough; although it reached the minimum calculated sample size, the samples were not divided evenly between the two groups. Therefore, a multicenter randomized controlled prospective study is required for further research.

CONCLUSION

Compared with conventional EP, the novel method can reduce postoperative adverse events and improve the postoperative condition of patients. The novel EP achieves its benefits by isolating the contact between bile and pancreatic juice with a bile stent and protecting the wound surface with metal clips and fibrin glue.

ARTICLE HIGHLIGHTS

Research background

Endoscopic papillectomy (EP) is one of the main treatments for duodenal papillary lesions.

Research motivation

The postoperative adverse events of EP limit its wide application.

Research objectives

To reduce postoperative adverse events by a novel EP, and to verify its safety and feasibility.

Research methods

The novel method of endoscopic papillectomy mainly includes two modifications: Isolating bile from pancreatic juice with a bile duct stent and closing the wound surface with metal clips and fibrin glue. We retrospectively compared the postoperative condition and adverse event rates of the novel EP and conventional EP to reveal the safety and feasibility of the novel EP.

Research results

Patients who underwent the novel EP had a better postoperative condition and lower adverse event rates compared with patients who underwent the conventional EP. Postoperative perforation was entirely prevented by the novel method.

Research conclusions

This study demonstrates that novel endoscopic papillectomy is a potentially effective and safe method for reducing postoperative adverse events.

Research perspectives

A randomized controlled prospective study is required to further verify the safety and feasibility of the novel EP. After the confirmation, it could be recommended for wider application.

ACKNOWLEDGEMENTS

We thank peer reviewers for the insightful and thorough suggestions on this manuscript. We thank Julia Jones for language editing and video contract recording.

REFERENCES

- 1 **Bohnacker S**, Soehendra N, Maguchi H, Chung JB, Howell DA. Endoscopic resection of benign tumors of the papilla of Vater. *Endoscopy* 2006; **38**: 521-525 [PMID: [16767591](#) DOI: [10.1055/s-2006-925263](#)]
- 2 **Stolte M**, Pscherer C. Adenoma-carcinoma sequence in the papilla of Vater. *Scand J Gastroenterol* 1996; **31**: 376-382 [PMID: [8726307](#) DOI: [10.3109/00365529609006414](#)]
- 3 **Yoon SM**, Kim MH, Kim MJ, Jang SJ, Lee TY, Kwon S, Oh HC, Lee SS, Seo DW, Lee SK. Focal early stage cancer in ampullary adenoma: surgery or endoscopic papillectomy? *Gastrointest Endosc* 2007; **66**: 701-707 [PMID: [17905011](#) DOI: [10.1016/j.gie.2007.02.049](#)]
- 4 **Standards of Practice Committee**. Adler DG, Qureshi W, Davila R, Gan SI, Lichtenstein D, Rajan E, Shen B, Zuckerman MJ, Fanelli RD, Van Guilder T, Baron TH. The role of endoscopy in ampullary and duodenal adenomas. *Gastrointest Endosc* 2006; **64**: 849-854 [PMID: [17140885](#) DOI: [10.1016/j.gie.2006.08.044](#)]
- 5 **Kim AL**, Choi YI. Safety of duodenal ampullectomy for benign periampullary tumors. *Ann Hepatobiliary Pancreat Surg* 2017; **21**: 146-150 [PMID: [28990001](#) DOI: [10.14701/ahbps.2017.21.3.146](#)]
- 6 **Klein A**, Ahlenstiel G, Tate DJ, Burgess N, Richardson A, Pang T, Byth K, Bourke MJ. Endoscopic resection of large duodenal and papillary lateral spreading lesions is clinically and economically advantageous compared with surgery. *Endoscopy* 2017; **49**: 659-667 [PMID: [28376545](#) DOI: [10.1055/s-0043-105484](#)]
- 7 **ASGE Standards of Practice Committee**. Chathadi KV, Khashab MA, Acosta RD, Chandrasekhara V, Eloubeidi MA, Faulx AL, Fonkalsrud L, Lightdale JR, Saltzman JR, Shaikat A, Wang A, Cash BD, DeWitt JM. The role of endoscopy in ampullary and duodenal adenomas. *Gastrointest Endosc* 2015; **82**: 773-781 [PMID: [26260385](#) DOI: [10.1016/j.gie.2015.06.027](#)]
- 8 **Moon JH**, Choi HJ, Lee YN. Current status of endoscopic papillectomy for ampullary tumors. *Gut Liver* 2014; **8**: 598-604 [PMID: [25368746](#) DOI: [10.5009/gnl14099](#)]
- 9 **Napoleon B**, Gincul R, Ponchon T, Berthiller J, Escourrou J, Canard JM, Boyer J, Barthet M, Ponsot P, Laugier R, Helbert T, Coumaros D, Scoazec JY, Mion F, Saurin JC; Société Française d'Endoscopie Digestive (SFED, French Society of Digestive Endoscopy). Endoscopic papillectomy for early ampullary tumors: long-term results from a large multicenter prospective study. *Endoscopy* 2014; **46**: 127-134 [PMID: [24477368](#) DOI: [10.1055/s-0034-1364875](#)]
- 10 **Ogawa T**, Ito K, Fujita N, Noda Y, Kobayashi G, Horaguchi J, Koshita S, Kanno Y, Masu K, Ishii S. Endoscopic papillectomy as a method of total biopsy for possible early ampullary cancer. *Dig Endosc* 2012; **24**: 291 [PMID: [22725127](#) DOI: [10.1111/j.1443-1661.2011.01214.x](#)]
- 11 **Hernandez LV**, Catalano MF. Endoscopic papillectomy. *Curr Opin Gastroenterol* 2008; **24**: 617-622 [PMID: [19122504](#) DOI: [10.1097/MOG.0b013e3283088e12](#)]
- 12 **Kim SH**, Moon JH, Choi HJ, Kim DC, Lee TH, Cheon YK, Cho YD, Park SH, Kim SJ. Usefulness of pancreatic duct wire-guided endoscopic papillectomy for ampullary adenoma for preventing post-procedure pancreatitis. *Endoscopy* 2013; **45**: 838-841 [PMID: [23918619](#) DOI: [10.1055/s-0033-1344392](#)]
- 13 **Poincloux L**, Scanzi J, Goutte M, Pereira B, Devaud H, Joubert J, Dapigny M, Bommelaer G, Abergel A. Pancreatic intubation facilitated by methylene blue injection decreases the risk for postpapillectomy acute pancreatitis. *Eur J Gastroenterol Hepatol* 2014; **26**: 990-995 [PMID: [25072383](#) DOI: [10.1055/s-0033-1344392](#)]

- 10.1097/MEG.000000000000146]
- 14 **Han J**, Kim MH. Endoscopic papillectomy for adenomas of the major duodenal papilla (with video). *Gastrointest Endosc* 2006; **63**: 292-301 [PMID: [16427938](#) DOI: [10.1016/j.gie.2005.07.022](#)]
- 15 **Lee SK**, Kim MH, Seo DW, Lee SS, Park JS. Endoscopic sphincterotomy and pancreatic duct stent placement before endoscopic papillectomy: are they necessary and safe procedures? *Gastrointest Endosc* 2002; **55**: 302-304 [PMID: [11818948](#) DOI: [10.1067/mge.2002.120885](#)]
- 16 **Moon JH**, Cha SW, Cho YD, Ryu CB, Cheon YK, Kwon KW, Kim YS, Kim YS, Lee JS, Lee MS, Shim CS, Kim BS. Wire-guided endoscopic snare papillectomy for tumors of the major duodenal papilla. *Gastrointest Endosc* 2005; **61**: 461-466 [PMID: [15758926](#) DOI: [10.1016/s0016-5107\(04\)02649-5](#)]
- 17 **Attaallah W**, Gunal O, Mokhtare S, Ozmen T, Cingi A. Endoscopic snare excision of adenoma of the papilla of Vater without prophylactic pancreatic-duct stent. *JOP* 2014; **15**: 587-590 [PMID: [25435575](#) DOI: [10.6092/1590-8577/2639](#)]
- 18 **Napoléon B**, Alvarez-Sanchez MV, Leclercq P, Mion F, Pialat J, Gincul R, Ribeiro D, Cambou M, Lefort C, Rodríguez-Girondo M, Scazecz JY. Systematic pancreatic stenting after endoscopic snare papillectomy may reduce the risk of postinterventional pancreatitis. *Surg Endosc* 2013; **27**: 3377-3387 [PMID: [23549765](#) DOI: [10.1007/s00464-013-2920-9](#)]
- 19 **Yamao T**, Isomoto H, Kohno S, Mizuta Y, Yamakawa M, Nakao K, Irie J. Endoscopic snare papillectomy with biliary and pancreatic stent placement for tumors of the major duodenal papilla. *Surg Endosc* 2010; **24**: 119-124 [PMID: [19517183](#) DOI: [10.1007/s00464-009-0538-8](#)]
- 20 **Katsinelos P**, Paroutoglou G, Kountouras J, Beltsis A, Papaziogas B, Mimidis K, Zavos C, Dimiropoulos S. Safety and long-term follow-up of endoscopic snare excision of ampullary adenomas. *Surg Endosc* 2006; **20**: 608-613 [PMID: [16508819](#) DOI: [10.1007/s00464-004-2278-0](#)]
- 21 **Ghidirim G**, Mişin I, Istrate V, Cazacu S. Endoscopic papillectomy into the treatment of neoplastic lesions of vater papilla. *Curr Health Sci J* 2009; **35**: 92-97 [PMID: [24778815](#)]
- 22 **Irani S**, Arai A, Ayub K, Biehl T, Brandabur JJ, Dorer R, Gluck M, Jiranek G, Patterson D, Schembre D, Traverso LW, Kozarek RA. Papillectomy for ampullary neoplasm: results of a single referral center over a 10-year period. *Gastrointest Endosc* 2009; **70**: 923-932 [PMID: [19608181](#) DOI: [10.1016/j.gie.2009.04.015](#)]
- 23 **Jung MK**, Cho CM, Park SY, Jeon SW, Tak WY, Kweon YO, Kim SK, Choi YH. Endoscopic resection of ampullary neoplasms: a single-center experience. *Surg Endosc* 2009; **23**: 2568-2574 [PMID: [19360365](#) DOI: [10.1007/s00464-009-0464-9](#)]
- 24 **Igarashi Y**, Okano N, Ito K, Mimura T, Nakano S. Endoscopic snare excision of a major duodenal papillary tumor. *Dig Surg* 2010; **27**: 119-122 [PMID: [20551655](#) DOI: [10.1159/000286715](#)]
- 25 **Ahn DW**, Ryu JK, Kim J, Yoon WJ, Lee SH, Kim YT, Yoon YB. Endoscopic papillectomy for benign ampullary neoplasms: how can treatment outcome be predicted? *Gut Liver* 2013; **7**: 239-245 [PMID: [23560162](#) DOI: [10.5009/gnl.2013.7.2.239](#)]
- 26 **Will U**, Müller AK, Fuedner F, Wanzar I, Meyer F. Endoscopic papillectomy: data of a prospective observational study. *World J Gastroenterol* 2013; **19**: 4316-4324 [PMID: [23885142](#) DOI: [10.3748/wjg.v19.i27.4316](#)]
- 27 **De Palma GD**, Luglio G, Maione F, Esposito D, Siciliano S, Gennarelli N, Cassese G, Persico M, Forestieri P. Endoscopic snare papillectomy: a single institutional experience of a standardized technique. A retrospective cohort study. *Int J Surg* 2015; **13**: 180-183 [PMID: [25498490](#) DOI: [10.1016/j.ijssu.2014.11.045](#)]
- 28 **Soma H**, Miyata N, Hozawa S, Higuchi H, Yamagishi Y, Nakamura Y, Saeki K, Kameyama K, Masugi Y, Yahagi N, Kanai T. Ampullary Adenoma Treated by Endoscopic Double-Snare Retracting Papillectomy. *Gut Liver* 2015; **9**: 689-692 [PMID: [26087781](#) DOI: [10.5009/gnl14206](#)]
- 29 **Tsuji S**, Itoi T, Sofuni A, Mukai S, Tonozuka R, Moriyasu F. Tips and tricks in endoscopic papillectomy of ampullary tumors: single-center experience with large case series (with videos). *J Hepatobiliary Pancreat Sci* 2015; **22**: E22-E27 [PMID: [25688984](#) DOI: [10.1002/jhbp.207](#)]
- 30 **Attila T**, Parlak E, Alper E, Dişibeyaz S, Çiçek B, Ödemiş B. Endoscopic papillectomy of benign ampullary lesions: Outcomes from a multicenter study. *Turk J Gastroenterol* 2018; **29**: 325-334 [PMID: [29755017](#) DOI: [10.5152/tjg.2018.17378](#)]
- 31 **Kobayashi M**, Ryozaawa S, Iwano H, Araki R, Tanisaka Y, Fujita A, Kobatake T. The usefulness of wire-guided endoscopic snare papillectomy for tumors of the major duodenal papilla. *PLoS One* 2019; **14**: e0211019 [PMID: [30673748](#) DOI: [10.1371/journal.pone.0211019](#)]
- 32 **Pérez-Cuadrado-Robles E**, Piesseaux H, Moreels TG, Yeung R, Aouattah T, Komuta M, Dano H, Joret-Mourin A, Deprez PH. Combined excision and ablation of ampullary tumors with biliary or pancreatic intraductal extension is effective even in malignant neoplasms. *United European Gastroenterol J* 2019; **7**: 369-376 [PMID: [31019705](#) DOI: [10.1177/2050640618817215](#)]
- 33 **Lee R**, Huelsen A, Gupta S, Hourigan LF. Endoscopic ampullectomy for non-invasive ampullary lesions: a single-center 10-year retrospective cohort study. *Surg Endosc* 2020 [PMID: [32215745](#) DOI: [10.1007/s00464-020-07433-7](#)]
- 34 **Taglieri E**, Micelli-Neto O, Bonin EA, Goldman SM, Kemp R, Dos Santos JS, Ardengh JC. Analysis of risk factors associated with acute pancreatitis after endoscopic papillectomy. *Sci Rep* 2020; **10**: 4132 [PMID: [32139734](#) DOI: [10.1038/s41598-020-60941-3](#)]
- 35 **De Palma GD**. Endoscopic papillectomy: indications, techniques, and results. *World J Gastroenterol* 2014; **20**: 1537-1543 [PMID: [24587629](#) DOI: [10.3748/wjg.v20.i6.1537](#)]
- 36 **Kang SH**, Kim KH, Kim TN, Jung MK, Cho CM, Cho KB, Han JM, Kim HG, Kim HS. Therapeutic outcomes of endoscopic papillectomy for ampullary neoplasms: retrospective analysis of a multicenter study. *BMC Gastroenterol* 2017; **17**: 69 [PMID: [28558658](#) DOI: [10.1186/s12876-017-0626-5](#)]
- 37 **Ismael S**, Marianne U, Heikki J, Jorma H, Leena K. Endoscopic papillectomy, single-centre experience. *Surg Endosc* 2014; **28**: 3234-3239 [PMID: [24928230](#) DOI: [10.1007/s00464-014-3596-5](#)]
- 38 **Boix J**, Lorenzo-Zúñiga V, Moreno de Vega V, Domènech E, Gassull MA. Endoscopic resection of ampullary tumors: 12-year review of 21 cases. *Surg Endosc* 2009; **23**: 45-49 [PMID: [18398649](#) DOI: [10.1007/s00464-008-9866-3](#)]

- 39 **Nguyen N**, Shah JN, Binmoeller KF. Outcomes of endoscopic papillectomy in elderly patients with ampullary adenoma or early carcinoma. *Endoscopy* 2010; **42**: 975-977 [PMID: [21072717](#) DOI: [10.1055/s-0030-1255875](#)]
- 40 **Ito K**, Fujita N, Noda Y, Kobayashi G, Obana T, Horaguchi J, Koshita S, Kanno Y, Ogawa T, Kato Y, Yamashita Y. Impact of technical modification of endoscopic papillectomy for ampullary neoplasm on the occurrence of complications. *Dig Endosc* 2012; **24**: 30-35 [PMID: [22211409](#) DOI: [10.1111/j.1443-1661.2011.01161.x](#)]
- 41 **Hyun JJ**, Lee TH, Park JS, Han JH, Jeong S, Park SM, Lee HS, Moon JH, Park SH. A prospective multicenter study of submucosal injection to improve endoscopic snare papillectomy for ampullary adenoma. *Gastrointest Endosc* 2017; **85**: 746-755 [PMID: [27566056](#) DOI: [10.1016/j.gie.2016.08.013](#)]
- 42 **Chang WI**, Min YW, Yun HS, Lee KH, Lee JK, Lee KT, Rhee PL. Prophylactic pancreatic stent placement for endoscopic duodenal ampullectomy: a single-center retrospective study. *Gut Liver* 2014; **8**: 306-312 [PMID: [24827628](#) DOI: [10.5009/gnl.2014.8.3.306](#)]
- 43 **Leal-Lopes C**, Velloso FJ, Campopiano JC, Sogayar MC, Correa RG. Roles of Commensal Microbiota in Pancreas Homeostasis and Pancreatic Pathologies. *J Diabetes Res* 2015; **2015**: 284680 [PMID: [26347203](#) DOI: [10.1155/2015/284680](#)]
- 44 **Allison MC**, Sandoe JA, Tighe R, Simpson IA, Hall RJ, Elliott TS; Endoscopy Committee of the British Society of Gastroenterology. Antibiotic prophylaxis in gastrointestinal endoscopy. *Gut* 2009; **58**: 869-880 [PMID: [19433598](#) DOI: [10.1136/gut.2007.136580](#)]
- 45 **Ito K**, Fujita N, Noda Y. Endoscopic diagnosis and treatment of ampullary neoplasm (with video). *Dig Endosc* 2011; **23**: 113-117 [PMID: [21429014](#) DOI: [10.1111/j.1443-1661.2010.01101.x](#)]
- 46 **van Geenen EJ**, van der Peet DL, Bhagirath P, Mulder CJ, Bruno MJ. Etiology and diagnosis of acute biliary pancreatitis. *Nat Rev Gastroenterol Hepatol* 2010; **7**: 495-502 [PMID: [20703238](#) DOI: [10.1038/nrgastro.2010.114](#)]
- 47 **Högström H**, Haglund U, Zederfeldt B. Beneficial effect of proteinase inhibitors on early breaking strength of intestinal anastomoses. *Acta Chir Scand* 1985; **151**: 529-532 [PMID: [3911697](#)]
- 48 **Meddahi A**, Benoit J, Ayoub N, Sézeur A, Barritault D. Heparin-like polymers derived from dextran enhance colonic anastomosis resistance to leakage. *J Biomed Mater Res* 1996; **31**: 293-297 [PMID: [8806053](#) DOI: [10.1002/\(SICI\)1097-4636\(199607\)31:3<293::AID-JBM1>3.0.CO;2-H](#)]
- 49 **Shogan BD**, Belogortseva N, Luong PM, Zaborin A, Lax S, Bethel C, Ward M, Muldoon JP, Singer M, An G, Umanskiy K, Konda V, Shakhshere B, Luo J, Klabbers R, Hancock LE, Gilbert J, Zaborina O, Alverdy JC. Collagen degradation and MMP9 activation by *Enterococcus faecalis* contribute to intestinal anastomotic leak. *Sci Transl Med* 2015; **7**: 286ra68 [PMID: [25947163](#) DOI: [10.1126/scitranslmed.3010658](#)]
- 50 **Innerfield I**, Schwarz A, Angrist A. Intravenous trypsin; its anticoagulant, fibrinolytic and thrombolytic effects. *J Clin Invest* 1952; **31**: 1049-1055 [PMID: [13011195](#) DOI: [10.1172/JCI102698](#)]
- 51 **Sarkar NK**. Mechanism of clot lysis. *Nature* 1960; **185**: 624-625 [PMID: [14441752](#) DOI: [10.1038/185624a0](#)]
- 52 **Zhang WG**, Linghu EQ, Li HK. Fibrin sealant for closure of mucosal penetration at the cardia during peroral endoscopic myotomy: A retrospective study at a single center. *World J Gastroenterol* 2017; **23**: 1637-1644 [PMID: [28321165](#) DOI: [10.3748/wjg.v23.i9.1637](#)]
- 53 **Li H**, Linghu E, Wang X. Fibrin sealant for closure of mucosal penetration at the cardia during peroral endoscopic myotomy (POEM). *Endoscopy* 2012; **44** Suppl 2 UCTN: E215-E216 [PMID: [22622752](#) DOI: [10.1055/s-0032-1309358](#)]
- 54 **Mutignani M**, Seerden T, Tringali A, Feisal D, Perri V, Familiari P, Costamagna G. Endoscopic hemostasis with fibrin glue for refractory postsphincterotomy and postpapillectomy bleeding. *Gastrointest Endosc* 2010; **71**: 856-860 [PMID: [20363432](#) DOI: [10.1016/j.gie.2009.12.024](#)]
- 55 **de Rezende DT**, Brunaldi VO, Bernardo WM, Ribeiro IB, Mota RCL, Baracat FI, de Moura DTH, Baracat R, Matuguma SE, de Moura EGH. Use of hemostatic powder in treatment of upper gastrointestinal bleeding: a systematic review and meta-analysis. *Endosc Int Open* 2019; **7**: E1704-E1713 [PMID: [31803822](#) DOI: [10.1055/a-0977-2897](#)]
- 56 **Pittayanon R**, Prueksapanich P, Rerknimitr R. The efficacy of Hemospray in patients with upper gastrointestinal bleeding from tumor. *Endosc Int Open* 2016; **4**: E933-E936 [PMID: [27652296](#) DOI: [10.1055/s-0042-109863](#)]
- 57 **Arena M**, Masci E, Eusebi LH, Iabichino G, Mangiavillano B, Viaggi P, Morandi E, Fanti L, Granata A, Traina M, Testoni PA, Opocher E, Luigiano C. Hemospray for treatment of acute bleeding due to upper gastrointestinal tumours. *Dig Liver Dis* 2017; **49**: 514-517 [PMID: [28065526](#) DOI: [10.1016/j.dld.2016.12.012](#)]
- 58 **Hagel AF**, Albrecht H, Nägel A, Vitali F, Vetter M, Dauth C, Neurath MF, Raithel M. The Application of Hemospray in Gastrointestinal Bleeding during Emergency Endoscopy. *Gastroenterol Res Pract* 2017; **2017**: 3083481 [PMID: [28232848](#) DOI: [10.1155/2017/3083481](#)]
- 59 **Ofosu A**, Ramai D, Latson W, Adler DG. Endoscopic management of bleeding gastrointestinal tumors. *Ann Gastroenterol* 2019; **32**: 346-351 [PMID: [31263356](#) DOI: [10.20524/aog.2019.0391](#)]
- 60 **Baracat FI**, de Moura DTH, Brunaldi VO, Tranquillini CV, Baracat R, Sakai P, de Moura EGH. Randomized controlled trial of hemostatic powder versus endoscopic clipping for non-variceal upper gastrointestinal bleeding. *Surg Endosc* 2020; **34**: 317-324 [PMID: [30927124](#) DOI: [10.1007/s00464-019-06769-z](#)]



Published by **Baishideng Publishing Group Inc**
7041 Koll Center Parkway, Suite 160, Pleasanton, CA 94566, USA

Telephone: +1-925-3991568

E-mail: bpgoffice@wjgnet.com

Help Desk: <https://www.f6publishing.com/helpdesk>

<https://www.wjgnet.com>

