

World Journal of *Gastroenterology*

World J Gastroenterol 2020 October 28; 26(40): 6111-6303



REVIEW

- 6111** Cirrhotic portal hypertension: From pathophysiology to novel therapeutics

Gunarathe LS, Rajapaksha H, Shackel N, Angus PW, Herath CB

- 6141** Role of gut microbiota *via* the gut-liver-brain axis in digestive diseases

Ding JH, Jin Z, Yang XX, Lou J, Shan WX, Hu YX, Du Q, Liao QS, Xie R, Xu JY

MINIREVIEWS

- 6163** Imaging-based algorithmic approach to gallbladder wall thickening

Gupta P, Marodia Y, Bansal A, Kalra N, Kumar-M P, Sharma V, Dutta U, Sandhu MS

- 6182** Overlooked risk for needle tract seeding following endoscopic ultrasound-guided minimally invasive tissue acquisition

Gao RY, Wu BH, Shen XY, Peng TL, Li DF, Wei C, Yu ZC, Luo MH, Xiong F, Wang LS, Yao J

- 6195** Prevalence, diagnosis, and treatment of primary hepatic gastrointestinal stromal tumors

Qian XH, Yan YC, Gao BQ, Wang WL

ORIGINAL ARTICLE

Basic Study

- 6207** Prediction of clinically actionable genetic alterations from colorectal cancer histopathology images using deep learning

Jang HJ, Lee A, Kang J, Song IH, Lee SH

- 6224** New strain of *Pediococcus pentosaceus* alleviates ethanol-induced liver injury by modulating the gut microbiota and short-chain fatty acid metabolism

Jiang XW, Li YT, Ye JZ, Lv LX, Yang LY, Bian XY, Wu WR, Wu JJ, Shi D, Wang Q, Fang DQ, Wang KC, Wang QQ, Lu YM, Xie JJ, Li LJ

Retrospective Cohort Study

- 6241** Predicting cholecystocholedochal fistulas in patients with Mirizzi syndrome undergoing endoscopic retrograde cholangiopancreatography

Wu CH, Liu NJ, Yeh CN, Wang SY, Jan YY

Retrospective Study

- 6250** Novel endoscopic papillectomy for reducing postoperative adverse events (with videos)

Jiang L, Ling-Hu EQ, Chai NL, Li W, Cai FC, Li MY, Guo X, Meng JY, Wang XD, Tang P, Zhu J, Du H, Wang HB

Clinical Trials Study

- 6260** Pediatric bowel preparation: Sodium picosulfate, magnesium oxide, citric acid *vs* polyethylene glycol, a randomized trial

Cuffari C, Ciciora SL, Ando M, Boules M, Croffie JM

SYSTEMATIC REVIEWS

- 6270** Insufficient etiological workup of COVID-19-associated acute pancreatitis: A systematic review

Juhász MF, Ocskay K, Kiss S, Hegyi P, Párnitzky A

META-ANALYSIS

- 6279** Diagnostic efficacy of the Japan Narrow-band-imaging Expert Team and Pit pattern classifications for colorectal lesions: A meta-analysis

Zhang Y, Chen HY, Zhou XL, Pan WS, Zhou XX, Pan HH

CASE REPORT

- 6295** Compromised therapeutic value of pediatric liver transplantation in ethylmalonic encephalopathy: A case report

Zhou GP, Qu W, Zhu ZJ, Sun LY, Wei L, Zeng ZG, Liu Y

ABOUT COVER

Editorial Board Member of *World Journal of Gastroenterology*, Dr. Rakesh Kochhar is a Professor in and Head of the Department of Gastroenterology at the Postgraduate Institute of Medical Education and Research, Chandigarh, India. Having completed his MBBS from J N Medical College (Aligarh, India), he performed postgraduate training in Medicine and undertook a fellowship in Gastroenterology at the Postgraduate Institute of Medical Education and Research. He then joined his alma mater as faculty and became a professor in 2003. Widely travelled, he worked as a World Health Organization Fellow at Mayo Clinic (Rochester, USA) and St Bart's Hospital (London, UK). His ongoing research interests include corrosive injuries to the gastrointestinal tract, stricture dilatation, acute pancreatitis, and celiac disease. He has served as President of the Society of Gastrointestinal Endoscopy of India and is currently the President-elect of the Indian Society of Gastroenterology. (L-Editor: Filipodia)

AIMS AND SCOPE

The primary aim of *World Journal of Gastroenterology* (WJG, *World J Gastroenterol*) is to provide scholars and readers from various fields of gastroenterology and hepatology with a platform to publish high-quality basic and clinical research articles and communicate their research findings online. WJG mainly publishes articles reporting research results and findings obtained in the field of gastroenterology and hepatology and covering a wide range of topics including gastroenterology, hepatology, gastrointestinal endoscopy, gastrointestinal surgery, gastrointestinal oncology, and pediatric gastroenterology.

INDEXING/ABSTRACTING

The WJG is now indexed in Current Contents®/Clinical Medicine, Science Citation Index Expanded (also known as SciSearch®), Journal Citation Reports®, Index Medicus, MEDLINE, PubMed, PubMed Central, and Scopus. The 2020 edition of Journal Citation Report® cites the 2019 impact factor (IF) for WJG as 3.665; IF without journal self cites: 3.534; 5-year IF: 4.048; Ranking: 35 among 88 journals in gastroenterology and hepatology; and Quartile category: Q2.

RESPONSIBLE EDITORS FOR THIS ISSUE

Production Editor: Ji-Hong Liu; Production Department Director: Yun-Xiaojuan Wu; Editorial Office Director: Ze-Mao Gong.

NAME OF JOURNAL

World Journal of Gastroenterology

ISSN

ISSN 1007-9327 (print) ISSN 2219-2840 (online)

LAUNCH DATE

October 1, 1995

FREQUENCY

Weekly

EDITORS-IN-CHIEF

Andrzej S Tarnawski, Subrata Ghosh

EDITORIAL BOARD MEMBERS

<http://www.wjgnet.com/1007-9327/editorialboard.htm>

PUBLICATION DATE

October 28, 2020

COPYRIGHT

© 2020 Baishideng Publishing Group Inc

INSTRUCTIONS TO AUTHORS

<https://www.wjgnet.com/bpg/gerinfo/204>

GUIDELINES FOR ETHICS DOCUMENTS

<https://www.wjgnet.com/bpg/GerInfo/287>

GUIDELINES FOR NON-NATIVE SPEAKERS OF ENGLISH

<https://www.wjgnet.com/bpg/gerinfo/240>

PUBLICATION ETHICS

<https://www.wjgnet.com/bpg/GerInfo/288>

PUBLICATION MISCONDUCT

<https://www.wjgnet.com/bpg/gerinfo/208>

ARTICLE PROCESSING CHARGE

<https://www.wjgnet.com/bpg/gerinfo/242>

STEPS FOR SUBMITTING MANUSCRIPTS

<https://www.wjgnet.com/bpg/GerInfo/239>

ONLINE SUBMISSION

<https://www.f6publishing.com>

Compromised therapeutic value of pediatric liver transplantation in ethylmalonic encephalopathy: A case report

Guang-Peng Zhou, Wei Qu, Zhi-Jun Zhu, Li-Ying Sun, Lin Wei, Zhi-Gui Zeng, Ying Liu

ORCID number: Guang-Peng Zhou 0000-0002-3063-4528; Wei Qu 0000-0002-4484-5940; Zhi-Jun Zhu 0000-0001-7031-2083; Li-Ying Sun 0000-0003-1101-7994; Lin Wei 0000-0002-0435-3829; Zhi-Gui Zeng 0000-0003-1457-7495; Ying Liu 0000-0001-9087-899X.

Author contributions: Zhu ZJ contributed to conception and design of the study and performed the operation for the patient; Zhou GP collected the data, performed the data analysis, and wrote the initial draft of the manuscript; Qu W, Sun LY, Wei L, Zeng ZG, and Liu Y participated in the clinical management and follow-up of the patient and analysis and interpretation of data; All authors contributed to manuscript drafting and revision and issued final approval for the submitted version.

Supported by Beijing Municipal Science & Technology Commission, No. Z181100001718220, and Capital's Funds for Health Improvement and Research, No. 2020-1-2024.

Informed consent statement: Informed written consent was obtained from the patient for publication of this report and any accompanying images.

Conflict-of-interest statement: The authors declare that they have no

Guang-Peng Zhou, Wei Qu, Zhi-Jun Zhu, Lin Wei, Zhi-Gui Zeng, Ying Liu, Liver Transplantation Center, National Clinical Research Center for Digestive Diseases, Beijing Friendship Hospital, Capital Medical University, Beijing 100050, China

Li-Ying Sun, Liver Transplantation Center, Intensive Care Unit, Beijing Friendship Hospital, Capital Medical University, Beijing 100050, China

Corresponding author: Zhi-Jun Zhu, MD, PhD, Chief Doctor, Professor, Surgeon, Liver Transplantation Center, Beijing Friendship Hospital, Capital Medical University, No. 95 Yong'an Road, Xicheng District, Beijing 100050, China. zhu-zhijun@outlook.com

Abstract

BACKGROUND

Ethylmalonic encephalopathy (EE) is a rare autosomal recessive metabolic disorder caused by impaired mitochondrial sulfur dioxygenase. Due to poor therapeutic effect of current conventional treatments, progressive psychomotor regression and neurological impairment usually contribute to early death in the first decade of life. Liver transplantation (LT) is emerging as a novel therapeutic option for EE; however, worldwide experience is still limited.

CASE SUMMARY

An 18-mo-old patient with the diagnosis of EE received a living donor liver transplant in our institution, which, to our knowledge, is the first case in Asian-Pacific countries. During 20 mo of follow-up, the longitudinal metabolic evaluations revealed a wild fluctuation in urinary EMA levels, still far beyond the normal range. Urinary 2-methylsuccinic acid levels gradually restored to normal, whereas the concentrations of urinary isobutyrylglycine and plasma C4- and C5-acylcarnitines fluctuated markedly and still remained above the reference limits. Only mild amelioration of petechiae and ecchymosis was observed, and no dramatic reversion of chronic mucoid diarrhea and orthostatic acrocyanosis occurred. Although brain magnetic resonance imaging suggested a certain improvement in basal ganglia lesions, the patient still presented developmental delay and neurologic disability.

CONCLUSION

LT may bring about a partial but not complete cure to EE. Given its definite role in defending against the devastating natural progression of EE, LT should still be considered for patients with EE in the absence of other superior therapeutic options. Early establishment of diagnosis and initiation of conventional treatment

conflicts of interest.

CARE Checklist (2016) statement:

The authors have read the CARE Checklist (2016), and the manuscript was prepared and revised according to the CARE Checklist (2016).

Open-Access: This article is an open-access article that was selected by an in-house editor and fully peer-reviewed by external reviewers. It is distributed in accordance with the Creative Commons Attribution NonCommercial (CC BY-NC 4.0) license, which permits others to distribute, remix, adapt, build upon this work non-commercially, and license their derivative works on different terms, provided the original work is properly cited and the use is non-commercial. See: <http://creativecommons.org/licenses/by-nc/4.0/>

Manuscript source: Unsolicited manuscript

Received: May 12, 2020

Peer-review started: May 12, 2020

First decision: June 18, 2020

Revised: June 25, 2020

Accepted: September 18, 2020

Article in press: September 18, 2020

Published online: October 28, 2020

P-Reviewer: Iliescu EL, Verran DJ

S-Editor: Huang P

L-Editor: Filipodia

P-Editor: Wang LL



pre-transplant, timely LT, and continuous administration of metabolism-correcting medications post-transplant may be helpful in minimizing the neurologic impairment and maximizing the therapeutic value of LT in EE.

Key Words: Ethylmalonic encephalopathy; Liver transplantation; Mitochondrial disorder; ETHE1; Pediatric; Case report

©The Author(s) 2020. Published by Baishideng Publishing Group Inc. All rights reserved.

Core Tip: Liver transplantation (LT) is emerging as a novel therapeutic option for ethylmalonic encephalopathy (EE). However, worldwide experience is still limited. Our case of LT for EE, to the best of our knowledge, is the first case in Asian-Pacific countries. The case suggests that despite only a partial cure, LT does have a definite role in defending against the devastating natural progression of EE. Early establishment of diagnosis and initiation of conventional treatment pre-transplant, timely LT, and continuous administration of metabolism-correcting medications post-transplant may be helpful in minimizing the neurologic impairment and maximizing the therapeutic value of LT in EE.

Citation: Zhou GP, Qu W, Zhu ZJ, Sun LY, Wei L, Zeng ZG, Liu Y. Compromised therapeutic value of pediatric liver transplantation in ethylmalonic encephalopathy: A case report. *World J Gastroenterol* 2020; 26(40): 6295-6303

URL: <https://www.wjgnet.com/1007-9327/full/v26/i40/6295.htm>

DOI: <https://dx.doi.org/10.3748/wjg.v26.i40.6295>

INTRODUCTION

Ethylmalonic encephalopathy [EE, Online Mendelian Inheritance in Man number #602473]^[1] is a rare autosomal recessively inherited disorder of mitochondrial metabolism caused by homozygous or compound heterozygous mutations in the *ETHE1* gene, which is located on chromosome 19q13^[2]. To date, more than 100 patients with EE have been reported worldwide^[3] but rarely reported in China. However, based on the results of newborn screening from Jining city in 2014-2015, live-birth incidence of EE is approximately 1:25000^[4]. *ETHE1* deficiency results in chronic accumulation of hydrogen sulfide (H₂S) and its derivative thiosulfate in multisystemic tissues such as colonic mucosa, liver, muscle, and brain^[5,6]. Characteristic patients with *ETHE1* disease present with (1) progressive neurological degeneration, including global neurodevelopmental delay, early-onset psychomotor regression, progressive pyramidal and extrapyramidal signs, and seizures and (2) diffuse microvasculature injury, including recurrent petechial purpura, orthostatic acrocyanosis, and chronic hemorrhagic diarrhea^[6,7]. Currently, the mainstay of conservative treatment options aimed at lowering production and promoting detoxification of H₂S is a methionine and isoleucine restricted diet and combined use of metronidazole (an antibiotic against enterobacterial anaerobic flora) and N-acetylcysteine (a cell-permeable precursor of the H₂S scavenger glutathione)^[8]. For EE patients presenting with severe encephalopathy, intravenous N-acetylcysteine infusion therapy may be more effective^[9]. Since most affected individuals are compound heterozygotes resulting in unclear genotype-phenotype correlation, some patients with milder courses of EE who receive combined treatments with metronidazole and N-acetylcysteine may survive into childhood and adolescence, even though they are likely to suffer acute episodes of metabolic decompensation. Kitzler *et al*^[10] found that during an acute episode of metabolic decompensation, continuous renal replacement therapy may help to regain metabolic control in patients with EE. Despite this, the overall outcome of this devastating disorder remains poor. Progressive clinical deterioration along with psychomotor regression usually result in death within the first few years of life.

Since 2016, Dionisi-Vici *et al*^[3] and Tam *et al*^[11] successively performed liver transplantation (LT) in three children with EE. Although psychomotor delay remained after liver transplant, progressive improvements of neurological function and psychomotor development and dramatic amelioration of biochemical abnormalities

were observed. These results suggest that LT may be a promising therapeutic approach that can improve the prognosis of EE. However, worldwide experience is still limited, and potential benefits of LT must be weighed against the potentially high risk of this procedure. Herein we describe a case of living donor liver transplantation (LDLT) for an 18-mo-old patient with EE. To our knowledge, this is the first case in Asian-Pacific countries.

CASE PRESENTATION

Chief complaints

A 15-mo-old boy with the diagnosis of EE was admitted for consideration of LT.

History of present illness

The patient was the first child of non-consanguineous parents after an uncomplicated pregnancy. He had persistent mucoid diarrhea since birth, and scattered petechiae and ecchymosis occurred in the periocular and extremities (Figure 1A). By 9 mo of age, the boy still had poor head control and no ability to sit or roll over unaided. Then, he was referred to a local children hospital. A lactose-free diet and administration of levocarnitine, benzhexol hydrochloride, coenzyme Q10, and multivitamins were initiated. However, during 3-mo follow-up, no obvious improvements in diarrhea, acrocyanosis, and developmental retardation occurred to him.

History of past illness

The patient had no other significant medical history.

Personal and family history

There was no significant personal and family medical history.

Physical examination

The neurological examination revealed significant axial hypotonia, muscle weakness, increased deep tendon reflexes, clonus, and sustained bilateral Babinski sign.

Laboratory examinations

Urine organic acid profile revealed elevated EMA at 142.53 (reference range: 0.00-6.20) and a slight increased isobutyrylglycine and 2-methylsuccinic acid at 3.61 (reference range: 0.00-0.40) and 7.99 (reference range: 0.00-6.40), respectively. Plasma acylcarnitine profile revealed elevated C4 at 2.61 $\mu\text{mol/L}$ (reference range: $< 1.00 \mu\text{mol/L}$) and C5 at 1.11 $\mu\text{mol/L}$ (reference range: $< 0.65 \mu\text{mol/L}$) (Figure 2). Gene sequencing analysis showed compound heterozygous mutations in the *ETHE1* gene, a previously reported pathogenic mutation (c.375+5G>A chr19:44030348 splicing)^[2] and a novel mutation (c.462T>A chr19:44015632 p.D154E) (Figure 1B).

Imaging examinations

Brain magnetic resonance imaging (MRI) by our institution revealed fronto-temporal atrophy with multiple bilateral symmetrical abnormal low and high signal intensity of basal ganglia in T1- and T2-weighted images, respectively (Figure 3).

FINAL DIAGNOSIS

The patient was diagnosed with EE.

TREATMENT

A sulfur-containing amino acids restricted diet and the combined use of metronidazole (30 mg/kg/d) and N-acetylcysteine (80 mg/kg/d) were started for the boy until we found that he was allergic to N-acetylcysteine (manifested by fever and rash), for which N-acetylcysteine was stopped immediately. Following 3 mo of combined medical and dietary treatments, urinary EMA levels decreased slightly, but remained elevated at 74.93, and values of isobutyrylglycine and 2-methylsuccinic acid rose to 5.84 and 11.31, respectively. Plasma acylcarnitine profile showed a slight decrease in

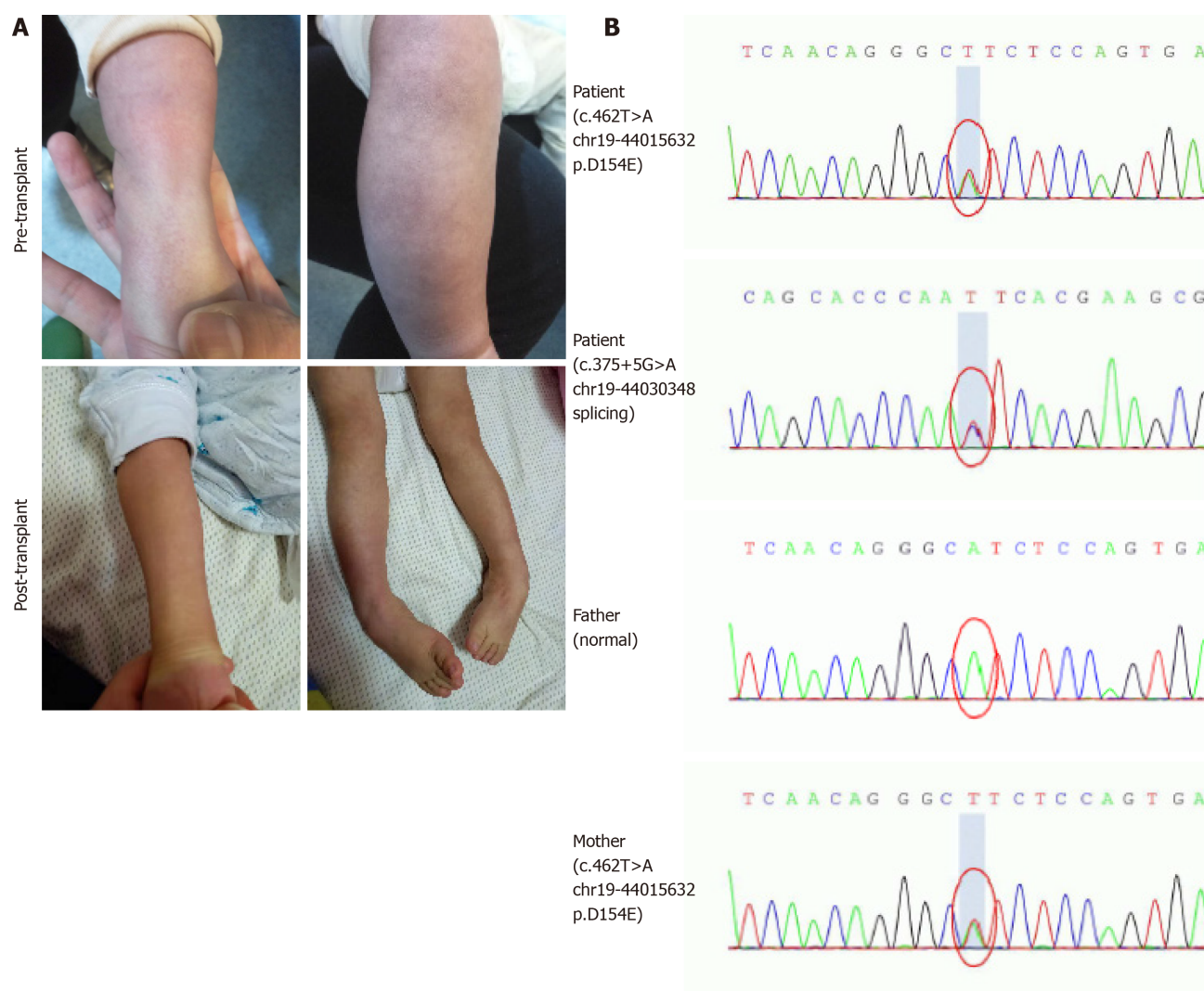


Figure 1 Clinical symptoms and gene sequencing analysis. A: The pre- and post-transplant scattered petechiae in the extremities and orthostatic acrocyanosis; B: Sequence electropherogram of the compound heterozygous mutation (c.375+5G>A and c.462T>A) in patient, heterozygous mutation in mother, and no mutation in father.

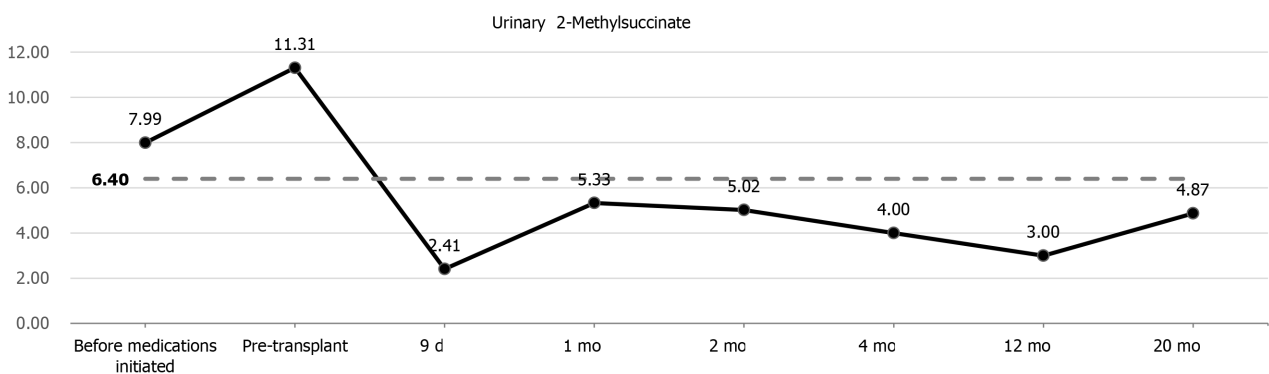
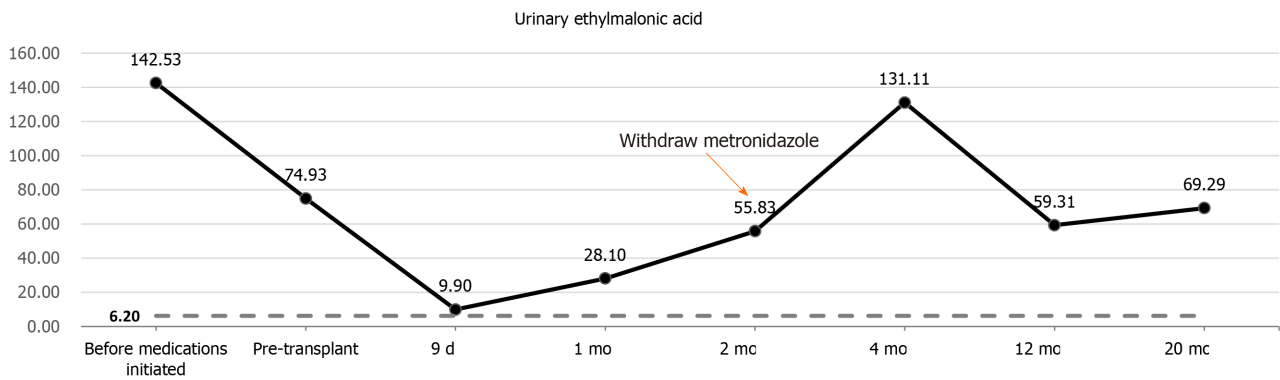
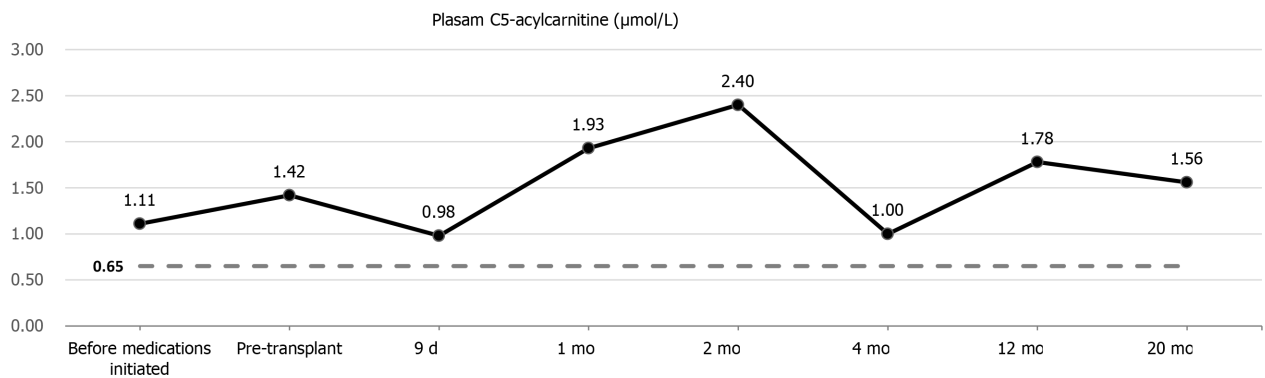
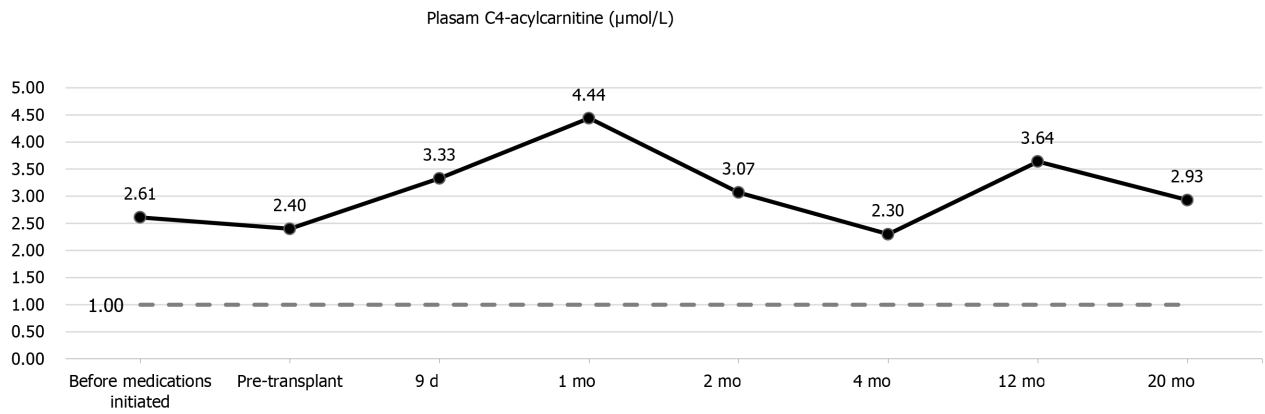
C4 (2.40 $\mu\text{mol/L}$) and increase in C5 (1.42 $\mu\text{mol/L}$) (Figure 2). No obvious improvements were observed in his clinical conditions.

At the age of 18 mo, the boy received a LDLT with reduced-size left lateral lobe donated by his heterozygous mother under the approval of the Ethical Committee of Beijing Friendship Hospital, Capital Medical University.

OUTCOME AND FOLLOW-UP

The patient underwent a smooth operation, and postoperative course was uneventful. Immunosuppressive treatments consisted of tacrolimus and low-dose corticosteroids. Administration of metronidazole and levocarnitine was continued during the perioperative period, and metabolite levels decreased evidently. Urinary EMA, isobutyrylglycine, and 2-methylsuccinic acid levels decreased to 9.90, 0.30, and 2.41, respectively, on post-transplantation day 9. Plasma C4 increased and C5 decreased, and they did not return to normal levels (Figure 2). However, due to the recipient's intolerance of metronidazole, the administration was privately discontinued by his mother 2 mo after transplantation.

During the 20-mo follow-up period, the patient was administered levocarnitine supplementation without a strict protein-restriction diet. Although his liver graft function remained constantly in the normal range, no remarkable amelioration of clinical conditions and neurological development was observed. The longitudinal evaluations disclosed a wild fluctuation in urinary EMA levels, far beyond the normal



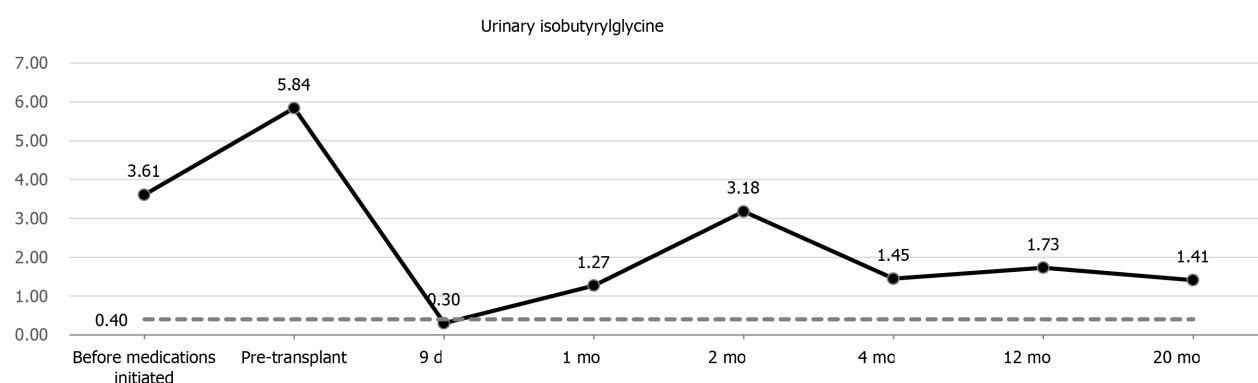


Figure 2 Changes of pre- and post-transplant urine organic acid profile and plasma acylcarnitine profile in the patient with ethylmalonic encephalopathy.

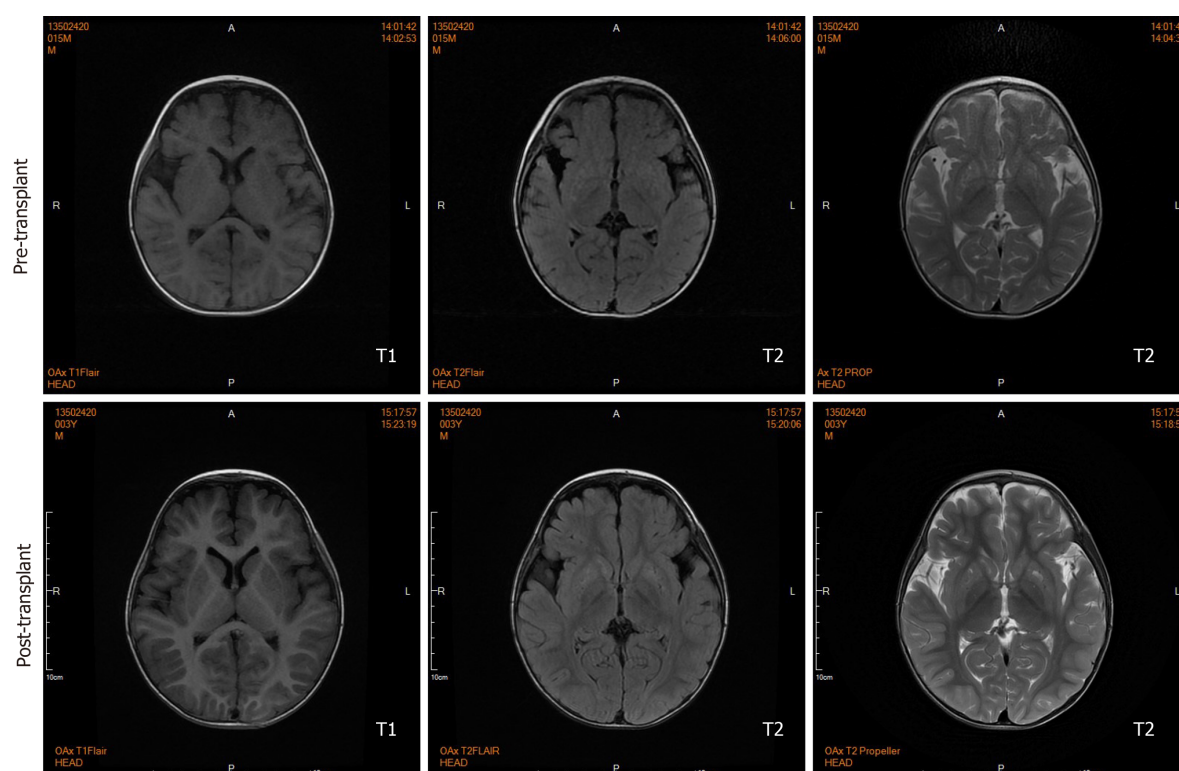


Figure 3 Pre- and post-transplant axial sections of brain magnetic resonance imaging scan. Before liver transplantation, brain magnetic resonance imaging shows fronto-temporal atrophy with multiple bilateral symmetrical abnormal low and high signal intensity involving caudate nucleus and lentiform nucleus in T1- and T2-weighted sections, respectively. Twenty months after transplantation, brain magnetic resonance imaging shows lesions remained but ameliorated.

range. Urinary 2-methylsuccinic acid levels gradually restored to normal, whereas the concentrations of urinary isobutyrylglycine and plasma C4- and C5-acylcarnitines fluctuated markedly and still remained above the reference limits (Figure 2). Only mild amelioration of petechiae and ecchymosis was observed, and no dramatic reversion of chronic mucoid diarrhea and orthostatic acrocyanosis occurred (Figure 1). Although brain MRI suggested a certain improvement in basal ganglia lesions (Figure 3), developmental delay and neurologic disability continued. Now, at the age of 38 mo, the boy has a certain extent of head control, but is still unable to roll over, sit, stand, or walk by himself. He can just say several simple words, such as mama and papa. Meanwhile, the living donor recovered well with no postoperative complications during the follow-up.

DISCUSSION

EE is an inborn error of metabolism caused by a defect in the mitochondrial sulfur dioxygenase. The widely distributed metabolic deficit leads to significant accumulation of toxic metabolites in multiple organs. Patients with *ETHE1* deficiency are characterized by a relentless progressive clinical deterioration, usually leading to death within the first decade of life. Current therapeutic approaches are most often supportive, having no remarkable impact on the natural history of EE^[8,12].

Di Meo *et al.*^[13] found that intravenous injection of adeno-associated virus 2/8 carrying the *ETHE1* gene into the livers of constitutive *Ethe1*^{-/-} mice resulted in obvious amelioration of clinical phenotypes, spectacular prolongation of survival, and improvements in biochemical parameters. Based on the above findings, replacing the metabolically defective liver may help regain enzyme activity, and thus LT has been viewed as one of the most potential treatment modalities for EE. Since the first attempt in 2016, LT is emerging as a promising therapeutic option for this devastating disease^[3,11]. However, the clinical outcomes of LT in our patient was not favorable. Though 20 mo have elapsed since LT, the recipient merely achieved minimal improvements in biochemical features as well as the lesions in the brain MRI without significant clinical and neurological amelioration, which compromised the promising therapeutic value of LT in EE.

Since EE is a multisystemic disease, the underlying enzymatic defect also exists in other tissues besides liver. Although the implanted liver graft containing normal *ETHE1* gene expression could help regain missing enzymatic activity, the overall metabolic defect is only partially corrected, as extrahepatic synthesis and accumulation of toxic metabolites remain^[6]. Illustrating this fact, after successful LT, postoperative levels of blood and urine metabolites among three previous recipients^[3,11] and our patient did not decrease to the normal ranges. Nevertheless, cases including ours suggest that LT does have a definite role in defending against the devastating natural progression of EE. Moreover, satisfactory neurodevelopmental improvements and partial reversal of biochemical abnormalities were observed in those three liver transplant recipients. Our patient, by contrast, has not yet fully benefited from the promising therapeutic effects of LT. The detailed characteristics of these four patients are summarized in [Table 1](#). It can be inferred that our patient's unfavorable prognosis may be attributed to the late diagnosis of EE, late initiation of conventional treatment, pre-transplant administration of metronidazole alone, and post-transplant discontinuation of metronidazole. Furthermore, undefined genotype-phenotype correlation and the use of a heterozygous carrier donor in LDLT may also lead to the post-transplant suboptimal clinical outcomes of our patient.

The long-term clinical prognosis, especially neurodevelopmental outcomes, of liver transplant recipients depends largely on the pre- and post-transplant metabolic control. Early establishment of diagnosis and early initiation of conventional supportive management before the onset of clinical symptoms are of paramount importance as they can control the H₂S overload, thereby improving clinical outcomes and biochemical markers^[14]. The early clinical manifestations and neurologic deterioration arising from EE may present soon after birth^[12]. It is necessary for physicians to strengthen their understanding of EE in order to make an early and correct diagnosis for these patients. After the diagnosis and before LT, combined medical and dietary treatments should be initiated without delay. It should be emphasized that only correct medical and dietary treatments, namely the combined use of metronidazole and N-acetylcysteine and a diet restricted in sulfur-containing amino acids, can help minimize H₂S toxicity. Given LT cannot be performed until optimal age and weight criteria for liver transplant are achieved, conventional treatments in newborns until transplant could therefore contribute to opportune LT. The continuous administration of metronidazole and N-acetylcysteine is also necessary after liver transplant to minimize accumulation of toxic metabolites and maximize therapeutic effect of LT. Nevertheless, heterogenous genotype-phenotype correlations may influence the residual *ETHE1* enzymatic activity, severity of phenotypes, and response to conventional interventions in patients with EE, which may partially explain the difference in outcomes with LT among the present several patients. In addition, although previous study suggested that the use of asymptomatic heterozygous carrier donor in LDLT for this autosomal-recessive condition was viable with satisfactory clinical outcomes^[3], *ETHE1* enzyme activity within the different heterozygous carrier donors' livers may vary. However, due to the unavailability of enzyme activity measurement technology, we did not perform donor enzyme activity assay before LT. Thus, whether the compromised therapeutic effect in our patient is associated with the use of a heterozygous carrier donor remains unclear. Notably,

Table 1 The characteristics of liver transplant recipients with ethylmalonic encephalopathy before and after liver transplantation

Ref.	Case number	Gender	Age at diagnosis	Pre-LT dietary restriction	Pre-LT medical treatment	Age at LT in mo	Type of graft	Post-LT dietary restriction	Post-LT medical treatment	Follow-up in mo	Neurodevelopmental outcomes
Dionisi-Vici <i>et al</i> ^[3] 2016	1	Female	7 mo	N/A	Metronidazole, N-acetylcysteine	9	LDLT	N/A	Carnitine, metronidazole	12	Striking neurological improvement, remarkable achievements in psychomotor development.
Tam <i>et al</i> ^[11] 2019	2	Female	13 mo	N/A	Metronidazole, N-acetylcysteine	19	DDLT	N/A	Carnitine, metronidazole, N-acetylcysteine	9	Drastically improved social interaction and language.
	3	Male	8 wk	N/A	Metronidazole, N-acetylcysteine	13	OLT	N/A	Metronidazole, N-acetylcysteine	22	No other encephalopathic episodes and slow developmental progress.
Present case	4	Male	9 mo	Yes (start from 15 mo)	Carnitine, metronidazole, (start from 15 m)	18	LDLT	No	Carnitine, metronidazole (stop 2 mo post-LT)	20	No obvious improvement.

DDLT: Decreased donor liver transplantation; N/A: Not available; LT: Liver transplantation; LDLT: Living donor liver transplantation; OLT: Orthotopic liver transplantation.

there was no description of dietary restriction for the three previous liver transplant recipients. Whether a diet restricted in sulfur-containing amino acids could further improve liver transplant recipients' clinical prognosis deserves further research.

Although the reversal of neurological damage still needs to be further observed in the long run, the possibility of irreversibility of neurological disability posttransplant should always be kept in the mind of doctors and patients' guardians. Taking into account the perioperative morbidity, transplant-related complications, and long-term immunosuppression, scrupulous preoperative clinical assessment of patient's overall clinical conditions, especially severity of neurological damage, is necessary for the evaluation of the benefit-risk ratio. More importantly, the joint participation of a multidisciplinary team including metabolism physicians, pediatric hepatologists, pediatric neurologists, pediatric transplantation team, metabolic nutritionists, and neurorehabilitation physicians, is indispensable for the long-term management of patients with EE.

CONCLUSION

LT does have a definite role in defending against the devastating natural progression of EE. Despite only a partial cure, LT should still be considered for patients with EE in the absence of other superior therapeutic options. Early establishment of diagnosis and initiation of conventional treatment pre-transplant, timely LT, and continuous administration of metabolism-correcting medications post-transplant may be helpful in minimizing the neurologic impairment and maximizing the therapeutic value of LT in EE.

ACKNOWLEDGEMENTS

We would like to thank He EH, Xu RF and Yi ZX who contributed to ultrasound monitoring in this patient.

REFERENCES

- 1 **Online Mendelian Inheritance in Man [Internet].** Available from: <https://www.omim.org/entry/602473>
- 2 **Tiranti V, D'Adamo P, Briem E, Ferrari G, Mineri R, Lamantea E, Mandel H, Balestri P, Garcia-Silva MT, Vollmer B, Rinaldo P, Hahn SH, Leonard J, Rahman S, Dionisi-Vici C, Garavaglia B, Gasparini P, Zeviani M.** Ethylmalonic encephalopathy is caused by mutations in ETHE1, a gene encoding a mitochondrial matrix protein. *Am J Hum Genet* 2004; **74**: 239-252 [PMID: [14732903](#) DOI: [10.1086/381653](#)]
- 3 **Dionisi-Vici C, Diodato D, Torre G, Picca S, Pariente R, Giuseppe Picardo S, Di Meo I, Rizzo C, Tiranti V, Zeviani M, De Ville De Goyet J.** Liver transplant in ethylmalonic encephalopathy: a new treatment for an otherwise fatal disease. *Brain* 2016; **139**: 1045-1051 [PMID: [26917598](#) DOI: [10.1093/brain/aww013](#)]
- 4 **Yang CJ, Wei N, Li M, Xie K, Li JQ, Huang CG, Xiao YS, Liu WH, Chen XG.** Diagnosis and therapeutic monitoring of inborn errors of metabolism in 100,077 newborns from Jinling city in China. *BMC Pediatr* 2018; **18**: 110 [PMID: [29534692](#) DOI: [10.1186/s12887-018-1090-2](#)]
- 5 **Tiranti V, Viscomi C, Hildebrandt T, Di Meo I, Mineri R, Tiveron C, Levitt MD, Prella A, Fagioli G, Rimoldi M, Zeviani M.** Loss of ETHE1, a mitochondrial dioxigenase, causes fatal sulfide toxicity in ethylmalonic encephalopathy. *Nat Med* 2009; **15**: 200-205 [PMID: [19136963](#) DOI: [10.1038/nm.1907](#)]
- 6 **Tiranti V, Zeviani M.** Altered sulfide (H₂S) metabolism in ethylmalonic encephalopathy. *Cold Spring Harb Perspect Biol* 2013; **5**: a011437 [PMID: [23284046](#) DOI: [10.1101/cshperspect.a011437](#)]
- 7 **Di Meo I, Lamperti C, Tiranti V.** Mitochondrial diseases caused by toxic compound accumulation: from etiopathology to therapeutic approaches. *EMBO Mol Med* 2015; **7**: 1257-1266 [PMID: [26194912](#) DOI: [10.15252/emmm.201505040](#)]
- 8 **Viscomi C, Burlina AB, Dweikat I, Savoirdo M, Lamperti C, Hildebrandt T, Tiranti V, Zeviani M.** Combined treatment with oral metronidazole and N-acetylcysteine is effective in ethylmalonic encephalopathy. *Nat Med* 2010; **16**: 869-871 [PMID: [20657580](#) DOI: [10.1038/nm.2188](#)]
- 9 **Kılıç M, Dedeoğlu Ö, Göçmen R, Kesici S, Yüksel D.** Successful treatment of a patient with ethylmalonic encephalopathy by intravenous N-acetylcysteine. *Metab Brain Dis* 2017; **32**: 293-296 [PMID: [27830356](#) DOI: [10.1007/s11011-016-9928-5](#)]
- 10 **Kitzler TM, Gupta IR, Osterman B, Poulin C, Trakadis Y, Waters PJ, Buhar DC.** Acute and Chronic Management in an Atypical Case of Ethylmalonic Encephalopathy. *JIMD Rep* 2019; **45**: 57-63 [PMID: [30349987](#) DOI: [10.1007/8904_2018_136](#)]
- 11 **Tam A, AlDhaheri NS, Mysore K, Tessier ME, Goss J, Fernandez LA, D'Alessandro AM, Schwoerer JS, Rice GM, Elsea SH, Scaglia F.** Improved clinical outcome following liver transplant in patients with ethylmalonic encephalopathy. *Am J Med Genet A* 2019; **179**: 1015-1019 [PMID: [30864297](#) DOI: [10.1002/ajmg.a.61104](#)]
- 12 **Boyer M, Sowa M, Di Meo I, Eftekharian S, Steenari MR, Tiranti V, Abdenur JE.** Response to medical and a novel dietary treatment in newborn screen identified patients with ethylmalonic encephalopathy. *Mol Genet Metab* 2018; **124**: 57-63 [PMID: [29526615](#) DOI: [10.1016/j.ymgme.2018.02.008](#)]
- 13 **Di Meo I, Auricchio A, Lamperti C, Burlina A, Viscomi C, Zeviani M.** Effective AAV-mediated gene therapy in a mouse model of ethylmalonic encephalopathy. *EMBO Mol Med* 2012; **4**: 1008-1014 [PMID: [22903887](#) DOI: [10.1002/emmm.201201433](#)]
- 14 **Govindaraj P, Parayil Sankaran B, Nagappa M, Arvinda HR, Deepha S, Jessena Ponmalar JN, Sinha S, Gayathri N, Taly AB.** Child Neurology: Ethylmalonic encephalopathy. *Neurology* 2020; **94**: e1336-e1339 [PMID: [32111695](#) DOI: [10.1212/WNL.0000000000009144](#)]



Published by **Baishideng Publishing Group Inc**
7041 Koll Center Parkway, Suite 160, Pleasanton, CA 94566, USA

Telephone: +1-925-3991568

E-mail: bpgoffice@wjgnet.com

Help Desk: <https://www.f6publishing.com/helpdesk>

<https://www.wjgnet.com>

