

World Journal of *Gastroenterology*

World J Gastroenterol 2020 November 14; 26(42): 6514-6705



EDITORIAL

- 6514** Nonalcoholic fatty liver disease in lean subjects: Prognosis, outcomes and management
Chrysavgis L, Ztriva E, Protopapas A, Tziomalos K, Cholongitas E

REVIEW

- 6529** Simultaneous colorectal and parenchymal-sparing liver resection for advanced colorectal carcinoma with synchronous liver metastases: Between conventional and mini-invasive approaches
De Raffele E, Mirarchi M, Cuicchi D, Lecce F, Casadei R, Ricci C, Selva S, Minni F
- 6556** What could microRNA expression tell us more about colorectal serrated pathway carcinogenesis?
Peruhova M, Peshevska-Sekulovska M, Krastev B, Panayotova G, Georgieva V, Konakchieva R, Nikolaev G, Velikova TV

MINIREVIEWS

- 6572** Modern surgical strategies for perianal Crohn's disease
Zabot GP, Cassol O, Saad-Hossne R, Bemelman W
- 6582** Vascular anomalies associated with hepatic shunting
Schmalz MJ, Radhakrishnan K

ORIGINAL ARTICLE

Basic Study

- 6599** Reactive oxygen species-induced activation of Yes-associated protein-1 through the c-Myc pathway is a therapeutic target in hepatocellular carcinoma
Cho Y, Park MJ, Kim K, Kim SW, Kim W, Oh S, Lee JH
- 6614** Fedora-type magnetic compression anastomosis device for intestinal anastomosis
Chen H, Ma T, Wang Y, Zhu HY, Feng Z, Wu RQ, Lv Y, Dong DH

Retrospective Cohort Study

- 6626** Attention deficit hyperactivity disorder and gastrointestinal morbidity in a large cohort of young adults
Kedem S, Yust-Katz S, Carter D, Levi Z, Kedem R, Dickstein A, Daher S, Katz LH
- 6638** Nomograms and risk score models for predicting survival in rectal cancer patients with neoadjuvant therapy
Wei FZ, Mei SW, Chen JN, Wang ZJ, Shen HY, Li J, Zhao FQ, Liu Z, Liu Q

Observational Study

- 6658** Estimation of visceral fat is useful for the diagnosis of significant fibrosis in patients with non-alcoholic fatty liver disease

Hernández-Conde M, Llop E, Fernández Carrillo C, Tormo B, Abad J, Rodríguez L, Perelló C, López Gomez M, Martínez-Porras JL, Fernández Puga N, Trapero-Marugán M, Fraga E, Ferre Aracil C, Calleja Panero JL

Prospective Study

- 6669** Accuracy of carbon dioxide insufflation for endoscopic retrograde cholangiopancreatography using double-balloon endoscopy

Niwa Y, Nakamura M, Kawashima H, Yamamura T, Maeda K, Sawada T, Mizutani Y, Ishikawa E, Ishikawa T, Kakushima N, Furukawa K, Ohno E, Honda T, Ishigami M, Fujishiro M

SYSTEMATIC REVIEWS

- 6679** Prognostic role of artificial intelligence among patients with hepatocellular cancer: A systematic review

Lai Q, Spoleitini G, Mennini G, Larghi Laureiro Z, Tsilimigras DI, Pawlik TM, Rossi M

CASE REPORT

- 6689** Case series of three patients with hereditary diffuse gastric cancer in a single family: Three case reports and review of literature

Hirakawa M, Takada K, Sato M, Fujita C, Hayasaka N, Nobuoka T, Sugita S, Ishikawa A, Mizukami M, Ohnuma H, Murase K, Miyaniishi K, Kobune M, Takemasa I, Hasegawa T, Sakurai A, Kato J

- 6698** Intussusception due to hematogenous metastasis of hepatocellular carcinoma to the small intestine: A case report

Mashiko T, Masuoka Y, Nakano A, Tsuruya K, Hirose S, Hirabayashi K, Kagawa T, Nakagohri T

ABOUT COVER

Editorial Board Member of *World Journal of Gastroenterology*, Dr. Misha Luyer is a Senior Consultant for upper gastrointestinal and pancreas surgery and Chair of the Department of Surgery. After finishing his surgical training in 2010, he started as a Fellow at the Catharina Hospital in Eindhoven (Netherlands), where he received specialized training in upper gastrointestinal, bariatric and pancreatic surgery. In 2012, he was appointed consultant at the Catharina Hospital. Since then, he has been involved in national training courses for minimally invasive upper gastrointestinal surgery and pancreatic surgery. He has authored more than 150 articles published in peer-reviewed scientific journals and book chapters in the fields of upper gastroenterology and pancreas. He currently serves on the Editorial Board of several peer-reviewed scientific journals. (L-Editor: Filipodia)

AIMS AND SCOPE

The primary aim of *World Journal of Gastroenterology* (WJG, *World J Gastroenterol*) is to provide scholars and readers from various fields of gastroenterology and hepatology with a platform to publish high-quality basic and clinical research articles and communicate their research findings online. WJG mainly publishes articles reporting research results and findings obtained in the field of gastroenterology and hepatology and covering a wide range of topics including gastroenterology, hepatology, gastrointestinal endoscopy, gastrointestinal surgery, gastrointestinal oncology, and pediatric gastroenterology.

INDEXING/ABSTRACTING

The WJG is now indexed in Current Contents®/Clinical Medicine, Science Citation Index Expanded (also known as SciSearch®), Journal Citation Reports®, Index Medicus, MEDLINE, PubMed, PubMed Central, and Scopus. The 2020 edition of Journal Citation Report® cites the 2019 impact factor (IF) for WJG as 3.665; IF without journal self cites: 3.534; 5-year IF: 4.048; Ranking: 35 among 88 journals in gastroenterology and hepatology; and Quartile category: Q2.

RESPONSIBLE EDITORS FOR THIS ISSUE

Production Editor: Ji-Hong Liu; Production Department Director: Yun-Xiao Jian Wu; Editorial Office Director: Ze-Mao Gong.

NAME OF JOURNAL

World Journal of Gastroenterology

ISSN

ISSN 1007-9327 (print) ISSN 2219-2840 (online)

LAUNCH DATE

October 1, 1995

FREQUENCY

Weekly

EDITORS-IN-CHIEF

Andrzej S Tarnawski, Subrata Ghosh

EDITORIAL BOARD MEMBERS

<http://www.wjgnet.com/1007-9327/editorialboard.htm>

PUBLICATION DATE

November 14, 2020

COPYRIGHT

© 2020 Baishideng Publishing Group Inc

INSTRUCTIONS TO AUTHORS

<https://www.wjgnet.com/bpg/gerinfo/204>

GUIDELINES FOR ETHICS DOCUMENTS

<https://www.wjgnet.com/bpg/GerInfo/287>

GUIDELINES FOR NON-NATIVE SPEAKERS OF ENGLISH

<https://www.wjgnet.com/bpg/gerinfo/240>

PUBLICATION ETHICS

<https://www.wjgnet.com/bpg/GerInfo/288>

PUBLICATION MISCONDUCT

<https://www.wjgnet.com/bpg/gerinfo/208>

ARTICLE PROCESSING CHARGE

<https://www.wjgnet.com/bpg/gerinfo/242>

STEPS FOR SUBMITTING MANUSCRIPTS

<https://www.wjgnet.com/bpg/GerInfo/239>

ONLINE SUBMISSION

<https://www.f6publishing.com>

Prospective Study

Accuracy of carbon dioxide insufflation for endoscopic retrograde cholangiopancreatography using double-balloon endoscopy

Yoshiki Niwa, Masanao Nakamura, Hiroki Kawashima, Takeshi Yamamura, Keiko Maeda, Tsunaki Sawada, Yasuyuki Mizutani, Eri Ishikawa, Takuya Ishikawa, Naomi Kakushima, Kazuhiro Furukawa, Eizaburo Ohno, Takashi Honda, Masatoshi Ishigami, Mitsuhiro Fujishiro

ORCID number: Yoshiki Niwa 0000-0002-4166-4941; Masanao Nakamura 0000-0002-5444-143X; Hiroki Kawashima 0000-0002-3720-781X; Takeshi Yamamura 0000-0003-4994-016X; Keiko Maeda 0000-0001-7615-0476; Tsunaki Sawada 0000-0002-4779-9708; Yasuyuki Mizutani 0000-0002-4363-3161; Eri Ishikawa 0000-0003-1623-7996; Takuya Ishikawa 0000-0001-5814-3555; Naomi Kakushima 0000-0002-9635-2099; Kazuhiro Furukawa 0000-0003-0980-9095; Eizaburo Ohno 0000-0002-7730-4630; Takashi Honda 0000-0001-8951-0952; Masatoshi Ishigami 0000-0003-0938-631X; Mitsuhiro Fujishiro 0000-0002-4074-1140.

Author contributions: Niwa Y and Nakamura M contributed to the conception and design; Niwa Y, Nakamura M, Kawashima H and Ishikawa T, Kakushima N contributed to the analysis and interpretation of the data; Niwa Y drafted the article; Ohno E, Ishikawa E, Yamamura T, Maeda K, Sawada T, Honda T, Mizutani Y, Furukawa K, and Ishigami M contributed to critical revision of the article for important intellectual content; Nakamura M and Yamamura T contributed to Statistical analysis; Fujishiro M made final approval of the article; all authors have read and approve

Yoshiki Niwa, Masanao Nakamura, Takeshi Yamamura, Yasuyuki Mizutani, Eri Ishikawa, Takuya Ishikawa, Naomi Kakushima, Kazuhiro Furukawa, Eizaburo Ohno, Takashi Honda, Masatoshi Ishigami, Mitsuhiro Fujishiro, Department of Gastroenterology and Hepatology, Nagoya University Graduate School of Medicine, Nagoya 466-8560, Japan

Hiroki Kawashima, Keiko Maeda, Tsunaki Sawada, Department of Endoscopy, Nagoya University Hospital, Nagoya 466-8560, Japan

Corresponding author: Masanao Nakamura, MD, PhD, Lecturer, Department of Gastroenterology and Hepatology, Nagoya University Graduate School of Medicine, 65 Tsurumai-cho, Showa-ku, Nagoya 466-8560, Japan. makamura@med.nagoya-u.ac.jp

Abstract

BACKGROUND

Retrograde cholangiopancreatography using double-balloon endoscopic retrograde cholangiography (DBERC) is a valuable technique to treat biliary stone and jejunobiliary anastomotic stenosis in patients with altered gastrointestinal anatomy. The accurate selection of the route at the anastomosis branch is one of the most important factors in reaching the target in a timely manner.

AIM

To determine the accuracy of carbon dioxide insufflation enterography (CDE) at the branch for selecting the correct route during DBERC.

METHODS

We enrolled 52 consecutive patients scheduled for DBERC at our institution from June 2015 to November 2017. Route selection *via* two methods (visual observation and CDE) was performed in each patient. We determined the correct rate of route selection using CDE.

RESULTS

Thirty-three patients had a jejunojejunal anastomosis and 19 patients had a gastrojejunal anastomosis. The therapeutic target region was reached in 50 patients. The mean procedure times from the teeth to the target (total insertion time), from the teeth to the branch, and from the branch to the target, and the

the final manuscript.

Institutional review board

statement: The study was reviewed and approved by the Ethics Committee of Nagoya University Hospital.

Clinical trial registration statement:

The study was registered in the University Hospital Medical Information Network and in a clinical trial registry (UMIN000018357).

Informed consent statement: All study participants provided informed written consent prior to study enrollment.

Conflict-of-interest statement:

Department of Gastroenterology and Hepatology, Nagoya University Graduate School of Medicine is receiving a scholarship donation from FUJIFILM. There are no additional conflict of interest that would pertain to the content of this study.

Data sharing statement: No additional data are available.

CONSORT 2010 statement: The authors have read the CONSORT 2010 statement, and the manuscript was prepared and revised according to the CONSORT 2010 statement.

Open-Access: This article is an open-access article that was selected by an in-house editor and fully peer-reviewed by external reviewers. It is distributed in accordance with the Creative Commons Attribution NonCommercial (CC BY-NC 4.0) license, which permits others to distribute, remix, adapt, build upon this work non-commercially, and license their derivative works on different terms, provided the original work is properly cited and the use is non-commercial. See: <http://creativecommons.org/licenses/by-nc/4.0/>

Manuscript source: Unsolicited manuscript

Specialty type: Gastroenterology and hepatology

mean total examination time were 15.2, 5.0, 8.2, and 60.3 min, respectively. The rate of correct route selection using visual observation and CDE were 36/52 (69.2%) and 48/52 (92.3%), respectively ($P = 0.002$). The rate of correct route selection using CDE in patients with a jejunojejunal anastomosis was 29/33 (87.8%), and the rate in patients with a gastrojejunal anastomosis was 19/19 (100%).

CONCLUSION

CDE is helpful in selecting the route at the branch in the anastomosis for more timely access to the target in patients with altered gastrointestinal anatomy undergoing DBERC.

Key Words: Retrograde cholangiopancreatography; Double-balloon endoscopy; Carbon dioxide insufflation; Anastomosis; Accuracy; Prospective study

©The Author(s) 2020. Published by Baishideng Publishing Group Inc. All rights reserved.

Core Tip: Carbon dioxide insufflation enterography (CDE) may be useful for selecting route at branch in patients with altered gastrointestinal anatomy in double-balloon endoscopy. The endoscopist inserts the tip of the endoscope into one of the two tracts at the branch and insufflate carbon dioxide with an obstruction created by the inflation of an endoscopic balloon. Fluoroscopy is used to determine the direction of carbon dioxide flow. This prospective study evaluated the usefulness of CDE during double-balloon endoscopic retrograde cholangiopancreatography in patients with altered gastrointestinal anatomy by prospectively investigating the accuracy of route selection using CDE at the branch of the anastomosis. The mean procedure times from the teeth to the target (total insertion time), from the teeth to the branch, and from the branch to the target, and the mean total examination time were 15.2, 5.0, 8.2, and 60.3 min, respectively. The rate of correct route selection using CDE in patients with a jejunojejunal anastomosis was 29/33 (87.8%), and the rate in patients with a gastrojejunal anastomosis was 19/19 (100%).

Citation: Niwa Y, Nakamura M, Kawashima H, Yamamura T, Maeda K, Sawada T, Mizutani Y, Ishikawa E, Ishikawa T, Kakushima N, Furukawa K, Ohno E, Honda T, Ishigami M, Fujishiro M. Accuracy of carbon dioxide insufflation for endoscopic retrograde cholangiopancreatography using double-balloon endoscopy. *World J Gastroenterol* 2020; 26(42): 6669-6678

URL: <https://www.wjgnet.com/1007-9327/full/v26/i42/6669.htm>

DOI: <https://dx.doi.org/10.3748/wjg.v26.i42.6669>

INTRODUCTION

Previously, biliary stones in patients with altered gastrointestinal (GI) anatomy were treated *via* a percutaneous trans-hepatic approach, however, this approach is sometimes challenging and may require a long therapeutic period in order to reach the stones^[1]. In 2008, retrograde cholangiopancreatography (ERCP) using a short type of double-balloon endoscopy (DBE) called double-balloon endoscopic retrograde cholangiopancreatography (DBERC) was reported by Matsushita *et al*^[2] and biliary stones were able to be treated during a single endoscopic procedure. Since then, improvement in the endoscopic equipment was made and access to the blind end and subsequent treatment became easier^[3-5]. A multicenter prospective study demonstrated that the mean time required to reach the blind end was 22.4 min and the therapeutic success rate was 97.9%^[6].

However, in patients with a longer blind loop, severe adhesions, or a past history of hepatectomy, reaching the blind end for biliary drainage is still challenging^[7]. The proper route at the bifurcation of the jejunojejunal anastomosis, as in Roux-en-Y reconstructions, or the gastrojejunal anastomosis, as in Billroth II reconstructions, is sometime difficult to be identified. When the incorrect route is initially selected, the examination and treatment time becomes much longer, as the endoscopist must return

Country/Territory of origin: Japan**Peer-review report's scientific quality classification**

Grade A (Excellent): 0
 Grade B (Very good): B
 Grade C (Good): 0
 Grade D (Fair): 0
 Grade E (Poor): 0

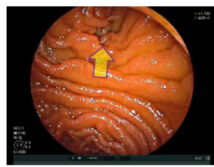
Received: August 17, 2020**Peer-review started:** August 17, 2020**First decision:** September 12, 2020**Revised:** September 14, 2020**Accepted:** September 23, 2020**Article in press:** September 23, 2020**Published online:** November 14, 2020**P-Reviewer:** Altonbary AY**S-Editor:** Zhang L**L-Editor:** A**P-Editor:** Liu JH

to the anastomosis in order to choose the correct path. It has been reported that the type of reconstruction may also affect the time required to reach the blind end as well as the ERCP success rate^[7]. The correct selection of the route at the anastomosis can lead to a decreased insertion time. Yano *et al*^[8] reported that the direction in which sprayed indigo carmine solution flowed due to peristalsis indicates the afferent loop of a Roux-en-Y anastomosis, and that the alternate route should be selected. The correct route was selected in 80% of the patients in their study. Fukuba *et al*^[9] used carbon dioxide insufflation enterography (CDE) to confirm the correct route. In this method, the endoscopist inserts the tip of the endoscope into one of the two tracts at the branch and insufflate carbon dioxide (CO₂) with an obstruction created by the inflation of an endoscopic balloon. Fluoroscopy is used to determine the direction of CO₂ flow. However, their study had retrospective fashion and included small number of cases. The aim of this prospective study was to evaluate the usefulness of CDE during DBERC in patients with altered GI anatomy by prospectively investigating the accuracy of route selection using CDE at the branch of the anastomosis.

MATERIALS AND METHODS

Inclusion criteria was the consecutive patients who were scheduled to undergo DBERC from June 2015 to November 2017 at our institution. Exclusion criteria were the Patients with a poor general condition and emergent cases. Informed consent was obtained from each patient prior to his or her involvement in this study. A short-type double-balloon endoscope consisting of an EI-530B endoscope (effective length: 1.550 mm, working channel: 2.8 mm, FUJIFILM, Tokyo, Japan) and a TS13101 overtube (FUJIFILM, Tokyo, Japan) were used for each examination. CO₂ insufflation was performed in all procedures^[7]. DBE insertion was performed by experienced endoscopists (Nakamura M and Yamamura T) and their assistants who held the overtube. Patients were placed under conscious sedation with diazepam (0.02 mg/kg) and pentazocine (7.5 mg) with left lateral decubitus position. Analgesics were additionally and repeatedly used for 7.5 mg as necessary, based on the consciousness and pain of the patient during the procedure. Dexmedetomidine (loaded at 6 µg/kg/h for 10 min and maintained at 0.4 µg/kg/h) was administered concomitantly in patients in whom sufficient sedation was not achieved using diazepam and pentazocine^[10]. General anesthesia was used in child and adolescent patients. The pancreatobiliary team (Kawashima H, Ohno E, and Ishikawa T) performed the ERCPs. After reaching the target site, the body position was changed to dorsal or abdominal to perform ERCP. We performed both visual observation and CDE route selection in each patient from the jejunojejunal or gastrojejunal anastomosis to the target of the jejunobiliary anastomosis or the original Vater papilla and compared the accuracies of both route selection methods. When the endoscope reached the anastomosis during DBERC, the main endoscopist selected one of two lumens as the visual observation (Figure 1, Evaluation 1). The lumen on the left was initially selected, and the lumen that made a sharp angle if side selection was not available (Figure 1). The endoscopist then advanced the endoscope by one stroke and inflated the balloon on the tip of the endoscope to avoid a backflow of carbon dioxide, as previously reported^[9]. Carbon dioxide was added up to ten seconds under fluoroscopy until the endoscopist could estimate whether the selected route lead to the target (Figure 1, Evaluation 2). When carbon dioxide could be seen in the patient's upper, right abdomen (Video 1), the selected route was considered to be correct. Then the endoscope was advanced and ERCP was performed. When CDE enhanced the pelvis (Video 2), the selected route was considered incorrect, and the endoscopist pulled back to the anastomosis and continued the procedure using the other route. In patients with the Billroth II reconstruction and a Braun anastomosis leading to the original Vater papilla, we initially selected the left route at Braun anastomosis. If the left route did not lead to the target, the center route was chosen. The definitions of correct and incorrect routes are shown in Figure 1. The primary endpoint was the correct rate of CDE for selection of the route to the target. Secondary endpoints were the comparison of correct rate between visual observation and CDE around the anastomosis and examination times. Regarding the relation between patient's burden, the factors associated with the dose of sedation and analgesic were analyzed using logistic regression analysis. The study was registered in the University Hospital Medical Information Network and in a clinical trial registry (UMIN000018357), and was approved by ethic committee at Nagoya University Hospital (registration No. 2015-0228).

(Jejunojejunal or gastrojejunal anastomosis)

Evaluation 1: Route selection by visual observation
(Select left and sharp angle side)

One stroke advance and carbon dioxide enterography (CDE)

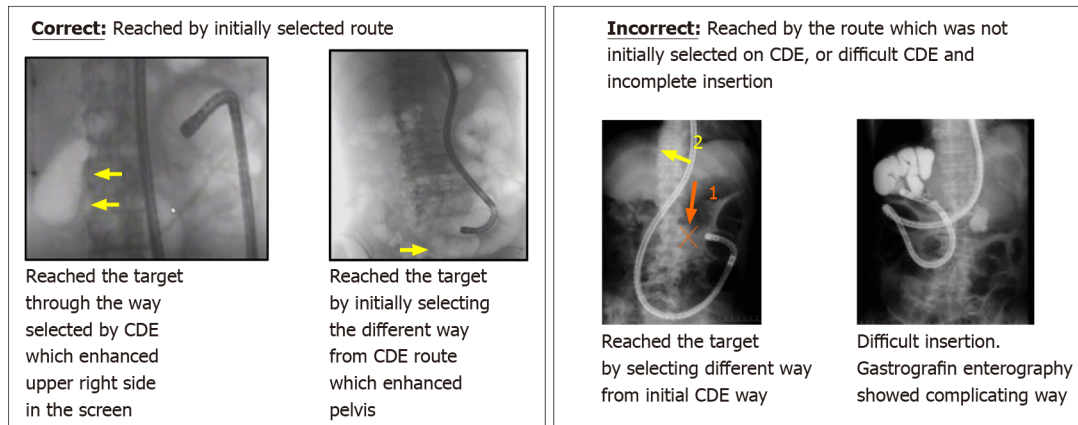
Evaluation 2: route selection by CDE

Figure 1 Jejunojejunal or gastrojejunal anastomosis. Evaluation 1 for route selection by visual observation and Evaluation 2 for route selection by carbon dioxide insufflation enterography. CDE: Carbon dioxide insufflation enterography.

Statistical analysis

SPSS version 26 for Windows (SPSS Inc., Chicago, IL, United States) was used to analyze the data in this study. The McNemar test was used to compare the rates of correct route selection between the two methods. The patients' clinical results were compared using the Kruskal-Wallis test and the Mann-Whitney *U* test. Multiple logistic regression using the stepwise selection method was used to determine the effects of the dosages of sedation and analgesics in each patient. Statistical significance was set at $P < 0.05$.

RESULTS

We were able to reach the target in 50/52 patients (Table 1). The remaining two patients had severe adhesions that prevented the endoscopist from reaching the target. Thirty-three patients were included in the jejunojejunal anastomosis group (due to Roux-en-Y reconstruction and liver transplantation) and the gastrojejunal anastomosis group (due to Billroth II reconstruction and pancreatoduodenectomy) included 19 patients, six of whom had Braun anastomoses. The most frequent indication for ERCP was the treatment of biliary stones. Time from the branch to the target was likely to be longer than that from the incisor tooth to the branch.

CDE was more accurate than visual observation in both groups (Table 2). The rate of correct route selection using CDE was higher in the gastrojejunal anastomosis group than in the jejunojejunal anastomosis group. Incorrect CDE in the patients with Braun anastomoses was occurred in 2/6 (33.3%) and higher than those without Braun anastomosis. Table 3 shows the patients' clinical results for each group. Time from the branch to the target and total examination time were longer in patients with incorrect selection by CDE ($n = 4$). Of these four patients, the target was reached in two patients, one of who had too sharp angle at the branch to occlude the lumen and the other in whom the balloon attached on tip of endoscope was prolapsed to the anastomosis during CDE. Pancreatobiliary interventions were performed in 38 patients. To evaluate the relation between patient's burden and DBERC, the factors associated with the dose

Table 1 Clinical results of double-balloon endoscopic retrograde cholangiography

Clinical results	<i>n</i> = 52
Male:female	32:20
Age (years old, mean \pm SD)	62.5 \pm 17.6
Types of branch	
Jejuno-jejunal anastomosis (Roux-en Y reconstruction, liver transplantation)	33
Gastro-jejunal anastomosis (Billroth II, pancreatoduodenectomy)	19
Indications	
Cholangitis	20
Biliary stone	13
Jaundice	7
Suspected tumor	5
Hyperamylasemia	3
Stenosis at anastomosis	2
Foreign body in the bile duct	1
Abdominal pain	1
Reached target, <i>n</i> (%)	50/52 (96.1)
Examination time	
Insertion time, minutes (range)	15.2 (5.0-90.7)
Teeth-branch, minutes (range)	5.0 (1.3-25.5)
Branch-target, minutes (range)	8.2 (3.3-72.4)
Total examination, minutes (range)	60.3 (20.6-165.6)
Sedations	
Midazolam, <i>n</i> [median (range)]	49 [10 mg (2.5-40)]
Pentazocine, <i>n</i> [median (range)]	49 [15 mg (7.5-45)]
Dexmedetomidine, <i>n</i> (dose)	3 (137, 103, 80 μ g)
General anesthesia, <i>n</i>	3
Interventions	
EPBD with biliary stone extraction	12
Biliary stone extraction	10
Balloon dilation of the anastomosis stricture	7
ENBD	4
Metallic stent placement	3
Endoscopic sphincterotomy	1
Extraction of foreign body	1

EPBD: Endoscopic papillary balloon dilatation; ENBD: Endoscopic nasobiliary drainage.

of sedation and analgesic were analyzed using logistic regression analysis. We found no significant relationships between patient factors and the required dose of midazolam, though a higher analgesic dose was significantly associated with an age < 65 years (Tables 4 and 5). There were not any adverse events related to DBE insertion in this study.

Table 2 Correct rate for route selection

Total	
Correct on visual (%)	36/52 (69.2)
Correct on CDE (%)	48/52 (92.3) ¹
Jejuno-jejunal anastomosis	
Correct on visual (%)	20/33 (60.6)
Correct on CDE (%)	29/33 (87.8) ²
Billroth II, Pancreatoduodenectomy	
Correct on visual (%)	16/19 (82.3)
Correct on CDE (%)	19/19 (100) ³

Visual *vs* carbon dioxide insufflation enterography,

¹*P* = 0.002,

²*P* = 0.012,

³*P* = 0.250. CDE: Carbon dioxide insufflation enterography.

Table 3 Comparison of clinical results according to evaluation groups

Group	A	B	C	D	<i>P</i> value ¹
Evaluation 1: Visual observation	Correct	Correct	Incorrect	Incorrect	
Evaluation 2: CDE	Correct	Incorrect	Correct	Incorrect	
<i>n</i>	35	1	13	3	
Age	59.4 (21.4)	76	56.3 (23.3)	67.3 (6.0)	0.568
Male	20	0	9	3	
Insertion time [minutes, mean (SD)]	16.9 (14.9) ²	90	25.5 (22.3)	68.3 (45.0)	0.008
Incisor tooth to branch [minutes, mean (SD)]	4.8 (4.1)	20	8.5 (7.7)	16.6 (12.3)	0.042
Branch- target [minutes, mean (SD)]	12.0 (13.2) ³	70	17.0 (18.1)	52.6 (32.5)	0.014
Total examination time [minutes, mean (SD)]	62.9 (26.6)	165	73.0 (33.9)	82.0 (33)	0.229
Treatment, <i>n</i>	26	0	7	0	
Baseline CRP (mg/dL, mean (SD))	2.2 (4.0)	3.5	2.6 (2.7)	0.10 (0.11)	
Baseline serum amylase [IU/L, mean (SD)]	175 (220)	793	138 (100)	118 (58)	

¹Kruskal-Wallis test.

²*P* = 0.042 (*vs* Group D).

³*P* = 0.047 (*vs* Group D), Mann-Whitney *U* test, Bonferroni correction. CRP: C-reactive protein; CDE: Carbon dioxide insufflation enterography.

DISCUSSION

This was the first prospective study to evaluate the results of CDE for selecting the route to the target during DBERC. These results indicated that CDE accurately selected the correct route at the anastomosis in patients with GI reconstruction who underwent DBERC. The mean total insertion time in this study was 15 min, which was shorter than that in the previous report^[6]. When CDE accurately selected the route, the total insertion time was shorter. When visual observation is used to select a route, its accuracy cannot be determined until the target is reached. The use of CDE allows endoscopists to estimate the direction and distance of the target prior to reaching it, which results in a decrease in the total insertion time. The CDE method takes approximately 30 s to complete, including 10 s of CO₂ insufflation. However, when CDE leads the endoscopist to choose the incorrect route, a longer total insertion time results. This emphasizes the importance of the accuracy of CDE.

When a balloon is used to occlude the lumen, insufflated CO₂ can only go forward.

Table 4 Univariate analysis influencing factors for dose of sedation

Factors	Univariate analysis			
	P value	Odds ratio	95%CI	
			Lower limit	Upper limit
Age (less than 65 yr)	0.241	0.500	0.157	1.594
Gender	0.556	0.708	0.224	2.240
Correct visual selection	0.700	1.286	0.358	4.617
Correct CDE	0.770	0.655	0.039	11.119
Intervention	0.466	0.643	0.196	2.108
Insertion time (more than 22 min.)	0.895	0.917	0.251	3.350
Total examination time (more than 80 min.)	0.797	1.179	0.377	4.125
CRP level normal	0.805	1.167	0.344	3.956
Serum amylase level normal	0.432	0.583	0.152	2.240
Billroth II and PD	0.721	0.808	0.250	2.612
Previous surgery more than 2 times	0.270	0.467	0.120	1.810

CDE: Carbon dioxide insufflation enterography; CRP: C-reactive protein.

Table 5 Univariate and multivariate analyses influencing factors for dose of pentazocine

Factors	Univariate analysis				Multivariate analysis			
	P value	Odds ratio	95%CI		P value	Odds ratio	95%CI	
			Lower limit	Upper limit			Lower limit	Upper limit
Age (less than 65 yr)	0.025	12.429	1.362	113.410	0.033	11.338	1.232	105.219
Gender	0.868	0.872	0.173	4.392				
Correct visual selection	0.999	-	-	-				
Correct CDE	0.999	-	-	-				
Intervention	0.744	1.339	0.231	7.751				
Insertion time (more than 22 min)	0.283	2.475	0.473	12.961				
Total examination time (more than 80 min)	0.353	2.182	0.421	11.318				
CRP level normal	0.834	1.207	0.208	7.012				
Serum amylase level normal	0.867	1.164	0.197	6.891				
Billroth II and PD	0.582	0.612	0.106	3.521				
Previous surgery more than 2 times	0.166	0.305	0.057	1.639	0.313	0.389	0.062	2.431

CDE: Carbon dioxide insufflation enterography; CRP: C-reactive protein.

However, CO₂ can sometimes flow back to the main route to the cecum *via* the small space between the lumen and balloon, in which situation, it is difficult to assess the routes as CO₂ is observed in all areas of the abdomen. CDE should be performed as soon as the balloon is inflated, when there is no space between the lumen and the balloon. In contrast, visual observation of the jejunojejunal branch was accurate in 60% of patients, which is comparable to the 50% that would be predicted based on having two, equal choices. The left side lumen often had a sharp angle at the branch and the endoscopist chose that way; however, it was not always correct. We believe that it was easy to rotate the anastomosis and the position was changeable by several factors, namely air insufflation volume, insertion technique, and bowel movement. The accuracy of the visual observation method was slightly higher in patients with

gastrojejunal anastomoses, which are unlikely to be influenced by these factors.

Yane *et al*^[11] reported that a pancreatic indication, the first ERCP attempt, and no transparent hood were statistically significant factors affecting procedural failure for short-type single-balloon enteroscope-assisted ERCP. Other insertion-related items besides transparent hood were not investigated. However, the procedural failure is also related to the procedure time, which can affect adverse events such as aspiration pneumonia and acute pancreatitis^[12,13]. DBERC is a sequential procedure involving an insertion technique and biliary intervention. Adhesions and other factors can result in a challenging insertion of the endoscope into the GI tract. When insertion requires more than 60 min, a delicate technique should be used for subsequent biliary interventions. Based on our study, incorrect CDE may lead to an insertion requiring more than 60 min (Table 3). In patients < 65 years old, longer insertion times may lead to abdominal pain (Table 5). Therefore, accurate CDE is important to reduce the patient's burden and improve safety.

In patients with reconstructed GI tracts, success of DBERC is highly dependent on the exact anatomy. The DBERC endoscope insertion and procedural success rates in patients with stenosis of the anastomosis site after liver transplantation have been reported as 68%-85% and 78%-88.2%, respectively, and are lower than the success rates in patients who underwent other GI reconstruction procedures^[14-17]. This may be due to the fact that endoscope insertion and therapeutic procedures are more difficult due to changes in hepatic volume and afferent loop length after such surgery^[7]. In patients who have undergone a hepatectomy, the selection of the correct route at the hepaticojejunostomy anastomosis is important to access the target site in a timely manner.

DBERC has a learning curve. The time required to complete the DBERC procedure in this study, especially the time required to reach the blind end, is less than that in previous reports^[18,19]. This indicates that endoscopists who have experience maneuvering the DBERC may have shorter examination times. However, the procedure duration time still had a wide range. Some difficult cases inevitably require a long duration to complete the procedures. It is challenging to perform procedures within the expected duration, and this problem may be overcome by the improvement of endoscopes and devices^[20].

This study had several limitations. First, it includes a small sample size in which both methods were used in the same patient. The result and performance of the second evaluation method depended on the first evaluation. A randomized, comparative study between CDE and visual observation for the proper route selection is necessary.

CONCLUSION

In conclusion, CDE is able to accurately select the route at the anastomosis in patients with GI reconstruction who are undergoing DBERC.

ARTICLE HIGHLIGHTS

Research background

Double-balloon endoscopic retrograde cholangiography (DBERC) has been widely used for pancreatobiliary diseases after reconstruction in gastrointestinal surgery, but sometimes it is complicating.

Research motivation

The accurate selection of the route at the anastomosis branch is one of the most important factors for the success of DBERC. We used carbon dioxide insufflation enterography (CDE) for selecting the route.

Research objectives

The aim of this study was to determine the accuracy of CDE at the branch for selecting the correct route during DBERC.

Research methods

Route selection *via* two methods (visual observation and CDE) was performed in each patient in DBERC. We determined the correct rate of route selection using CDE. The

primary endpoint was the correct rate of CDE for selection of the route to the target. Secondary endpoints were the comparison of correct rate between visual observation and CDE around the anastomosis and examination times.

Research results

We enrolled 52 consecutive patients scheduled for DBERC at our institution from June 2015 to November 2017. We were able to reach the target in 50/52 patients. The rate of correct route selection using visual observation and CDE were 36/52 (69.2%) and 48/52 (92.3%), respectively ($P = 0.002$). The rate of correct route selection using CDE in patients with a jejunojejunal anastomosis was 29/33 (87.8%), and the rate in patients with a gastrojejunal anastomosis was 19/19 (100%).

Research conclusions

CDE was able to accurately select the route at the anastomosis in patients with gastrointestinal reconstruction who are undergoing DBERC.

Research perspectives

Using CDE, DBERC will be performed safely and easily for patients who underwent any gastrointestinal reconstruction. A randomized, comparative study between CDE and visual observation for the proper route selection is necessary.

REFERENCES

- 1 **Kühn JP**, Busemann A, Lerch MM, Heidecke CD, Hosten N, Puls R. Percutaneous biliary drainage in patients with nondilated intrahepatic bile ducts compared with patients with dilated intrahepatic bile ducts. *AJR Am J Roentgenol* 2010; **195**: 851-857 [PMID: 20858809 DOI: 10.2214/AJR.09.3461]
- 2 **Matsushita M**, Shimatani M, Takaoka M, Okazaki K. "Short" double-balloon enteroscope for diagnostic and therapeutic ERCP in patients with altered gastrointestinal anatomy. *Am J Gastroenterol* 2008; **103**: 3218-3219 [PMID: 19086985 DOI: 10.1111/j.1572-0241.2008.02161_18.x]
- 3 **Shimatani M**, Matsushita M, Takaoka M, Koyabu M, Ikeura T, Kato K, Fukui T, Uchida K, Okazaki K. Effective "short" double-balloon enteroscope for diagnostic and therapeutic ERCP in patients with altered gastrointestinal anatomy: a large case series. *Endoscopy* 2009; **41**: 849-854 [PMID: 19750447 DOI: 10.1055/s-0029-1215108]
- 4 **Shimatani M**, Takaoka M, Matsushita M, Okazaki K. Endoscopic approaches for pancreatobiliary diseases in patients with altered gastrointestinal anatomy. *Dig Endosc* 2014; **26** Suppl 1: 70-78 [PMID: 24118126 DOI: 10.1111/den.12175]
- 5 **Kawashima H**, Hirooka Y, Ohno E, Ishikawa T, Miyahara R, Watanabe O, Hayashi K, Ishigami M, Hashimoto S, Ebata T, Nagino M, Goto H. Effectiveness of a modified 6-Fr endoscopic nasobiliary drainage catheter for patients with preoperative perihilar cholangiocarcinoma. *Endosc Int Open* 2018; **6**: E1020-E1030 [PMID: 30105289 DOI: 10.1055/a-0614-2202]
- 6 **Shimatani M**, Hatanaka H, Kogure H, Tsutsumi K, Kawashima H, Hanada K, Matsuda T, Fujita T, Takaoka M, Yano T, Yamada A, Kato H, Okazaki K, Yamamoto H, Ishikawa H, Sugano K; Japanese DB-ERC Study Group. Diagnostic and Therapeutic Endoscopic Retrograde Cholangiography Using a Short-Type Double-Balloon Endoscope in Patients with Altered Gastrointestinal Anatomy: A Multicenter Prospective Study in Japan. *Am J Gastroenterol* 2016; **111**: 1750-1758 [PMID: 27670601 DOI: 10.1038/ajg.2016.420]
- 7 **Nishio R**, Kawashima H, Nakamura M, Ohno E, Ishikawa T, Yamamura T, Maeda K, Sawada T, Tanaka H, Sakai D, Miyahara R, Ishigami M, Hirooka Y, Fujishiro M. Double-balloon endoscopic retrograde cholangiopancreatography for patients who underwent liver operation: A retrospective study. *World J Gastroenterol* 2020; **26**: 1056-1066 [PMID: 32205996 DOI: 10.3748/wjg.v26.i10.1056]
- 8 **Yano T**, Hatanaka H, Yamamoto H, Nakazawa K, Nishimura N, Wada S, Tamada K, Sugano K. Intraluminal injection of indigo carmine facilitates identification of the afferent limb during double-balloon ERCP. *Endoscopy* 2012; **44** Suppl 2 UCTN: E340-E341 [PMID: 23012011 DOI: 10.1055/s-0032-1309865]
- 9 **Fukuba N**, Moriyama I, Ishihara S, Yuki T, Kawashima K, Ishimura N, Kinoshita Y. Carbon dioxide enterography: a useful method for double-balloon enteroscopy-assisted ERCP. *Endoscopy* 2014; **46** Suppl 1 UCTN: E587-E588 [PMID: 25502252 DOI: 10.1055/s-0034-1377943]
- 10 **Oshima H**, Nakamura M, Watanabe O, Yamamura T, Funasaka K, Ohno E, Kawashima H, Miyahara R, Goto H, Hirooka Y. Dexmedetomidine provides less body motion and respiratory depression during sedation in double-balloon enteroscopy than midazolam. *SAGE Open Med* 2017; **5**: 2050312117729920 [PMID: 28904794 DOI: 10.1177/2050312117729920]
- 11 **Yane K**, Katanuma A, Maguchi H, Takahashi K, Kin T, Ikarashi S, Sano I, Yamazaki H, Kitagawa K, Yokoyama K, Koga H, Nagai K, Nojima M. Short-type single-balloon enteroscope-assisted ERCP in postsurgical altered anatomy: potential factors affecting procedural failure. *Endoscopy* 2017; **49**: 69-74 [PMID: 27760436 DOI: 10.1055/s-0042-118301]
- 12 **Zepeda-Gómez S**, Barreto-Zuñiga R, Ponce-de-León S, Meixueiro-Daza A, Herrera-López JA, Camacho J, Tellez-Avila F, Valdovinos-Andraca F, Vargas-Vorackova F. Risk of hyperamylasemia and acute pancreatitis after double-balloon enteroscopy: a prospective study. *Endoscopy* 2011; **43**: 766-770 [PMID: 21626472 DOI: 10.1055/s-0030-1256473]
- 13 **Mensink PB**, Haringsma J, Kucharzik T, Cellier C, Pérez-Cuadrado E, Mönkemüller K, Gasbarrini A,

- Kaffes AJ, Nakamura K, Yen HH, Yamamoto H. Complications of double balloon enteroscopy: a multicenter survey. *Endoscopy* 2007; **39**: 613-615 [PMID: 17516287 DOI: 10.1055/s-2007-966444]
- 14 **Chua TJ**, Kaffes AJ. Balloon-assisted enteroscopy in patients with surgically altered anatomy: a liver transplant center experience (with video). *Gastrointest Endosc* 2012; **76**: 887-891 [PMID: 22840290 DOI: 10.1016/j.gie.2012.05.019]
- 15 **Sanada Y**, Mizuta K, Yano T, Hatanaka W, Okada N, Wakiya T, Umehara M, Egami S, Urahashi T, Hishikawa S, Fujiwara T, Sakuma Y, Hyodo M, Yamamoto H, Yasuda Y, Kawarasaki H. Double-balloon enteroscopy for bilioenteric anastomotic stricture after pediatric living donor liver transplantation. *Transpl Int* 2011; **24**: 85-90 [PMID: 20738835 DOI: 10.1111/j.1432-2277.2010.01156.x]
- 16 **Tomoda T**, Tsutsumi K, Kato H, Mizukawa S, Yabe S, Akimoto Y, Seki H, Uchida D, Matsumoto K, Yamamoto N, Horiguchi S, Okada H. Outcomes of management for biliary stricture after living donor liver transplantation with hepaticojejunostomy using short-type double-balloon enteroscopy. *Surg Endosc* 2016; **30**: 5338-5344 [PMID: 27059976 DOI: 10.1007/s00464-016-4886-x]
- 17 **Tsujino T**, Isayama H, Kogure H, Sato T, Nakai Y, Koike K. Endoscopic management of biliary strictures after living donor liver transplantation. *Clin J Gastroenterol* 2017; **10**: 297-311 [PMID: 28600688 DOI: 10.1007/s12328-017-0754-z]
- 18 **Osoegawa T**, Motomura Y, Akahoshi K, Higuchi N, Tanaka Y, Hisano T, Itaba S, Gibo J, Yamada M, Kubokawa M, Sumida Y, Akiho H, Ihara E, Nakamura K. Improved techniques for double-balloon-enteroscopy-assisted endoscopic retrograde cholangiopancreatography. *World J Gastroenterol* 2012; **18**: 6843-6849 [PMID: 23239923 DOI: 10.3748/wjg.v18.i46.6843]
- 19 **Cho S**, Kamalporn P, Kandel G, Kortan P, Marcon N, May G. 'Short' double-balloon enteroscope endoscopic retrograde cholangiopancreatography in patients with a surgically altered upper gastrointestinal tract. *Can J Gastroenterol* 2011; **25**: 615-619 [PMID: 22059169 DOI: 10.1155/2011/354546]
- 20 **Shimatani M**, Tokuhara M, Kato K, Miyamoto S, Masuda M, Sakao M, Fukata N, Miyoshi H, Ikeura T, Takaoka M, Okazaki K. Utility of newly developed short-type double-balloon endoscopy for endoscopic retrograde cholangiography in postoperative patients. *J Gastroenterol Hepatol* 2017; **32**: 1348-1354 [PMID: 28019036 DOI: 10.1111/jgh.13713]



Published by **Baishideng Publishing Group Inc**
7041 Koll Center Parkway, Suite 160, Pleasanton, CA 94566, USA

Telephone: +1-925-3991568

E-mail: bpgoffice@wjgnet.com

Help Desk: <https://www.f6publishing.com/helpdesk>

<https://www.wjgnet.com>

