

# World Journal of *Gastroenterology*

*World J Gastroenterol* 2020 November 21; 26(43): 6706-6908



## Contents

Weekly Volume 26 Number 43 November 21, 2020

## OPINION REVIEW

- 6706 Gastric acid level of humans must decrease in the future  
*Fujimori S*

## EXPERT CONSENSUS

- 6710 First United Arab Emirates consensus on diagnosis and management of inflammatory bowel diseases: A 2020 Delphi consensus  
*Alkhatry M, Al-Rifai A, Annese V, Georgopoulos F, Jazzar AN, Khassouan AM, Koutoubi Z, Nathwani R, Taha MS, Limdi JK*

## MINIREVIEWS

- 6770 Hepatocellular carcinoma after direct-acting antiviral hepatitis C virus therapy: A debate near the end  
*Muzica CM, Stanciu C, Huiban L, Singeap AM, Sfarti C, Zenovia S, Cojocariu C, Trifan A*

## ORIGINAL ARTICLE

## Basic Study

- 6782 *Lactobacillus bulgaricus* inhibits colitis-associated cancer via a negative regulation of intestinal inflammation in azoxymethane/dextran sodium sulfate model  
*Silveira DSC, Veronez LC, Lopes-Júnior LC, Anatriello E, Brunaldi MO, Pereira-da-Silva G*
- 6795 Antifungal activity and antidiarrheal activity via antimotility mechanisms of (-)-fenchone in experimental models  
*Pessoa MLS, Silva LMO, Araruna MEC, Serafim CAL, Alves Júnior EB, Silva AO, Pessoa MMB, Diniz Neto H, de Oliveira Lima E, Batista LM*
- 6810 Effects of Yue-Bi-Tang on water metabolism in severe acute pancreatitis rats with acute lung-kidney injury  
*Hu J, Zhang YM, Miao YF, Zhu L, Yi XL, Chen H, Yang XJ, Wan MH, Tang WF*
- 6822 Tissue microarray-chip featuring computerized immunophenotypical characterization more accurately subtypes ampullary adenocarcinoma than routine histology  
*Palmeri M, Funel N, Di Franco G, Furbetta N, Gianardi D, Guadagni S, Bianchini M, Pollina LE, Ricci C, Del Chiaro M, Di Candio G, Morelli L*

## Retrospective Cohort Study

- 6837 Feasibility and nutritional impact of laparoscopic assisted tailored subtotal gastrectomy for middle-third gastric cancer  
*Liu H, Jin P, Ma FH, Ma S, Xie YB, Li Y, Li WK, Kang WZ, Tian YT*
- 6853 Role of doublecortin-like kinase 1 and leucine-rich repeat-containing G-protein-coupled receptor 5 in patients with stage II/III colorectal cancer: Cancer progression and prognosis  
*Kang XL, He LR, Chen YL, Wang SB*

**Clinical Trials Study**

- 6867** Comparison of two supplemental oxygen methods during gastroscopy with propofol mono-sedation in patients with a normal body mass index

*Shao LJZ, Zou Y, Liu FK, Wan L, Liu SH, Hong FX, Xue FS*

**Observational Study**

- 6880** Barriers for resuming endoscopy service in the context of COVID-19 pandemic: A multicenter survey from Egypt

*Elshaarawy O, Lashen SA, Makhoulf NA, Abdeltawab D, Zaghloul MS, Ahmed RM, Fathy H, Afifi S, Abdel-Gawad M, Abdelsameea E, Abd-El salam S, Mohamed SY, Tag-Adeen M, Tharwat M, Alzamzamy A, Bekhit AN, Eid AM, Awad A, Aamr M, Abd El Dayem WA, Wifi MN, Alborae M*

**SYSTEMATIC REVIEWS**

- 6891** Crohn's disease in low and lower-middle income countries: A scoping review

*Rajbhandari R, Blakemore S, Gupta N, Adler AJ, Noble CA, Mannan S, Nikolli K, Yih A, Joshi S, Bukhman G*

**ABOUT COVER**

Editorial Board Member of *World Journal of Gastroenterology*, Dr. Vasiliy I Reshetnyak is a Distinguished Professor at the AI Yevdokimov Moscow State University of Medicine and Dentistry in Moscow, Russia. In 1977, he graduated with honors from the Medical Faculty of IM Sechenov 1st Moscow Medical Institute. In 1982m Dr. Reshetnyak defended his PhD thesis. Working at the Central Research Institute of Gastroenterology (CRIG) led to obtainment of his doctoral thesis (DSc) in 1996 and his rise to Deputy Director on Scientific Work at the CRIG. Since 2003, Professor Reshetnyak has served as an Academic Secretary of the Research Institute of General Reanimatology. His scientific research activity has focused on the diagnosis, clinical and laboratory manifestations, and treatment of gastroenterological diseases with patients in critical states. Since 2019, Dr. Reshetnyak has held the rank of Professor of the Department of Propaedeutic of Internal Diseases and Gastroenterology. (L-Editor: Filipodia)

**AIMS AND SCOPE**

The primary aim of *World Journal of Gastroenterology* (WJG, *World J Gastroenterol*) is to provide scholars and readers from various fields of gastroenterology and hepatology with a platform to publish high-quality basic and clinical research articles and communicate their research findings online. WJG mainly publishes articles reporting research results and findings obtained in the field of gastroenterology and hepatology and covering a wide range of topics including gastroenterology, hepatology, gastrointestinal endoscopy, gastrointestinal surgery, gastrointestinal oncology, and pediatric gastroenterology.

**INDEXING/ABSTRACTING**

The WJG is now indexed in Current Contents®/Clinical Medicine, Science Citation Index Expanded (also known as SciSearch®), Journal Citation Reports®, Index Medicus, MEDLINE, PubMed, PubMed Central, and Scopus. The 2020 edition of Journal Citation Report® cites the 2019 impact factor (IF) for WJG as 3.665; IF without journal self cites: 3.534; 5-year IF: 4.048; Ranking: 35 among 88 journals in gastroenterology and hepatology; and Quartile category: Q2.

**RESPONSIBLE EDITORS FOR THIS ISSUE**

Production Editor: Yu-Jie Ma; Production Department Director: Xiang Li; Editorial Office Director: Ze-Mao Gong.

**NAME OF JOURNAL**

*World Journal of Gastroenterology*

**ISSN**

ISSN 1007-9327 (print) ISSN 2219-2840 (online)

**LAUNCH DATE**

October 1, 1995

**FREQUENCY**

Weekly

**EDITORS-IN-CHIEF**

Andrzej S Tarnawski, Subrata Ghosh

**EDITORIAL BOARD MEMBERS**

<http://www.wjgnet.com/1007-9327/editorialboard.htm>

**PUBLICATION DATE**

November 21, 2020

**COPYRIGHT**

© 2020 Baishideng Publishing Group Inc

**INSTRUCTIONS TO AUTHORS**

<https://www.wjgnet.com/bpg/gerinfo/204>

**GUIDELINES FOR ETHICS DOCUMENTS**

<https://www.wjgnet.com/bpg/GerInfo/287>

**GUIDELINES FOR NON-NATIVE SPEAKERS OF ENGLISH**

<https://www.wjgnet.com/bpg/gerinfo/240>

**PUBLICATION ETHICS**

<https://www.wjgnet.com/bpg/GerInfo/288>

**PUBLICATION MISCONDUCT**

<https://www.wjgnet.com/bpg/gerinfo/208>

**ARTICLE PROCESSING CHARGE**

<https://www.wjgnet.com/bpg/gerinfo/242>

**STEPS FOR SUBMITTING MANUSCRIPTS**

<https://www.wjgnet.com/bpg/GerInfo/239>

**ONLINE SUBMISSION**

<https://www.f6publishing.com>



Clinical Trials Study

## Comparison of two supplemental oxygen methods during gastroscopy with propofol mono-sedation in patients with a normal body mass index

Liu-Jia-Zi Shao, Yi Zou, Fu-Kun Liu, Lei Wan, Shao-Hua Liu, Fang-Xiao Hong, Fu-Shan Xue

**ORCID number:** Liu-Jia-Zi Shao 0000-0002-8888-1804; Yi Zou 0000-0001-7520-3775; Fu-Kun Liu 0000-0002-5997-1915; Lei Wan 0000-0003-4120-7393; Shao-Hua Liu 0000-0002-9374-0192; Fang-Xiao Hong 0000-0003-0516-8956; Fu-Shan Xue 0000-0002-1028-6036.

**Author contributions:** Shao LJZ and Zou Y contributed equally to this study, study design/planning, study conduct, data analysis, and writing and revising the paper; Liu FK assisted with study conduct, data analysis, and revising the paper; Wan L assisted with study design/planning, study conduct, data analysis, and revising the paper; Liu SH assisted with study conduct, data analysis and curation, and revising the paper; Hong FX assisted with study design/planning, study conduct, data analysis, and revising the paper; Xue FS assisted with study design/planning, study conduct, and writing and revising the paper.

**Supported by** "Renfu" Research Fund by Chinese Society of Digestive Endoscopy, No. CSDE012017120006.

**Institutional review board statement:** This study was approved by the Institutional

Liu-Jia-Zi Shao, Yi Zou, Fu-Kun Liu, Lei Wan, Shao-Hua Liu, Fang-Xiao Hong, Fu-Shan Xue, Department of Anesthesiology, Beijing Friendship Hospital, Capital Medical University, Beijing 100050, China

**Corresponding author:** Fu-Shan Xue, MD, Professor, Department of Anesthesiology, Beijing Friendship Hospital, Capital Medical University, No. 95 Yong'an Road, Xicheng District, Beijing 100050, China. [fushanxue@outlook.com](mailto:fushanxue@outlook.com)

### Abstract

#### BACKGROUND

Hypoxemia due to respiratory depression and airway obstruction during upper gastrointestinal endoscopy with sedation is a common concern. The Wei nasal jet tube (WNJT) is a new nasopharyngeal airway with the ability to provide supraglottic jet ventilation and oxygen insufflation *via* its built-in wall channel. The available evidence indicates that with a low oxygen flow, compared with nasal cannula, the WNJT does not decrease the occurrence of hypoxemia during upper gastrointestinal endoscopy with propofol sedation. To date, there has been no study assessing the performance of WNJT for supplemental oxygen during upper gastrointestinal endoscopy with sedation when a moderate oxygen flow is used.

#### AIM

To determine whether the WNJT performs better than the nasal prongs for the prevention of hypoxemia during gastroscopy with propofol mono-sedation when a moderate oxygen flow is provided in patients with a normal body mass index.

#### METHODS

This study was performed in 291 patients undergoing elective gastroscopy with propofol mono-sedation. Patients were randomized into one of two groups to receive either the WNJT (WNJT group,  $n = 147$ ) or the nasal cannula (nasal cannula group,  $n = 144$ ) for supplemental oxygen at a 5-L/min flow during gastroscopy. The lowest SpO<sub>2</sub> during gastroscopy was recorded. The primary endpoint was the incidence of hypoxemia or severe hypoxemia during gastroscopy.

#### RESULTS



Ethics Committee of Beijing Friendship Hospital, China (Ethics Committee number: 2017-P2-009-02).

#### Clinical trial registration statement:

This study is registered with the Chinese Clinical Trial Registry (registration No. ChiCTR-IOR-17013089).

**Informed consent statement:** The written informed consent was obtained from each patient included in the study.

**Conflict-of-interest statement:** No external funding or competing interests declared.

**Data sharing statement:** No additional data are available.

**CONSORT 2010 statement:** The authors have read the CONSORT 2010 statement, and the manuscript was prepared and revised according to the CONSORT 2010 statement.

**Open-Access:** This article is an open-access article that was selected by an in-house editor and fully peer-reviewed by external reviewers. It is distributed in accordance with the Creative Commons Attribution NonCommercial (CC BY-NC 4.0) license, which permits others to distribute, remix, adapt, build upon this work non-commercially, and license their derivative works on different terms, provided the original work is properly cited and the use is non-commercial. See: <http://creativecommons.org/licenses/by-nc/4.0/>

**Manuscript source:** Unsolicited manuscript

**Specialty type:** Gastroenterology and hepatology

**Country/Territory of origin:** China

#### Peer-review report's scientific quality classification

Grade A (Excellent): 0  
Grade B (Very good): 0  
Grade C (Good): C  
Grade D (Fair): 0  
Grade E (Poor): 0

The total incidence of hypoxemia and severe hypoxemia during gastroscopy was significantly decreased in the WNJT group compared with the nasal cannula group ( $P = 0.000$ ). The lowest median SpO<sub>2</sub> during gastroscopy was significantly higher (98%; interquartile range, 97-99) in the WNJT group than in the nasal cannula group (96%; interquartile range, 93-98). Epistaxis by device insertion in the WNJT group occurred in 7 patients but stopped naturally without any treatment. The two groups were comparable in terms of the satisfaction of physicians, anesthetists and patients.

#### CONCLUSION

With a moderate oxygen flow, the WNJT is more effective for the prevention of hypoxemia during gastroscopy with propofol mono-sedation compared with nasal prongs, but causing slight epistaxis in a few patients.

**Key Words:** Gastroscopy; Hypoxemia; Wei nasal jet tube; Nasal cannula; Supplemental oxygen; Adverse outcomes

©The Author(s) 2020. Published by Baishideng Publishing Group Inc. All rights reserved.

**Core Tip:** This study is a prospective randomized controlled trial aimed to determine whether the Wei nasal jet tube (WNJT) performs better than the nasal prongs for the prevention of hypoxemia during gastroscopy with propofol mono-sedation when a moderate oxygen flow is provided in patients with a normal body mass index. Our results show that compared with nasal prongs for supplemental oxygen, the WNJT is more effective for the prevention of hypoxemia during gastroscopy with propofol mono-sedation when a moderate oxygen flow is provided. However, the WNJT caused slight epistaxis in a few patients.

**Citation:** Shao LJZ, Zou Y, Liu FK, Wan L, Liu SH, Hong FX, Xue FS. Comparison of two supplemental oxygen methods during gastroscopy with propofol mono-sedation in patients with a normal body mass index. *World J Gastroenterol* 2020; 26(43): 6867-6879

**URL:** <https://www.wjgnet.com/1007-9327/full/v26/i43/6867.htm>

**DOI:** <https://dx.doi.org/10.3748/wjg.v26.i43.6867>

## INTRODUCTION

Endoscopy is an effective method for early detection of gastrointestinal (GI) cancers, as well as a standard technique for the diagnosis and treatment of many GI diseases<sup>[1,2]</sup>. However, patients are often reluctant to undergo GI endoscopy while awake due to its uncomfortable nature and adverse reactions, such as nausea, vomiting, anxiety, throat bleeding, and others<sup>[3]</sup>. As the use of sedation may significantly reduce patients' discomfort during GI endoscopy, it can improve patient satisfaction, acceptance and compliance with repeated GI endoscopy screening<sup>[4]</sup>. Thus, sedation using short-acting intravenous anesthetics, such as propofol and remifentanyl, has been recommended by the international guidelines for upper GI endoscopy<sup>[5-8]</sup>. However, hypoxemia due to respiratory depression and airway obstruction during GI endoscopy with sedation is a common concern<sup>[9]</sup>. In particular, severe hypoxemia not only requires emergent airway management, such as mask ventilation and even endotracheal intubation, but can also result in an interruption of the endoscopic procedure<sup>[10]</sup>. Therefore, prevention of hypoxemia is essential in safe and effective sedation for GI endoscopy.

Currently, both the American Society of Anesthesiologists and the American Society for Gastrointestinal Endoscopy recommend the use of supplemental oxygen to reduce the occurrence of hypoxemia during GI endoscopy with sedation. Furthermore, the nasal cannula is one of most convenient tools for providing supplemental oxygen. It has been shown that compared with patients not receiving supplemental oxygen, those receiving supplemental oxygen using a nasal cannula exhibit a significantly decreased incidence of hypoxemia during GI endoscopy with sedation<sup>[9]</sup>. However, the use of nasal cannula cannot overcome upper airway obstruction due to soft tissue collapse and tongue falling, which is a major cause of hypoxemia during GI endoscopy

**Received:** July 19, 2020  
**Peer-review started:** July 19, 2020  
**First decision:** August 8, 2020  
**Revised:** August 10, 2020  
**Accepted:** October 20, 2020  
**Article in press:** October 20, 2020  
**Published online:** November 21, 2020

**P-Reviewer:** Chan SM  
**S-Editor:** Zhang L  
**L-Editor:** MedE-Ma JY  
**P-Editor:** Li JH



in patients receiving deep sedation<sup>[11]</sup>. For this condition, a supraglottic airway device, such as the nasopharyngeal airway, might be a good solution because it can be conveniently inserted to ensure upper airway opening without interfering with the gastroscopic procedure<sup>[12]</sup>. It has been shown that compared with nasal prongs in obese patients undergoing gastroscopy with intravenous anesthesia, the use of a convenient nasopharyngeal airway for supplemental oxygen results in attenuated SpO<sub>2</sub> reduction and improves the satisfaction of physicians and anesthetists<sup>[13]</sup>. However, the insertion of a convenient nasopharyngeal airway is an invasive procedure with the potential risk of airway injury<sup>[13,14]</sup>.

The Wei nasal jet tube (WNJT; Well Lead Medical Co. Ltd., Guangzhou, China; **Figure 1**) is a new design of special nasopharyngeal airway with two additional channels built inside the wall for jet oxygen supplementation and monitoring of the end-tidal partial concentration of carbon dioxide. In contrast to the convenient nasopharyngeal airways, the WNJT can directly connect to an anesthesia machine to deliver oxygen into the upper airway through its jet ventilation channel. Furthermore, the end-tidal partial concentration of carbon dioxide monitored continuously by another channel of the WNJT can be used as a sign to observe regular breathing airflow in the upper airway and the occurrence of respiratory depression during GI endoscopy with sedation<sup>[15,16]</sup>. Currently, there are two sizes of WNJTs commercially available for adult patients with inner diameters of 5.0 mm and 7.0 mm, outer diameters of 7.3 mm and 10.0 mm, and lengths of 145 mm and 155 mm.

Recently, one multicenter, randomized controlled trial assessing the influence of supplemental oxygen with the WNJT on respiration and ventilation during gastroscopy with propofol sedation showed that with a low oxygen flow of 2 L/min, compared with the nasal cannula, the WNJT only decreased use of the jaw-thrust maneuver for upper airway opening but did not reduce the incidences of total adverse events, subclinical respiratory depression, hypoxemia, severe hypoxemia, or facemask ventilation<sup>[15]</sup>. It is believed that increasing oxygen flow will improve the efficacy of supplemental oxygen in the upper airway<sup>[17]</sup>. However, no study has assessed the performance of WNJT for supplemental oxygen during GI endoscopy with sedation when a moderate oxygen flow is used. Most importantly, the insertion of the WNJT is an invasive procedure with a potential risk of epistaxis. To help anesthesiologists choose appropriate supplemental oxygen methods based on the risk-benefit ratio, we conducted a prospective randomized controlled trial to compare the efficacy and safety of WNJT and nasal prongs for supplemental oxygen during gastroscopy with sedation in patients with a normal body mass index (BMI) when a moderate oxygen flow was used.

## MATERIALS AND METHODS

### *Patient population and study design*

After the study protocol was approved by the Institutional Ethics Committee of Beijing Friendship Hospital, China (Ethics Committee number: 2017-P2-009-02) and registered with the Chinese Clinical Trial Registry (registration No. ChiCTR-IOR-17013089), adult patients scheduled for gastroscopy with propofol mono-sedation between November 2017 and December 2018 were recruited. The inclusion criteria were male or female patients aged 18 to 65 years, a BMI of 18 to 25 kg/m<sup>2</sup>, American Society of Anesthesiologists physical status classification 1-2 and the ability to provide informed consent. Exclusion criteria were a history of coagulopathies or nose bleeding; severe cardiac, pulmonary, hepatic or renal diseases; infection of the mouth, the nose, or the throat; and allergy to propofol, eggs, soybean, or albumin.

Written informed consent was obtained from each patient included in the study. According to a random number table generated by a computer, patients were randomly assigned to receive either the WNJT (WNJT group) or the nasal prongs (nasal cannula group) for supplemental oxygen during gastroscopy. All patients fasted for 8 h before gastroscopy. After patients entered the examination room, topical anesthesia of the oral cavity and pharynx was administered by gargling a 2% lidocaine gel (10 g; 0.2 g; Jumpcan Pharmaceutical Group, China), and routine monitoring, including heart rate, noninvasive blood pressure, and pulse oxygen saturation (SpO<sub>2</sub>), was performed. After intravenous access was established, the patient was placed in the lateral position, and preoxygenation was performed until an end-tidal oxygen concentration of 88%-90% was reached. To facilitate preoxygenation, patients were asked to take 8 deep breaths in 60 s with 100% oxygen.

After adequate preoxygenation, sedation was induced with slow intravenous

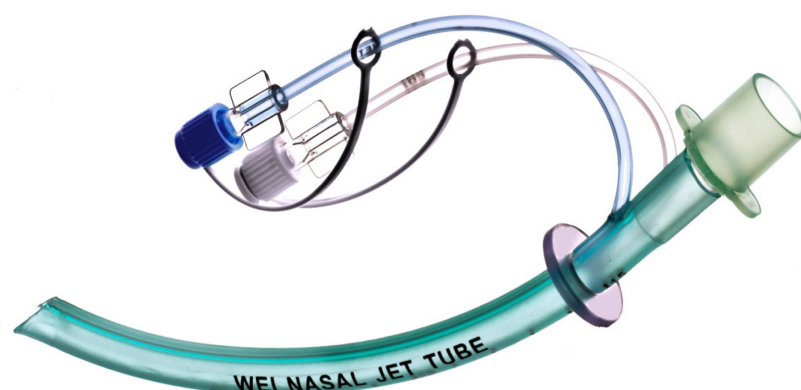


Figure 1 Wei nasal jet tube.

injection of propofol (10 mg/1 mL; Diprivan, Astrazeneca, United Kingdom). Sedation depth was evaluated according to the modified observer's assessment of alertness/sedation (MOAA/S) score<sup>[18]</sup>: 5: Responds readily to spoken name; 4: Lethargic response; 3: Response after name called loudly; 2: Response after mild to moderate shaking; 1: Response to trapezius squeeze. The depth of sedation was assessed by an anesthesiologist blinded to the group assignment who was well trained to master the application of the MOAA/S scoring system before the initiation of this study. According to our routine practice, deep sedation with a MOAA/S score of 1 was first obtained to ensure successful gastroscope insertion and to decrease adverse responses to the insertion of the gastroscope into the upper airway. During gastroscopy, moderate sedation with a MOAA/S score of 2 or 3 was maintained with 20-30 mg additional propofol as needed.

Before sedation, two sprays of ephedrine were applied to each nostril in all patients. The selected naris for the placement of the studied devices was the one that the patient thought was more patent. By examining the outer diameter of the WNJT and the size of patients' nostrils, an appropriate WNJT size was selected for each patient in the WNJT group. Using the scale on the exterior wall of the WNJT, the distance between the tip of the nose and earlobe on one side was measured in each patient and was used as the predicted insertion depth of the WNJT. After adequate depth of sedation was obtained before gastroscopy was initiated, the oxygen facemask was removed. Then, both the WNJT and nasal prongs were placed for supplemental oxygen. After inserting the WNJT, its position in the upper airway was re-examined by gastroscopy and adjusted if needed. If the insertion of the WNJT was difficult *via* the selected nasal passage, the other side was tried. If it was still unsuccessful after three attempts, the insertion of the WNJT was regarded as a failure.

During gastroscopy, a moderate oxygen flow of 5 L/min was continuously delivered through the WNJT and nasal cannula in both groups. After gastroscopy, the WNJT and nasal cannula were removed before full recovery from sedation. Consequently, patients were also blinded to their group assignment. The duration of gastroscopy and total dosage of propofol were recorded.

### Observed variables

The lowest SpO<sub>2</sub> during gastroscopy was noted. If hypoxemia (SpO<sub>2</sub> < 90%) occurred, we implemented the following measures: (1) No additional drug was administered; (2) Audio or painful stimulation was applied; (3) Oxygen flow was increased from 5 to 8 L/min; (4) Airway opening was performed using conventional maneuvers, including jaw thrust, head extension and head position change; (5) The gastroscope tube was removed and facemask ventilation was performed if necessary; and (6) Endotracheal intubation for artificial ventilation was performed if the above measures were unsuccessful.

The primary outcome was the incidence of hypoxemia (SpO<sub>2</sub> = 75%-89% for < 60 s) and severe hypoxemia (SpO<sub>2</sub> < 75% at any time or < 90% for > 60 s)<sup>[15]</sup>. Secondary outcomes included (1) The lowest SpO<sub>2</sub> during gastroscopy; (2) Interventions to manage hypoxemia, including jaw thrust, facemask ventilation, and endotracheal intubation; (3) Adverse events, such as epistaxis, body movement and cough during gastroscopy, and postoperative sore throat; and (4) Satisfaction of anesthetists,



physicians, and patients. Epistaxis was assessed by gastroscopy using a subjective scale: 0, no bleeding; 1, minimal bleeding not requiring suctioning; 2, moderate bleeding requiring suctioning but not hampering visualization; and 3, severe bleeding requiring suctioning and hampering visualization<sup>[19]</sup>. If severe epistaxis occurred in the WNJT group, compression hemostasis was first performed; if it did not work, other medical or surgical measures were considered. Postoperative sore throat was assessed at the time of consciousness recovery and 30 min later. At 30 min after the procedure, satisfaction of anesthetists, physicians, and patients was evaluated using a 10-point scale and classified as follows: Poor, 1-4; Fair, 5-7; and Good, 8-10<sup>[20]</sup>.

### Randomization and sample size estimation

Computer-generated randomization sequences were used for group assignment in our study. The randomization sequence was generated by a research assistant who was independent of the study and did not have contact with the study participants. Randomization was performed using opaque sealed envelopes before sedation induction.

Sample size was calculated using Pass software (version 11.0, NCSS, LLC, Kaysville, UT, United States). Two independent proportions of procedures were used. Based on our preliminary study, the incidence of hypoxemia during gastroscopy with propofol mono-sedation was approximately 30%. Thus, a 30% of patients in the nasal cannula group were expected to develop hypoxemia. P1 and P2 were calculated from the assumption that the WNJT would achieve a reduction from 30% to 15% in the incidence of hypoxemia. With  $\alpha = 0.05$  and a power of 90%, we estimated that 131 patients per group would be required for our study. If the dropout rate was approximately 10%, a total of 288 patients (144 in each group) would be required.

### Statistical analysis

Statistical analysis of data was performed using Statistical Product and Service Solutions (23.0) by a blinded statistician from the Clinical Research Institute of Beijing Friendship Hospital. Data are summarized as the mean  $\pm$  SD or median (25<sup>th</sup> and 75<sup>th</sup> percentile) for continuous data and as frequency and percentages for categorical data. For continuous data, the characteristics and outcomes of the two groups were compared using Student's *t* test or Wilcoxon-Mann-Whitney test based on viability of the normality assumption. Chi-squared or Fisher's exact tests were used to compare two groups with categorical characteristics and outcomes. A *P* value  $< 0.05$  was considered statistically significant.

## RESULTS

The flow chart of included and excluded patients in this study is shown in **Figure 2**. A total of 303 patients were enrolled, and 12 were excluded. Of the 12 excluded patients, 3 were allergic to eggs, 2 had chronic obstructive pulmonary disease, 2 had uremia, one had nasal bone fracture, 3 had incomplete consent forms, and one had missing basic data. Thus, a total of 291 subjects were randomized into the two groups. After randomization, however, 3 patients in the WNJT group were further excluded due to a failed WNJT insertion. Finally, 144 patients in each group were included for data analysis. The baseline characteristics of patients were not significantly different between the groups, but the procedure time and total propofol dosage were significantly lower in the nasal cannula group than in the WNJT group (**Table 1**).

Adverse events and interventions related to hypoxemia are listed in **Table 2**. The median lowest SpO<sub>2</sub> during gastroscopy was 98% (interquartile range, 97, 99) and 96% (interquartile range, 93, 98) in the WNJT and nasal cannula groups, respectively, with a significant difference between the groups. The incidence of severe hypoxemia (0.7% *vs* 1.4%) during gastroscopy was comparable between the two groups (*P* = 1.000), but the incidence of hypoxemia (1.4% *vs* 13.2%, respectively) and the total incidence of hypoxemia and severe hypoxemia (2.1% *vs* 14.6%, respectively) during gastroscopy were significantly lower in the WNJT group than in the nasal cannula group (*P* = 0.000). Furthermore, the use of airway opening maneuvers to correct hypoxemia was reduced in the WNJT group compared with the nasal cannula group (2.8% *vs* 25%, respectively, *P* = 0.000). In the WNJT group, epistaxis occurred in 7 patients, but visible epistaxis was uncommon. In the nasal cannula group, no case experienced epistaxis, but 4 patients required an interruption of the endoscopic procedure for facemask ventilation to correct hypoxemia. In addition, the incidence of epistaxis was significantly higher in the WNJT group than in the nasal cannula group, but other

**Table 1** Baseline characteristics of patients, procedure time and total propofol dosage

	WNJT group (n = 144)	Nasal cannula group (n = 144)	P value
Age (yr)	53 (40, 60)	55 (41, 60)	0.537
Gender (M/F)	43/101	46/98	0.702
Body mass index (kg/m <sup>2</sup> )	23 (21,24)	22 (21,24)	0.086
ASA physical classification (1/2)	(32/112)	(41/103)	0.223
Baseline SpO <sub>2</sub> (%)	98 (97, 99)	98 (97, 98)	0.061
Procedure times (min)	5.0 (4.4, 5.2)	4.8 (4.5, 5.0)	0.002
Total propofol dosages (mg)	160 (140, 188)	140 (120, 160)	0.000

Data are presented as median (interquartile range) or number of patients. SpO<sub>2</sub>: Pulse oxygen saturation; ASA: American Society of Anesthesiologists; WNJT: Wei nasal jet tube.

**Table 2** Hypoxemia and lowest pulse oxygen saturation during the gastroscopy, and interventions related to hypoxemia and adverse events

	WNJT group (n = 144)	Nasal cannula group (n = 144)	P value
Total occurrence of hypoxemia	3 (2.1)	21 (14.6)	0.000
Hypoxemia	2 (1.4)	19 (13.2)	0.000
Severe hypoxemia	1 (0.7)	2 (1.4)	1.000
Lowest SpO <sub>2</sub>	98 (97, 99)	96 (93, 98)	0.000
Airway opening maneuvers	4 (2.8)	36 (25)	0.000
Facemask ventilation	0 (0)	4 (2.8)	0.131
Body movement	8 (5.6)	9 (6.3)	0.803
Cough	10 (6.9)	11 (7.6)	0.821
Epistaxis (0/1/2/3)	0/7/0/0 (4.9)	0 (0)	0.022
Sore throat	2 (1.4)	3 (2.1)	1.000

Data are presented as median (interquartile range) or number of patients (percent). SpO<sub>2</sub>: Pulse oxygen saturation; WNJT: Wei nasal jet tube.

adverse events were not significantly different between the two groups.

The two groups were comparable in terms of the satisfaction of physicians, anesthetists and patients (Table 3).

## DISCUSSION

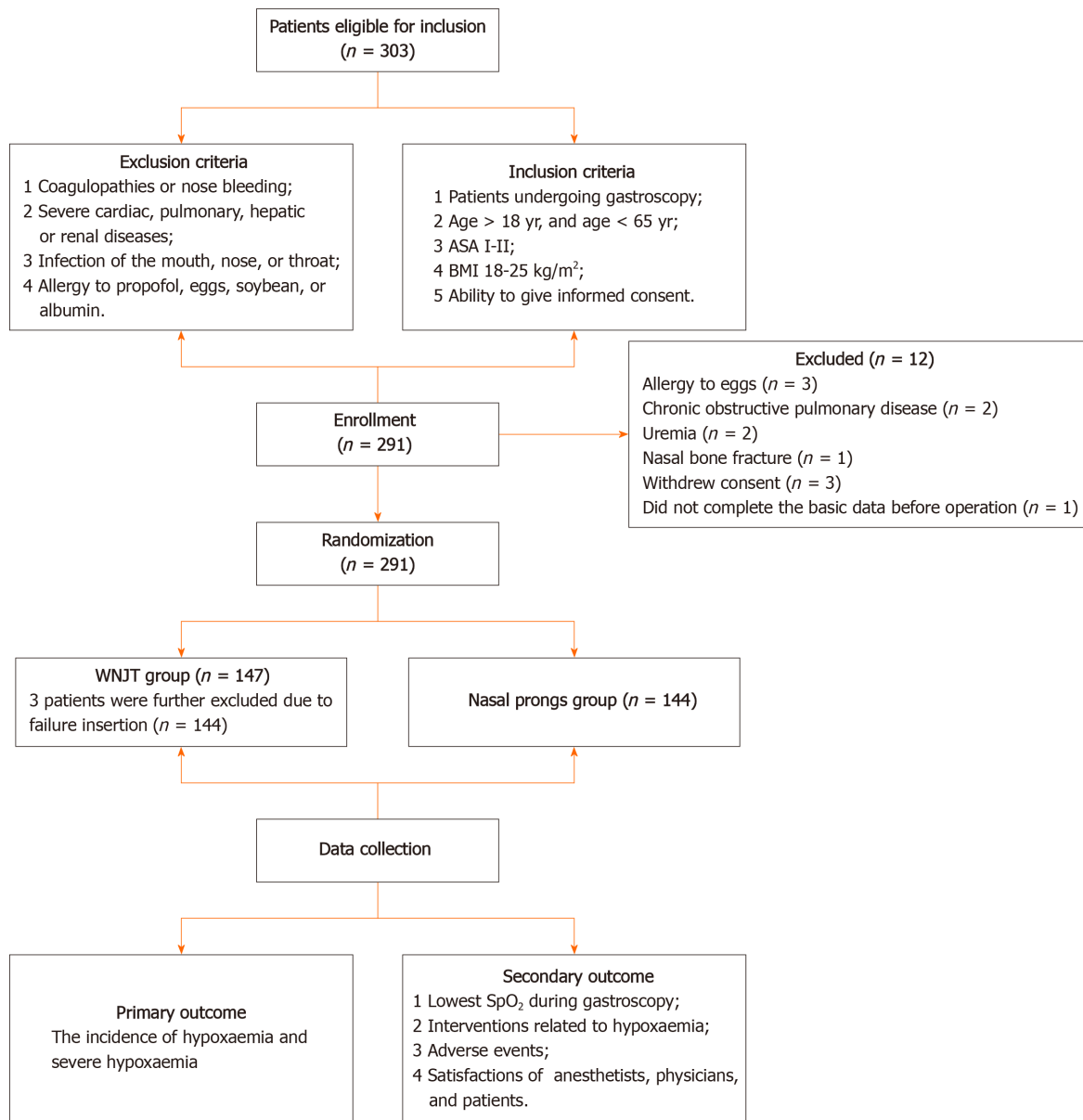
Hypoxemia is common during GI endoscopy with sedation<sup>[10]</sup>. Although this issue is commonly transient and may spontaneously recover, it can occasionally lead to the need for urgent airway management and interruption of the endoscopic procedure<sup>[11]</sup>. It has been reported that propofol deep sedation for GI endoscopy is associated with an increased risk of airway adverse events compared to general anesthesia administered in the operating room<sup>[21]</sup>. Most importantly, it is difficult for anesthetists to identify early signs of hypoxemia and manage it promptly, as sedated patients do not exhibit a proper response to hypoxia<sup>[9]</sup>. Thus, there is increasing enthusiasm worldwide for exploring effective measures to prevent or decrease the occurrence of hypoxemia during GI endoscopy with sedation.

Given that intravenous propofol alone is often the preferred sedation method for the vast majority of patients undergoing GI endoscopy with a short procedure time<sup>[22]</sup>, propofol mono-sedation was selected in this study. By comparing the efficacy and safety of WNJT and nasal prongs for supplemental oxygen during gastroscopy with propofol mono-sedation, the primary purpose of the present study was to determine

**Table 3** Satisfaction of physicians, anesthetists and patients

	WNJT group (n = 144)			Nasal cannula group (n = 144)			P value
	Good	Fair	Poor	Good	Fair	Poor	
Physicians	143 (99.3)	1 (0.7)	0	139 (96.5)	4 (2.8)	1 (0.7)	0.214
Anesthetists	140 (97.2)	4 (2.8)	0	134 (93.1)	8 (5.6)	2 (1.4)	0.196
Patients	142 (98.6)	2 (1.4)	0	144 (100)	0	0	0.498

Data are presented as number of patients (percent). WNJT: Wei nasal jet tube.



**Figure 2** Flow chart of included and excluded patients in this study. ASA: American Society of Anesthesiologists; BMI: Body mass index; WNJT: Wei nasal jet tube.

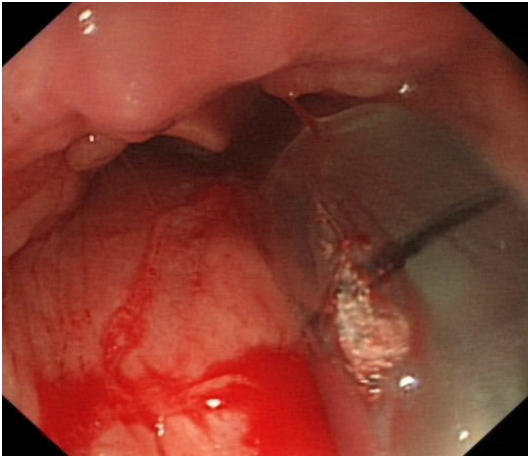
whether the WNJT performed better than the convenient nasal prongs for providing supplemental oxygen during gastroscopy with propofol mono-sedation in patients with a normal BMI. The primary findings included the following: (1) The use of the WNJT significantly decreased the occurrence of hypoxemia and improved arterial oxygenation level; (2) The incidence of postoperative adverse events was similar in the two groups, but epistaxis by device insertion only occurred in the WNJT group; and

(3) The two devices provided the same satisfaction of physicians, anesthetists and patients.

Qin *et al*<sup>[15]</sup> previously assessed the performance of WNJT for supplemental oxygen during gastroscopy with propofol mono-sedation. They showed that compared to nasal prongs, the WNJT only decreased use of the jaw-thrust maneuver but did not decrease the incidences of hypoxemia/severe hypoxemia or the use of facemask ventilation. We noted that the incidence of severe hypoxemia in the WNJT group was comparable between their study and our study (0.2% *vs* 0.7%), but the incidence of hypoxemia in the WNJT group was significantly higher in their study than in our study (8% *vs* 1.4%). This may be due to the following factors. First, a low oxygen flow of 2 L/min was used in their study, while a moderate oxygen flow of 5 L/min was implemented in our study. It is generally believed that increasing oxygen flow improves the efficacy of supplemental oxygen in the upper airway<sup>[17]</sup>. Second, a wealth of evidence indicates that adequate preoxygenation enables patients to tolerate a prolonged period of apnea and provides an increased margin of safety<sup>[23,24]</sup>. In our center, preoxygenation aimed at obtaining an expiratory oxygen concentration of 88% to 90% is routinely performed before sedation for GI endoscopy. This has been considered a particularly meaningful process for patients who are unable to obtain immediate facemask ventilation when hypoxemia occurs in some conditions, for example, in the course of gastroscopy. Third, in our study, an initial deep sedation was induced by the use of propofol alone to facilitate gastroscope insertion and decrease the adverse events induced by gastroscope insertion. In contrast, a moderate sedation level with an MOAA/S score of 2 or 3 was used in the Qin *et al*<sup>[15]</sup> study. The available evidence indicates that when propofol is intravenously injected as a single agent and administered to the level of moderate sedation, patients often present significant responses to GI endoscope insertion, which may interfere with the endoscopic procedure<sup>[4]</sup>. If airway topical anesthesia or other drugs are not combined, upper GI endoscope insertion under moderate sedation with propofol can induce significant airway reflexes and increase the occurrence of adverse events<sup>[25]</sup>.

The WNJT is a new supraglottic airway device that can be used for supraglottic jet oxygenation and ventilation (SJOV), as shown in other studies<sup>[15,16]</sup>. Furthermore, Qin *et al*<sup>[15]</sup> found that compared to supplemental oxygen using the WNJT, SJOV with the WNJT decreased the occurrence of hypoxemia and adverse events during gastroscopy with propofol mono-sedation when an oxygen flow of 2 L/min was provided. However, SJOV with the WNJT was not applied in our study due to the following factors: (1) Gastroscopy is commonly a short procedure with a duration of less than 5 min in our center; (2) The need for a manual jet ventilator for SJOV increases the complexity of supplemental oxygen; (3) SJOV may result in complications, such as barotrauma, gastric distension, and xerostomia; and (4) Propofol mono-sedation used in our study has been shown to produce reduced respiratory suppression during GI endoscopy compared to sedation schemes combining propofol with other anesthetics<sup>[26]</sup>. Actually, the incidence of hypoxemia during gastroscopy was 3% when SJOV with the WNJT was used in the study by Qin *et al*<sup>[15]</sup>, while the incidence of hypoxemia during gastroscopy was only 1.4% in the WNJT group without SJOV in our study. These results indicate that with a moderate oxygen flow of 5 L/min, the use of the WNJT alone as a nasopharyngeal airway for supplemental oxygen effectively decreases the occurrence of hypoxemia during gastroscopy with propofol mono-sedation, and SJOV is not necessary.

Our results demonstrated that the use of airway opening maneuvers and facemask ventilation to correct hypoxemia was less common in the WNJT group compared to the nasal cannula group. This further supports the effectiveness of WNJT in preventing hypoxemia during gastroscopy with propofol mono-sedation. To determine the risk-benefit ratio of the studied devices, however, adverse effects should always be considered in a clinical trial. Thus, our study compared the complications of two tested devices to enable clinicians to fully consider the study results. Our results showed that adverse events were not significantly different between the groups, but the WNJT occasionally resulted in the occurrence of epistaxis. It has been reported that the incidence of epistaxis caused by inserting the convenient nasopharyngeal airway is approximately 5%-12.5%<sup>[27-29]</sup>. In contrast, the incidence of epistaxis by the WNJT insertion was only 0.7%-2% in the study by Qin *et al*<sup>[15]</sup> and 4.9% in our study. The low incidence of epistaxis with the WNJT may be due to its soft material texture. However, the incidence of epistaxis with the WNJT was significantly higher in our study than in the Qin *et al*'s<sup>[15]</sup> study. As the details of the assessment criteria for epistaxis in their study are not provided, the exact reason for these different findings is unclear. In our experience, after placement of the WNJT, bleeding due to nasal mucosa injury in some patients was noted by gastroscopy, as shown in **Figure 3**, but no visible epistaxis



**Figure 3** Epistaxis observed by gastroscopy in patients with Wei nasal jet tube placement.

occurred. Thus, we infer that epistaxis defined by gastroscopy may be one of the important reasons for the higher incidence of epistaxis with the WNJT in our study. Moreover, we recommend that when epistaxis is used as an outcome variable in airway studies, the use of endoscopy or laryngoscopy to define the occurrence of nasal mucosa injury may be a more reliable assessment method than visible observation of epistaxis.

Although all nasal bleeding due to the WNJT insertion in our study stopped naturally without any treatment and none of the patients with epistaxis complained of sore throat 30 min after the procedure, care should still be taken to avoid violent insertion of the WNJT. Due to possible stenosis of the nasal cavity, insertion failure of the WNJT occurred in 3 (2.1%) of our patients. The incidence of failed WNJT insertion in our study was similar to findings using a convenient nasopharyngeal airway in the study by Gasparović *et al*<sup>[21]</sup>.

In our study, both the procedure time and total propofol dosage were significantly decreased in the nasal cannula group compared to the WNJT group. This may be because the insertion of the WNJT requires additional time and can produce stronger stimuli to the nasal passage and the upper airway. Despite all this, the total incidence of hypoxemia and severe hypoxemia was still significantly decreased in the WNJT group. This may primarily be attributed to the upper airway opening and periglottic oxygen delivery by the WNJT. Moreover, the difference in median propofol dosages between groups was only 20 mg. For most adult patients, this small difference in median propofol dosages would not be clinically significant.

Our study also showed that satisfactions of physicians, anesthetists, and patients were not significantly different between groups. These findings may be due to the following factors. (1) The occurrence of adverse events and the use of interventions during GI endoscopy with sedation are the primary determinants for the satisfaction of anesthetists<sup>[30]</sup>. Other than a higher incidence of hypoxemia and increased use of convenient airway maneuvers during gastroscopy in the nasal cannula group, the incidences of other adverse events were very low in the two groups and were not significantly different between groups. When hypoxemia occurred during gastroscopy with propofol mono-sedation, the six-step intervention mentioned above was performed in our study. By increasing oxygen flow and opening the upper airway with a jaw-lift maneuver in most patients with hypoxemia, SpO<sub>2</sub> rapidly increased. In addition, the use of a six-step intervention to correct hypoxemia is easy to perform. These may explain why the two methods are comparable with respect to the satisfaction of anesthetists. (2) The use of the WNJT was an invasive procedure, but it was inserted after adequate sedation and removed before full recovery of sedation. Furthermore, epistaxis was only noted by gastroscopy in a few patients using the WNJT, with no visible epistaxis after the procedure noted by patients, and the incidence of postoperative sore throat was the same between the two groups. These factors might be attributed to the same satisfaction of patients in the two groups. And (3) Multiple attempts at gastroscopy insertion by significant body movement and interruption of endoscopy by urgent airway management were the main reasons for the dissatisfaction of physicians<sup>[30,31]</sup>. As an initial deep sedation was routinely used in our practice, all body movements observed in this study were slight and did not affect the gastroscopy insertion procedure. Furthermore, the incidence of body movement



was not significantly different between groups. In addition, only 4 patients in the nasal cannula group required an interruption of the gastroscopic procedure for facemask ventilation to correct hypoxemia. Differences in satisfaction of physicians due to this low-incidence event should be further determined.

The main strength of this study is the inclusion of a large sample with consistent GI endoscopic procedures and the use of a prospective randomized controlled design. However, there are still some limitations in our study design that deserve special attention. First, the insertion of the WNJT after sedation and removal of the WNJT before full recovery of sedation blinds patients to the group assignment, but the investigators were not blinded to the studied devices. Thus, this study is only a single-blinded trial and may result in biases in outcome assessment, affecting the power of the results. Second, the duration of gastroscopy in our study was relatively short at approximately 5 min. Therefore, our results should not be extrapolated to other settings with a long duration of endoscopic procedures, such as endoscopic retrograde cholangiopancreatography. Third, the subjects of this study were healthy adults aged 18–65 years with a normal BMI. Thus, our findings are not applicable for older patients and those with an abnormal BMI, as these patients often have comorbidities, increased sensitivity to sedatives and anesthetics, and limited physiological reserves<sup>[13,32]</sup>. Further clinical trials are needed to address the above issues.

## CONCLUSION

In summary, for patients with a normal BMI, compared to nasal prongs used for supplemental oxygen, the WNJT is more effective for the prevention of hypoxemia during gastroscopy with propofol mono-sedation when a moderate oxygen flow of 5 L/min is provided. However, the WNJT results in slight epistaxis in a few patients. When making a decision about the choice of supplemental oxygen methods for gastroscopy with propofol mono-sedation in patients with a normal BMI, the risk-benefit ratio of using the WNJT should also be considered.

## ARTICLE HIGHLIGHTS

### Research background

Hypoxemia by respiratory depression and airway obstruction during upper gastrointestinal endoscopy with sedation is a common concern. The nasal cannula is one of most convenient tools for supplemental oxygen, but it cannot overcome upper airway obstruction. Compared to the nasal prongs, the convenient nasopharyngeal airway provides improved efficiency of supplemental oxygen delivery during upper gastrointestinal endoscopy with sedation, but the insertion of the nasopharyngeal airway is an invasive procedure with a potential risk of airway injury.

### Research motivation

In view of the significant limitations of available supplemental oxygen methods, it is necessary to identify new effective measures for supplemental oxygen during upper gastrointestinal endoscopy with sedation. The Wei nasal jet tube (WNJT) is a new design of special nasopharyngeal airway made of soft material. The available evidence indicates that with a low oxygen flow, compared to nasal cannula, the WNJT does not decrease the occurrence of hypoxemia during upper gastrointestinal endoscopy with propofol sedation. Given that increasing oxygen flow improves the efficacy of supplemental oxygen in the upper airway, we designed this study to compare the efficacy and safety of WNJT and nasal prongs for supplemental oxygen delivery during gastroscopy with sedation in patients with a normal body mass index when a moderate oxygen flow was provided.

### Research objectives

In this study, we aimed to determine whether the WNJT performs better than the nasal prongs for the prevention of hypoxemia during gastroscopy with propofol mono-sedation when a moderate oxygen flow is provided.

### Research methods

To address whether the WNJT performs better than the nasal prongs for the

prevention of hypoxemia during gastroscopy with propofol mono-sedation when a moderate oxygen flow is provided, we designed this study as a prospective randomized controlled trial in which patients undergoing elective gastroscopy with propofol mono-sedation were randomized into one of two groups to receive either the WNJT or the nasal cannula supplemental oxygen with a 5-L/min flow. The primary endpoint was the incidences of hypoxemia or severe hypoxemia during gastroscopy.

### Research results

A total of 291 subjects were randomized into two groups, but a total of only 144 patients were used for data analysis because 3 patients in the WNJT group were excluded. The total incidence of hypoxemia and severe hypoxemia during gastroscopy was significantly lower in the WNJT group than in the nasal cannula group. In the WNJT group, however, epistaxis by device insertion occurred in 7 patients.

### Research conclusions

With a moderate oxygen flow of 5 L/min, compared to nasal prongs, the WNJT is more effective for the prevention of hypoxemia during gastroscopy with propofol mono-sedation, but resulted in slight epistaxis in a few patients.

### Research perspectives

With a moderate oxygen flow of 5 L/min, the WNJT performs better than the nasal prongs for the prevention of hypoxemia during gastroscopy with propofol mono-sedation in patients with a normal body mass index. Thus, the WNJT may represent a useful tool for supplemental oxygen during gastroscopy with propofol mono-sedation. Because the WNJT insertion results in a risk of slight epistaxis in a few patients, the risk-benefit ratio of using the WNJT should be considered.

## ACKNOWLEDGEMENTS

We thank Dr. Na Zeng from the Department of Methodology Platform, Institute of Clinical Medicine, Beijing Friendship Hospital, for her help with the statistical analysis of the data.

## REFERENCES

- 1 **Ross R**, Newton JL. Heart Rate and Blood Pressure Changes during Gastroscopy in Healthy Older Subjects. *Gerontology* 2004; **50**: 182-186 [PMID: [15114041](#) DOI: [10.1159/000076778](#)]
- 2 **Crew KD**, Neugut AI. Epidemiology of gastric cancer. *World J Gastroenterol* 2006; **12**: 354-362 [PMID: [16489633](#) DOI: [10.3748/wjg.v12.i3.354](#)]
- 3 **Meining A**, Semmler V, Kassem AM, Sander R, Frankenberger U, Burzin M, Reichenberger J, Bajbouj M, Prinz C, Schmid RM. The effect of sedation on the quality of upper gastrointestinal endoscopy: an investigator-blinded, randomized study comparing propofol with midazolam. *Endoscopy* 2007; **39**: 345-349 [PMID: [17285514](#) DOI: [10.1055/s-2006-945195](#)]
- 4 **Rex DK**. Review article: moderate sedation for endoscopy: sedation regimens for non-anaesthesiologists. *Aliment Pharmacol Ther* 2006; **24**: 163-171 [PMID: [16842446](#) DOI: [10.1111/j.1365-2036.2006.02986.x](#)]
- 5 **Dumonceau JM**, Riphaut A, Aparicio JR, Beilenhoff U, Knape JT, Ortmann M, Paspatis G, Ponsioen CY, Racz I, Schreiber F, Vilman P, Wehrmann T, Wientjes C, Walder B; NAAP Task Force Members. European Society of Gastrointestinal Endoscopy, European Society of Gastroenterology and Endoscopy Nurses and Associates, and the European Society of Anaesthesiology Guideline: Non-anesthesiologist administration of propofol for GI endoscopy. *Endoscopy* 2010; **42**: 960-974 [PMID: [21072716](#) DOI: [10.1055/s-0030-1255728](#)]
- 6 **Cohen LB**, Wechsler JS, Gaetano JN, Benson AA, Miller KM, Durkalski V, Aisenberg J. Endoscopic sedation in the United States: results from a nationwide survey. *Am J Gastroenterol* 2006; **101**: 967-974 [PMID: [16573781](#) DOI: [10.1111/j.1572-0241.2006.00500.x](#)]
- 7 **Riphaut A**, Wehrmann T, Hausmann J, Weber B, von Delius S, Jung M, Tonner P, Arnold J, Behrens A, Beilenhoff U, Bitter H, Domagk D, In der Smitten S, Kallinowski B, Meining A, Schaible A, Schilling D, Seifert H, Wappler F, Kopp I. Update S3-guideline: "sedation for gastrointestinal endoscopy" 2014 (AWMF-register-no. 021/014). *Z Gastroenterol* 2016; **54**: 58-95 [PMID: [26751118](#) DOI: [10.1055/s-0041-109680](#)]
- 8 **Vargo JJ**, Cohen LB, Rex DK, Kwo PY. Position statement: Nonanesthesiologist administration of propofol for GI endoscopy. *Hepatology* 2009; **50**: 1683-1689 [PMID: [19937691](#) DOI: [10.1002/hep.23326](#)]
- 9 **Reshef R**, Shiller M, Kinberg R, Rennert H, Rennert G, Herskovits M, Loberant N. A prospective study evaluating the usefulness of continuous supplemental oxygen in various endoscopic procedures. *Isr J Med Sci* 1996; **32**: 736-740 [PMID: [8865828](#)]
- 10 **Beitz A**, Riphaut A, Meining A, Kronshage T, Geist C, Wagenpfeil S, Weber A, Jung A, Bajbouj M, Pox C, Schneider G, Schmid RM, Wehrmann T, von Delius S. Capnographic monitoring reduces the incidence of

- arterial oxygen desaturation and hypoxemia during propofol sedation for colonoscopy: a randomized, controlled study (ColoCap Study). *Am J Gastroenterol* 2012; **107**: 1205-1212 [PMID: [22641306](#) DOI: [10.1038/ajg.2012.136](#)]
- 11 **Siampalioti A**, Karavias D, Zotou A, Kalfarentzos F, Filos K. Anesthesia management for the super obese: is sevoflurane superior to propofol as a sole anesthetic agent? *Eur Rev Med Pharmacol Sci* 2015; **19**: 2493-2500 [PMID: [26214787](#)]
  - 12 **Kumar AR**, Guilleminault C, Certal V, Li D, Capasso R, Camacho M. Nasopharyngeal airway stenting devices for obstructive sleep apnoea: a systematic review and meta-analysis. *J Laryngol Otol* 2015; **129**: 2-10 [PMID: [25544266](#) DOI: [10.1017/S0022215114003119](#)]
  - 13 **Xiao Q**, Yang Y, Zhou Y, Guo Y, Ao X, Han R, Hu J, Chen D, Lan C. Comparison of Nasopharyngeal Airway Device and Nasal Oxygen Tube in Obese Patients Undergoing Intravenous Anesthesia for Gastroscopy: A Prospective and Randomized Study. *Gastroenterol Res Pract* 2016; **2016**: 2641257 [PMID: [26997951](#) DOI: [10.1155/2016/2641257](#)]
  - 14 **Cavusoglu T**, Yazici I, Demirtas Y, Gunaydin B, Yavuzer R. A rare complication of nasotracheal intubation: accidental middle turbinectomy. *J Craniofac Surg* 2009; **20**: 566-568 [PMID: [19305259](#) DOI: [10.1097/SCS.0b013e31819ba378](#)]
  - 15 **Qin Y**, Li LZ, Zhang XQ, Wei Y, Wang YL, Wei HF, Wang XR, Yu WF, Su DS. Supraglottic jet oxygenation and ventilation enhances oxygenation during upper gastrointestinal endoscopy in patients sedated with propofol: a randomized multicentre clinical trial. *Br J Anaesth* 2017; **119**: 158-166 [PMID: [28974061](#) DOI: [10.1093/bja/aex091](#)]
  - 16 **Wu C**, Wei J, Cen Q, Sha X, Cai Q, Ma W, Cao Y. Supraglottic jet oxygenation and ventilation-assisted fibre-optic bronchoscope intubation in patients with difficult airways. *Intern Emerg Med* 2017; **12**: 667-673 [PMID: [27637970](#) DOI: [10.1007/s11739-016-1531-6](#)]
  - 17 **Orhan-Sungur M**, Komatsu R, Sherman A, Jones L, Walsh D, Sessler DI. Effect of nasal cannula oxygen administration on oxygen concentration at facial and adjacent landmarks. *Anaesthesia* 2009; **64**: 521-526 [PMID: [19413822](#) DOI: [10.1111/j.1365-2044.2008.05820.x](#)]
  - 18 **Chernik DA**, Gillings D, Laine H, Hendler J, Silver JM, Davidson AB, Schwam EM, Siegel JL. Validity and reliability of the Observer's Assessment of Alertness/Sedation Scale: study with intravenous midazolam. *J Clin Psychopharmacol* 1990; **10**: 244-251 [PMID: [2286697](#)]
  - 19 **Vadhanan P**, Tripathy DK. Effect of Bougie-Guided Nasal Intubations upon Bleeding: A Randomised Controlled Trial. *Turk J Anaesthesiol Reanim* 2018; **46**: 96-99 [PMID: [29744243](#) DOI: [10.5152/TJAR.2017.51333](#)]
  - 20 **Ibáñez M**, Parra-Blanco A, Zaballa P, Jiménez A, Fernández-Velázquez R, Fernández-Sordo JO, González-Bernardo O, Rodrigo L. Usefulness of an intensive bowel cleansing strategy for repeat colonoscopy after preparation failure. *Dis Colon Rectum* 2011; **54**: 1578-1584 [PMID: [22067188](#) DOI: [10.1097/DCR.0b013e31823434c8](#)]
  - 21 **Gasparović S**, Rustemović N, Opacić M, Premuzić M, Korusić A, Božikov J, Bates T. Clinical analysis of propofol deep sedation for 1,104 patients undergoing gastrointestinal endoscopic procedures: a three year prospective study. *World J Gastroenterol* 2006; **12**: 327-330 [PMID: [16482639](#) DOI: [10.3748/wjg.v12.i2.327](#)]
  - 22 **Behrens A**, Kreuzmayr A, Manner H, Koop H, Lorenz A, Schaefer C, Plauth M, Jetschmann JU, von Tirpitz C, Ewald M, Sackmann M, Renner W, Krüger M, Schwab D, Hoffmann W, Engcke O, Pech O, Kullmann F, Pampuch S, Lenfers B, Weickert U, Schilling D, Boehm S, Beckebaum S, Cicinnati V, Erckenbrecht JF, Dumoulin FL, Benz C, Rabenstein T, Haltern G, Balsliemke M, de Mas C, Kleber G, Pehl C, Vogt C, Kiesslich R, Fischbach W, Koop I, Kuehne J, Breidert M, Sass NL, May A, Friedrich C, Veitt R, Porschen R, Ellrichmann M, Arlt A, Schmitt W, Dollhopf M, Schmidbaur W, Dignass A, Schmitz V, Labenz J, Kaiser G, Krannich A, Barteska N, Ell C. Acute sedation-associated complications in GI endoscopy (ProSed 2 Study): results from the prospective multicentre electronic registry of sedation-associated complications. *Gut* 2019; **68**: 445-452 [PMID: [29298872](#) DOI: [10.1136/gutjnl-2015-311037](#)]
  - 23 **Jense HG**, Dubin SA, Silverstein PI, O'Leary-Escolas U. Effect of obesity on safe duration of apnea in anesthetized humans. *Anesth Analg* 1991; **72**: 89-93 [PMID: [1984382](#) DOI: [10.1213/00000539-199101000-00016](#)]
  - 24 **Soro Domingo M**, Belda Nacher FJ, Aguilar Aguilar G, Ferrandis Comes R, García-Raimundo M, Martínez Pons V. [Preoxygenation for anesthesia]. *Rev Esp Anesthesiol Reanim* 2004; **51**: 322-327 [PMID: [15303533](#)]
  - 25 **Heuss LT**, Hanhart A, Dell-Kuster S, Zdrnja K, Ortmann M, Beglinger C, Bucher HC, Degen L. Propofol sedation alone or in combination with pharyngeal lidocaine anesthesia for routine upper GI endoscopy: a randomized, double-blind, placebo-controlled, non-inferiority trial. *Gastrointest Endosc* 2011; **74**: 1207-1214 [PMID: [22000794](#) DOI: [10.1016/j.gie.2011.07.072](#)]
  - 26 **Chan WH**, Chang SL, Lin CS, Chen MJ, Fan SZ. Target-controlled infusion of propofol vs intermittent bolus of a sedative cocktail regimen in deep sedation for gastrointestinal endoscopy: comparison of cardiovascular and respiratory parameters. *J Dig Dis* 2014; **15**: 18-26 [PMID: [24106806](#) DOI: [10.1111/1751-2980.12101](#)]
  - 27 **Stoneham MD**. The nasopharyngeal airway. Assessment of position by fiberoptic laryngoscopy. *Anaesthesia* 1993; **48**: 575-580 [PMID: [8346770](#) DOI: [10.1111/j.1365-2044.1993.tb07119.x](#)]
  - 28 **Gallagher WJ**, Pearce AC, Power SJ. Assessment of a new nasopharyngeal airway. *Br J Anaesth* 1988; **60**: 112-115 [PMID: [3337783](#) DOI: [10.1093/bja/60.1.112](#)]
  - 29 **Feldman SA**, Fauvel NJ, Ooi R. The cuffed pharyngeal airway. *Eur J Anaesthesiol* 1991; **8**: 291-295 [PMID: [1874227](#)]
  - 30 **Zhang H**, Liu CM. Target-controlled intravenous analgesia with remifentanyl on hypoxemia in obese patients with painless gastroscopy (Chinese). *Yixue Yanjiu Zazhi* 2017; **4**: 154-156 [DOI: [10.11969/j.issn.1673-548X.2017.04.039](#)]
  - 31 **Nonaka T**, Inamori M, Miyashita T, Inoh Y, Kanoshima K, Higurashi T, Ohkubo H, Iida H, Fujita K, Kusakabe A, Gotoh T, Nakajima A. Can sedation using a combination of propofol and dexmedetomidine enhance the satisfaction of the endoscopist in endoscopic submucosal dissection? *Endosc Int Open* 2018; **6**:

E3-E10 [PMID: 29340293 DOI: 10.1055/s-0043-122228]

- 32 **Homfray G**, Palmer A, Grimsmo-Powney H, Appelboam A, Lloyd G. Procedural sedation of elderly patients by emergency physicians: a safety analysis of 740 patients. *Br J Anaesth* 2018; **121**: 1236-1241 [PMID: 30442250 DOI: 10.1016/j.bja.2018.07.038]



Published by **Baishideng Publishing Group Inc**  
7041 Koll Center Parkway, Suite 160, Pleasanton, CA 94566, USA

**Telephone:** +1-925-3991568

**E-mail:** [bpgoffice@wjgnet.com](mailto:bpgoffice@wjgnet.com)

**Help Desk:** <https://www.f6publishing.com/helpdesk>

<https://www.wjgnet.com>

