

# World Journal of *Gastroenterology*

*World J Gastroenterol* 2020 December 7; 26(45): 7088-7271



### **GUIDELINES**

- 7088** Chinese guidelines on the management of liver cirrhosis (abbreviated version)  
*Xu XY, Ding HG, Li WG, Xu JH, Han Y, Jia JD, Wei L, Duan ZP, Ling-Hu EQ, Zhuang H*

### **MINIREVIEWS**

- 7104** Role of pancreatography in the endoscopic management of encapsulated pancreatic collections – review and new proposed classification  
*Proença IM, dos Santos MEL, de Moura DTH, Ribeiro IB, Matuguma SE, Cheng S, McCarty TR, do Monte Junior ES, Sakai P, de Moura EGH*

### **ORIGINAL ARTICLE**

#### **Basic Study**

- 7118** Discovery of unique African *Helicobacter pylori* CagA-multimerization motif in the Dominican Republic  
*Ono T, Cruz M, Nagashima H, Subsomwong P, Akada J, Matsumoto T, Uchida T, Suzuki R, Hosking C, Jiménez Abreu JA, Yamaoka Y*
- 7131** Nimbolide inhibits tumor growth by restoring hepatic tight junction protein expression and reduced inflammation in an experimental hepatocarcinogenesis  
*Ram AK, Vairappan B, Srinivas BH*

#### **Case Control Study**

- 7153** Altered metabolism of bile acids correlates with clinical parameters and the gut microbiota in patients with diarrhea-predominant irritable bowel syndrome  
*Wei W, Wang HF, Zhang Y, Zhang YL, Niu BY, Yao SK*
- 7173** Alteration of fecal tryptophan metabolism correlates with shifted microbiota and may be involved in pathogenesis of colorectal cancer  
*Sun XZ, Zhao DY, Zhou YC, Wang QQ, Qin G, Yao SK*

#### **Retrospective Cohort Study**

- 7191** High mortality associated with gram-negative bacterial bloodstream infection in liver transplant recipients undergoing immunosuppression reduction  
*Chen F, Pang XY, Shen C, Han LZ, Deng YX, Chen XS, Zhang JJ, Xia Q, Qian YB*

#### **Retrospective Study**

- 7204** Liver fibrosis index-based nomograms for identifying esophageal varices in patients with chronic hepatitis B related cirrhosis  
*Xu SH, Wu F, Guo LH, Zhang WB, Xu HX*

**Clinical Trials Study**

- 7222 Relationship between the incidence of non-hepatic hyperammonemia and the prognosis of patients in the intensive care unit

*Yao ZP, Li Y, Liu Y, Wang HL*

**Observational Study**

- 7232 Association between ADAMTS13 activity-VWF antigen imbalance and the therapeutic effect of HAIC in patients with hepatocellular carcinoma

*Takaya H, Namisaki T, Moriya K, Shimozato N, Kaji K, Ogawa H, Ishida K, Tsuji Y, Kaya D, Takagi H, Fujinaga Y, Nishimura N, Sawada Y, Kawaratani H, Akahane T, Matsumoto M, Yoshiji H*

**SYSTEMATIC REVIEWS**

- 7242 Diagnosis and treatment of iron-deficiency anemia in gastrointestinal bleeding: A systematic review

*Cotter J, Baldaia C, Ferreira M, Macedo G, Pedroto I*

**CASE REPORT**

- 7258 Endoscopic mucosal ablation - an alternative treatment for colonic polyps: Three case reports

*Mendoza Ladd A, Espinoza J, Garcia C*

- 7263 Tuberous sclerosis patient with neuroendocrine carcinoma of the esophagogastric junction: A case report

*Ishida N, Miyazu T, Tamura S, Suzuki S, Tani S, Yamade M, Iwaizumi M, Osawa S, Hamaya Y, Shinmura K, Sugimura H, Miura K, Furuta T, Sugimoto K*

**ABOUT COVER**

Editorial Board Member of *World Journal of Gastroenterology*, Professor Udo Rolle is a Distinguished Professor at the University Hospital of the Goethe-University in Frankfurt, Germany. Having received his doctoral degree from the University of Leipzig in 1994, Prof. Rolle undertook his postgraduate training, first at the University of Leipzig (Germany) and then at the University Hospital Dublin (Ireland), receiving his habilitation in 2003. He rose to Full Professor and Chief Surgeon in the Department of Paediatric Surgery and Paediatric Urology at the University Hospital Frankfurt in 2008. His ongoing research interests involve neonatal GI surgery, pediatric GI motility disorders with long-term follow-up in various congenital anomalies. Currently, he serves as President of the German Association of Paediatric Surgery, General Secretary of the World Federation of Associations of Paediatric Surgery, and General Secretary of the UEMS section of Paediatric Surgery. (L-Editor: Filipodia)

**AIMS AND SCOPE**

The primary aim of *World Journal of Gastroenterology* (WJG, *World J Gastroenterol*) is to provide scholars and readers from various fields of gastroenterology and hepatology with a platform to publish high-quality basic and clinical research articles and communicate their research findings online. WJG mainly publishes articles reporting research results and findings obtained in the field of gastroenterology and hepatology and covering a wide range of topics including gastroenterology, hepatology, gastrointestinal endoscopy, gastrointestinal surgery, gastrointestinal oncology, and pediatric gastroenterology.

**INDEXING/ABSTRACTING**

The WJG is now indexed in Current Contents®/Clinical Medicine, Science Citation Index Expanded (also known as SciSearch®), Journal Citation Reports®, Index Medicus, MEDLINE, PubMed, PubMed Central, and Scopus. The 2020 edition of Journal Citation Report® cites the 2019 impact factor (IF) for WJG as 3.665; IF without journal self cites: 3.534; 5-year IF: 4.048; Ranking: 35 among 88 journals in gastroenterology and hepatology; and Quartile category: Q2.

**RESPONSIBLE EDITORS FOR THIS ISSUE**

Production Editor: Yu-Jie Ma; Production Department Director: Xiang Li; Editorial Office Director: Ze-Mao Gong.

**NAME OF JOURNAL**

*World Journal of Gastroenterology*

**ISSN**

ISSN 1007-9327 (print) ISSN 2219-2840 (online)

**LAUNCH DATE**

October 1, 1995

**FREQUENCY**

Weekly

**EDITORS-IN-CHIEF**

Andrzej S Tarnawski, Subrata Ghosh

**EDITORIAL BOARD MEMBERS**

<http://www.wjgnet.com/1007-9327/editorialboard.htm>

**PUBLICATION DATE**

December 7, 2020

**COPYRIGHT**

© 2020 Baishideng Publishing Group Inc

**INSTRUCTIONS TO AUTHORS**

<https://www.wjgnet.com/bpg/gerinfo/204>

**GUIDELINES FOR ETHICS DOCUMENTS**

<https://www.wjgnet.com/bpg/GerInfo/287>

**GUIDELINES FOR NON-NATIVE SPEAKERS OF ENGLISH**

<https://www.wjgnet.com/bpg/gerinfo/240>

**PUBLICATION ETHICS**

<https://www.wjgnet.com/bpg/GerInfo/288>

**PUBLICATION MISCONDUCT**

<https://www.wjgnet.com/bpg/gerinfo/208>

**ARTICLE PROCESSING CHARGE**

<https://www.wjgnet.com/bpg/gerinfo/242>

**STEPS FOR SUBMITTING MANUSCRIPTS**

<https://www.wjgnet.com/bpg/GerInfo/239>

**ONLINE SUBMISSION**

<https://www.f6publishing.com>



## Endoscopic mucosal ablation - an alternative treatment for colonic polyps: Three case reports

Antonio Mendoza Ladd, Joaquin Espinoza, Cesar Garcia

**ORCID number:** Antonio Mendoza Ladd [0000-0002-8013-3545](https://orcid.org/0000-0002-8013-3545); Joaquin Espinoza [0000-0002-2256-729X](https://orcid.org/0000-0002-2256-729X); Cesar Garcia [0000-0001-9510-589X](https://orcid.org/0000-0001-9510-589X).

**Author contributions:** Mendoza Ladd A performed all the procedures, edited the video, drafted, edited and approved the final manuscript; Espinoza J and Garcia C drafted, edited and approved the final manuscript.

**Informed consent statement:** The study was considered exempt from needing to obtain informed consent. The IRB acknowledges that this project meets the criteria for exemption from formal IRB review in accordance with 45 CFR46.104 (d)(4)(iii). A Waiver of HIPAA Authorization for Research approved under 45 CFR164.512 (i)(2)(ii).

**Conflict-of-interest statement:** Antonio Mendoza Ladd has received fees for serving as a consultant for CONMED; Joaquin Espinoza and Cesar Garcia no conflicts of interest to disclose.

**CARE Checklist (2016) statement:** The authors have read the CARE Checklist (2016), and the manuscript was prepared and revised according to the CARE Checklist (2016).

**Open-Access:** This article is an

**Antonio Mendoza Ladd**, Department of Internal Medicine, Division of Gastroenterology, Texas Tech University Health Sciences Center, Paul L Foster School of Medicine, El Paso, TX 79905, United States

**Joaquin Espinoza**, Escuela de Medicina Luis Razetti, Universidad Central de Venezuela, Caracas 999188, Venezuela

**Cesar Garcia**, Department of Endoscopy, University Medical Center of El Paso, El Paso, TX 79905, United States

**Corresponding author:** Antonio Mendoza Ladd, FACP, FASGE, Assistant Professor, Department of Internal Medicine, Division of Gastroenterology, Texas Tech University Health Sciences Center, Paul L Foster School of Medicine, 4800 Alberta Avenue, El Paso, TX 79905, United States. [dr\\_ladd25@yahoo.com](mailto:dr_ladd25@yahoo.com)

### Abstract

#### BACKGROUND

Endoscopic resection of non-invasive lesions is now the standard of care for lesions in the GI tract. However, resection techniques require extensive training, are not available in all endoscopy centers and are prone to complications. Endoscopic mucosal ablation (EMA) is a combination of resection and ablation techniques and it may offer an alternative in the management of such lesions.

#### CASE SUMMARY

In this case series we report the successful treatment of three flat colonic polyps using the EMA technique. Two lesions were treatment naïve and 1 was a recurrence after an endoscopic mucosal resection. The sizes ranged from 2 to 4 cm. All three polyps were ablated successfully with no immediate or delayed complications. The recurrence rate at 1 year of follow up was 0%.

#### CONCLUSION

Based on this initial experience, we conclude that EMA is a safe and effective technique for the treatment of non-invasive colonic polyps when endoscopic resection techniques are not available.

**Key Words:** Endoscopy; Mucosal ablation; Colon polyp; Argon plasma coagulation; Alternative; Safe; Case report



open-access article that was selected by an in-house editor and fully peer-reviewed by external reviewers. It is distributed in accordance with the Creative Commons Attribution NonCommercial (CC BY-NC 4.0) license, which permits others to distribute, remix, adapt, build upon this work non-commercially, and license their derivative works on different terms, provided the original work is properly cited and the use is non-commercial. See: <http://creativecommons.org/licenses/by-nc/4.0/>

**Manuscript source:** Unsolicited manuscript

**Specialty type:** Gastroenterology and hepatology

**Country/Territory of origin:** United States

**Peer-review report's scientific quality classification**

Grade A (Excellent): 0  
Grade B (Very good): B, B, B  
Grade C (Good): 0  
Grade D (Fair): 0  
Grade E (Poor): 0

**Received:** September 26, 2020

**Peer-review started:** September 26, 2020

**First decision:** November 8, 2020

**Revised:** November 9, 2020

**Accepted:** November 21, 2020

**Article in press:** November 21, 2020

**Published online:** December 7, 2020

**P-Reviewer:** Fu TL, Inal V, Protopapas A

**S-Editor:** Fan JR

**L-Editor:** A

**P-Editor:** Liu JH



©The Author(s) 2020. Published by Baishideng Publishing Group Inc. All rights reserved.

**Core Tip:** Endoscopic resection *via* endoscopic mucosal resection or endoscopic submucosal dissection is currently the standard of care for non-invasive colonic polyps. However, these resection techniques require extensive training, are not available in all endoscopy centers, and are prone to adverse events such as perforation and bleeding. Endoscopic mucosal ablation appears to be a safe and effective alternative in the treatment of colonic polyps without invasive features.

**Citation:** Mendoza Ladd A, Espinoza J, Garcia C. Endoscopic mucosal ablation - an alternative treatment for colonic polyps: Three case reports. *World J Gastroenterol* 2020; 26(45): 7258-7262

**URL:** <https://www.wjgnet.com/1007-9327/full/v26/i45/7258.htm>

**DOI:** <https://dx.doi.org/10.3748/wjg.v26.i45.7258>

## INTRODUCTION

Endoscopic mucosal resection (EMR) and/or endoscopic submucosal dissection (ESD) is now the standard of care for non-dysplastic, dysplastic and early malignant lesions of the gastrointestinal tract. The *sine qua non* of these techniques is the adequate formation of a submucosal cushion prior to resection, in order to avoid damage of the muscularis propria and hence, perforation. However, these resection techniques require rigorous training, are prone to complications and are not always available at all centers. Recently the submucosal cushion principle has been adopted in the management of dysplastic Barrett's esophagus (BE) prior to ablation with argon plasma in a technique called Hybrid APC<sup>[1]</sup>. We explored this concept in the management of 3 flat colonic polyps.

## CASE PRESENTATION

### Chief complaints

All patients presented in this case series had colon polyps requiring treatment.

### History of present illness

All three patients originally presented to their gastroenterology providers for routine colon cancer screening or surveillance and were referred to our endoscopy center.

### History of past illness

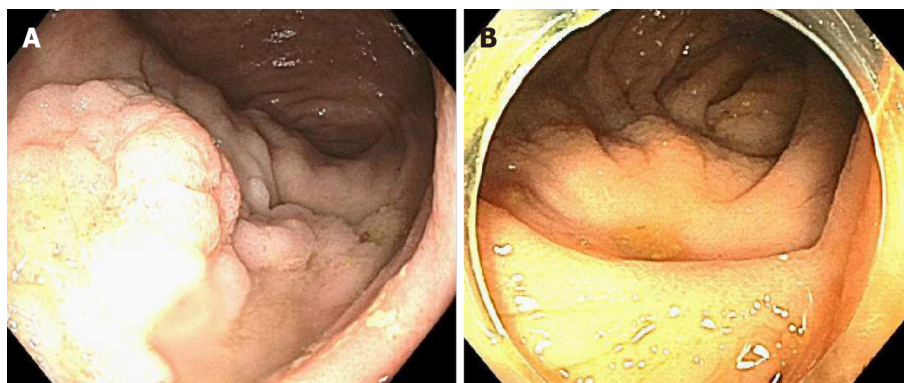
**Case 1:** Hypertension (HTN), DM2.

**Case 2:** DM2, HTN, hypercholesterolemia and treated tuberculosis.

**Case 3:** Hypercholesterolemia and osteoarthritis.

### Imaging examinations

**Case 1:** An 85 y/o M with previous medical history (PMH) described above was referred for evaluation of a cecal polyp. Colonoscopy revealed a 4 cm 0-IIa +Is lesion in the cecum that involved the IC valve (Figure 1A). Due to morphology of the lesion and the risk of incomplete resection *via* EMR (we did not perform ESD at our center at the time), removal was not attempted. The lesion was biopsied and pathological analysis established it was a tubular adenoma with no dysplasia. The patient was offered referral to an outside facility for ESD. However due to his lack of medical insurance, referral was not a possibility. Therefore, endoscopic mucosal ablation (EMA) was offered. After detailed explanation of the potential risks and benefits, he agreed to the procedure. The colonoscopy was repeated 2 mo later. The lesion was injected with a mix of O'rise gel<sup>TM</sup> (Boston Scientific, Natick, MA, United States) + epinephrine at 1:10000 to create the submucosal cushion. The lesion raised easily. Once raised, ablation of the lesion was performed using Argon Plasma Coagulation in forced



**Figure 1 Colonoscopy.** A: 0-IIa +Is lesion in the cecum involving the IC valve; B: Post endoscopic mucosal ablation scar.

coagulation mode at 1 L/min, 60 W, effect 2 (Video). The patient did well and was discharged the same day of the procedure. Colonoscopy 1 year later showed a scar with no evidence of polyp recurrence (Figure 1B). Biopsies of the scar confirmed eradication of the lesion.

**Case 2:** This was a 69 y/o M with PMH described above who was referred for removal of polyp recurrence after a previous EMR. Colonoscopy showed a 0-IIa lesion of approximately 3 cm at the previous EMR scar in the hepatic flexure (Figure 2A). The lesion was biopsied prior to ablation. After the biopsy, EMA was performed in a similar manner as in case 1 (video). The biopsy of the lesion revealed a tubular adenoma with no dysplasia. Colonoscopy at 11 mo showed a healthy scar with no signs of polyp recurrence (Figure 2B). Biopsy of the scar confirmed eradication.

**Case 3:** A 79 y/o F with a PMH described above was referred for evaluation of a flat polyp. Colonoscopy revealed a 2 cm 0-IIa lesion in the hepatic flexure (Figure 3A). The lesion was biopsied prior to ablation. Ablation ensued as described above (video). Biopsy of the lesion revealed tubular adenoma features with no dysplasia. Colonoscopy 13 mo later revealed a healthy scar with no polyp recurrence (Figure 3B). Biopsy of the scar confirmed eradication.

## FINAL DIAGNOSIS

All patients were diagnosed with TA with no dysplasia.

## TREATMENT

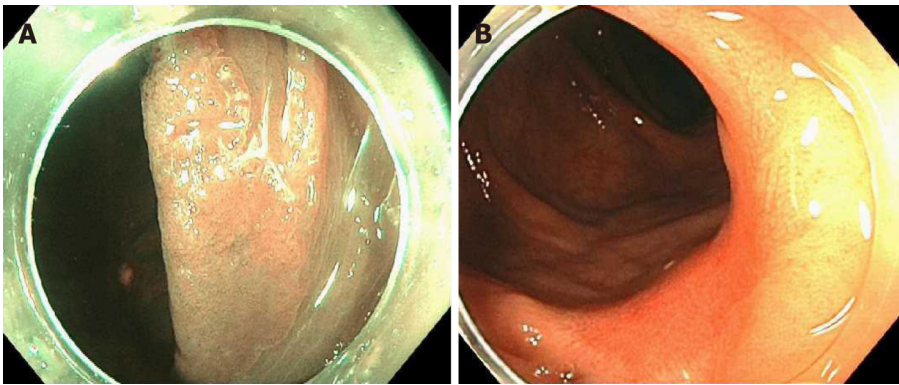
All patients were treated with the EMA technique.

## OUTCOME AND FOLLOW-UP

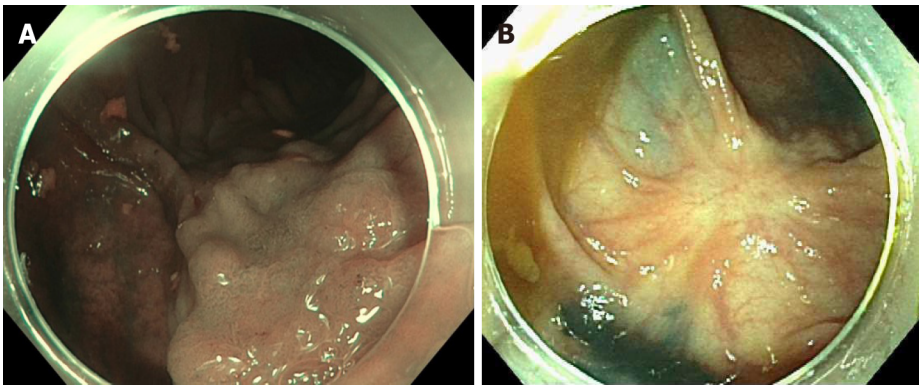
All patients had follow-up colonoscopy at 1 year and biopsy of the ablation site revealed no evidence of recurrence.

## DISCUSSION

EMA is a combination of established resection and ablation techniques already utilized in different sections of the GI tract. The EMA technique has been previously applied successfully in gastric lesions. Kothari *et al*<sup>[2]</sup> successfully treated a flat dysplastic lesion at the GJ anastomosis of a patient with a previous Roux-en-Y gastric bypass<sup>[2]</sup>. Estifan *et al*<sup>[3]</sup> also obtained adequate results using EMA to treat lesion recurrence after an ESD for intestinal metaplasia in the incisura<sup>[3]</sup>. The only available report of the application of this technique in the colon was published by Tsiamoulos *et al*<sup>[4]</sup>. In contrast to ours, this case series included only recurrent lesions after prior endoscopic resection. They



**Figure 2 Colonoscopy.** A: 0-IIa lesion in previous endoscopic mucosal resection site in hepatic flexure; B: Post endoscopic mucosal ablation scar.



**Figure 3 Colonoscopy.** A: 0-IIa lesion in the hepatic flexure; B: Post endoscopic mucosal ablation scar.

reported no complications and a recurrence rate of 82% at one year.

When utilizing EMA, a natural concern is the risk of complications such as perforation. However, studies in porcine models have demonstrated that ablation with argon plasma does not cause injury to the muscularis propria when a submucosal cushion is created<sup>[5,6]</sup>. This finding led to the novel technique of Hybrid APC. In this technique, a submucosal cushion is created and the affected mucosa is ablated. This technique has been applied in the treatment of BE and has shown promising results<sup>[1]</sup>.

The advantages of EMA include its simplicity, safety and its availability in most community endoscopy centers. The main disadvantage is that it does not produce a surgical specimen for pathological analysis. Although previous biopsy of the lesion can give preliminary information about the histology, it may not reflect that of the entire lesion. Therefore, endoscopists should only use EMA in colonic polyps when endoscopic resection *via* EMR or ESD is not available. Furthermore, this technique should not be utilized when the preparation of the colon is poor due to the risk of colonic explosion<sup>[7,8]</sup>.

## CONCLUSION

To our knowledge, this is the first report of the use of EMA in treatment naïve colonic lesions. We encountered no complications and our recurrence rate at 1 year was 0% with biopsies of the scars confirming eradication in all cases. Our results suggest that EMA is safe and effective in the treatment of colonic polyps when endoscopic resection is not possible or available.

## REFERENCES

- 1 Manner H, May A, Kouti I, Pech O, Vieth M, Ell C. Efficacy and safety of Hybrid-APC for the ablation of Barrett's esophagus. *Surg Endosc* 2016; **30**: 1364-1370 [PMID: 26104794 DOI: 10.1007/s00464-016-5000-0]



- 10.1007/s00464-015-4336-1]
- 2 **Kothari TH**, Kothari S, Kaul V. Hybrid argon plasma coagulation: a new modality for treatment of a diffuse foregut anastomotic dysplastic lesion. *VideoGIE* 2019; **4**: 209-210 [PMID: [31061940](#) DOI: [10.1016/j.vgie.2019.02.002](#)]
- 3 **Estifan E**, Cavanagh Y, Grossman MA. Hybrid Argon Plasma Coagulation for Treatment of Gastric Intestinal Metaplasia. *Cureus* 2020; **12**: e7427 [PMID: [32337147](#) DOI: [10.7759/cureus.7427](#)]
- 4 **Tsiamoulos ZP**, Bourikas LA, Saunders BP. Endoscopic mucosal ablation: a new argon plasma coagulation/injection technique to assist complete resection of recurrent, fibrotic colon polyps (with video). *Gastrointest Endosc* 2012; **75**: 400-404 [PMID: [22154411](#) DOI: [10.1016/j.gie.2011.09.003](#)]
- 5 **Fujishiro M**, Yahagi N, Nakamura M, Kakushima N, Kodashima S, Ono S, Kobayashi K, Hashimoto T, Yamamichi N, Tateishi A, Shimizu Y, Oka M, Ichinose M, Omata M. Submucosal injection of normal saline may prevent tissue damage from argon plasma coagulation: an experimental study using resected porcine esophagus, stomach, and colon. *Surg Laparosc Endosc Percutan Tech* 2006; **16**: 307-311 [PMID: [17057569](#) DOI: [10.1097/01.sle.0000213739.85277.3d](#)]
- 6 **Goulet CJ**, Disario JA, Emerson L, Hilden K, Holubkov R, Fang JC. In vivo evaluation of argon plasma coagulation in a porcine model. *Gastrointest Endosc* 2007; **65**: 457-462 [PMID: [17321247](#) DOI: [10.1016/j.gie.2006.09.005](#)]
- 7 **Manner H**, Plum N, Pech O, Ell C, Enderle MD. Colon explosion during argon plasma coagulation. *Gastrointest Endosc* 2008; **67**: 1123-1127 [PMID: [18513555](#) DOI: [10.1016/j.gie.2008.02.035](#)]
- 8 **Pichon N**, Maisonnète F, Cessot F, Sodji M, Sautereau D. Colonic perforations after gas explosion induced by argon plasma coagulation. *Endoscopy* 2004; **36**: 573 [PMID: [15202067](#) DOI: [10.1055/s-2004-814431](#)]



Published by **Baishideng Publishing Group Inc**  
7041 Koll Center Parkway, Suite 160, Pleasanton, CA 94566, USA

**Telephone:** +1-925-3991568

**E-mail:** [bpgoffice@wjgnet.com](mailto:bpgoffice@wjgnet.com)

**Help Desk:** <https://www.f6publishing.com/helpdesk>

<https://www.wjgnet.com>

