

# World Journal of *Gastroenterology*

*World J Gastroenterol* 2021 July 21; 27(27): 4252-4483



### REVIEW

- 4252** Update on the association of hepatitis B with intrahepatic cholangiocarcinoma: Is there new evidence?  
*Fragkou N, Sideras L, Panas P, Emmanouilides C, Sinakos E*
- 4276** Viral infections in inflammatory bowel disease: Tips and tricks for correct management  
*Craviotto V, Furfaro F, Loy L, Zilli A, Peyrin-Biroulet L, Fiorino G, Danese S, Allocca M*
- 4298** Pancreatic cancer: A review of epidemiology, trend, and risk factors  
*Hu JX, Zhao CF, Chen WB, Liu QC, Li QW, Lin YY, Gao F*
- 4322** Minimally invasive image-guided therapy of primary and metastatic pancreatic cancer  
*Bibok A, Kim DW, Malafa M, Kis B*
- 4342** Comprehensive review of diagnostic modalities for early chronic pancreatitis  
*Ge QC, Dietrich CF, Bhutani MS, Zhang BZ, Zhang Y, Wang YD, Zhang JJ, Wu YF, Sun SY, Guo JT*

### MINIREVIEWS

- 4358** Dysregulated liver function in SARS-CoV-2 infection: Current understanding and perspectives  
*Huang YK, Li YJ, Li B, Wang P, Wang QH*
- 4371** Impact of surgery for chronic pancreatitis on the risk of pancreatic cancer: Untying the Gordian knot  
*Kalayarasan R, Narayanan S, Sahoo J, Mohan P*
- 4383** Neoadjuvant therapy for pancreatic ductal adenocarcinoma: Opportunities for personalized cancer care  
*Hamad A, Brown ZJ, Ejaz AM, Dillhoff M, Cloyd JM*
- 4395** Role of artificial intelligence in multidisciplinary imaging diagnosis of gastrointestinal diseases  
*Berbis MA, Aneiros-Fernández J, Mendoza Olivares FJ, Nava E, Luna A*
- 4413** Hyperbaric oxygen therapy as a complementary treatment for radiation proctitis: Useless or useful? – A literature review  
*Alpuim Costa D, Amaro CE, Nunes A, Cardoso JS, Daniel PM, Rosa I, Branco JV*

### ORIGINAL ARTICLE

#### Retrospective Study

- 4429** Multifocal autoimmune pancreatitis: A retrospective study in a single tertiary center of 26 patients with a 20-year literature review  
*Huang XM, Shi ZS, Ma CL*

- 4441** Recent trends in the prevalence and distribution of colonic diverticula in Japan evaluated using computed tomography colonography

*Isohata N, Nagata K, Utano K, Nozaki R, Nozu S, Kato T, Kijima S, Matsumoto H, Majima K, Ryu Y, Hirayama M, Endo S*

**Observational Study**

- 4453** Prognostic role of plasma level of angiopoietin-1, angiopoietin-2, and vascular endothelial growth factor in hepatocellular carcinoma

*Choi GH, Jang ES, Kim JW, Jeong SH*

**Prospective Study**

- 4468** Determinants of disease-specific knowledge among children with inflammatory bowel disease and their parents: A multicentre study

*Kowalska-Duplaga K, Gawlik-Scislo A, Krzesiek E, Jarocka-Cyrta E, Łazowska-Przeorek I, Duplaga M, Banaszkiewicz A*

**LETTER TO THE EDITOR**

- 4481** Is there higher percentage of undetected osteopenia and osteoporosis among patients with ulcerative colitis in Saudi Arabia?

*Olic Akrapovic I, Radic M, Tonkic A*

**ABOUT COVER**

Editorial Board Member of *World Journal of Gastroenterology*, Jong-Inn Lee, PhD, MD, Member of Healthcare Review and Assessment Committee in Seoul, Institute of Healthcare Insurance Review and Assessment Service, Review and Assessment Division 3, 135, Jungdae-ro (IT Venturetower East Building 9th Floor), Songpa-gu, Seoul 05717, South Korea. jileesto@hira.or.kr

**AIMS AND SCOPE**

The primary aim of *World Journal of Gastroenterology* (WJG, *World J Gastroenterol*) is to provide scholars and readers from various fields of gastroenterology and hepatology with a platform to publish high-quality basic and clinical research articles and communicate their research findings online. WJG mainly publishes articles reporting research results and findings obtained in the field of gastroenterology and hepatology and covering a wide range of topics including gastroenterology, hepatology, gastrointestinal endoscopy, gastrointestinal surgery, gastrointestinal oncology, and pediatric gastroenterology.

**INDEXING/ABSTRACTING**

The WJG is now indexed in Current Contents®/Clinical Medicine, Science Citation Index Expanded (also known as SciSearch®), Journal Citation Reports®, Index Medicus, MEDLINE, PubMed, PubMed Central, and Scopus. The 2021 edition of Journal Citation Report® cites the 2020 impact factor (IF) for WJG as 5.742; Journal Citation Indicator: 0.79; IF without journal self cites: 5.590; 5-year IF: 5.044; Ranking: 28 among 92 journals in gastroenterology and hepatology; and Quartile category: Q2. The WJG's CiteScore for 2020 is 6.9 and Scopus CiteScore rank 2020: Gastroenterology is 19/136.

**RESPONSIBLE EDITORS FOR THIS ISSUE**

**Production Editor:** Yan-Xia Xing; **Production Department Director:** Xiang Li; **Editorial Office Director:** Ze-Mao Gong.

**NAME OF JOURNAL**

*World Journal of Gastroenterology*

**ISSN**

ISSN 1007-9327 (print) ISSN 2219-2840 (online)

**LAUNCH DATE**

October 1, 1995

**FREQUENCY**

Weekly

**EDITORS-IN-CHIEF**

Andrzej S Tarnawski, Subrata Ghosh

**EDITORIAL BOARD MEMBERS**

<http://www.wjgnet.com/1007-9327/editorialboard.htm>

**PUBLICATION DATE**

July 21, 2021

**COPYRIGHT**

© 2021 Baishideng Publishing Group Inc

**INSTRUCTIONS TO AUTHORS**

<https://www.wjgnet.com/bpg/gerinfo/204>

**GUIDELINES FOR ETHICS DOCUMENTS**

<https://www.wjgnet.com/bpg/GerInfo/287>

**GUIDELINES FOR NON-NATIVE SPEAKERS OF ENGLISH**

<https://www.wjgnet.com/bpg/gerinfo/240>

**PUBLICATION ETHICS**

<https://www.wjgnet.com/bpg/GerInfo/288>

**PUBLICATION MISCONDUCT**

<https://www.wjgnet.com/bpg/gerinfo/208>

**ARTICLE PROCESSING CHARGE**

<https://www.wjgnet.com/bpg/gerinfo/242>

**STEPS FOR SUBMITTING MANUSCRIPTS**

<https://www.wjgnet.com/bpg/GerInfo/239>

**ONLINE SUBMISSION**

<https://www.f6publishing.com>



## Retrospective Study

# Recent trends in the prevalence and distribution of colonic diverticula in Japan evaluated using computed tomography colonography

Noriyuki Isohata, Koichi Nagata, Kenichi Utano, Ryoichi Nozaki, Satoshi Nozu, Takashi Kato, Shigeyoshi Kijima, Hiroshi Matsumoto, Kenichiro Majima, Yasuji Ryu, Michiaki Hirayama, Shungo Endo

**ORCID number:** Noriyuki Isohata 0000-0003-4281-9340; Koichi Nagata 0000-0001-5195-7636; Kenichi Utano 0000-0002-1345-6993; Ryoichi Nozaki 0000-0003-3227-9061; Satoshi Nozu 0000-0002-5776-8251; Takashi Kato 0000-0003-4430-9678; Shigeyoshi Kijima 0000-0003-0704-5714; Hiroshi Matsumoto 0000-0003-2810-2888; Kenichiro Majima 0000-0001-9495-4873; Yasuji Ryu 0000-0002-6067-3616; Michiaki Hirayama 0000-0002-1443-4526; Shungo Endo 0000-0003-2383-8407.

**Author contributions:** Planning and conducting the study was performed by Endo S, Isohata N and Nagata K; Data collection was performed by Nagata K; Radiological interpretation of data was performed by Nagata K, Utano K, Nozaki R, Nozu S, Kato T, Kijima S, Matsumoto H, Majima K, Yasuji R and Hirayama M; Drafting the manuscript was performed Isohata N; all authors critically revised the report, commented on drafts of the manuscript, and approved the final report.

### Institutional review board

**statement:** This study was reviewed and approved by the Ethics Committee of the

**Noriyuki Isohata, Shungo Endo,** Department of Coloproctology, Fukushima Medical University, Aizu Medical Center, Aizuwakamatsu 969-3492, Fukushima, Japan

**Koichi Nagata,** Department of Gastroenterology, Fukushima Medical University, Fukushima 960-1295, Fukushima, Japan

**Kenichi Utano,** Department of Radiology, Fukushima Medical University, Aizu Medical Center, Aizuwakamatsu 969-3492, Fukushima, Japan

**Ryoichi Nozaki,** Department of Gastroenterology, Takano Hospital, Coloproctology Center, Kumamoto 862-0971, Kumamoto, Japan

**Satoshi Nozu,** Department of Radiology, Saitama Cancer Center, Ina 362-0806, Saitama, Japan

**Takashi Kato,** Department of Gastroenterology, National Hospital Organization Hokkaido Medical Center, Sapporo 063-0005, Hokkaido, Japan

**Shigeyoshi Kijima,** Department of Radiology, Jichi Medical University, Shimotsuke 329-0498, Tochigi, Japan

**Hiroshi Matsumoto,** Division of Gastroenterology, Kawasaki Medical School Hospital, Kurashiki 701-0192, Okayama, Japan

**Kenichiro Majima,** Department of Health Management, Kameda Medical Center, Kamogawa 296-8602, Chiba, Japan

**Yasuji Ryu,** Department of Radiology, Tonami General Hospital, Tonami 939-1395, Toyama, Japan

**Michiaki Hirayama,** Department of Gastroenterology, Tonan Hospital, Sapporo 060-0004, Hokkaido, Japan

**Corresponding author:** Noriyuki Isohata, MD, PhD, Assistant Professor, Department of Coloproctology, Fukushima Medical University, Aizu Medical Center, 21-2 Maeda, Tanisawa, Kawahigashi-Machi, Aizuwakamatsu 969-3492, Fukushima, Japan. [nisohata@fmu.ac.jp](mailto:nisohata@fmu.ac.jp)



Fukushima Medical University Hospital.

**Informed consent statement:**

Participants were not required to give informed consent to this study because the analysis used anonymous clinical data that were obtained after each participant agreed to treatment by written consent.

**Conflict-of-interest statement:**

We have no financial relationship to disclosure.

**Data sharing statement:**

No additional data are available.

**Open-Access:** This article is an open-access article that was selected by an in-house editor and fully peer-reviewed by external reviewers. It is distributed in accordance with the Creative Commons Attribution NonCommercial (CC BY-NC 4.0) license, which permits others to distribute, remix, adapt, build upon this work non-commercially, and license their derivative works on different terms, provided the original work is properly cited and the use is non-commercial. See: <http://creativecommons.org/licenses/by-nc/4.0/>

**Manuscript source:** Unsolicited manuscript

**Specialty type:** Gastroenterology and hepatology

**Country/Territory of origin:** Japan

**Peer-review report's scientific quality classification**

Grade A (Excellent): 0  
Grade B (Very good): B  
Grade C (Good): C  
Grade D (Fair): 0  
Grade E (Poor): 0

**Received:** April 27, 2021

**Peer-review started:** April 27, 2021

**First decision:** May 27, 2021

**Revised:** June 6, 2021

**Accepted:** July 9, 2021

**Article in press:** July 9, 2021

**Published online:** July 21, 2021

**P-Reviewer:** Du P, Perez AR

**S-Editor:** Wu YXJ

# Abstract

## BACKGROUND

Computed tomography colonography (CTC) may be superior to colonoscopy and barium enema for detecting diverticula. However, few studies have used CTC to diagnose diverticula.

## AIM

To evaluate the current prevalence and distribution of colonic diverticula in Japan using CTC.

## METHODS

This study was conducted as part of the Japanese National Computed Tomographic Colonography Trial, which included 1181 participants from 14 hospitals in Japan. We analyzed the prevalence and distribution of colonic diverticula and their relationships with age and sex. The relationship between the diverticula and the length of the large intestine was also analyzed.

## RESULTS

Diverticulosis was present in 48.1% of the participants. The prevalence of diverticulosis was higher in the older participants ( $P < 0.001$  for trend). The diverticula seen in younger participants were predominantly located in the right-sided colon. Older participants had a higher frequency of bilateral type (located in the right- and left-sided colon) diverticulosis ( $P < 0.001$  for trend). The length of the large intestine with multiple diverticula in the sigmoid colon was significantly shorter in those without diverticula ( $P < 0.001$ ).

## CONCLUSION

The prevalence of colonic diverticulosis in Japan is higher than that previously reported. The prevalence was higher, and the distribution tended to be bilateral in older participants.

**Key Words:** Computed tomography colonography; Diverticulosis; Diverticular disease; Colon

©The Author(s) 2021. Published by Baishideng Publishing Group Inc. All rights reserved.

**Core Tip:** In this retrospective study, we evaluated the current prevalence and distribution of colonic diverticula in Japan using computed tomography colonography. Diverticulosis was present in 48.1% of the 1181 participants. The prevalence of diverticulosis was higher among the older participants. The diverticula seen in younger participants were predominantly located in the right-sided colon. Older participants had a higher frequency of the bilateral type. The length of the large intestine with multiple diverticula in the sigmoid colon was significantly shorter in participants without diverticula.

**Citation:** Isohata N, Nagata K, Utano K, Nozaki R, Nozu S, Kato T, Kijima S, Matsumoto H, Majima K, Ryu Y, Hirayama M, Endo S. Recent trends in the prevalence and distribution of colonic diverticula in Japan evaluated using computed tomography colonography. *World J Gastroenterol* 2021; 27(27): 4441-4452

**URL:** <https://www.wjgnet.com/1007-9327/full/v27/i27/4441.htm>

**DOI:** <https://dx.doi.org/10.3748/wjg.v27.i27.4441>

## INTRODUCTION

Colonic diverticulosis is a common abnormality of the colon. Almost all colonic diverticula are pseudodiverticula, which are small outpouchings of the colonic mucosa and submucosa that herniate through the muscle layers at sites of vascular perforation [1]. Diverticulosis refers to asymptomatic diverticula, whereas diverticular disease

L-Editor: A

P-Editor: Xing YX



refers to symptomatic diverticula. Diverticular disease is classified into uncomplicated and complicated diseases, including perforation, fistulae, obstructions, and bleeding [1]. The cumulative incidences of bleeding and diverticulitis in patients with colonic diverticulosis are 10% and 10%-25%, respectively [2,3]. Additionally, the prevalence of colonic diverticulosis increases with age [1,4,5]. Due to Japan's aging population, the incidence of diverticular diseases in older patients who need treatment will also likely increase [6].

Findings from studies involving colonoscopy or barium enema have shown that the prevalence and distribution of diverticulosis differ according to country, region, and race [7-11]. These reports are from the early 2000s until the mid-2010s, and also reported that the incidence of diverticula increased with time [5,8]. Colonic diverticula occur mainly in the left colon in Western populations and in the right colon in Japanese and other Asian populations [7-9,11,12]. Recent studies have reported that the overall prevalence of diverticulosis in Japan is 20%-26.0% [5,7,8].

Colonoscopy is a standard technique that is widely performed for the screening and diagnosis of colonic and rectal diseases. However, there are reports suggesting that compared to colonoscopy, assessments based on barium enema are superior for diagnosing colonic diverticula, especially in the sigmoid colon [13,14]. In recent years, computed tomography colonography (CTC) has been widely used as an alternative colon cancer screening method. CTC can detect diverticula as outpouchings of the colonic wall from a more advantageous perspective, and it may be superior to colonoscopy and barium enema for detecting diverticula. Only one large study has evaluated the prevalence and distribution of colonic diverticula using CTC [15]. Hence, this study is the largest study in the world and is the first to accurately evaluate the prevalence and distribution of colonic diverticula in Japanese patients using CTC.

## MATERIALS AND METHODS

This study was conducted as a part of another study on the application of CTC for detecting polypoid lesions [Japanese National Computed Tomographic Colonography Trial (JANCT)] [16]. The trial was registered with Clinical Trials.gov (No. NCT00997802) and the UMIN Clinical Trials Registry (No. UMIN000002097). The medical ethics committee of Fukushima Medical University reviewed and approved the study design. The JANCT data were analyzed using the Digital Imaging and Communications in Medicine protocol. Patients from 14 hospitals in Japan were enrolled between September 2009 and August 2011. This study was conducted in accordance with the principles of the Declaration of Helsinki. The institutional review board of each hospital approved the study. All patients provided written informed consent prior to enrollment. The patients included in this study underwent CTC for screening purposes or because they had abdominal symptoms, positive fecal immunochemical test (FIT) results, a personal history of polyps, or a familial history of colorectal cancer (CRC) or polyps. Moreover, 847 participants were screened, 96 for abdominal symptoms or change in bowel habits, 165 for positive FIT, 42 for melena or hematochezia, 11 for surveillance after polypectomy, and 19 for abnormal blood test results (anemia or tumor marker elevation). The exclusion criteria have been described in detail previously [16]. Briefly, participants with serious medical conditions for bowel preparation and colonoscopy or CTC, who underwent colonoscopy or barium enema during the preceding 3 years, with known colorectal polyps or cancers, a history of inflammatory bowel disease, and familial polyposis, and who underwent colorectal surgery were excluded from the study.

### Computed tomography colonography

Details of the CTC procedure have been previously published [16]. A polyethylene glycol electrolyte lavage solution (Niflec; Ajinomoto Pharmaceuticals, Tokyo, Japan) was used for bowel preparation, and contrast medium containing sodium diatrizoate (Gastrografin; Bayer Yakuhin, Osaka, Japan) was added to tag the residual fluid. A tube was inserted while the patients were in the left decubitus position before CO<sub>2</sub> insufflation and CTC scanning. CO<sub>2</sub> insufflation was performed using an automated CO<sub>2</sub> insufflator (HP-2; Horii Pharmaceutical Industries, Ltd., Osaka, Japan). All CTC examinations were performed using 64- or 16-channel multidetector row computed tomography (CT) scanners. CT scanning was performed under single breath-holds while the patients were in the supine and prone positions.

### **Evaluation of the diverticula using computed tomographic colonography**

Four radiologists and six gastroenterologists participated in this study as readers of the CTC images. The readers analyzed CTC images from a median of 1750 patients (range: 400–8000 patients). Identification of the colonic diverticula and measuring the length of the large intestine were performed at workstations at each hospital, namely: AZE Virtual Place (AZE, Tokyo, Japan), Synapse Vincent (Fujifilm Medical Co., Tokyo, Japan), and Ziostation (Ziosoft, Tokyo, Japan). Axial 2-dimensional (2D) images, captured while the patients were in the supine position, were primarily used to determine the number of diverticula. A diverticulum was identified as an outpouching from the colonic wall. If necessary, other 2D and 3-dimensional (3D) images, comprising luminal fly-through or air-contrast barium enema images, were analyzed (Figure 1). The readers recorded the number of diverticula in each colonic segment, including the cecum and as well as the ascending, transverse, descending, sigmoid, and rectosigmoid colons. The rectosigmoid colon was defined as the segment between the promontrium and the inferior margin of the second sacral vertebra. Diverticula in the terminal ileum and appendix were also evaluated. The terminal ileum was defined as the portion of the ileum 10 cm from the ileocecal valve. If there were < 20 diverticula, the readers recorded the numbers as is; if there were > 20 diverticula, the readers recorded their findings as severe. When diverticula were found in multiple colonic segments, we evaluated the number of diverticula in each segment in duplicate. In analysis, the grading of diverticula was in accordance with a previous study to allow for comparison with the previous study[15]. The number of diverticula was graded in each segment: 1-5 diverticula were classified as rare, 6-20 diverticula were classified as multiple, and more than 20 diverticula were classified as severe. The length of the large intestine was defined as the distance from the anus to the appendiceal orifice and was measured automatically using 3D workstations.

### **Endpoints**

The primary endpoint of this study was to clarify the prevalence of colonic diverticulosis by CTC and to evaluate it by sex, age group, and segment. There were two secondary endpoints; the first of which was to investigate the prevalence of diverticulosis in the terminal ileum and appendix (which have not been evaluated accurately so far), and the second was to investigate the relationship between diverticulosis and the length of the large intestine.

### **Statistical analyses**

Continuous variables are reported as medians and ranges. To evaluate differences in the prevalence of diverticula and the length of the large intestine, the Mann-Whitney *U* test for unpaired samples was performed. We used the chi-squared test to assess the relationship between the prevalence of diverticulosis and sex. Trends in age-related difference and increases in the prevalence of diverticula were evaluated using the Cochran-Armitage test. Statistical significance was set at  $P < 0.05$ . Test of normal distribution was evaluated using Shapiro-Wilk test. All statistical analyses were performed using IBM®SPSS® software, version 26 (IBM Corp., Armonk, NY, United States), except for the Cochran-Armitage test and Shapiro-Wilk test, which was performed using Bell Curve for Excel version 2.20 (Social Survey Research Information Co., Ltd., Tokyo, Japan).

## **RESULTS**

### **Characteristics of the participants and relationship between age, sex and location**

Our study population comprised 1181 participants, including 669 men (56.6%) and 512 women (43.4%) with a median age of 62 years (range: 23-91 years). Of the 1181 participants, 568 (48.1%) had  $\geq 1$  diverticula. The median age of the participants with diverticula was 64 years (range: 27-91 years); that of participants with no diverticulum was 60 years (range: 23-84 years). Participants with diverticula were significantly older than participants with no diverticulum ( $P < 0.001$ ) (Table 1). The participants were stratified into five groups according to age. There were 108 participants in the 40 years or younger group, 165 in the 41-50 years group, 268 in the 51-60 years group, 327 in the 61-70 years group, and 313 in the 71 years and over group. A normal distribution of age dates was performed.

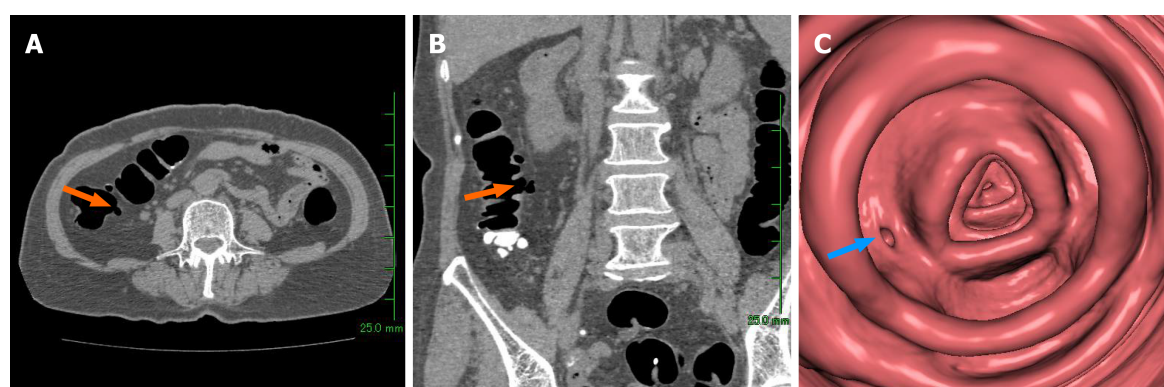
Diverticulosis was present in 346 men (29.3%) and 222 women (18.8%). The frequency of diverticulosis in men was significantly higher than that in women ( $P =$



**Table 1 Characteristics of the participants**

	Diverticula positive (n = 568)	Diverticulum negative (n = 613)	P value
Age: Median (range)	64 (27-91)	60 (23-84)	< 0.001
Sex, n (%): Male:female	346 (29.3):222 (18.8)	323 (27.3):290 (24.6)	0.004
Age group, n (%): Male:female			
≤ 40 (n = 108)	27 (25.0):1 (0.9)	56 (51.9):24 (22.2)	0.004
41-50 (n = 165)	42 (25.5):19 (11.5)	56 (33.9):48 (29.1)	0.058
51-60 (n = 268)	80 (29.9):50 (18.7)	67 (25.0):71 (26.5)	0.033
61-70 (n = 327)	97 (29.7):80 (24.5)	88 (26.9):62 (19.0)	0.485
≥ 71 (n = 313)	100 (31.9):72 (23.0)	56 (17.9):85 (27.2)	0.001

Characteristics of the 1181 participants analyzed in this study. The prevalence of diverticulosis according to age group and the relationship between diverticulosis and sex were analyzed.



**Figure 1 Detection of diverticula using computed tomography colonography.** The diverticula were detected mainly in 2-dimensional (2D) supine axial images. If necessary, other 2D or 3-dimensional (3D) images were used. The arrow indicates a diverticulum. A: 2D-supine axial image; B: 2D-supine coronal image; C: 3D-virtual colonoscopy image.

0.004). The frequency of diverticulosis was significantly higher or tended to occur in men in other age groups, but did not differ between sexes in the 60s. The distribution of diverticula and the relationship between sex and location of diverticula are also shown in Table 2. Diverticula were most often found in the ascending colon. The frequency of diverticulosis in men was higher in all segments except the rectosigmoid colon. Regarding the relationship between age and frequency of diverticulosis, the prevalence of diverticulosis significantly increased with age ( $P < 0.001$  for trend) (Figure 2). Over half of the participants aged > 60 years had diverticula.

### **Distribution and grade of diverticula in each age group**

The prevalence and the number of diverticula in each colonic segment increased with age, and diverticula were also found in the terminal ileum and appendix (Table 3). Thirteen participants (1.1%) had diverticula in the terminal ileum, and all had less than six diverticula. The appendix was visualized in 680 participants (57.6%), six (0.5%) of whom had appendiceal diverticula. Five participants had one diverticulum, with one participant in his 60s having three diverticula in the appendix.

### **Relationship between age and location of diverticula**

Participants with diverticula were divided into three groups according to the location of the diverticula: The right-sided type was defined as diverticula located from the ileum to the transverse colon only; the left-sided type was defined only from the descending to rectosigmoid colon; and the bilateral type was defined as located on both sides of the colon. We investigated the proportion of diverticula in each type in all patients (Figure 3). As mentioned above, the prevalence of diverticula increased with age, while the prevalence of right-sided and left-sided diverticula did not differ

**Table 2 Relationship between sex and location of diverticia**

Segment	n (%)	Male:Female
Ileum	13 (1.1)	9:4
Appendix	6 (0.5)	5:1
Cecum	258 (21.8)	153:105
Ascending colon	431 (36.5)	266:165
Transverse colon	124 (10.5)	78:46
Descending colon	149 (12.6)	102:47
Sigmoid colon	200 (16.9)	129:71
Rectosigmoid colon	4 (0.3)	1:3

The distribution of diverticula and the relationship between sex and location of diverticula were analyzed. When there was overlap in segments of the diverticula in one participant, all segments were evaluated in duplicate. The percentages of all participants are also listed.

( $P = 0.236$ ,  $P = 0.346$  for trend), even among older patients. The presence of the bilateral type increased significantly with age ( $P < 0.001$  for trend).

### **Relationship between diverticula and the length of the large intestine**

There was no significant difference between the length of the large intestine without diverticula and that with diverticula ( $P = 0.104$ ): median length was 157.2 cm (range: 104.9-259.3 cm) and 154.7 cm (range: 103.9-246.6 cm), respectively. The median length of the large intestine with  $\geq 6$  diverticula in cecum and/or ascending colon was 154.5 cm (range: 114.6-246.6 cm). This result also did not differ when compared to the length of the large intestine with no diverticula ( $P = 0.260$ ). The median length of the large intestine with  $\geq 6$  and  $\geq 21$  diverticula in the sigmoid colon was 149.9 cm (range: 113.5-195.6 cm) and 145.1 cm (range: 115.0-192.0 cm), respectively, which were both significantly shorter than those with no diverticula ( $P < 0.001$ ) (Table 4).

## **DISCUSSION**

Geographical and racial variations have been reported in relation to the prevalence and distribution of colonic diverticula[1,4,17]. In developed Western countries, the prevalence of diverticulosis is high, affecting 5% of people in their 40s and approximately half of those in their 80s[18], with an estimated mortality rate of 2.5% per 100000 per year. This disease is the fifth most important gastrointestinal disease in terms of healthcare costs[19]. The incidence of diverticula has also been reported to increase over time[5,8]. The most recent large studies using colonoscopy showed that the prevalence of diverticulosis was 42% in the United States[4] and 23.9% in Japan[8]. Diverticula are mainly left-sided in patients in the United States and in other western countries. On the other hand, patients in Japan often manifest right-sided diverticula, with an associated age-related increase in disease prevalence[1,4,5,8,12]. In our study, the prevalence of colonic diverticulosis detected using CTC was 48.1%, which is much higher than the rates reported in previous studies using colonoscopy in Japan[5,8]. A report from Europe on the prevalence of diverticula diagnosed by CTC reported a prevalence of 51.6%, similar to ours, with a higher prevalence in the right-sided colon than expected[15]; however, compared to our results, the prevalence of diverticula in the right-sided colon in Caucasians was lower than that in Japanese. Most of the recent epidemiologic studies of diverticulosis have been evaluated through colonoscopy, which is a standard technique that is performed worldwide for the screening and diagnosis of colonic diseases[4,5,8]. However, investigators have reported that compared to colonoscopy, assessments evaluated using barium enema are superior for diagnosing colonic diverticulosis[13,14]. Among diverticula that had been detected using barium enema, Niikura *et al*[14] reported colonoscopy detection ratios of 41% and 32% for diverticula in the entire colon and in the left colon, respectively. Therefore, the actual prevalence of colonoscopy-detected diverticulosis in Japan may be over 25%. Conducting clinical studies on the prevalence of diverticulosis determined that the use of barium enema is difficult, given the widespread use of

**Table 3 Sex and grade of diverticula in each segment and age group, *n* (%)**

Age group (yr)					
	≤ 40 ( <i>n</i> = 108)	41-50 ( <i>n</i> = 165)	51-60 ( <i>n</i> = 268)	61-70 ( <i>n</i> = 327)	≥ 71 ( <i>n</i> = 313)
Sex					
Male	83 (76.9)	98 (59.4)	147 (54.9)	185 (56.6)	156 (49.8)
Female	25 (23.1)	67 (40.6)	121 (45.1)	142 (43.4)	157 (50.2)
Grade of diverticula in segment					
Ileum					
Rare	0	2 (1.2)	2 (0.7)	5 (1.5)	4 (1.3)
Multiple	0	0	0	0	0
Severe	0	0	0	0	0
Appendix					
Rare	0	0	1 (0.4)	4 (1.2)	1 (0.3)
Multiple	0	0	0	0	0
Severe	0	0	0	0	0
Cecum					
Rare	10 (9.3)	21 (12.7)	48 (17.9)	77 (23.5)	75 (24.0)
Multiple	0	3 (1.8)	9 (3.4)	7 (2.1)	4 (1.3)
Severe	0	0	1 (0.4)	3 (0.9)	0
Ascending colon					
Rare	12 (11.1)	35 (21.2)	60 (22.3)	81 (24.8)	77 (24.6)
Multiple	4 (3.7)	8 (4.8)	30 (11.2)	34 (10.4)	49 (15.7)
Severe	1 (0.9)	1 (0.6)	11 (4.1)	15 (4.6)	13 (4.2)
Transverse colon					
Rare	5 (4.6)	8 (4.8)	25 (9.3)	29 (8.9)	30 (9.6)
Multiple	0	0	4 (1.5)	12 (3.7)	9 (2.9)
Severe	0	1 (0.6)	0	1 (0.3)	0
Descending colon					
Rare	4 (3.7)	6 (3.6)	25 (9.3)	30 (9.2)	32 (10.2)
Multiple	0	2 (1.2)	8 (3.0)	14 (4.3)	14 (4.5)
Severe	0	1 (0.6)	0	5 (1.5)	8 (2.6)
Sigmoid colon					
Rare	7 (6.5)	7 (4.2)	29 (10.8)	31 (9.5)	34 (10.9)
Multiple	0	0	10 (3.7)	20 (6.1)	27 (8.6)
Severe	0	2 (1.2)	3 (1.1)	11 (3.4)	19 (6.1)
Rectosigmoid colon					
Rare	0	0	1 (0.4)	0	2 (0.6)
Multiple	0	0	0	0	1 (0.3)
Severe	0	0	0	0	0

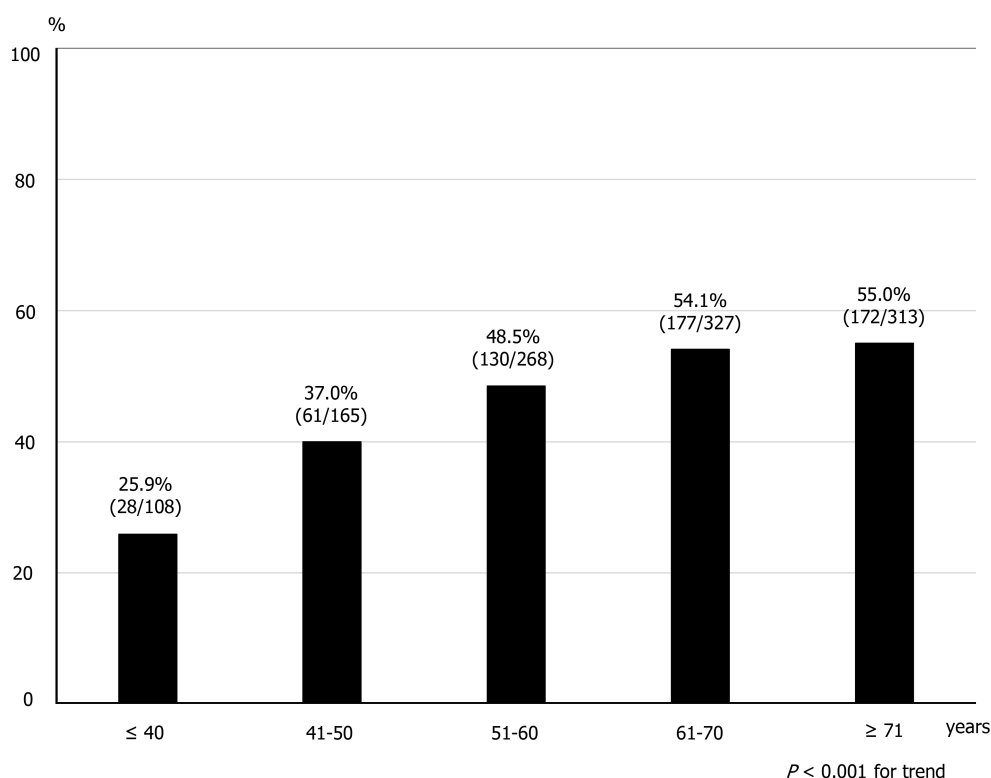
In each colonic segment, the prevalence and the number of diverticula increased with age. Diverticula identified in the appendix, terminal ileum, and rectosigmoid colon were also evaluated. Rare: 1-5 diverticula; Multiple: 6-20 diverticula; Severe: ≥ 21 diverticula.

colonoscopy. According to the European Society of Gastrointestinal Endoscopy and the European Society of Gastrointestinal and Abdominal Radiology Guideline -

**Table 4 Length of the large intestine by states of diverticula**

	Median (cm)	Range (cm)
Diverticula negative in any segment	157.2	104.9-259.3
Diverticula positive in any segment	154.7	103.9-246.6
Multiple in cecum to ascending colon	154.5	114.9-246.6
Severe in cecum to ascending colon	151.6	119.6-198.4
Multiple in sigmoid colon	149.9	113.5-195.6
Severe in sigmoid colon	145.1	115.0-192.0

The large intestine of participants with multiple and severe diverticula in the sigmoid colon was significantly shorter than that of the participants with no diverticula ( $P < 0.001$ ).

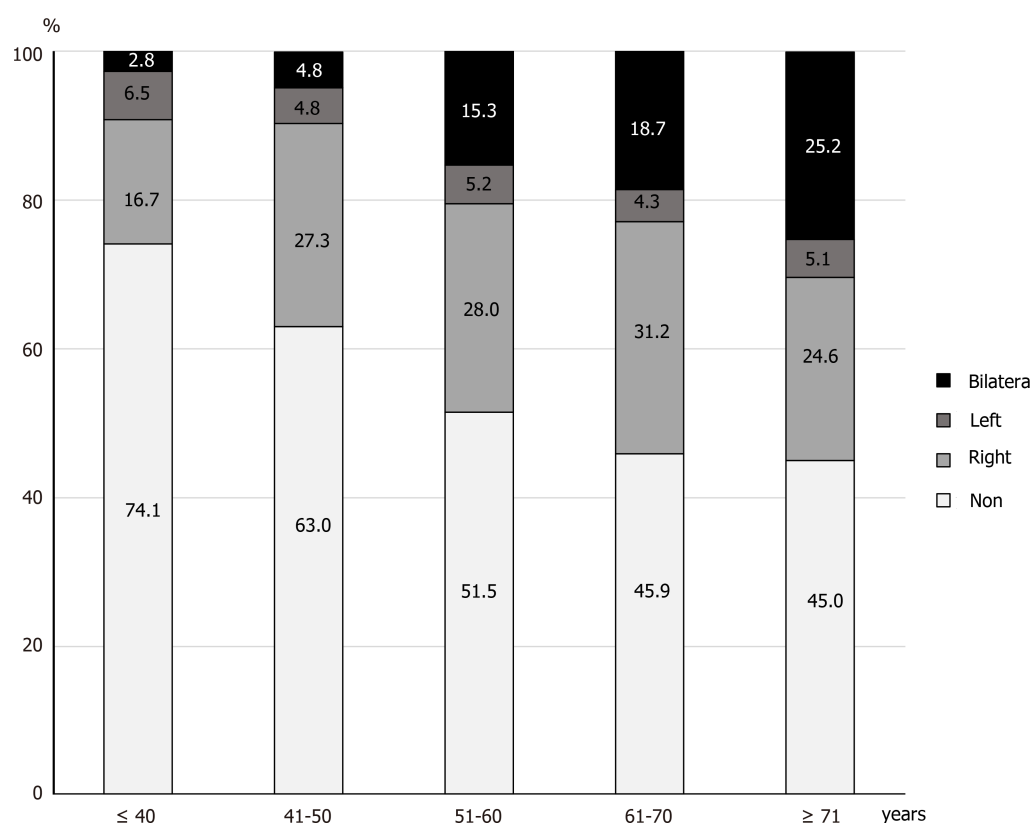


**Figure 2 Prevalence of diverticulosis by age group.** The prevalence of diverticulosis increased with age ( $P < 0.001$  for trend).

Update 2020[20], barium enema for the diagnosis of colorectal neoplasia was not recommended (strong recommendation); in this regard, barium enema cannot be used in this setting.

In recent years, CTC has become more popular for screening and diagnosing colorectal cancer[21,22]; therefore, CTC could be used as an alternative to colonoscopy due to its diagnostic ability and safety[20,23]. It might be superior for detecting diverticula because it can evaluate the colon from more advantageous perspectives and avoid impediments caused by overlapping adjacent sections of the colon. In fact, De Cecco *et al*[15] reported that the prevalence of diverticulosis identified using CTC was 51.6%, which was much higher than that previously reported using colonoscopes in Western countries[4]. This result is similar to our results.

Our results showed that the prevalence of diverticulosis is increasing in Japan, mimicking the trend seen in Western countries. Several studies have shown that age, low intake of dietary fiber, fat intake, red meat intake, alcohol consumption, smoking, and increasing body weight are pathogenic risk factors associated with colonic diverticulosis[1,4,7,8,24]. Increasing age and changing to a westernized diet might be the most closely associated risk factor for the increasing prevalence of diverticulosis in



**Figure 3 Location of diverticula by age group.** An analysis of all participants showed that diverticulosis of the younger generation was predominantly right-sided, and bilateral diverticulosis increased with age ( $P < 0.001$  for trend).

Japan.

In our study, the prevalence and grades of colonic diverticula increased with age, which concurs with the findings of previous studies[1,4,8]. Moreover, right-sided colonic diverticula were more predominant in patients aged  $< 70$  years. While the prevalence of diverticula in the right- and left-sided colon did not differ, even in older patients, the prevalence of bilateral diverticula was higher in older patients. Patients with right-sided diverticula only may eventually develop left-sided diverticula with aging. Consequently, they may ultimately develop bilateral diverticula[25]. Although reports from Western countries suggest that the rate of diverticulosis does not differ between the sexes, our results showed that diverticulosis was more common in men, which is consistent with the findings of previous studies in Japan[1,4,5,8].

In this study, diverticula were also identified in the terminal ileum and appendix. Although there are few case reports and research on resected specimens[26-28], this is the first epidemiological report of asymptomatic diverticulosis of the appendix and terminal ileum. This should be considered in the differential diagnosis of acute abdomen and lower gastrointestinal bleeding. Diverticula in the appendix and terminal ileum, and as well as low numbers of right-sided diverticula, might be congenital. Similar to colonic diverticula, inflammation and hemorrhage are occasional consequences.

This is the first study to investigate the relationship between the length of the large intestine and the presence of diverticula. The large intestine with multiple ( $\geq 6$ ) diverticula in the sigmoid colon was significantly shorter than that with no diverticula. There have been no reports of studies on the relationship between colonic diverticulosis and the length of the large intestine. The ability to accurately measure the length of the large intestine using a workstation is an advantage of CTC, a study made possible because of CTC. However, the length of the large intestine did not differ between the participants with multiple diverticula in the cecum and/or ascending colon in those with no diverticula. When multiple diverticula are present, the colonic wall can thicken and become rigid[18], and the sigmoid colon may shorten because it is free in the peritoneal cavity. In contrast, the colon is unlikely to shorten in patients with multiple right-sided diverticula because it is attached to the retroperitoneum.



This study had several limitations. First, about 70% of asymptomatic participants participated for screening purpose. The study also included participants who underwent CTC for the purpose of examination for any abdominal symptoms, or positive FIT, or abnormal blood test, or a familial history of CRC and polyps, or for the surveillance of polyps. Hence, the findings of this study may not necessarily reflect those of an asymptomatic general population. Second, participants aged > 50 years accounted for > 75% of the study population, and only a small number of patients aged < 40 years were included in this study. This differs from the age structure of the general population in Japan, which may explain why the prevalence of colonic diverticula in this study was much higher than what was previously reported. However, asymptomatic younger people have not been evaluated in previous studies. There might be the same bias in previous studies diagnosed by colonoscopy or barium enema on the prevalence of diverticula. Third, the patients' diet, lifestyle, and physical factors could underlie the increase in the prevalence of diverticulosis; however, data describing these factors were absent from this study. Fourth, the number of participants was smaller than the number of studies conducted based on colonoscopy [5,7,8]. This is because CTC is not yet widely used as a screening modality for colorectal neoplasms, and the facilities that can be used are limited. However, the number of participants in this study was slightly larger than that in a previous study conducted by CTC[15]. Moreover, the data used in this study are approximately 10 years old and are a bit out of date. We believe that a large-scale prospective study should be conducted after standardization of bowel preparation and imaging protocols in the future.

## CONCLUSION

This is the first investigation to use CTC to evaluate the prevalence and distribution of colonic diverticula in Japan. The prevalence of colonic diverticulosis was higher than that reported previously. In addition to the superiority of CTC in detecting colonic diverticula, the aging of the Japanese population and the change to a Western diet may be behind the high prevalence of colonic diverticulosis observed in this study. The diverticula were predominantly right-sided in the younger generation, while right- and left-sided diverticula were more common in older participants. The prevalence of asymptomatic diverticulosis in the terminal ileum and appendix can be clarified for the first time. These results may be helpful in the management of diverticular diseases.

## ARTICLE HIGHLIGHTS

### Research background

Colonic diverticulosis is a common abnormality of the colon. The prevalence of diverticulosis and diverticular disease in Japan is increasing due to aging and a westernized diet.

### Research motivation

Recent trends in the prevalence and distribution of colonic diverticula in Japan are not clear. Most recent studies on diverticulosis in Japan involved the use of colonoscopy. In recent years, computed tomography colonography (CTC) has been widely used as an alternative colon cancer screening method. We considered CTC to detect diverticula as outpouchings of the colonic wall from a more advantageous perspective, and it may be superior to colonoscopy and barium enema for detecting diverticula.

### Research objectives

The main objective of this study was to evaluate the prevalence and distribution of colonic diverticula in Japan.

### Research methods

This study included 1181 participants from 14 hospitals in Japan. We analyzed the prevalence and distribution of colonic diverticula and their relationships with age and sex using CTC and analyzed the relationship between the diverticula and the length of the large intestine.

### Research results

Diverticulosis was present in 48.1% of the participants. The prevalence of diverticulosis was higher in the older participants. The diverticula seen in younger participants were predominantly located in the right-sided colon and on the bilateral side for older participants. The length of the large intestine with multiple diverticula in the sigmoid colon was significantly shorter in those without diverticula.

### Research conclusions

The prevalence of colonic diverticulosis in Japan is 48.1%. This was much higher than that previously reported. In older participants, the prevalence was higher, and the distribution tended to be bilateral.

### Research perspectives

The data used in this study were slightly limited and a bit out of date. We hope to perform a large-scale prospective study after standardization of bowel preparation and imaging protocols, and CTC use will become widespread in the future. We also hope to determine the relationship between the trends in diverticulosis and its accompanying symptoms.

## REFERENCES

- 1 Stollman N, Raskin JB. Diverticular disease of the colon. *Lancet* 2004; **363**: 631-639 [PMID: 14987890 DOI: 10.1016/S0140-6736(04)15597-9]
- 2 Niikura R, Nagata N, Shimbo T, Aoki T, Yamada A, Hirata Y, Sekine K, Okubo H, Watanabe K, Sakurai T, Yokoi C, Mizokami M, Yanase M, Akiyama J, Koike K, Uemura N. Natural history of bleeding risk in colonic diverticulosis patients: a long-term colonoscopy-based cohort study. *Aliment Pharmacol Ther* 2015; **41**: 888-894 [PMID: 25715746 DOI: 10.1111/apt.13148]
- 3 Shahedi K, Fuller G, Bolus R, Cohen E, Vu M, Shah R, Agarwal N, Kaneshiro M, Atia M, Sheen V, Kurzbard N, van Oijen MG, Yen L, Hodgkins P, Erder MH, Spiegel B. Long-term risk of acute diverticulitis among patients with incidental diverticulosis found during colonoscopy. *Clin Gastroenterol Hepatol* 2013; **11**: 1609-1613 [PMID: 23856358 DOI: 10.1016/j.cgh.2013.06.020]
- 4 Peery AF, Keku TO, Martin CF, Eluri S, Runge T, Galanko JA, Sandler RS. Distribution and Characteristics of Colonic Diverticula in a United States Screening Population. *Clin Gastroenterol Hepatol* 2016; **14**: 980-985. e1 [PMID: 26872402 DOI: 10.1016/j.cgh.2016.01.020]
- 5 Nagata N, Niikura R, Aoki T, Shimbo T, Itoh T, Goda Y, Suda R, Yano H, Akiyama J, Yanase M, Mizokami M, Uemura N. Increase in colonic diverticulosis and diverticular hemorrhage in an aging society: lessons from a 9-year colonoscopic study of 28,192 patients in Japan. *Int J Colorectal Dis* 2014; **29**: 379-385 [PMID: 24317937 DOI: 10.1007/s00384-013-1808-4]
- 6 Wheat CL, Strate LL. Trends in Hospitalization for Diverticulitis and Diverticular Bleeding in the United States From 2000 to 2010. *Clin Gastroenterol Hepatol* 2016; **14**: 96-103. e1 [PMID: 25862988 DOI: 10.1016/j.cgh.2015.03.030]
- 7 Nagata N, Niikura R, Shimbo T, Kishida Y, Sekine K, Tanaka S, Aoki T, Watanabe K, Akiyama J, Yanase M, Itoh T, Mizokami M, Uemura N. Alcohol and smoking affect risk of uncomplicated colonic diverticulosis in Japan. *PLoS One* 2013; **8**: e81137 [PMID: 24339905 DOI: 10.1371/journal.pone.0081137]
- 8 Yamamichi N, Shimamoto T, Takahashi Y, Sakaguchi Y, Kakimoto H, Matsuda R, Kataoka Y, Saito I, Tsuji Y, Yakabi S, Takeuchi C, Minatsuki C, Niimi K, Asada-Hirayama I, Nakayama C, Ono S, Kodashima S, Yamaguchi D, Fujishiro M, Yamaji Y, Wada R, Mitsushima T, Koike K. Trend and risk factors of diverticulosis in Japan: age, gender, and lifestyle/metabolic-related factors may cooperatively affect on the colorectal diverticula formation. *PLoS One* 2015; **10**: e0123688 [PMID: 25860671 DOI: 10.1371/journal.pone.0123688]
- 9 Hong W, Geng W, Wang C, Dong L, Pan S, Yang X, Zippi M, Xu C, Zhou M, Pan J. Prevalence of colonic diverticulosis in mainland China from 2004 to 2014. *Sci Rep* 2016; **6**: 26237 [PMID: 27184602 DOI: 10.1038/srep26237]
- 10 Golder M, Ster IC, Babu P, Sharma A, Bayat M, Farah A. Demographic determinants of risk, colon distribution and density scores of diverticular disease. *World J Gastroenterol* 2011; **17**: 1009-1017 [PMID: 21448352 DOI: 10.3748/wjg.v17.i8.1009]
- 11 Miura S, Kodaira S, Shatari T, Nishioka M, Hosoda Y, Hisa TK. Recent trends in diverticulosis of the right colon in Japan: retrospective review in a regional hospital. *Dis Colon Rectum* 2000; **43**: 1383-1389 [PMID: 11052515 DOI: 10.1007/BF02236634]
- 12 Nakaji S, Danjo K, Munakata A, Sugawara K, MacAuley D, Kernohan G, Baxter D. Comparison of etiology of right-sided diverticula in Japan with that of left-sided diverticula in the West. *Int J Colorectal Dis* 2002; **17**: 365-373 [PMID: 12355211 DOI: 10.1007/s00384-002-0403-x]
- 13 Rockey DC, Koch J, Yee J, McQuaid KR, Halvorsen RA. Prospective comparison of air-contrast barium enema and colonoscopy in patients with fecal occult blood: a pilot study. *Gastrointest Endosc*

- 2004; **60**: 953-958 [PMID: [15605011](#) DOI: [10.1016/S0016-5107\(04\)02223-0](#)]
- 14 **Niikura R**, Nagata N, Shimbo T, Akiyama J, Uemura N. Colonoscopy can miss diverticula of the left colon identified by barium enema. *World J Gastroenterol* 2013; **19**: 2362-2367 [PMID: [23613630](#) DOI: [10.3748/wjg.v19.i15.2362](#)]
- 15 **De Cecco CN**, Ciolina M, Annibale B, Rengo M, Bellini D, Muscogiuri G, Maruotti A, Saba L, Iafrate F, Laghi A. Prevalence and distribution of colonic diverticula assessed with CT colonography (CTC). *Eur Radiol* 2016; **26**: 639-645 [PMID: [26105021](#) DOI: [10.1007/s00330-015-3866-1](#)]
- 16 **Nagata K**, Endo S, Honda T, Yasuda T, Hirayama M, Takahashi S, Kato T, Horita S, Furuya K, Kasai K, Matsumoto H, Kimura Y, Utano K, Sugimoto H, Kato H, Yamada R, Yamamichi J, Shimamoto T, Ryu Y, Matsui O, Kondo H, Doi A, Abe T, Yamano HO, Takeuchi K, Hanai H, Saida Y, Fukuda K, Näppi J, Yoshida H. Accuracy of CT Colonography for Detection of Polypoid and Nonpolypoid Neoplasia by Gastroenterologists and Radiologists: A Nationwide Multicenter Study in Japan. *Am J Gastroenterol* 2017; **112**: 163-171 [PMID: [27779195](#) DOI: [10.1038/ajg.2016.478](#)]
- 17 **Martel J**, Raskin JB; NDSG. History, incidence, and epidemiology of diverticulosis. *J Clin Gastroenterol* 2008; **42**: 1125-1127 [PMID: [18936648](#) DOI: [10.1097/MCG.0b013e3181865f18](#)]
- 18 **Petruzzello L**, Iacopini F, Bulajic M, Shah S, Costamagna G. Review article: uncomplicated diverticular disease of the colon. *Aliment Pharmacol Ther* 2006; **23**: 1379-1391 [PMID: [16669953](#) DOI: [10.1111/j.1365-2036.2006.02896.x](#)]
- 19 **Sandler RS**, Everhart JE, Donowitz M, Adams E, Cronin K, Goodman C, Gemmen E, Shah S, Avdic A, Rubin R. The burden of selected digestive diseases in the United States. *Gastroenterology* 2002; **122**: 1500-1511 [PMID: [11984534](#) DOI: [10.1053/gast.2002.32978](#)]
- 20 **Spada C**, Hassan C, Bellini D, Burling D, Cappello G, Carretero C, Dekker E, Eliakim R, de Haan M, Kaminski MF, Koulaouzidis A, Laghi A, Lefere P, Mang T, Milluzzo SM, Morrin M, McNamara D, Neri E, Pecere S, Pioche M, Plumb A, Rondonotti E, Spaander MC, Taylor S, Fernandez-Urien I, van Hooft JE, Stoker J, Regge D. Imaging alternatives to colonoscopy: CT colonography and colon capsule. European Society of Gastrointestinal Endoscopy (ESGE) and European Society of Gastrointestinal and Abdominal Radiology (ESGAR) Guideline - Update 2020. *Eur Radiol* 2021; **31**: 2967-2982 [PMID: [33104846](#) DOI: [10.1007/s00330-020-07413-4](#)]
- 21 **Levin B**, Lieberman DA, McFarland B, Smith RA, Brooks D, Andrews KS, Dash C, Giardiello FM, Glick S, Levin TR, Pickhardt P, Rex DK, Thorson A, Winawer SJ; American Cancer Society Colorectal Cancer Advisory Group; US Multi-Society Task Force; American College of Radiology Colon Cancer Committee. Screening and surveillance for the early detection of colorectal cancer and adenomatous polyps, 2008: a joint guideline from the American Cancer Society, the US Multi-Society Task Force on Colorectal Cancer, and the American College of Radiology. *CA Cancer J Clin* 2008; **58**: 130-160 [PMID: [18322143](#) DOI: [10.3322/CA.2007.0018](#)]
- 22 **US Preventive Services Task Force**, Bibbins-Domingo K, Grossman DC, Curry SJ, Davidson KW, Epling JW Jr, García FAR, Gillman MW, Harper DM, Kemper AR, Krist AH, Kurth AE, Landefeld CS, Mangione CM, Owens DK, Phillips WR, Phipps MG, Pignone MP, Siu AL. Screening for colorectal cancer. US Preventive Services Task Force Recommendation Statement. *JAMA* 2016; **315**: 2564-2575 [PMID: [27304597](#) DOI: [10.1001/jama.2016.5989](#)]
- 23 **Nagata K**, Takabayashi K, Yasuda T, Hirayama M, Endo S, Nozaki R, Shimada T, Kanazawa H, Fujiwara M, Shimizu N, Iwatsuki T, Iwano T, Saito H. Adverse events during CT colonography for screening, diagnosis and preoperative staging of colorectal cancer: a Japanese national survey. *Eur Radiol* 2017; **27**: 4970-4978 [PMID: [28674967](#) DOI: [10.1007/s00330-017-4920-y](#)]
- 24 **Strate LL**. Lifestyle factors and the course of diverticular disease. *Dig Dis* 2012; **30**: 35-45 [PMID: [22572683](#) DOI: [10.1159/000335707](#)]
- 25 **Miura S**, Kodaira S, Aoki H, Hosoda Y. Bilateral type diverticular disease of the colon. *Int J Colorectal Dis* 1996; **11**: 71-75 [PMID: [8739830](#) DOI: [10.1007/BF00342463](#)]
- 26 **Käser SA**, Willi N, Maurer CA. Prevalence and clinical implications of diverticulosis of the vermiform appendix. *J Int Med Res* 2013; **41**: 1350-1356 [PMID: [23771712](#) DOI: [10.1177/0300060513487651](#)]
- 27 **Iwano T**, Nagata K, Egawa T, Yamashita H. Appendiceal diverticulosis incidentally detected by computed tomographic colonography. *Dig Liver Dis* 2016; **48**: 565 [PMID: [26965784](#) DOI: [10.1016/j.dld.2016.02.006](#)]
- 28 **Nakazawa N**, Suzuki H, Ebara G, Watanabe Y, Tsukagoshi R, Ieta K, Morohara K, Osawa H, Katayama K, Yasuda Y, Tanaka S, Kuwano H. Adult intussusceptions induced by a terminal ileum diverticulum: a case report. *Clin Case Rep* 2018; **6**: 674-677 [PMID: [29636938](#) DOI: [10.1002/ccr3.1403](#)]



Published by **Baishideng Publishing Group Inc**  
7041 Koll Center Parkway, Suite 160, Pleasanton, CA 94566, USA

**Telephone:** +1-925-3991568

**E-mail:** [bpgoffice@wjgnet.com](mailto:bpgoffice@wjgnet.com)

**Help Desk:** <https://www.f6publishing.com/helpdesk>

<https://www.wjgnet.com>

