

# World Journal of *Gastroenterology*

*World J Gastroenterol* 2021 July 28; 27(28): 4484-4745



### EDITORIAL

- 4484** Asymptomatic small intestinal ulcerative lesions: Obesity and *Helicobacter pylori* are likely to be risk factors  
*Fujimori S*

### GUIDELINE INTERPRETATION

- 4493** Recent advances in gastrointestinal cancers  
*Bordry N, Astaras C, Ongaro M, Goossens N, Frossard JL, Koessler T*

### REVIEW

- 4504** Gastrointestinal and hepatic diseases during the COVID-19 pandemic: Manifestations, mechanism and management  
*Mohamed DZ, Ghoneim MES, Abu-Risha SES, Abdelsalam RA, Farag MA*
- 4536** Management of cholelithiasis with choledocholithiasis: Endoscopic and surgical approaches  
*Cianci P, Restini E*
- 4555** Cellular factors involved in the hepatitis C virus life cycle  
*Li HC, Yang CH, Lo SY*
- 4582** Modulation of cell physiology under hypoxia in pancreatic cancer  
*Estaras M, Gonzalez A*
- 4603** Viral hepatitis: Milestones, unresolved issues, and future goals  
*Torre P, Aglitti A, Masarone M, Persico M*

### MINIREVIEWS

- 4639** Addition of statins to the standard treatment in patients with cirrhosis: Safety and efficacy  
*Muñoz AE, Pollarsky FD, Marino M, Cartier M, Vázquez H, Salgado P, Romero G*
- 4653** Genetic variant of cyclooxygenase-2 in gastric cancer: More inflammation and susceptibility  
*Ji XK, Madhurapantula SV, He G, Wang KY, Song CH, Zhang JY, Wang KJ*

### ORIGINAL ARTICLE

#### Basic Study

- 4667** Y-box binding protein 1 augments sorafenib resistance *via* the PI3K/Akt signaling pathway in hepatocellular carcinoma  
*Liu T, Xie XL, Zhou X, Chen SX, Wang YJ, Shi LP, Chen SJ, Wang YJ, Wang SL, Zhang JN, Dou SY, Jiang XY, Cui RL, Jiang HQ*

**Retrospective Study**

- 4687** *Lens culinaris* agglutinin-reactive fraction of alpha-fetoprotein improves diagnostic accuracy for hepatocellular carcinoma

*Lee HA, Lee YR, Lee YS, Jung YK, Kim JH, An H, Yim HJ, Jeon YT, Yeon JE, Byun KS, Seo YS*

- 4697** New anti-reflux plastic stent to reduce the risk of stent-related cholangitis in the treatment of biliary strictures

*Yuan XL, Ye LS, Zeng XH, Tan QH, Mou Y, Liu W, Wu CC, Yang H, Hu B*

**Clinical Trials Study**

- 4710** Modified Xiaochaihu Decoction for gastroesophageal reflux disease: A randomized double-simulation controlled trial

*Li Z, Tao L, Zhang SS, Sun XH, Chen SN, Wu J*

**Observational Study**

- 4722** Relationship between clinical features and intestinal microbiota in Chinese patients with ulcerative colitis

*He XX, Li YH, Yan PG, Meng XC, Chen CY, Li KM, Li JN*

**CASE REPORT**

- 4738** HER2-positive adenocarcinoma arising from heterotopic pancreas tissue in the duodenum: A case report

*Hirokawa YS, Iwata T, Okugawa Y, Tanaka K, Sakurai H, Watanabe M*

**ABOUT COVER**

Editorial Board Member of *World Journal of Gastroenterology*, Kentaro Yoshioka, MD, PhD, Director, Center for Liver Diseases, Meijo Hospital, 1-3-1 Sannomaru, Naka-ku, Nagoya 460-0001, Japan. kyoshiok@fujita-hu.ac.jp

**AIMS AND SCOPE**

The primary aim of *World Journal of Gastroenterology* (WJG, *World J Gastroenterol*) is to provide scholars and readers from various fields of gastroenterology and hepatology with a platform to publish high-quality basic and clinical research articles and communicate their research findings online. WJG mainly publishes articles reporting research results and findings obtained in the field of gastroenterology and hepatology and covering a wide range of topics including gastroenterology, hepatology, gastrointestinal endoscopy, gastrointestinal surgery, gastrointestinal oncology, and pediatric gastroenterology.

**INDEXING/ABSTRACTING**

The WJG is now indexed in Current Contents®/Clinical Medicine, Science Citation Index Expanded (also known as SciSearch®), Journal Citation Reports®, Index Medicus, MEDLINE, PubMed, PubMed Central, and Scopus. The 2021 edition of Journal Citation Report® cites the 2020 impact factor (IF) for WJG as 5.742; Journal Citation Indicator: 0.79; IF without journal self cites: 5.590; 5-year IF: 5.044; Ranking: 28 among 92 journals in gastroenterology and hepatology; and Quartile category: Q2. The WJG's CiteScore for 2020 is 6.9 and Scopus CiteScore rank 2020: Gastroenterology is 19/136.

**RESPONSIBLE EDITORS FOR THIS ISSUE**

Production Editor: Li-Li Wang; Production Department Director: Yan-jie Ma; Editorial Office Director: Ze-Mao Gong.

**NAME OF JOURNAL**

*World Journal of Gastroenterology*

**ISSN**

ISSN 1007-9327 (print) ISSN 2219-2840 (online)

**LAUNCH DATE**

October 1, 1995

**FREQUENCY**

Weekly

**EDITORS-IN-CHIEF**

Andrzej S Tarnawski, Subrata Ghosh

**EDITORIAL BOARD MEMBERS**

<http://www.wjgnet.com/1007-9327/editorialboard.htm>

**PUBLICATION DATE**

July 28, 2021

**COPYRIGHT**

© 2021 Baishideng Publishing Group Inc

**INSTRUCTIONS TO AUTHORS**

<https://www.wjgnet.com/bpg/gerinfo/204>

**GUIDELINES FOR ETHICS DOCUMENTS**

<https://www.wjgnet.com/bpg/GerInfo/287>

**GUIDELINES FOR NON-NATIVE SPEAKERS OF ENGLISH**

<https://www.wjgnet.com/bpg/gerinfo/240>

**PUBLICATION ETHICS**

<https://www.wjgnet.com/bpg/GerInfo/288>

**PUBLICATION MISCONDUCT**

<https://www.wjgnet.com/bpg/gerinfo/208>

**ARTICLE PROCESSING CHARGE**

<https://www.wjgnet.com/bpg/gerinfo/242>

**STEPS FOR SUBMITTING MANUSCRIPTS**

<https://www.wjgnet.com/bpg/GerInfo/239>

**ONLINE SUBMISSION**

<https://www.f6publishing.com>





## Gastrointestinal and hepatic diseases during the COVID-19 pandemic: Manifestations, mechanism and management

Dina Zakaria Mohamed, Mai El-Sayed Ghoneim, Sally El-Sayed Abu-Risha, Ramy Ahmed Abdelsalam, Mohamed Abdelhalem Farag

**ORCID number:** Dina Zakaria Mohamed [0000-0003-4003-2800](https://orcid.org/0000-0003-4003-2800); Mai El-Sayed Ghoneim [0000-0002-5651-5877](https://orcid.org/0000-0002-5651-5877); Sally El-Sayed Abu-Risha [0000-0001-8099-0590](https://orcid.org/0000-0001-8099-0590); Ramy Ahmed Abdelsalam [0000-0003-1289-2862](https://orcid.org/0000-0003-1289-2862); Mohamed Abdelhalem Farag [0000-0002-2533-4600](https://orcid.org/0000-0002-2533-4600).

**Author contributions:** All authors contributed equally to the conception and topics for this review and to revising the article critically for intellectual content; all authors approved the final version of the manuscript for submission.

**Conflict-of-interest statement:** The authors have no conflicts of interest to declare. The authors only are responsible for the content and writing of the article.

**Open-Access:** This article is an open-access article that was selected by an in-house editor and fully peer-reviewed by external reviewers. It is distributed in accordance with the Creative Commons Attribution NonCommercial (CC BY-NC 4.0) license, which permits others to distribute, remix, adapt, build upon this work non-commercially, and license their derivative works on different terms, provided the original work is properly cited and the use is non-commercial. See: <http://creativecommons.org/License>

**Dina Zakaria Mohamed, Sally El-Sayed Abu-Risha,** Department of Pharmacology and Toxicology, Faculty of Pharmacy, Tanta University, Tanta 31511, Egypt

**Mai El-Sayed Ghoneim,** Department of Pharmacology and Toxicology, Faculty of Pharmacy, University of Sadat City, Menoufia 32632, Egypt

**Ramy Ahmed Abdelsalam,** Department of Pathology, Faculty of Medicine, Mansoura University, Mansoura 35511, Egypt

**Mohamed Abdelhalem Farag,** Department of Pediatrics, Nebru General Hospital, Nebru 35511, Egypt

**Corresponding author:** Dina Zakaria Mohamed, MSc, Assistant Lecturer, Department of Pharmacology and Toxicology, Faculty of Pharmacy, Tanta University, El-Geish Street, Tanta 31511, Egypt. [m\\_halem1986@yahoo.com](mailto:m_halem1986@yahoo.com)

### Abstract

Severe acute respiratory syndrome coronavirus 2 (SARS-CoV-2) is considered the causative pathogen of coronavirus disease 2019 (COVID-19) and has become an international danger to human health. Although respiratory transmission and symptoms are still the essential manifestations of COVID-19, the digestive system could be an unconventional or supplementary route for COVID-19 to be transmitted and manifested, most likely due to the presence of angiotensin-converting enzyme 2 (ACE2) in the gastrointestinal tract. In addition, SARS-CoV-2 can trigger hepatic injury *via* direct binding to the ACE2 receptor in cholangiocytes, antibody-dependent enhancement of infection, systemic inflammatory response syndrome, inflammatory cytokine storms, ischemia/reperfusion injury, and adverse events of treatment drugs. Gastrointestinal symptoms, including anorexia, nausea, vomiting, and diarrhea, which are unusual in patients with COVID-19, and some digestive signs may occur without other respiratory symptoms. Furthermore, SARS-CoV-2 can be found in infected patients' stool, demonstrating the likelihood of transmission through the fecal-oral route. In addition, liver function should be monitored during COVID-19, particularly in more severe cases. This review summarizes the evidence for extra-pulmonary manifestations, mechanisms, and management of COVID-19, particularly those related to the gastrointestinal tract and liver.

s/by-nc/4.0/

**Manuscript source:** Invited manuscript**Specialty type:** Gastroenterology and hepatology**Country/Territory of origin:** Egypt**Peer-review report's scientific quality classification**

Grade A (Excellent): A, A

Grade B (Very good): B, B

Grade C (Good): C, C, C

Grade D (Fair): 0

Grade E (Poor): 0

**Received:** January 15, 2021**Peer-review started:** January 15, 2021**First decision:** January 31, 2021**Revised:** February 12, 2021**Accepted:** June 7, 2021**Article in press:** June 7, 2021**Published online:** July 28, 2021**P-Reviewer:** Perisetti A, Song B, Vij M, Watanabe T**S-Editor:** Fan JR**L-Editor:** Webster JR**P-Editor:** Yuan YY**Key Words:** COVID-19; Angiotensin-converting enzyme 2; Gastrointestinal; Inflammatory bowel disease; Liver; Management

©The Author(s) 2021. Published by Baishideng Publishing Group Inc. All rights reserved.

**Core Tip:** The coronavirus disease 2019 (COVID-19) pandemic has affected millions worldwide, with high lethality. In addition to typical respiratory symptoms of COVID-19, gastrointestinal and hepatic symptoms have been frequently observed in COVID-19 patients. The main purpose of this article is to focus on the manifestations, mechanisms, and management of the gastrointestinal tract and liver that occurred during the course of COVID-19. Therefore, physicians must not undervalue the digestive symptoms during COVID-19 and rapidly adjust the treatment options for COVID-19 patients with gastrointestinal symptoms and liver enzyme abnormalities.

**Citation:** Mohamed DZ, Ghoneim MES, Abu-Risha SES, Abdelsalam RA, Farag MA. Gastrointestinal and hepatic diseases during the COVID-19 pandemic: Manifestations, mechanism and management. *World J Gastroenterol* 2021; 27(28): 4504-4535

**URL:** <https://www.wjgnet.com/1007-9327/full/v27/i28/4504.htm>

**DOI:** <https://dx.doi.org/10.3748/wjg.v27.i28.4504>

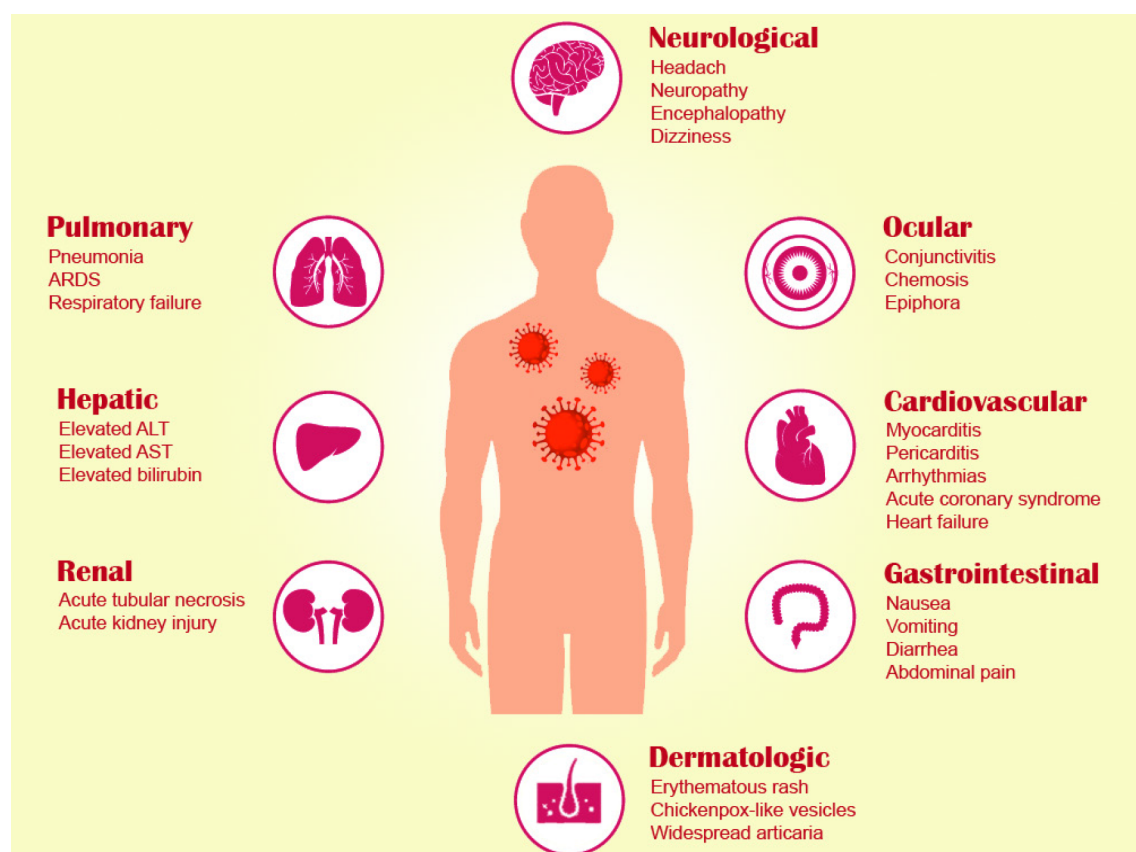
## INTRODUCTION

Coronaviruses (CoV) is the largest group of spike-like viruses in the Nidovirales family. In the last two decades the CoVs have caused three worldwide outbreaks, with the most recent pandemic caused by severe acute respiratory syndrome coronavirus 2 (SARS-CoV-2) which has resulted in coronavirus disease 2019 (COVID-19). The first 21<sup>st</sup> century outbreak in Guangdong Province, China, in November 2002, caused by SARS-CoV (SARS-CoV-1), an extreme SARS, resulted in 8098 fatalities (9.6%) globally [1,2]. The second outbreak in Saudi Arabia in 2012 was caused by Middle East respiratory syndrome (MERS)-CoV, with 2521 (36%) confirmed deaths[3].

SARS-CoV-2 first originated in China in December 2019 and critically threatened worldwide health[4,5]. On February 12, 2021, 108 million cases and 2 million deaths have been recorded in over 219 countries and regions worldwide[6]. The lung is the primary organ involved in COVID-19 pneumonia, and most COVID-19 patients suffer typical respiratory symptoms (*e.g.*, dyspnea, cough with sputum production, fatigue, and in severe cases, acute respiratory distress syndrome (ARDS), respiratory failure, and even death). On the other hand, extrapulmonary clinical manifestations of COVID-19 affect multiple other organs including cardiovascular (*e.g.*, arrhythmias, myocarditis, pericarditis, acute coronary syndrome, and heart failure), renal (*e.g.*, acute kidney injury and acute tubular necrosis), hepatic [*e.g.*, elevated alanine aminotransferase (ALT), aspartate aminotransferase (AST), and bilirubin], gastrointestinal (*e.g.*, diarrhea, nausea, vomiting, and abdominal pain), ocular (*e.g.*, epiphora, conjunctivitis, and chemosis), dermatologic (*e.g.*, erythematous rash, urticaria, and chickenpox-like vesicles), and neurological systems (*e.g.*, headache, neuropathy, encephalopathy, cerebrovascular disorders, and dizziness)[7] (Figure 1). Considering all the previously mentioned data, this article examines the effects of gastrointestinal (GI) and hepatic symptoms, their associated mechanisms, and management caused by SARS-CoV-2 infection and provides a guide for clinical prevention and treatment (Figure 2).

## DISEASE COURSE OF COVID-19

For SARS-CoV-2, the incubation period is an average of 4-5 d, with most patients having symptoms before 14 d, although there have been instances where the incubation period was longer[8]. The infection and hospitalization onset was documented from 9.1 to 12.5 d and emphasizes the difficulty in the early stage of the diagnosis and isolation of populations[9]. The average period for recovering patients from initial symptoms is 22 d, and for those who succumbed the time to death is approximately



**Figure 1 Pulmonary and extrapulmonary manifestations of coronavirus disease 2019.** ARDS: Acute respiratory distress syndrome; ALT: Alanine aminotransferase; AST: Aspartate aminotransferase. Headache and urticaria spelled wrongly.

18.5 d[9].

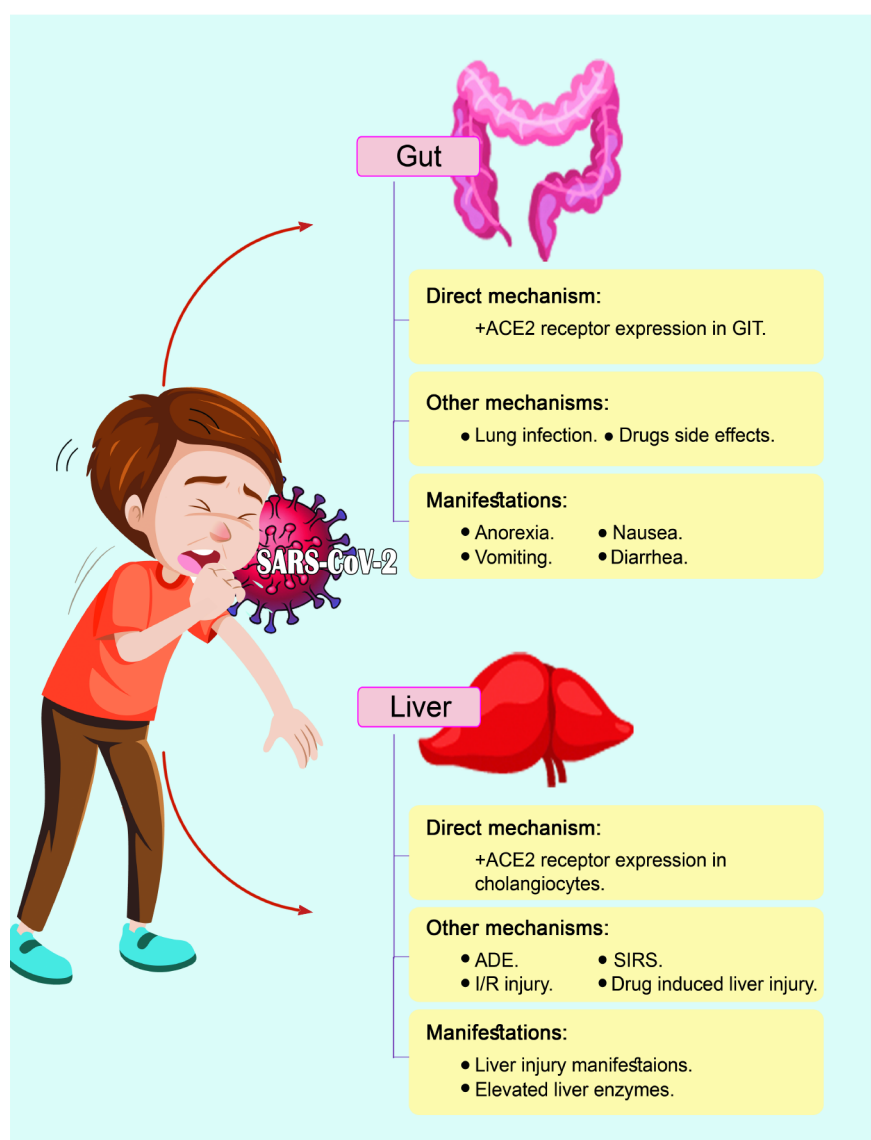
Overall, the case fatality ratio of COVID-19 is reported to be around 1-2% in patients aged 80 years, to over 15%[10]. Currently, WHO data show that most COVID-19 cases have mild to moderate signs of illness (80%), and 13.8% of cases have serious signs within 24-48 h with the following symptoms: shortness of breath; hypoxia < 300% and/or pulmonary infiltration > 50%; tachypnea > 30 breaths/min[11]. 6.1% of patients with critical infections also have septic shock, respiratory and multiple-organ failure[11,12]. Approximately 25% of hospitalized patients require intensive care unit (ICU) care, and 4.3% die[12].

## GENDER AND RACE DURING COVID-19

It has been demonstrated that 51% of reported cases of COVID-19 are male patients. This may be due to the higher levels of estrogen in female COVID-19 patients which can reduce COVID-19 severity and mortality *via* the elevation in innate and humoral immunity[13-19]. Moreover, *in vivo* studies have demonstrated that there are higher levels of angiotensin-converting enzyme 2 (ACE2) expression in male kidneys than in female kidneys, which may explain the differences in the susceptibility and development of COVID-19 between male and female patients.

Whether ACE2 expression varies in the lungs of male and female COVID-19 patients, is still unclear[20,21]. Furthermore, preclinical trials have suggested that ACE2 expression may increase vulnerability to COVID-19 in pregnant patients[22,23].

In the same way, COVID-19 varies between different ethnic groups in terms of severity and mortality. During the COVID-19 pandemic, American, Hispanic, and African communities have displayed higher rates of infection and hospitalization in comparison to Caucasian communities[24]. These discrepancies may be due to the higher occurrence of heart diseases, hypertension, obesity, diabetes, and asthma in minority groups[24].



**Figure 2 Mechanisms and manifestations of coronavirus disease 2019 in the gut and liver.** SARS-CoV-2: Severe acute respiratory syndrome coronavirus 2; ACE2: Angiotensin-converting enzyme 2; GIT: gastrointestinal tract; ADE: Antibody-dependent enhancement of infection; SIRS: Systemic inflammatory response syndrome; I/R: Ischemia and hypoxia reperfusion injury.

## GASTROINTESTINAL SYMPTOMS AND COVID-19

### GI manifestations in COVID-19 patients

Gastrointestinal symptoms including, nausea, anorexia, vomiting, diarrhea, and abdominal pain are common in COVID-19 patients (Table 1)[12,25-35]. In the SARS infection of 2002-2003, diarrhea was the main feature and appeared in 16%-73% of SARS patients mainly in the first week of infection[36]. Similarly, diarrhea is considered a common digestive sign in COVID-19 patients, with an incidence of 1.3%-29.3%. However, the criteria for the diagnosis of diarrhea may be different in various hospitals, and its prevalence varied in different studies[37].

Among 204 COVID-19 patients in Hubei China, only 99 (48.5%) had gastrointestinal signs as their chief complaint. These COVID-19 patients had a diversity of digestive symptoms, including abdominal pain (0.4%), anorexia (83.8%), diarrhea (29.3%), and vomiting (0.8%)[38]. A retrospective study conducted by Guan *et al*[39] reported that among 1099 COVID-19 patients from 552 centers across China, 5% of cases had nausea and vomiting, and 3.8% of cases had diarrhea. A further study indicated that 32.5% of COVID-19 patients had at least one gastrointestinal tract (GIT) symptom. These symptoms included diarrhea (37.8%), anorexia (56.7%), abdominal pain (10.4%), nausea (16.5%), and vomiting (7.9%)[40]. Additionally, Luo *et al*[41] documented that 16% of 1141 cases, had at least one GIT symptom including, anorexia (98%), nausea, vomiting (66%), diarrhea (37%), and abdominal pain (25%). Furthermore, a research

**Table 1 Incidence of common gastrointestinal symptoms in patients with severe acute respiratory syndrome coronavirus 2 infection**

Ref.	Patient number	Anorexia, nausea or vomiting, <i>n</i> (%)	Diarrhea, <i>n</i> (%)	Abdominal pain, <i>n</i> (%)
Kujawski <i>et al</i> [207], 2020	12	Nausea: 3 (25)	4 (33.3)	2 (16.7)
Hajifathalian <i>et al</i> [44], 2020	1059	Anorexia: 240 (22.7) Nausea: 168 (15.3) Vomiting: 91 (8.6)	234 (22.1)	72 (6.8)
Young <i>et al</i> [208], 2020	18	NA	3 (17)	NA
Tabata <i>et al</i> [209], 2020	104	NA	8 (9.6)	NA
Wölfel <i>et al</i> [210], 2020	9	NA	2 (22)	NA
Chen <i>et al</i> [26], 2020	99	Nausea and vomiting: 1 (1)	2 (2)	NA
Xu <i>et al</i> [27], 2020	62	NA	3 (8)	NA
Gritti <i>et al</i> [211], 2020	21	NA	5 (23.8)	NA
COVID-19 National Incident Room Surveillance Team[212]	295	Nausea: 34 (11.5)	48 (16.3)	6 (1)
COVID-19 National Emergency response Center[213]	28	NA	2 (7)	1 (4)
Sierpiński <i>et al</i> [214], 2020	1942	NA	470 (24.2)	NA
Wu <i>et al</i> [28], 2020	80	Nausea and vomiting: 1 (1.25)	1 (1.3)	NA
Wang <i>et al</i> [12], 2020	138	Anorexia: 55 (39.9) Nausea: 14 (10.1)	14 (10.1)	3 (2.2)
Shi <i>et al</i> [29], 2020	81	Anorexia: 1 (1) Vomiting: 4 (5)	3 (4)	NA
Yang <i>et al</i> [30], 2020	50	Vomiting: 2 (4)	NA	NA
Mo <i>et al</i> [31], 2020	155	Anorexia: 26 (31.7) Nausea: 3 (3.7) Vomiting: 3 (3.7)	7 (4.5)	NA
Qi <i>et al</i> [215], 2020	267	Anorexia: 46 (14.2) Nausea: 6 (2.2)	10 (3.7)	NA
Wen <i>et al</i> [216], 2020	417	NA	29 (7)	NA
Dan <i>et al</i> [217], 2020	305	Anorexia: 101(50.2) Nausea: 59 (29.4) Vomiting: 3 (2)	146 (49.5)	12 (6)
Ma <i>et al</i> [218], 2020	81	NA	6(7.41)	NA
Luo <i>et al</i> [41], 2020	1141	Anorexia: NA Nausea: 134 (11.7) Vomiting: 119 (10.4)	68 (6)	45 (3.9)
Liu <i>et al</i> [219], 2020	238	Anorexia: 14 (9.2) Nausea: 2 (1.3) Vomiting: 3 (2)	14 (9.2)	1 (0.7)
Ai <i>et al</i> [220], 2020	102	Anorexia: NA Nausea: 9 (8.8) Vomiting: 2 (2)	15 (14.3)	3 (2.9)
Zhao <i>et al</i> [221], 2020	75	NA	7 (9.3)	1 (1.3)



Li <i>et al</i> [222], 2020	83	NA	7 (8.4)	7 (8.4)
Lin <i>et al</i> [223], 2020	95	Anorexia: 17 (17.8) Nausea: 17 (17.9) Vomiting: 4 (4.2)	23 (24.2)	2 (2.1)
Cholankeril <i>et al</i> [224], 2020	207	Anorexia: NA Nausea: 22 (10.8) Vomiting: NA	22 (10.8)	14 (7.1)
Ferm <i>et al</i> [43], 2020	892	Anorexia: 105 (11.8) Nausea: 148 (16.6) Vomiting: 91 (10.2)	177 (19.8)	70 (7.8)
Redd <i>et al</i> [225], 2020	318	Anorexia: 110 (34.8) Nausea: 84 (26.4) Vomiting: 49 (15.4)	107 (33.7)	46 (14.5)
Kluytmans <i>et al</i> [226], 2020	86	NA	16 (18.6)	5 (5.8)

SARS-CoV-2: Severe acute respiratory syndrome coronavirus 2; NA: Not applicable; COVID-19: Coronavirus disease 2019.

study conducted by Jin *et al*[42], which was the first COVID-19 study outside Wuhan, reported that the incidence of GIT symptoms was 11.4%; diarrhea was the most common of these symptoms (8.14%)[42].

In New York, GIT symptoms have been identified in a single-center-case series, which included 892 cases. The most common symptom was diarrhea (19.8%), accompanied by nausea (16.6%), abdominal pain (7.8%), vomiting (10.2%), and anorexia (11.8%)[43]. An additional retrospective study conducted in New York showed that of 1059 COVID-19 patients, 22% had diarrhea, 6% had nausea, 19% had vomiting, and 7% had abdominal pain[44]. In addition to these studies, the pooled prevalence of GI symptoms was found to be 17.6 % in a meta-analysis of 60 studies involving 4243 cases in 6 countries. The most frequent symptom was anorexia (26.8%), accompanied by diarrhea (12.5%), nausea/vomiting (10.2%) and stomach pain/discomfort (9.2%)[45].

Furthermore, Goyal *et al*[46] indicated that hyperlipidemia was found in 11.7% of patients affected by SARS-CoV-2 where 92 patients out of 756 with COVID-19, had elevated serum lipase levels, resulting in acute pancreatitis. Therefore, COVID-19 patients with hyperlipidemia have an approximately 3-fold higher risk of poor clinical outcomes, including the need for ICU admission, mechanical ventilation, and death [46].

The study by Gadiparthi *et al*[47] showed that the higher Glasgow Blatchford bleeding score was 7 and 11 in 2 of 3 patients on admission and represents a high risk of gastrointestinal bleeding (GIB) with a need for intervention of more than 50%. However, both young patients responded by carefully controlling hemodynamic parameters, levels of hematocrit or hemoglobin, transfusion of packed red blood cells as needed and medical therapy. Although GIB was resolved, two patients died due to respiratory failure[47].

Besides GIT symptoms, autopsies of COVID-19 patients showed that there are gross and microscopic changes in the GIT. Segmental dilation and stenosis of the small intestine, accompanied by mucosal shedding and necrosis was described at autopsy, whereas colitis, inflammatory infiltrates, and interstitial edema, were found on histopathology imaging[48,49]. Lui *et al*[50] have shown pneumatosis, intestinalis, pneumoperitoneum, ascites, and thickening bowel wall in addition to ileus on abdominal imaging. Therefore, abnormalities of the GIT can be obvious on imaging.

Based on these previous data, physicians must realize that the key characteristics of COVID-19 infection before respiratory symptoms may be digestive symptoms and, in rare instances may be the only COVID-19 symptoms to occur.

### **Mechanisms of GI injury during COVID-19**

**Direct infection of gastrointestinal cells:** The entry of SARS-CoV-2 virus into host cells is the main part of cross-species transmission. All coronaviruses bind to receptors



and mediate their entry *via* glycoprotein and spike proteins[51]. It has been recognized that ACE2 mainly contains receptors for SARS-CoV[52], and dipeptidyl peptidase 4, for MERS-CoV[53]. A plethora of studies has shown that the spike (S) protein of SARS-CoV-2 has a high host ACE2 affinity[54], and enters host cells *via* the ACE2 receptor [55] as shown in Figure 3.

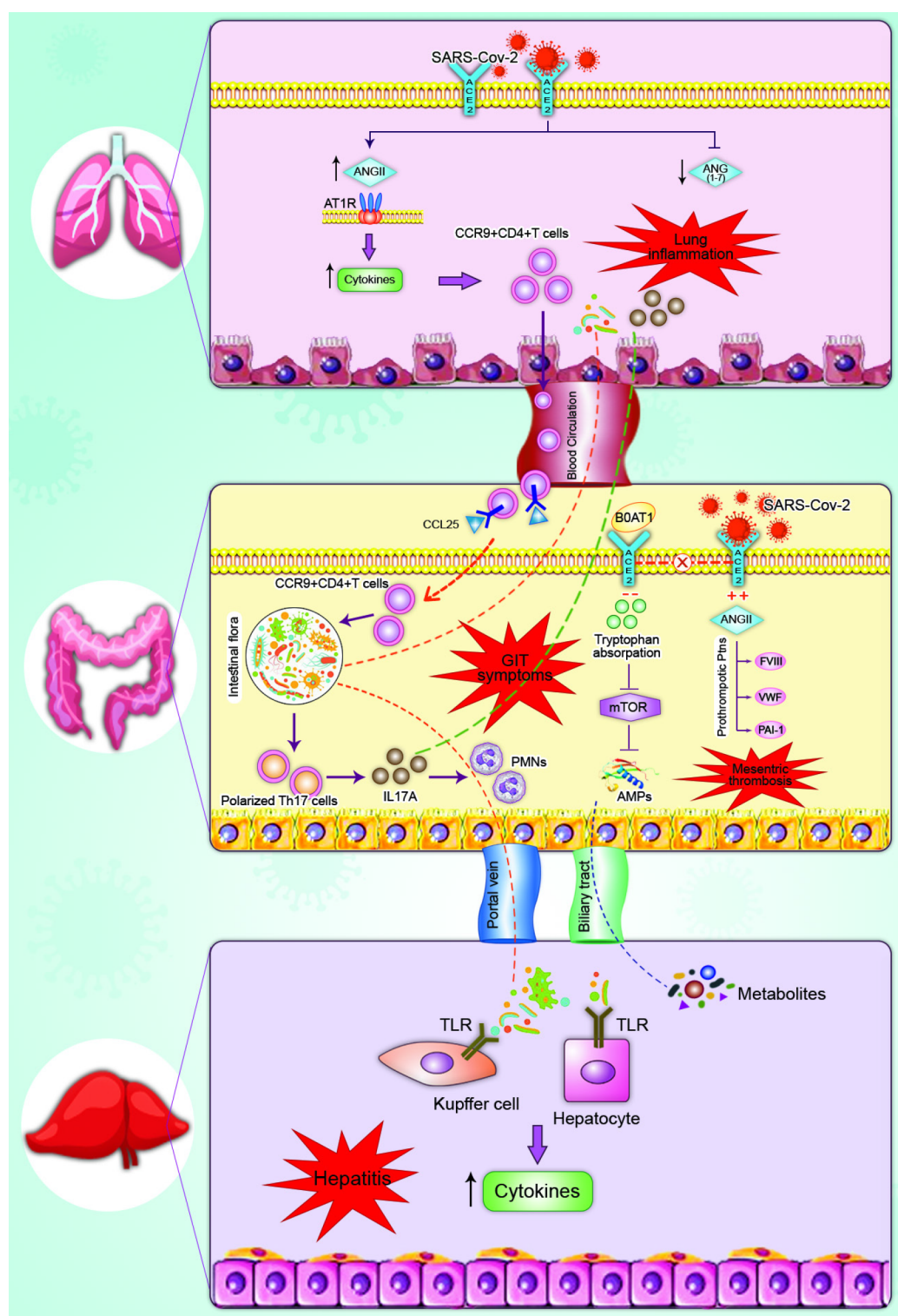
In small intestine cells, ACE2 is usually located and strongly expressed in type II epithelial cells[56,57]. It is considered an important enzyme in the renin-angiotensin system (RAS)[58,59] and plays an essential role in controlling inflammation and diarrhea[60]. Moreover, its deficiency leads to the accumulation of angiotensin II (ANG II)[61]. Subsequent studies[12,62-64] have proven that SARS-CoV-2, in COVID-19 patients, may invade the GIT *via* ACE2 receptors, causing digestive symptoms. It is now well acknowledged that the significant upsurge of ANG II level in COVID-19 patients is the cause of progression and severity of the disease.

Although in the mouse colon, the knockdown of ACE2 by the virus leads to an upsurge of ANG II levels; ACE2 does not primarily act *via* the intestinal RAS system but controls the homeostasis of intestinal amino acids, gut microbes and the expression of antimicrobial peptides[65]. Mice with blocked ACE2, for example, have significantly inhibited serum tryptophan that is important to the body's niacin synthesis[66], therefore, inadequate intake of tryptophan or niacin results in pellagra[65]. It is well-recognized that tryptophan is absorbed on the lumen surface of intestinal epithelial cells *via* the B0AT1/ACE2 transport route and induces the mammalian target of rapamycin, which controls the consequently appearance of antimicrobial peptides, thereby having a direct influence on components of intestinal flora[65]. Ultimately, more than 90% of pellagra patients will develop colitis[67]. Hence, it is considered that SARS-CoV-2 attachment to the ACE2 in the GIT lowers the critical receptor level, disrupting the absorption of tryptophan and ultimately destroying the steady-state of the gut flora, resulting in diarrhea.

Furthermore, He *et al*[68] demonstrated that the pathological results of autopsies on COVID-19 patients indicated that proinflammatory cytokines (PICs) such as tumor growth factor- $\beta$ 1, monocyte chemokine-1 (MCP-1), tumor necrosis factor- $\alpha$  (TNF- $\alpha$ ), interleukin (IL)-1 $\beta$ , and IL-6 were highly expressed in ACE2-expressing cells. There is an absence of PICs in cells that do not express ACE2. Numerous PICs produce the cytokine storm, which finally leads to multiple organ failure. Besides, plasma IL-2, recombinant human interferon (IFN)-induced protein-10, MCP-1, macrophage inflammatory protein-1A, IL-7, granulocyte colony-stimulating factor, IL-10, and TNF- $\alpha$  levels in COVID-19 patients were higher than those in healthy people[25]. Dendritic cells and macrophages show low levels of IFN and high levels of PICs and chemokines in the early stage of SARS-CoV infection[69-71]. Later, there is a rise in cytokine and chemokine levels, which causes severe tissue damage due to the large number of inflammatory cells, such as neutrophils and monocytes. In the same manner, SARS-CoV-2 can induce cells expressing ACE2 to release inflammatory cytokines, leading to the cytokine storm and multiple organ failure[72]. Furthermore, cytokine storms can have an effect on immune cells; lymphocytosis is known to be a common sign in severe cases of COVID-19, with a significant decline in the number of B, CD8+ and CD4+T cells as well as natural killer cells, which leads to lymph node necrosis, spleen atrophy, hepatomegaly, renal hemorrhage, necrosis, and degeneration of neurons[73].

Thromboembolic complications are being increasingly documented in COVID-19 [74]. Acute mesenteric ischemia (AMI) has been reported in severe COVID-19 patients in addition to deep venous thrombosis and pulmonary embolism[75]. It has been demonstrated that ANG II stimulates the expression of tissue factor VIII (FVIII), von Willebrand factor, and plasminogen activator inhibitor-1 by endothelial cells, resulting in a state of hypercoagulation[76,77]. Histology of the small intestine secondary to mesenteric thrombosis revealed a prominent endothelium of the submucosa with evidence of direct viral invasion of endothelial cells along with diffuse endothelial swelling with mononuclear cell infiltrate. It is understood that there is stimulation of alternate and lectin complement trajectories [C5b-9 (membrane attack complex), C4d, and mannose-binding protein-associated serine protease 2] that destroy endothelial cells[78]. SARS-CoV-2 infection also resulted in an elevation of ANG II levels and other prothrombotic proteins, which led to AMI[78-81].

**Gastrointestinal damage caused by lung infection:** Any change in intestinal flora constituents affects the respiratory tract, *via* the common mucous immune system. Reciprocally, any damage to the respiratory tract mainly affects the digestive tract *via* immune regulation. This effect is known as the "gut-lung axis"[82,83]. Furthermore, SARS-CoV-2 cannot be detected in the stools of COVID-19 patients with digestive symptoms and thus GIT symptoms may not be affected by the direct damage caused



**Figure 3 Mechanism of gastrointestinal symptoms in patients with coronavirus disease 2019.** (1) Gut-lung axis: Severe acute respiratory syndrome coronavirus 2 (SARS-CoV-2) binds with angiotensin-converting enzyme 2 (ACE2) to enter the lung, which leads to the accumulation of angiotensin II (ANG II) and the reduction of Angiotensin (1-7). ANG II combined with angiotensin 1 receptor stimulates cytokine release and causes an upsurge of C-C chemokine receptor type 9 (CCR9) CD4T cells. Chemokine (C-C motif) ligand 25 subsequently enhances the recruitment of CCR9 CD4T cells into the small intestine. The changing flora then stimulates the polarization of T helper 17 cells, and eventually, interleukin 17A induces the recruitment of neutrophils. Cytokines and intestinal bacteria also enter the lung through the bloodstream, further affecting lung inflammation; and (2) Gut-liver axis: SARS-CoV-2 binds with ACE2 to enter the intestine, prevents absorption of the B0AT1/ACE2 transport pathway, and then decreases the stimulation of mammalian target of rapamycin to diminish the expression of antimicrobial peptides which result in gastrointestinal tract symptoms or enhanced ANG II that leads to the upregulation of tissue factor VIII, Von Willebrand factor, and plasminogen activator inhibitor-1 expression by endothelial cells resulting in mesenteric thrombosis. The intestinal flora, through the portal vein, is transferred to the liver, where it binds to toll-like receptors resulting in hepatitis. Additionally, the liver, can transport metabolites to the intestine via the biliary tract. COVID-19: Coronavirus disease 2019; SARS-CoV-2: Severe acute respiratory syndrome coronavirus 2; ACE2: Angiotensin-converting enzyme 2; ANG II: Angiotensin II; Ang1-7: Angiotensin (1-7); AT1R: Angiotensin 1 receptor; CCR9: C-C chemokine receptor type 9; CCL25: Chemokine (C-C motif) ligand 25; Th17: T helper 17; IL-17: Interleukin 17; PMNS: Neutrophils.

Polymorphonuclear neutrophils; B0AT1: Sodium-dependent neutral amino acid transporter; mTOR: Mammalian target of rapamycin; AMPs: Antimicrobial peptides; FVIII: Tissue factor VIII; VWF: Von Willebrand factor; PAI-1: Plasminogen activator inhibitor-1; TLR: Toll-like receptor.

by SARS-CoV-2. The entry of CD4<sup>+</sup> T cells is essential to immunity and chronic enteritis in the intestinal mucosa. It is known that C-C chemical receptor type 9 (CCR9) is an important chemical receptor for the introduction of CD4<sup>+</sup>T cells into small gut cells [84]. Wang *et al* [84] showed after viral infection, that CCR9<sup>+</sup> CD4<sup>+</sup> T lung derived cells were amplified. The small intestinal epithelium can include chemokine (C-C motif) ligand 25 [85], which promotes the recruitment of CCR9<sup>+</sup> CD4<sup>+</sup> T cells into the small intestine [86], which leads to impairment of the gut's immune system and to destruction of intestinal flora homeostasis. This, in turn, stimulates the polarization of T helper 17 (Th17) cells in the intestine, and recruitment of neutrophils due to the production of large amounts of IL-17A [87], causing diarrhea, intestinal immune damage, and other gastrointestinal symptoms. Inflammation in the intestine may lead to the entry of intestinal flora and cytokines into the lung through the bloodstream, which affects the lung immune system [88]. Additionally, bacterial imbalance and intestinal mucosal damage can affect the gut-liver axis. In the intestine, host metabolites are transported through the portal vein to the liver and affect the function of the liver. The liver releases bioactive contents and bile acids and transfers them into the intestines through the systemic circulation [89]. This may lead to liver dysfunction in COVID-19 patients, due to these abnormalities [90] (Figure 3).

**Gastrointestinal symptoms caused by drug side effects:** Diarrhea due to antibiotics is the most common unwanted side effect of antimicrobial agents, including cephalosporins, macrolides and  $\beta$ -lactams. A retrospective study, in China, demonstrated that 260 COVID-19 patients treated with macrolides, fluoroquinolones, and cephalosporins resulted in 24.2% of patients developing diarrhea [91]. Another study of 138 patients with SARS-CoV-2 found that 38% had diarrhea with a medium period of 3-7 d during treatment [92]. The abovementioned data indicate that the early use of large quantities of antimicrobial agents could be linked to symptoms of diarrhea during COVID-19. Similarly, the prevalence of diarrhea in patients treated with antiviral agents such as oseltamivir is about 55.2% [93]. Other antiviral agents which can cause diarrhea as an adverse effect during the management of COVID-19 include lopinavir, chloroquine phosphate, remdesivir, and Chinese patent medicines (*e.g.*, lianhuaqingwen capsules) [94]. Additionally, treatment with broad-spectrum antibiotics is a major risk factor for *Clostridium difficile* infection, which is considered the primary reason for nosocomial diarrhea [95]. It is unclear whether the above-mentioned factors including, the use of antibiotics or antiviral agents and increased gut inflammation along with a decrease in mammalian target of rapamycin (mTOR) activity, and antimicrobial peptides, are partly responsible alone or in combination for causing diarrhea in patients infected with COVID-19 *via* alterations in the gut flora [96].

Proton pump inhibitors (PPIs) are mainly used as a therapy for patients with peptic ulcers and gastroesophageal reflux disease. By blocking the proton pump, PPIs decrease gastric acid released into the stomach. Although the decrease in stomach acid can be beneficial in patients with stomach diseases, it can make the gut more susceptible to COVID-19 infection [97-99]. SARS-CoV S protein was suggested to fuse with patients' cells in neutral pH conditions. Additionally, Darnell *et al* [100] also established that highly acidic pH (1-3) and alkaline pH (12-14) may lead to inactivation of SARS-CoV, while, in the case of neutral pH, the virus remains stable [101]. Zhou *et al* [102] reported that, under the conditions of pH 1.0 and 2.0, SARS-CoV-2 was inactivated and unable to infect cells which was related to the pH in an empty stomach by creating viruses pseudotyped with SARS-CoV-2 S protein. In addition, the study by Ramachandran *et al* [103] found that prehospitalization PPI-exposed patients had worse clinical outcomes, involving mortality of COVID-19 patients, irrespective of the existence of cardiovascular diseases. A possible explanation for this is that secretions in the stomach are in the pH range 1.0 to 3.5, while the pH in the small and large bowels ranges from 7.5 to 8.0. SARS-CoV-2 can cause gastric acid to inactivate most virus particles. If a person has a long period of acid suppression with PPIs, the pH in the stomach decreases. SARS-CoV-2 can also have a higher rate of entry in the gut, which leads to viral infection.

### COVID-19 and pre-existing digestive diseases

In general, the existence of comorbidities is associated with dramatically low outcomes

in COVID-19 patients. This may cause consequences for the management of previous gastrointestinal patients[104]. Patients that have inflammatory bowel disease (IBD) and have been treated with immunosuppressive drugs are more at risk for regular and serious infections and may be more at risk for SARS-CoV-2 infection[105]. It was reported in the IBD registry in Wuhan that none of 318 patients (204 patients with ulcerative colitis and 114 patients with Crohn's disease) had been infected with SARS-CoV-2 following precautions for COVID-19 control and prevention[106]. Thus, the use of biologics and immunosuppressants, diet therapy, deliberate postponement of elective and endoscopic surgery and provisions for personal safety are recommended [107].

**Considerations and management of IBD medications during COVID-19 infection:** It is currently not recommended that IBD patients stop immunosuppressant drugs[11]. This is because there is a risk of disease reactivation in patients who discontinue their treatment, leading to severe inflammation, surgery, increased risk of hospitalization, and infection[108,109]. Non-hormonal anti-inflammatory drug use should be prohibited as the adverse effects of viral respiratory infections have been associated with triggering the reactivation of IBD[110].

No evidence-based recommendations for immunosuppressed patients have been made by clinical parties. Table 2 shows the specific considerations for the treatment of IBD patients mainly based on specialist beliefs. These suggestions can be edited and updated as new evidence emerges[108,110]. Overall, the same therapies can be used by patients with moderate to serious Crohn's disease or ulcerative colitis, regardless of COVID-19 infection[110]. IBD therapies can be restarted after 14 d for asymptomatic IBD patients with SARS-CoV-2 infection whose therapy has been stopped[110].

It is noteworthy that IBD patients should discontinue immunosuppressant drugs until COVID-19 is resolved, and medications can be resumed after complete resolution of COVID-19 symptoms or after two negative polymerase chain reaction (PCR) tests [111].

**IBD surgery in the context of the COVID-19 pandemic:** The new strain of coronavirus has increased the risk of severe pulmonary infection and extended hospitalization for IBD patients waiting for surgery, which is critical for IBD immunosuppressed patients. A recent report in Wuhan, China, demonstrated that 34 patients who underwent elective surgical procedures during the COVID-19 incubation period, developed COVID-19 pneumonia after surgery; 44.1% of patients were admitted to the ICU, and 20.5% of patients died[112]. Therefore, the majority of physicians have recommended postponing both elective and endoscopic surgery to protect patients and healthcare personnel and to minimize the usage of healthcare services and use personal protection equipment[113,114]. Eventually, the ultimate goal is to ensure the safety of patients and health care workers.

### COVID-19 and the fecal-oral transmission route

A number of articles have disclosed that SARS-CoV-2 RNA can be found in patients' stool, suggesting that SARS-CoV-2 has the ability to be transmitted *via* the fecal-oral route[115-117]. It has been demonstrated that some COVID-19 patients had positive fecal but negative PCR tests[118]. Wang *et al*[117] revealed that of 153 (29%) patients with COVID-19, 44 showed positive stool virus. Moreover, Xiao *et al*[49] indicated that of 73 COVID-19 patients hospitalized in China, 39 (53.42%) showed SARS-CoV-2 RNA in stools[49]. Surprisingly, stool samples were positive in 17 (23.29%) patients but respiratory samples were negative and the period of positivity ranged from 1 to 12 d in stools. Xiao *et al*[49] demonstrated that infectious SARS-CoV-2 may be secreted from virus-infected gastrointestinal cells. Therefore, stool samples should be frequently tested using real-time-PCR and transmission-based precautions should be taken into consideration[119].

Furthermore, the probability of SARS-CoV-2 fecal-oral transmission has highlighted the importance of adequate hand hygiene, especially in certain areas. Strict measures must be taken to deal with the stools of COVID-19 patients and the sewage from hospitals. Therefore, patients with preexisting gastrointestinal diseases will be more worried when they are infected with SARS-CoV-2 in addition to potential fecal microbiota transplant donors.

### Pharmacologic management of GI symptoms in COVID-19

**Microecological preparation:** The intestinal flora generates various vitamins, bile acids, immune factors, and fatty acids *via* the decomposition of food and participates in immune system regulation[120]. If there is dysfunction or damage in the intestinal



**Table 2** Therapy-specific considerations for inflammatory bowel disease patients

Drug	Effects
Aminosalicylate acid derivatives (5-ASA)	No proof of increased risk of COVID-19 infection Continue treatment even in the case of COVID-19 infection
Corticosteroids	Their safety during COVID-19 infection is uncertain They can be used at a low dose and for a short period to treat disease relapses Discontinue as soon as possible Ileo-cecal CD patients can be treated with Budesonide; IUC patients can be treated with Budesonide MMX
Immunomodulators (Thiopurines and Methotrexate)	No proof of increased risk of COVID-19 infection Accompanied by increased risk of other viral infection Not recommended to start with monotherapy Combination therapy with biologics should be maintained Recommendations in stopping Stable disease Sustained reduction in the case of elderly patients and/or significant comorbidities Symptom progression of COVID-19 infection
Anti-TNF therapy	No proof of increased risk of COVID-19 infection Infusion and dose intervals should be maintained Starting with monotherapy (adalimumab or certolizumab) Stop in the case of developing symptoms of COVID-19
Anti-IL-12/23p40 therapy (Ustekinumab)	No proof of increased risk of COVID-19 infection Monotherapy is recommended Stop in the case of developing symptoms of COVID-19
Anti-α4β7 integrin therapy (Vedolizumab)	No proof of increased risk of COVID-19 infection Monotherapy is recommended Stop in the case of developing symptoms of COVID-19
Janus Kinase inhibitors (tofacitinib)	Although there is no proof of increasing the risk of COVID-19 infection, it may inhibit the immune reaction against viral infections Starting is not recommended Therapy should be maintained without elevating the dose Stop if symptoms of COVID-19 develop

UC: Ulcerative colitis; CD: Crohn's disease; COVID-19: Coronavirus disease 2019; TNF: Tumor necrosis factor; IL: Interleukin.

flora and/or mucosa, the virus may further stimulate infection through this pathway. Other studies have stated that probiotics have the availability to manage diarrhea caused by rotavirus[121]. Also, lactic acid bacteria and Bifidobacteria can contribute to antiviral antibodies in the human body, accelerating virus removal. Therefore, probiotic treatments and/or antiviral drugs, and antibacterial drugs may enhance the symptoms of SARS-CoV-2 diarrhea. Regarding the diagnosis and treatment protocols of COVID-19 in China, the use of intestinal flora regulators is preferred to preserve the intestinal micro-environmental balance and avoid secondary bacterial infection[122].

**ACE2 inhibitors:** As previously mentioned, ACE2 binds SARS-CoV-2 in cells. Therefore, to avoid SARS-CoV-2 infection the interaction between the receptor connection domain (RBD) of the virus and ACE2 could be blocked. A number of studies have shown that ACE2 inhibitors can regulate bowel metabolism, innate immunity, secretion of antibacterial peptides, and intestinal microbial homeostasis [122]. It was experimentally confirmed that the ACE2 pathway in epithelial cells of the small intestine trigger mTOR *via* nutrient stimulation and/or the tryptophan-nicoti-

namide pathway, thus affecting the composition of intestinal flora, and decreasing GIT indications in mice[60]. Azathioprine is an immunosuppressive agent similar to chloroquine. A recent study evaluated azathioprine and found that it could be regarded as an ACE2 inhibitor[123]. Additionally, *in vitro* studies have shown that Vaccinia virus can be inhibited by azathioprine[124]. With regard to molecular immunity, azathioprine competitively binds to ACE2, using a single chain (ScFv) antibody fragment attached to ACE2 or SARS-CoV-2, *via* the RBD. Thus, the human recombinant ACE2 antibody Fc segment bound by the S protein works by inhibiting attachment of the virus to ACE2[55]. It has been documented that a combination of Chinese medicines (*e.g.*, baicalin in the Chinese medicine *Scutellaria baicalensis*, scutellarin in *Erigeron breviscapus*, hesperetin in lime and orange peel, glycyrrhizin in liquorice, and nicotinamide in soybean) and ACE2 resulted in the prevention of SARS CoV-2 infection.

**Diet and enteral nutrition:** A number of COVID-19 patients have significant anorexia. To ensure effective therapy, the basic energy, absorption, enteral and peristalsis movement of the intestine, and normal function of GIT micro-organisms and mucosal immunity should be taken into account as well as the functioning of the GIT and patients' nutrition[94]. Nutritional risk assessment should be performed in patients with serious COVID-19 and gastrointestinal symptoms[125]. Once the risk of enteral nutrition has been eliminated, enteral nutrition should immediately be restored. If the patient has a gastrointestinal disorder and cannot withstand enteral nutrition, parenteral nutrition should be supplemented with a sufficient supply of energy. Patients in poor condition can be given digestive enzymes[125]. A nasogastric tube can be used for enteral feeding in patients who have undergone mechanical ventilation and are unable to take food orally. A nasal jejunal tube can be inserted when patients are at high risk of reflux aspiration or cannot handle nasogastric tube feeding. Generally, the patient gastrointestinal tolerability should be estimated appropriately and the enteral nutrition program correspondingly adjusted.

## LIVER AND COVID-19

### ***Clinical manifestations and pathological changes in hepatic injury in patients with COVID-19***

Hepatic injury is a frequent adverse event in both SARS-CoV and Middle East respiratory coronavirus-infected patients and is associated with the severity of disease [126]. A substantial systematic analysis of 11 studies assessing the liver laboratory parameters of 2541 patients with COVID-19 showed increased AST and/or ALT (25%), lactate dehydrogenase (20%), bilirubin (3%) and normal alkaline phosphatase (ALP) [127]. This may indicate minimal direct liver damage caused by ACE2 overexpression in cholangiocytes. A major published study of 5700 patients found that AST and ALT were increased in COVID-19 patients by 58.4% and 39.0%, respectively[128]. Cai *et al* [129] showed that in 41% of patients, gamma-glutamyl transferase (GGT) was increased more than  $3 \times$  ULN, while, another research study demonstrated that GGT was raised in severe cases, but without an elevation in ALP[126].

Data from a preprint meta-analysis involving 20 retrospective studies and 3428 COVID-19 patients showed that increased levels of COVID-19 were related to significant increases in the levels of ALT, AST, and bilirubin[130]. Recently, a plethora of studies reported increased serum ALT, AST, and GGT levels in severe compared with mild or non-severe COVID-19 patients[39,131]. A recent meta-analysis associated high marker admission levels with patient mortality[132]. Other studies have shown that the increase in these parameters resulted in a worse pulmonary computed tomography (CT) score[133], increased numbers of ICU patients[12] and longer hospital stays[134]. In patients who died due to COVID-19, the incidence of elevated liver parameters ranged from 58.06% to 78%[32,135].

According to a study conducted by Lei *et al*[132], AST was the first indicator to be considered high when patients were admitted to hospital and was correlated with the highest COVID-19 death rates. A recent study carried out by Guan *et al*[39], around 1100 Chinese patients reported elevated levels of serum AST and ALT of 18% and 26% in non-severe COVID-19 patients, respectively, compared with 56% and 28% in severe COVID-19 patients. Previous findings revealed the crucial role of immune-mediated systemic inflammation in liver dysfunction in patients with serious COVID-19[9]. Recently, Gordon *et al*[136] proposed that mitochondrial proteins may interact directly



with the virus, providing a cause for the high level of AST in the liver profile[136]. Wang *et al*[137] also identified anomalies in liver enzymes, higher radiologic scores as well as a partial pressure differential between alveolar arterial oxygen, higher GGT, disease intensity, higher ferritin, lower CD4+ T and B cells and lower albumin. It is considered that total bilirubin, AST/ALT, and ALT/ALP ratios have helped to predict survival in cirrhotic COVID-19 patients[138]. Serum albumin levels were also markedly lower in patients who died of COVID-19[32]. The adverse path of COVID-19 patients has been shown to include elevated serum levels of IL-6, ferritin, procalcitonin, and C-reactive protein. In addition to reduced albumin content and platelet count, the parallel increase in the level of ferritin, ALT and IL-6 indicates a greater role for liver participation in COVID-19[32,134]. The CT imaging score for pulmonary lesions is known as a hepatic injury indicator. Therefore, patients must undergo careful monitoring of liver function in order to identify any liver insults at an early stage[133]. The incidence of hepatic abnormalities in COVID-19 patients are depicted in Table 3.

Morphological findings regarding the interpretation and description of liver parenchymal changes accompanying COVID-19 are rare, and most are seen at autopsy. It is noteworthy that the first autopsy liver specimen examinations carried out by Xu *et al*[139] showed moderate microvesicular steatosis and both portal activity and mild lobular activity. SARS-CoV-2 infection or drug-related hepatic damage may result in this liver insult. These results matched with those of Liu *et al*[140]. Preliminary research, consisting of 49 patients with COVID-19, showed that the portal intrahepatic system was affected with acute (thrombotic and luminal ectasia) or chronic (fibrous thickening of the vascular wall) features and the intrahepatic blood vessels were abnormally configured. These findings indicated that the major trigger in the pathogenesis of COVID-19 hepatitis is considered endothelial damage or coagulation dysfunction[141]. Additionally, in patients with critical COVID-19 there were no signs of damage to bile ducts or histological changes in liver failure[140]. Several studies failed to identify viral inclusion bodies in liver tissue[139,142]. Furthermore, the study by Li and Xiao[143] demonstrated that cirrhosis and regeneration signs with macrovesicular steatosis and accumulation in hepatocytes, along with atypical lymphocytic infiltration in the portal tract, may occur due to COVID-19. In the portal triad and centrilobular zones, sinusoidal expansion dilatation in zone 3, mild lymphocytic infiltrations and patchy liver necrosis were also revealed.

Moreover, the study by Ramachandran *et al*[144] showed that in hospitalized COVID-19 patients, elevated aminotransferases were associated with higher mechanical oxygen concentrations but did not achieve statistical significance after inflammatory marker measurement. In addition, patients with elevated aminotransferases did not have higher rates of mortality or prolonged length of stay as shown in Table 4.

In China, some patients recovering from extreme COVID-19 were confirmed to have experienced special manifestations including a darkened face and pigmentation during treatment. The key causes of a darkened face and pigmentation were multiple organ injury, in particular liver injury[145,146]. Abnormal hepatic function can easily lead to pigmentation *via* the following three pathways: (1) Liver dysfunction can prevent estrogen from being inactivated[147]. The rise in estrogen decreases thiamine inhibition of tyrosinase *in vivo*, thus increasing the transformation of tyrosine into melanin[148]; (2) Abnormal liver function can cause hypofunction of adrenocortical hormones. The liver does not metabolize melanocytic stimulatory hormone produced by the anterior pituitary gland, which causes greater melanin secretion[149]; and (3) Liver damage can cause bleaching of the face due to iron in the blood that provides the facial skin[150,151] (Figure 4).

### **Mechanisms of liver injury during COVID-19**

**Direct damage:** It is established that SARS-CoV-2 enters the host cells *via* its binding to ACE2 on the surface of the host cell by the S protein[152,153]. However, the expression of ACE2 levels in liver tissue was estimated to be approximately 0.31% and its expression in bile duct cells was 20 times higher than that in hepatocytes on the basis of single cell sequencing and animal model analysis[154]. Furthermore, elevated levels of  $\gamma$ -glutamyl transferase and alkaline phosphatase were observed in COVID-19 patients[155], and inconsistent with biliary epithelial cells injury, approximately 10% of COVID-19 patients have high levels of total bilirubin. Thus, suggesting that SARS-CoV-2 can bind to cholangiocytes expressing ACE2, resulting in their injury (Figure 5).

**Antibody-dependent enhancement:** Antibody-dependent enhancement of infection (ADE) may arise in patients with SARS[156]. ADE indicates that the interplay between the virus-based antibody and the CR and/or FC receptor complements increases the

**Table 3 Incidence of hepatic abnormalities in patients with severe acute respiratory syndrome coronavirus 2 infection**

Ref.	Patient number	ALT (U/L)	AST (U/L)	TB (mg/dL)
Zhou <i>et al</i> [32], 2020	191	↑59 (31%)	None	NA
Shu <i>et al</i> [227], 2021	545	↑41 (7.5%)	↑35 (10.1%)	↑189 (34.7%)
Huang <i>et al</i> [25], 2020	41	NA	↑15 (37%)	NA
Huang <i>et al</i> [228], 2020	36	4 (13.3%)	18 (58%)	↑4 (12.9%)
Chen <i>et al</i> [26], 2020	99	↑28 (28%)	↑35 (35%)	↑18 (18%)
Ai <i>et al</i> [64], 2020	102	↑20 (19.6%)	↑26 (25.5%)	NA
Xu <i>et al</i> [27], 2020	62	↑3 (3.75%)	↑3 (3.75%)	NA
Yang <i>et al</i> [3], 2020	168	↑9 (8%)	↑18 (17.3%)	↑7 (6.4%)
Wu <i>et al</i> [28], 2020	80	↑3 (3.75%)	↑3 (3.75%)	NA
Yao <i>et al</i> [229], 2020	40	↑21 (52.5%)	↑16 (40%)	
Xu <i>et al</i> [230], 2020	355	↑91 (25.6%)	↑102 (28.7%)	↑10 (25%)
Cai <i>et al</i> [231], 2020	298	↑39 (13.1%)	↑25 (8.4%)	↑66 (18.6)
Richardson <i>et al</i> [1], 2020	5700	↑2176 (39.0%)	↑3263 (58.4%)	↑24 (8.1%)
				NA
Fan <i>et al</i> [1], 2020	40	↑27 (18.2%)	↑32 (21.6%)	↑9 (6.1%)
Guan <i>et al</i> [39], 2020	355	↑158 (21.3%)	↑168 (22.2%)	↑76 (10.5%)

ALT: Alanine aminotransferase; AST: Aspartate aminotransferase; TB: Total bilirubin; NA: Not applicable.

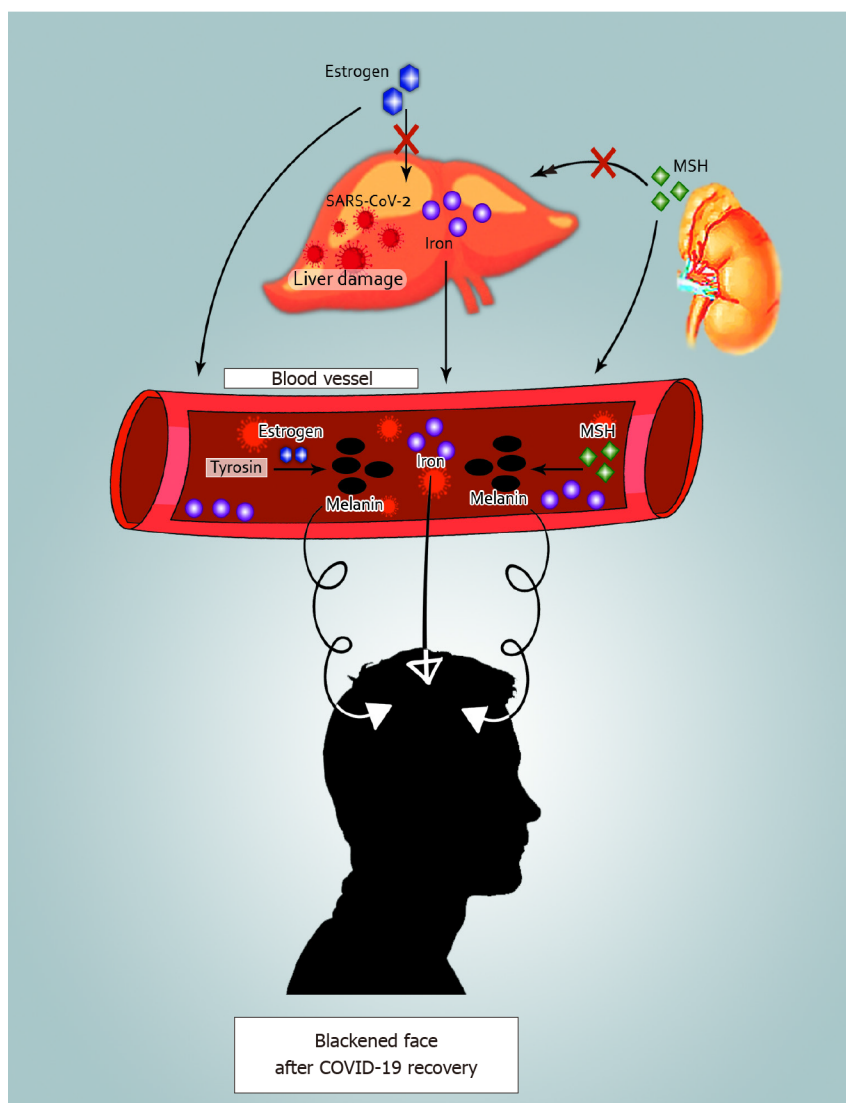
**Table 4 Outcome of the patients with severe elevation of aminotransferases in coronavirus disease 2019**

Ref.	Outcome of patients	SARS-CoV-2 patients with hypertransaminasemia (n = 20)	COVID-19 patients without hypertransaminasemia (n = 125)	P value
Ramachandran <i>et al</i> [169], 2020	Shock	9 (45%)	38 (30.4%)	0.207
	Mechanical ventilation	10 (50%)	30 (24%)	0.028
	Died	10 (50%)	46 (36.8%)	0.324
	Length of stay in days, median (IQR)	7 (4.3, 10.3)	7 (5, 10)	0.78

SARS-CoV-2: Severe acute respiratory syndrome coronavirus 2; IQR: Inter-quartile; COVID-19: Coronavirus disease 2019.

ability of the virus to reach macrophages, granulocytes, and monocytes (Figure 5). The virus frequently replicates in the aforementioned cells, leading to an increase in virus production and worsening of infection. Previous findings have indicated that SARS-CoV antibodies activate ADE, triggering SARS-CoV in immune cells that do not have ACE2 expression or harm the immune system[157]. Whether ADE can help SARS-CoV-2 infect immune cells through a non-ACE2-dependent pathway and participate in SARS-CoV-2 hepatic injury is an issue of concern.

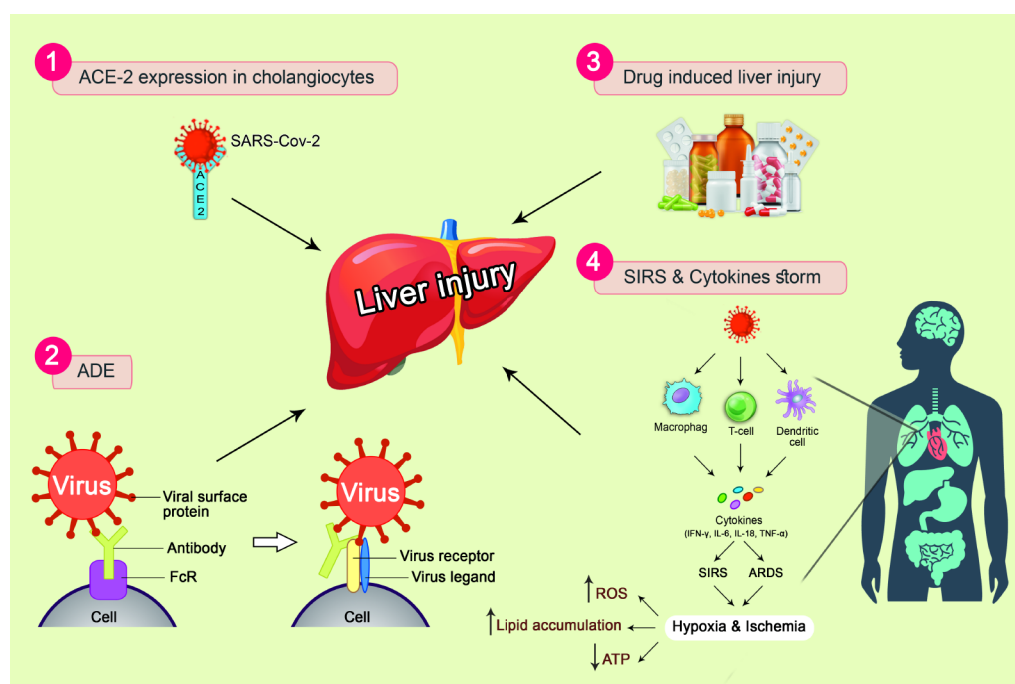
**Systemic inflammatory response syndrome and cytokine storms:** Research has revealed that the inflammatory cytokines, including endotoxin ILs, and TNF- $\alpha$  in SARS patients who have liver function impairment have significantly higher levels than patients with normal liver function. Therefore, systemic inflammatory response syndrome (SIRS) and cytokine storms are risk factors for liver impairment in SARS-CoV and in MERS-CoV infected patients[158-160]. Limited pathological findings have indicated that COVID-19 hepatocytes exhibit non-specific inflammatory modifications in patients with serious infection such as Kupffer-cell hyperplasia and moderate proliferation, hepatocyte swelling and steatosis and a limited number of lymphocytes.



**Figure 4 Facial blackness and dull skin after coronavirus disease 2019 recovery.** Three possible mechanisms are shown: (1) Iron in the damaged liver drains into blood vessels. Blood with high iron levels can lead to blackening of the face when it supplies the facial skin; (2) Estrogen cannot be metabolized in the damaged liver. Thus, elevated estrogen in the blood enhances the conversion of tyrosine to melanin; and (3) When liver function is impaired, adrenocortical function is hypoactive, and melanocyte-stimulating hormone increases resulting in an elevation in the secretion of melanin. SARS-CoV-2: Severe acute respiratory syndrome coronavirus 2; MSH: Melanocyte-stimulating hormone; COVID-19: Coronavirus disease 2019.

Furthermore, the amount of IL-2 and IL-6 in COVID-19 serum has been shown to be substantially increased and linked to the seriousness of the disease[4]. Moreover, cytokines secreted by Th1 and Th2 cells in the serum of COVID-19 patients, such as TNF, IL-6, IL-18, IL-4, and IL-10 were significantly intensified in pro-inflammatory cells (CCR4 + CCR6 + Th17)[25,30,139]. Following SARS-CoV-2 infection, a large number of immune cells activate and induce excessive cytokines, such as TNF- $\alpha$ , IFN- $\mu$ , IL-6, IL-8, *etc.*, leading to SIRS, acute respiratory distress syndrome, and induction of ischemia, eventually, resulting in cell destruction and necrosis as shown in Figure 4. Not only does such a vicious cycle lead to lung injury but may also progress to multiple organ damage. These results suggest that cytokine inflammatory storms may be one of the essential routes of liver injury (Figure 5).

**Ischemia and hypoxia reperfusion injury:** COVID-19 patients have various degrees of hypoxia, as more than 40% of cases required oxygen supplementation[30]. Complications such as aspiration and multiple organ failure can cause hypoxia, ischemia and subsequent shock. The suppression of cell survival signal transduction and hepatocyte death may be caused by ischemia and hypoxia, ATP depletion in hepatocytes, lipid accumulation, and glycogen consumption (Figure 5). Furthermore, the respiratory distress syndrome can cause oxidative stress that increases the production of reactive oxygen species (ROS). The ROS and lipid peroxidation products can induce redox-



**Figure 5 Mechanisms of liver injury in patients with coronavirus disease 2019.** (1) Angiotensin-converting enzyme 2-mediated targeting of cholangiocytes; (2) Antibody-dependent enhancement of infection; (3) Systemic inflammatory response syndrome and cytokine storms; and (4) Drug-induced liver injury. SARS-CoV-2: Severe acute respiratory syndrome coronavirus 2; ACE2: Angiotensin-converting enzyme 2; ADE: Antibody-dependent enhancement of infection; SIRS: Systemic inflammatory response syndrome; ARDS: Acute respiratory distress syndrome; IFN- $\gamma$ : Interferon- $\gamma$ ; IL-6: Interleukin-6; IL-18: Interleukin-18; TNF- $\alpha$ : Tumor necrosis factor- $\alpha$ ; ROS: Reactive oxygen species; ATP: Adenosine triphosphate.

sensitive transcription factors and then release various pro-inflammatory factors leading to liver damage. These changes can exaggerate the ischemia of hepatocytes, influence the excretion of toxic metabolites and eventually stimulate liver injury. Hypoxia is also one of the main causes of liver injury in patients with serious COVID-19[161].

**Drug hepatotoxicity:** In China, the occurrence of drug-induced hepatic damage including, traditional Chinese patent medicines[162,163], antitumor drugs, antibiotics, antimalarial drugs, and anti-tuberculosis drugs[164,165], is second only to fatty liver disease and viral hepatitis (alcoholic and nonalcoholic). Several COVID-19 patients have a fever and consequently, use antipyretic and analgesic drugs. Therefore, a drug overdose can cause hepatic damage.

Recently, this was observed with abidol, lopinavir, ritonavir and other antiviral medications used to control COVID-19. A recent study published in JCI[166] demonstrated that CAP3A4 plays a critical role of the side-effect and metabolic pathways of ritonavir which can generate electrophilic material, radical free oxygen that can be covalently linked with liver cells leading to lipid membrane peroxidation, membrane integrity disruption of the Ca<sup>2+</sup>-ATPase membrane, interruption of the internal and external Ca<sup>2+</sup> homeostasis of the cells, and finally leading to death. Furthermore, an overdose of the combination of lopinavir and ritonavir can stimulate the hepatic endoplasmic reticulum stress cascade, induce inflammatory reactions, trigger hepatocyte apoptosis through the caspase mechanism, suppress hepatocyte growth, and aggravate liver damage by the production of oxidative stress[167,168]. Some scientists have assumed that SARS-CoV-2 replication can be effectively inhibited by human immunodeficiency virus (HIV) protease inhibitors; although Shen *et al* stated that the risk of liver damage is increased in patients receiving hormones and HIV protease inhibitors[169]. The incidence of liver damage due to different medicines varies. However, the prevalence of liver damage due to more drug types is increasing. The diagnosis of hepatic damage due to medication includes a combination of medical history and appropriate testing to rule out other liver disorders and to estimate the relationship between hepatic injury and suspected medications by causality.

### COVID-19 and previously-existing liver disease

Due to the global spread of chronic liver disorders, correlations among patients

presenting with hepatic illness and COVID-19 need to be examined. A preliminary analysis showed that 2%–11% of patients had hepatic disease and COVID-19[170]. In a study of 1099 COVID-19 patients, hepatitis B infection occurred in 23 (2.1%) patients. Serious cases of hepatitis B infection were more likely (2.4% *vs* 0.6%) than milder cases [39]. SARS patients with hepatitis B virus (HBV) or hepatitis C virus (HCV) infection were more vulnerable to serious hepatitis, likely because viral replication was increased during SARS-CoV infection[171]. Older patients with COVID-19 and have other conditions such as diabetes, cardiovascular disease, hypertension, and nonalcoholic fatty liver disease, are more susceptible to liver injury.

Moreover, patients with liver cirrhosis may be more susceptible to infection due to their systemic disease[172], thus, preventing COVID-19 is extremely important. None of 111 patients with COVID-19 in Wuhan had decompensated cirrhosis due to preventive measures. In contrast to this, 17% of 101 patients with COVID-19 developed decompensated cirrhosis at other hospitals where preventive measures were not implemented[173]. Viral transmission could occur during liver transplantation from donor to recipient, as previously described in SARS infection[174]. Recently, Michaels and colleagues showed potential transplantation risks in COVID-19 recipients[175]. The Italian Transplant Authority is carrying out nasopharyngeal swabs to diagnose COVID-19 before donation, with the subsequent exclusion of positive donors[176].

**COVID-19 in liver transplant recipients:** The worldwide spread of COVID-19 raises additional challenges for organ transplants. Transplant recipients with preoperative decompensated organs and chronic illness tend to contract respiratory viruses. Liver transplant patients, who are exposed to more people, during their wait for transplantation, have an increased risk of cross-infection with COVID-19. Qin *et al*[177] confirmed COVID-19 hepatocellular carcinoma in a patient following liver transplantation. On the 11<sup>th</sup> day after hepatic transplantation, the patient was diagnosed with COVID-19 following a positive PCR-test, with multiple ground-glass opacities in the left lobes. Long-term immune treatment in transplantation recipients prevents allograft rejection but significantly reduces the ability to protect them against COVID-19 due to their compromised immune system. A systematic analysis of 15 studies involving 223 patients with confirmed COVID-19 showed that simultaneous diarrhea was more likely to be present in patients who had undergone liver transplantation. The higher mortality rates in elderly patients with dyspnea and diabetes were approximately 23% in COVID-19 patients[178]. However, the latest data still do not confirm susceptibility to COVID-19 in liver transplant patients. A number of cases in Italy have indicated that children receiving liver transplants were not at elevated risk of serious lung disease relative to the general population despite being immunocompromised [179]. Similarly, three COVID-19-related deaths observed by D'Antiga[179] at an Italian transplant center were long-term patients on a minimal immunosuppression regimen, rather than recently transplanted patients with complete immunosuppression. Furthermore, a large global observational study by Webb *et al*[180] showed that the risk of death in COVID-19 patients does not substantially increase following liver transplantation.

### **Pharmacologic management of liver injury in COVID-19**

COVID-19 causes mainly transient and indirect liver injuries, which can be caused by hypoxia, systemic inflammatory reactions, and medication. Thus, hepatic damage should be treated by elimination of the basic etiology in the COVID-19 patients. Correction of hypoxia by oxygen supplementation or mechanical ventilation, renal replacement treatment for cytokine storm, and restoration of intravascular effectiveness can enhance liver injuries in the event of septic shock[181]. Also early identification and reduction in the dosage of drugs inducing hepatic damage is crucial. Hepatoprotective anti-inflammatory medicines including L-ornithine-L-aspartate can be used in extreme cases as an adjuvant treatment[182]. It is worth noting that therapeutic drugs may be hepatotoxic, especially in chronic liver disease (CLD) patients. Furthermore, patients treated with immunosuppressive agents should be closely monitored due to drug interactions. Recommendations for the management of CLD, AIH, and immunosuppressed patients during a pandemic are summarized in Tables 5, 6 and 7[183,184].

## **COVID-19 IN THE ENDOSCOPY UNIT**

Although millions of people have remained at their houses to decrease the transmi-



**Table 5 Recommendations of the American Association for the Study of Liver Diseases, Asian Pacific Association for the Study of the Liver, and European Association for the Study of the Liver for management of liver disease during coronavirus disease 2019**

Selected recommendations	
To limit nosocomial spread	<ol style="list-style-type: none"> <li>(1) Decrease in-person visits <i>via</i> other alternatives such as virtual platforms</li> <li>(2) Symptom investigation before entering hospitals to identify COVID-19 patients</li> <li>(3) Reduce staffing to essential staff only</li> <li>(4) Reduce the frequency of screening and laboratory examinations</li> <li>(5) Adhere to recommended PPE by HCW and patients</li> <li>(6) Maintain proper social distancing in hospitals</li> <li>(7) Postpone unnecessary or elective operations</li> </ol>
Management of CLD patients with COVID-19	<ol style="list-style-type: none"> <li>(1) These patients should be admitted to hospital early</li> <li>(2) Prioritization of COVID-19 testing for patients with cirrhosis, CLD patients taking immunosuppressive agents and acute decompensated patients</li> <li>(3) Repeated LFTs are advisable</li> <li>(4) Early registration in clinical trials as much as possible</li> <li>(5) COVID-19 patients with NAFLD should be kept under supervision</li> <li>(6) Screening of hepatitis B surface antigen should be taken into consideration</li> <li>(7) Drug-induced liver injury should be monitored</li> <li>(8) These patients can receive 2-3 g/d of acetaminophen, while limiting the use of NSAIDs when possible</li> <li>(9) HBV prophylaxis should be considered before starting immunosuppressive agents</li> <li>(10) Stopping Remdesivir in decompensated liver disease patients with ALT more than 5 times the upper limit of normal</li> </ol>
Management of chronic viral hepatitis (HCV and HBV)	<ol style="list-style-type: none"> <li>(1) Despite COVID-19 status, treatment continuity of chronic HCV and HBV is recommended</li> <li>(2) In the absence of flare, HBV treatment should be stopped</li> <li>(3) For uninfected individuals, HCV and HBV treatment should be continued according to guidelines</li> </ol>
Management of HCC	<ol style="list-style-type: none"> <li>(1) HCC treatment should be continued according to guidelines; however, it can be delayed if necessary</li> <li>(2) In the case of COVID-19 patients, delaying elective transplants and resection surgery, and stopping immunotherapy are advisable</li> <li>(3) Early admission to hospital is recommended for HCC patients</li> </ol>
Management of pre- and post-transplant recipients	<ol style="list-style-type: none"> <li>(1) Screening donor and recipient for COVID-19 is suggested</li> <li>(2) For donors testing positive for COVID-19, transplantation surgery should be postponed</li> <li>(3) Prioritization of patients with short-term prognosis</li> <li>(4) For post-transplant patients, a reduction in immunosuppressive dose can be considered for moderate COVID-19 cases, while for mild COVID-19 cases, the dose should not be reduced</li> <li>(5) For post-transplant recipients, vaccination against pneumonia and influenza is advisable</li> </ol>

PPE: Personal protective equipment; HCWs: Healthcare workers; CLD: Chronic liver disease; COVID-19: Coronavirus disease 2019; LFTs: Liver function tests; NAFLD: Nonalcoholic fatty liver disease; NSAIDs: Non-steroidal anti-inflammatory drugs; HBV: Hepatitis B virus; ALT: Alanine aminotransferase; HCV: Hepatitis C virus; HCC: Hepatocellular carcinoma.

ssion of SARS-CoV-2, the risk of COVID-19 amongst health workers is high.

For example, the Chinese National Health Commission determined that approximately 3300 health workers were infected in early March[185]. It is well-known that endoscopic staff are at high risk of airborne droplet infection, conjunctiva contact and surface contact contamination[182,186]. Airway suction and other cough-induced procedures result in an increased risk of SARS-CoV-2 transmission[182]. It must be noted that the possible risk of exposure to feces removal is not confined to upper endoscopy[35].



**Table 6 Recommendations of the American Association for the Study of Liver Diseases and European Association for the Study of the Liver for the management of auto-immune hepatitis during coronavirus disease 2019**

Selected recommendations	
Virtual platforms are recommended to minimize in-person visits as much as possible	
COVID-19 testing is advised in cases of acute deterioration and liver failure	
Patients with low risk of complications (patients on chronic immunosuppressive therapy)	(1) Frequent patient-provider communications should be closely supervised; (2) Virtual platforms should be used to decrease contact; and (3) Ensure enough drug supply and refills to decrease running out of medications
Patients with moderate risk of complications (symptomatic disease without cirrhosis)	(1) Empiric therapy <i>via</i> virtual healthcare platforms as much as possible; and (2) Preventing liver biopsy whenever possible
Patients with high risk of complications (acute flare, decompensated cirrhosis)	(1) Reduce invasive procedures as much as possible; (2) In the case of COVID-19 patients, if lymphopenia develops, dose reduction of antimetabolites is recommended; and (3) In the case of infection, corticosteroids should be attenuated

COVID-19: Coronavirus disease 2019.

**Table 7 Recommendations of the American Association for the Study of Liver Diseases and European Association for the Study of the Liver on the use of immunosuppressive therapies in chronic liver disease during coronavirus disease 2019**

Suggestions	
(1) Starting with corticosteroids and immunomodulators should proceed; and (2) Risk benefit ratio assessments should be carried out	
Patients on immunosuppressive treatment and not infected with COVID-19	Decreases or adjustment of doses is not advisable
Patients infected with COVID-19 on immunosuppressive drugs	(1) Reduce corticosteroids dose after specialist physician (consider tapering to prevent adrenal insufficiency); and (2) Decreasing the doses of cyclosporine, mycophenolate, and azathioprine is recommended in severe COVID-19 (especially patients with lymphopenia)
Patients requiring initiation of immunosuppressive agents	Starting treatment is suggested in these patients regardless of COVID-19 status

COVID-19: Coronavirus disease 2019.

A prospective study conducted by Johnston *et al*[187], revealed the quantification of unrecognized bacteria to endoscopists exposed to biological samples leading to infection transmission. In this investigation, 227 endoscopic face shields were examined for colony-forming units (CFUs), and 1-15 CFU, 91/227 (40%); 16-30 CFU, 6/227 (2.6%); 30 or more CFU, 6/227 (2.6%) significantly increased after endoscopy. Similarly, in 1999, a research study carried out by Mohandas and Gopalakrishnan[188] in a tertiary care hospital in India of 786 endoscopies (149 lower and 162 therapeutic endoscopies) concluded that the splash rate to the skin of the forearms, feet, and face was 9.5%, while the splash rate to the eyes was 4.1%.

The duodenoscope is the most complex medical equipment that undergoes disinfection after patient use[189]. Virus risk factors include non-compatibility with disinfection guidelines, the promotion of biofilm deposition because of its complicated nature, surface defects and infected automated endoscopes[190,191]. It is considered that endogenous infections due to the gut flora of patients are the most common infections after endoscopy[192]. Exogenous infections such as *Escherichia coli* (71%), *Klebsiella* (14%), and *Enterobacter* (5%) can occur due to contaminated scopes and may be avoided by thorough cleaning[192,193]. Currently, *Pseudomonas aeruginosa* is the most common organism isolated from contaminated endoscopes[194]. Other microorganisms include, *Mycobacteria*, *Helicobacter pylori*, *Clostridium difficile*, HBV and HCV [195]. Recently, studies on duodenoscopy-associated infections including multidrug-resistant organisms, particularly carbapenem-resistant *Enterobacteriaceae*, have surfaced [196]. Numerous infections occurred despite sufficient disinfection, indicating that professional and government bodies should provide additional recommendations for duodenoscope processing[197,198]. To date, The Food and Drug Administration and Centers for Disease Control and Prevention have recommended comprehensive cleaning followed by high-level disinfection for reprocessing of flexible GI endoscopes [199-201].

In COVID-19 patients single-use duodeno-scopes may be important. However, they are not accessible worldwide and have cost-related constraints[202]. Several societies have advocated the use of room negative pressure, particularly for COVID-19 patients, or if endoscopy is urgently needed[203]. Intraprocedural changes such as minimal verbal communication, avoiding procedures in patients with inadequate bowel preparation, and avoiding spillage of GI contents *via* the biopsy channel should be introduced[204]. A previous study reported the use of a “double gauze technique”; one for the endoscopists and the other for technicians in a controlled fashion to prevent the “whip” effect of accessories and spillage of GIT secretions[204]. Institutional requirements for minimum staff involved in the procedure have been developed [205]. Thus, the risk of exposure among endoscopy personnel is diminished. Endoscopy techniques performed with moderate sedation without the need for anesthetic agents (endoscopy driven sedation) can also reduce the risk of transmission. However, in the case of procedures requiring general anesthesia, policymakers recently recommended the use of endotracheal intubation to diminish the risk of aerosolization due to suspected or confirmed COVID-19[206]. Other methods to avoid splashes include the use of regular precautions such as full-sleeve gowns and suitable footwear [187].

## GAPS IN KNOWLEDGE

Although there is a theoretical risk of fecal-oral transmission of COVID-19, the actual risk of transmission is extremely low. Despite this risk, endoscopy units have been functioning and reopening with no significant outbreaks noted.

## CONCLUSION

COVID-19 can lead to acute respiratory infection, and a high rate of morbidity and mortality. The main signs of COVID-19 are respiratory system reactions, and gastro-intestinal symptoms are also very common. COVID-19 patients with GIT symptoms are more probably associated with severe complications such as ARDS and liver damage, with a poor prognosis. Hence, during diagnosis and treatment of the disease, GIT symptoms should be taken into consideration as well as virus transmission *via* the fecal-oral route. In addition, it is advisable to take care of patients with chronic liver disease and they should be treated with medications that are able to prevent inflammatory responses and protect liver functions during COVID-19. Furthermore, the harmful effects of some drugs on the gut and liver during hospitalization must be identified and evaluated frequently. Further studies on the intrinsic relationship between COVID-19, hepatology and gastroenterology are urgently required.

## REFERENCES

- 1 **Raoult D**, Zumla A, Locatelli F, Ippolito G, Kroemer G. Coronavirus infections: Epidemiological, clinical and immunological features and hypotheses. *Cell Stress* 2020; **4**: 66-75 [PMID: [32292881](#) DOI: [10.15698/cst2020.04.216](#)]
- 2 **de Wilde AH**, Snijder EJ, Kikkert M, van Hemert MJ. Host Factors in Coronavirus Replication. *Curr Top Microbiol Immunol* 2018; **419**: 1-42 [PMID: [28643204](#) DOI: [10.1007/82\\_2017\\_25](#)]
- 3 **European Centre for Disease Prevention and Control (ECDC)**. Risk Assessment Guidelines for Infectious Diseases Transmitted on Aircraft (RAGIDA) Middle East Respiratory Syndrome Coronavirus (MERS-CoV). Stockholm: ECDC; 2020. [Cited 1 January 2021]. Available from: [www.hpsc.ie/A-Z/EmergencyPlanning/PortHealth/File,4661,en.pdf](http://www.hpsc.ie/A-Z/EmergencyPlanning/PortHealth/File,4661,en.pdf)
- 4 **Zhu N**, Zhang D, Wang W, Li X, Yang B, Song J, Zhao X, Huang B, Shi W, Lu R, Niu P, Zhan F, Ma X, Wang D, Xu W, Wu G, Gao GF, Tan W; China Novel Coronavirus Investigating and Research Team. A Novel Coronavirus from Patients with Pneumonia in China, 2019. *N Engl J Med* 2020; **382**: 727-733 [PMID: [31978945](#) DOI: [10.1056/NEJMoa2001017](#)]
- 5 **Wu YC**, Chen CS, Chan YJ. The outbreak of COVID-19: An overview. *J Chin Med Assoc* 2020; **83**: 217-220 [PMID: [32134861](#) DOI: [10.1097/JCMA.0000000000000270](#)]
- 6 **Worldometers**. info. COVID-19 CORONAVIRUS PANDEMIC. 2021. [Cited 1 January 2021]. Available from: <https://www.worldometers.info/coronavirus/#countries>
- 7 **Johnson KD**, Harris C, Cain JK, Hummer C, Goyal H, Perisetti A. Pulmonary and Extra-Pulmonary Clinical Manifestations of COVID-19. *Front Med (Lausanne)* 2020; **7**: 526 [PMID: [32903492](#) DOI: [10.3389/fmed.2020.00526](#)]

- 10.3389/fmed.2020.00526]
- 8 **Lauer SA**, Grantz KH, Bi Q, Jones FK, Zheng Q, Meredith HR, Azman AS, Reich NG, Lessler J. The Incubation Period of Coronavirus Disease 2019 (COVID-19) From Publicly Reported Confirmed Cases: Estimation and Application. *Ann Intern Med* 2020; **172**: 577-582 [PMID: 32150748 DOI: 10.7326/M20-0504]
- 9 **Li Q**, Guan X, Wu P, Wang X, Zhou L, Tong Y, Ren R, Leung KSM, Lau EHY, Wong JY, Xing X, Xiang N, Wu Y, Li C, Chen Q, Li D, Liu T, Zhao J, Liu M, Tu W, Chen C, Jin L, Yang R, Wang Q, Zhou S, Wang R, Liu H, Luo Y, Liu Y, Shao G, Li H, Tao Z, Yang Y, Deng Z, Liu B, Ma Z, Zhang Y, Shi G, Lam TTY, Wu JT, Gao GF, Cowling BJ, Yang B, Leung GM, Feng Z. Early Transmission Dynamics in Wuhan, China, of Novel Coronavirus-Infected Pneumonia. *N Engl J Med* 2020; **382**: 1199-1207 [PMID: 31995857 DOI: 10.1056/NEJMoa2001316]
- 10 **Wu Z**, McGoogan JM. Characteristics of and Important Lessons From the Coronavirus Disease 2019 (COVID-19) Outbreak in China: Summary of a Report of 72 314 Cases From the Chinese Center for Disease Control and Prevention. *JAMA* 2020; **323**: 1239-1242 [PMID: 32091533 DOI: 10.1001/jama.2020.2648]
- 11 **Scientific Research**. Report of the WHO-China Joint Mission on Coronavirus Disease 2019 (COVID-19). Geneva, Switzerland: WHO; 2020. [cited 1 January 2021]. Available from: <https://www.scirp.org/reference/referencespapers.aspx?referenceid=2725513>
- 12 **Wang D**, Hu B, Hu C, Zhu F, Liu X, Zhang J, Wang B, Xiang H, Cheng Z, Xiong Y, Zhao Y, Li Y, Wang X, Peng Z. Clinical Characteristics of 138 Hospitalized Patients With 2019 Novel Coronavirus-Infected Pneumonia in Wuhan, China. *JAMA* 2020; **323**: 1061-1069 [PMID: 32031570 DOI: 10.1001/jama.2020.1585]
- 13 **Jaillon S**, Berthenet K, Garlanda C. Sexual Dimorphism in Innate Immunity. *Clin Rev Allergy Immunol* 2019; **56**: 308-321 [PMID: 28963611 DOI: 10.1007/s12016-017-8648-x]
- 14 **Marriott I**, Huet-Hudson YM. Sexual dimorphism in innate immune responses to infectious organisms. *Immunol Res* 2006; **34**: 177-192 [PMID: 16891670 DOI: 10.1385/IR.34:3:177]
- 15 **Schröder J**, Kahlke V, Staubach KH, Zabel P, Stüber F. Gender differences in human sepsis. *Arch Surg* 1998; **133**: 1200-1205 [PMID: 9820351 DOI: 10.1001/archsurg.133.11.1200]
- 16 **García-Durán M**, de Frutos T, Díaz-Recasens J, García-Gálvez G, Jiménez A, Montón M, Farré J, Sánchez de Miguel L, González-Fernández F, Arriero MD, Rico L, García R, Casado S, López-Farré A. Estrogen stimulates neuronal nitric oxide synthase protein expression in human neutrophils. *Circ Res* 1999; **85**: 1020-1026 [PMID: 10571532 DOI: 10.1161/01.res.85.11.1020]
- 17 **Oertelt-Prigione S**. The influence of sex and gender on the immune response. *Autoimmun Rev* 2012; **11**: A479-A485 [PMID: 22155201 DOI: 10.1016/j.autrev.2011.11.022]
- 18 **Klein SL**. Sex influences immune responses to viruses, and efficacy of prophylaxis and treatments for viral diseases. *Bioessays* 2012; **34**: 1050-1059 [PMID: 23012250 DOI: 10.1002/bies.201200099]
- 19 **Scully EP**, Haverfield J, Ursin RL, Tannenbaum C, Klein SL. Considering how biological sex impacts immune responses and COVID-19 outcomes. *Nat Rev Immunol* 2020; **20**: 442-447 [PMID: 32528136 DOI: 10.1038/s41577-020-0348-8]
- 20 **Liu J**, Ji H, Zheng W, Wu X, Zhu JJ, Arnold AP, Sandberg K. Sex differences in renal angiotensin converting enzyme 2 (ACE2) activity are 17 $\beta$ -oestradiol-dependent and sex chromosome-independent. *Biol Sex Differ* 2010; **1**: 6 [PMID: 21208466 DOI: 10.1186/2042-6410-1-6]
- 21 **Sampson AK**, Moritz KM, Denton KM. Postnatal ontogeny of angiotensin receptors and ACE2 in male and female rats. *Gen Med* 2012; **9**: 21-32 [PMID: 22266307 DOI: 10.1016/j.genm.2011.12.003]
- 22 **Hussein J**. COVID-19: What implications for sexual and reproductive health and rights globally? *Sex Reprod Health Matters* 2020; **28**: 1746065 [PMID: 32191167 DOI: 10.1080/26410397.2020.1746065]
- 23 **Brosnihan KB**, Neves LA, Joyner J, Averill DB, Chappell MC, Sarao R, Penninger J, Ferrario CM. Enhanced renal immunocytochemical expression of ANG-(1-7) and ACE2 during pregnancy. *Hypertension* 2003; **42**: 749-753 [PMID: 12874086 DOI: 10.1161/01.HYP.0000085220.53285.11]
- 24 **Garg S**, Kim L, Whitaker M, O'Halloran A, Cummings C, Holstein R, Prill M, Chai SJ, Kirley PD, Alden NB, Kawasaki B, Yousey-Hindes K, Niccolai L, Anderson EJ, Openo KP, Weigel A, Monroe ML, Ryan P, Henderson J, Kim S, Como-Sabetti K, Lynfield R, Sosin D, Torres S, Muse A, Bennett NM, Billing L, Sutton M, West N, Schaffner W, Talbot HK, Aquino C, George A, Budd A, Brammer L, Langley G, Hall AJ, Fry A. Hospitalization Rates and Characteristics of Patients Hospitalized with Laboratory-Confirmed Coronavirus Disease 2019 - COVID-NET, 14 States, March 1-30, 2020. *MMWR Morb Mortal Wkly Rep* 2020; **69**: 458-464 [PMID: 32298251 DOI: 10.15585/mmwr.mm6915e3]
- 25 **Huang C**, Wang Y, Li X, Ren L, Zhao J, Hu Y, Zhang L, Fan G, Xu J, Gu X, Cheng Z, Yu T, Xia J, Wei Y, Wu W, Xie X, Yin W, Li H, Liu M, Xiao Y, Gao H, Guo L, Xie J, Wang G, Jiang R, Gao Z, Jin Q, Wang J, Cao B. Clinical features of patients infected with 2019 novel coronavirus in Wuhan, China. *Lancet* 2020; **395**: 497-506 [PMID: 31986264 DOI: 10.1016/S0140-6736(20)30183-5]
- 26 **Chen N**, Zhou M, Dong X, Qu J, Gong F, Han Y, Qiu Y, Wang J, Liu Y, Wei Y, Xia J, Yu T, Zhang X, Zhang L. Epidemiological and clinical characteristics of 99 cases of 2019 novel coronavirus pneumonia in Wuhan, China: a descriptive study. *Lancet* 2020; **395**: 507-513 [PMID: 32007143 DOI: 10.1016/S0140-6736(20)30211-7]
- 27 **Xu XW**, Wu XX, Jiang XG, Xu KJ, Ying LJ, Ma CL, Li SB, Wang HY, Zhang S, Gao HN, Sheng JF, Cai HL, Qiu YQ, Li LJ. Clinical findings in a group of patients infected with the 2019 novel

- coronavirus (SARS-Cov-2) outside of Wuhan, China: retrospective case series. *BMJ* 2020; **368**: m606 [PMID: [32075786](#) DOI: [10.1136/bmj.m606](#)]
- 28 **Wu J**, Liu J, Zhao X, Liu C, Wang W, Wang D, Xu W, Zhang C, Yu J, Jiang B, Cao H, Li L. Clinical Characteristics of Imported Cases of Coronavirus Disease 2019 (COVID-19) in Jiangsu Province: A Multicenter Descriptive Study. *Clin Infect Dis* 2020; **71**: 706-712 [PMID: [32109279](#) DOI: [10.1093/cid/ciaa199](#)]
  - 29 **Shi H**, Han X, Jiang N, Cao Y, Alwalid O, Gu J, Fan Y, Zheng C. Radiological findings from 81 patients with COVID-19 pneumonia in Wuhan, China: a descriptive study. *Lancet Infect Dis* 2020; **20**: 425-434 [PMID: [32105637](#) DOI: [10.1016/S1473-3099\(20\)30086-4](#)]
  - 30 **Yang X**, Yu Y, Xu J, Shu H, Xia J, Liu H, Wu Y, Zhang L, Yu Z, Fang M, Yu T, Wang Y, Pan S, Zou X, Yuan S, Shang Y. Clinical course and outcomes of critically ill patients with SARS-CoV-2 pneumonia in Wuhan, China: a single-centered, retrospective, observational study. *Lancet Respir Med* 2020; **8**: 475-481 [PMID: [32105632](#) DOI: [10.1016/S2213-2600\(20\)30079-5](#)]
  - 31 **Mo P**, Xing Y, Xiao Y, Deng L, Zhao Q, Wang H, Xiong Y, Cheng Z, Gao S, Liang K, Luo M, Chen T, Song S, Ma Z, Chen X, Zheng R, Cao Q, Wang F, Zhang Y. Clinical characteristics of refractory COVID-19 pneumonia in Wuhan, China. *Clin Infect Dis* 2020 [PMID: [32173725](#) DOI: [10.1093/cid/ciaa270](#)]
  - 32 **Zhou F**, Yu T, Du R, Fan G, Liu Y, Liu Z, Xiang J, Wang Y, Song B, Gu X, Guan L, Wei Y, Li H, Wu X, Xu J, Tu S, Zhang Y, Chen H, Cao B. Clinical course and risk factors for mortality of adult inpatients with COVID-19 in Wuhan, China: a retrospective cohort study. *Lancet* 2020; **395**: 1054-1062 [PMID: [32171076](#) DOI: [10.1016/S0140-6736\(20\)30566-3](#)]
  - 33 **Lee IC**, Huo TI, Huang YH. Gastrointestinal and liver manifestations in patients with COVID-19. *J Chin Med Assoc* 2020; **83**: 521-523 [PMID: [32243269](#) DOI: [10.1097/JCMA.0000000000000319](#)]
  - 34 **Sultan S**, Altayar O, Siddique SM, Davitkov P, Feuerstein JD, Lim JK, Falck-Ytter Y, El-Serag HB; AGA Institute. AGA Institute Rapid Review of the Gastrointestinal and Liver Manifestations of COVID-19, Meta-Analysis of International Data, and Recommendations for the Consultative Management of Patients with COVID-19. *Gastroenterology* 2020; **159**: 320-334.e27 [PMID: [32407808](#) DOI: [10.1053/j.gastro.2020.05.001](#)]
  - 35 **Gu J**, Han B, Wang J. COVID-19: Gastrointestinal Manifestations and Potential Fecal-Oral Transmission. *Gastroenterology* 2020; **158**: 1518-1519 [PMID: [32142785](#) DOI: [10.1053/j.gastro.2020.02.054](#)]
  - 36 **Ruan Q**, Yang K, Wang W, Jiang L, Song J. Clinical predictors of mortality due to COVID-19 based on an analysis of data of 150 patients from Wuhan, China. *Intensive Care Med* 2020; **46**: 846-848 [PMID: [32125452](#) DOI: [10.1007/s00134-020-05991-x](#)]
  - 37 **Liang W**, Feng Z, Rao S, Xiao C, Xue X, Lin Z, Zhang Q, Qi W. Diarrhoea may be underestimated: a missing link in 2019 novel coronavirus. *Gut* 2020; **69**: 1141-1143 [PMID: [32102928](#) DOI: [10.1136/gutjnl-2020-320832](#)]
  - 38 **Pan L**, Mu M, Yang P, Sun Y, Wang R, Yan J, Li P, Hu B, Wang J, Hu C, Jin Y, Niu X, Ping R, Du Y, Li T, Xu G, Hu Q, Tu L. Clinical Characteristics of COVID-19 Patients With Digestive Symptoms in Hubei, China: A Descriptive, Cross-Sectional, Multicenter Study. *Am J Gastroenterol* 2020; **115**: 766-773 [PMID: [32287140](#) DOI: [10.14309/ajg.0000000000000620](#)]
  - 39 **Guan WJ**, Ni ZY, Hu Y, Liang WH, Ou CQ, He JX, Liu L, Shan H, Lei CL, Hui DSC, Du B, Li LJ, Zeng G, Yuen KY, Chen RC, Tang CL, Wang T, Chen PY, Xiang J, Li SY, Wang JL, Liang ZJ, Peng YX, Wei L, Liu Y, Hu YH, Peng P, Wang JM, Liu JY, Chen Z, Li G, Zheng ZJ, Qiu SQ, Luo J, Ye CJ, Zhu SY, Zhong NS; China Medical Treatment Expert Group for Covid-19. Clinical Characteristics of Coronavirus Disease 2019 in China. *N Engl J Med* 2020; **382**: 1708-1720 [PMID: [32109013](#) DOI: [10.1056/NEJMoa2002032](#)]
  - 40 **Zhang H**, Liao YS, Gong J, Liu J, Xia X, Zhang H. Clinical characteristics of coronavirus disease (COVID-19) patients with gastrointestinal symptoms: A report of 164 cases. *Dig Liver Dis* 2020; **52**: 1076-1079 [PMID: [32507692](#) DOI: [10.1016/j.dld.2020.04.034](#)]
  - 41 **Luo S**, Zhang X, Xu H. Don't Overlook Digestive Symptoms in Patients With 2019 Novel Coronavirus Disease (COVID-19). *Clin Gastroenterol Hepatol* 2020; **18**: 1636-1637 [PMID: [32205220](#) DOI: [10.1016/j.cgh.2020.03.043](#)]
  - 42 **Jin X**, Lian JS, Hu JH, Gao J, Zheng L, Zhang YM, Hao SR, Jia HY, Cai H, Zhang XL, Yu GD, Xu KJ, Wang XY, Gu JQ, Zhang SY, Ye CY, Jin CL, Lu YF, Yu X, Yu XP, Huang JR, Xu KL, Ni Q, Yu CB, Zhu B, Li YT, Liu J, Zhao H, Zhang X, Yu L, Guo YZ, Su JW, Tao JJ, Lang GJ, Wu XX, Wu WR, Qv TT, Xiang DR, Yi P, Shi D, Chen Y, Ren Y, Qiu YQ, Li LJ, Sheng J, Yang Y. Epidemiological, clinical and virological characteristics of 74 cases of coronavirus-infected disease 2019 (COVID-19) with gastrointestinal symptoms. *Gut* 2020; **69**: 1002-1009 [PMID: [32213556](#) DOI: [10.1136/gutjnl-2020-320926](#)]
  - 43 **Ferm S**, Fisher C, Pakala T, Tong M, Shah D, Schwarzbaum D, Cooley V, Hussain S, Kim SH. Analysis of Gastrointestinal and Hepatic Manifestations of SARS-CoV-2 Infection in 892 Patients in Queens, NY. *Clin Gastroenterol Hepatol* 2020; **18**: 2378-2379.e1 [PMID: [32497637](#) DOI: [10.1016/j.cgh.2020.05.049](#)]
  - 44 **Hajifathalian K**, Krisko T, Mehta A, Kumar S, Schwartz R, Fortune B, Sharaiha RZ; WCM-GI research group\*. Gastrointestinal and Hepatic Manifestations of 2019 Novel Coronavirus Disease in a Large Cohort of Infected Patients From New York: Clinical Implications. *Gastroenterology* 2020; **159**: 1137-1140.e2 [PMID: [32389667](#) DOI: [10.1053/j.gastro.2020.05.010](#)]
  - 45 **Cheung KS**, Hung IFN, Chan PPY, Lung KC, Tso E, Liu R, Ng YY, Chu MY, Chung TWH, Tam



- AR, Yip CCY, Leung KH, Fung AY, Zhang RR, Lin Y, Cheng HM, Zhang AJX, To KKW, Chan KH, Yuen KY, Leung WK. Gastrointestinal Manifestations of SARS-CoV-2 Infection and Virus Load in Fecal Samples From a Hong Kong Cohort: Systematic Review and Meta-analysis. *Gastroenterology* 2020; **159**: 81-95 [PMID: [32251668](#) DOI: [10.1053/j.gastro.2020.03.065](#)]
- 46 **Goyal H**, Sachdeva S, Perisetti A, Mann R, Inamdar S, Tharian B. Hyperlipasemia and Potential Pancreatic Injury Patterns in COVID-19: A Marker of Severity or Innocent Bystander? *Gastroenterology* 2021; **160**: 946-948.e2 [PMID: [33129845](#) DOI: [10.1053/j.gastro.2020.10.037](#)]
- 47 **Gadiparthi C**, Perisetti A, Sayana H, Tharian B, Inamdar S, Korman A. Gastrointestinal Bleeding in Patients with Severe SARS-CoV-2. *Am J Gastroenterol* 2020; **115**: 1283-1285 [PMID: [32516204](#) DOI: [10.14309/ajg.0000000000000719](#)]
- 48 **Tian Y**, Rong L, Nian W, He Y. Review article: gastrointestinal features in COVID-19 and the possibility of faecal transmission. *Aliment Pharmacol Ther* 2020; **51**: 843-851 [PMID: [3222988](#) DOI: [10.1111/apt.15731](#)]
- 49 **Xiao F**, Tang M, Zheng X, Liu Y, Li X, Shan H. Evidence for Gastrointestinal Infection of SARS-CoV-2. *Gastroenterology* 2020; **158**: 1831-1833.e3 [PMID: [32142773](#) DOI: [10.1053/j.gastro.2020.02.055](#)]
- 50 **Lui K**, Wilson MP, Low G. Abdominal imaging findings in patients with SARS-CoV-2 infection: a scoping review. *Abdom Radiol (NY)* 2021; **46**: 1249-1255 [PMID: [32926211](#) DOI: [10.1007/s00261-020-02739-5](#)]
- 51 **Li F**. Structure, Function, and Evolution of Coronavirus Spike Proteins. *Annu Rev Virol* 2016; **3**: 237-261 [PMID: [27578435](#) DOI: [10.1146/annurev-virology-110615-042301](#)]
- 52 **Kuhn JH**, Li W, Choe H, Farzan M. Angiotensin-converting enzyme 2: a functional receptor for SARS coronavirus. *Cell Mol Life Sci* 2004; **61**: 2738-2743 [PMID: [15549175](#) DOI: [10.1007/s00018-004-4242-5](#)]
- 53 **Raj VS**, Mou H, Smits SL, Dekkers DH, Müller MA, Dijkman R, Muth D, Demmers JA, Zaki A, Fouchier RA, Thiel V, Drosten C, Rottier PJ, Osterhaus AD, Bosch BJ, Haagmans BL. Dipeptidyl peptidase 4 is a functional receptor for the emerging human coronavirus-EMC. *Nature* 2013; **495**: 251-254 [PMID: [23486063](#) DOI: [10.1038/nature12005](#)]
- 54 **Wan Y**, Shang J, Graham R, Baric RS, Li F. Receptor Recognition by the Novel Coronavirus from Wuhan: an Analysis Based on Decade-Long Structural Studies of SARS Coronavirus. *J Virol* 2020; **94** [PMID: [31996437](#) DOI: [10.1128/JVI.00127-20](#)]
- 55 **Zhou P**, Yang XL, Wang XG, Hu B, Zhang L, Zhang W, Si HR, Zhu Y, Li B, Huang CL, Chen HD, Chen J, Luo Y, Guo H, Jiang RD, Liu MQ, Chen Y, Shen XR, Wang X, Zheng XS, Zhao K, Chen QJ, Deng F, Liu LL, Yan B, Zhan FX, Wang YY, Xiao GF, Shi ZL. A pneumonia outbreak associated with a new coronavirus of probable bat origin. *Nature* 2020; **579**: 270-273 [PMID: [32015507](#) DOI: [10.1038/s41586-020-2012-7](#)]
- 56 **Hamming I**, Timens W, Bulthuis ML, Lely AT, Navis G, van Goor H. Tissue distribution of ACE2 protein, the functional receptor for SARS coronavirus. A first step in understanding SARS pathogenesis. *J Pathol* 2004; **203**: 631-637 [PMID: [15141377](#) DOI: [10.1002/path.1570](#)]
- 57 **Zou X**, Chen K, Zou J, Han P, Hao J, Han Z. Single-cell RNA-seq data analysis on the receptor ACE2 expression reveals the potential risk of different human organs vulnerable to 2019-nCoV infection. *Front Med* 2020; **14**: 185-192 [PMID: [32170560](#) DOI: [10.1007/s11684-020-0754-0](#)]
- 58 **Crackower MA**, Sarao R, Oudit GY, Yagil C, Kozieradzki I, Scanga SE, Oliveira-dos-Santos AJ, da Costa J, Zhang L, Pei Y, Scholey J, Ferrario CM, Manoukian AS, Chappell MC, Backx PH, Yagil Y, Penninger JM. Angiotensin-converting enzyme 2 is an essential regulator of heart function. *Nature* 2002; **417**: 822-828 [PMID: [12075344](#) DOI: [10.1038/nature00786](#)]
- 59 **Kuba K**, Imai Y, Rao S, Gao H, Guo F, Guan B, Huan Y, Yang P, Zhang Y, Deng W, Bao L, Zhang B, Liu G, Wang Z, Chappell M, Liu Y, Zheng D, Leibbrandt A, Wada T, Slutsky AS, Liu D, Qin C, Jiang C, Penninger JM. A crucial role of angiotensin converting enzyme 2 (ACE2) in SARS coronavirus-induced lung injury. *Nat Med* 2005; **11**: 875-879 [PMID: [16007097](#) DOI: [10.1038/nm1267](#)]
- 60 **Hashimoto T**, Perlot T, Rehman A, Trichereau J, Ishiguro H, Paolino M, Sigl V, Hanada T, Hanada R, Lipinski S, Wild B, Camargo SM, Singer D, Richter A, Kuba K, Fukamizu A, Schreiber S, Clevers H, Verrey F, Rosenstiel P, Penninger JM. ACE2 links amino acid malnutrition to microbial ecology and intestinal inflammation. *Nature* 2012; **487**: 477-481 [PMID: [22837003](#) DOI: [10.1038/nature11228](#)]
- 61 **Imai Y**, Kuba K, Rao S, Huan Y, Guo F, Guan B, Yang P, Sarao R, Wada T, Leong-Poi H, Crackower MA, Fukamizu A, Hui CC, Hein L, Uhlig S, Slutsky AS, Jiang C, Penninger JM. Angiotensin-converting enzyme 2 protects from severe acute lung failure. *Nature* 2005; **436**: 112-116 [PMID: [16001071](#) DOI: [10.1038/nature03712](#)]
- 62 **Fu L**, Wang B, Yuan T, Chen X, Ao Y, Fitzpatrick T, Li P, Zhou Y, Lin YF, Duan Q, Luo G, Fan S, Lu Y, Feng A, Zhan Y, Liang B, Cai W, Zhang L, Du X, Li L, Shu Y, Zou H. Clinical characteristics of coronavirus disease 2019 (COVID-19) in China: A systematic review and meta-analysis. *J Infect* 2020; **80**: 656-665 [PMID: [32283155](#) DOI: [10.1016/j.jinf.2020.03.041](#)]
- 63 **Shi JH**, Wang YR, Li WB, Gang R, Liu X, Xu L, Luo QF. A single-center descriptive study of COVID-19 inpatients in Wuhan, analysis of digestive system performance and disease severity in 54 cases. *Zhonghua Xiaohua Zazhi* 2020; **40**: 167-170 [DOI: [10.3760/cma.j.issn.0254-1432.2020.0010](#)]
- 64 **Zhao Y**, Zhong SP, Li F, Liu GQ, Wang XF, Liu ZJ. Analysis of clinical characteristics and risk factors of gastrointestinal symptoms of COVID-19 patients in Xinyang, Henan province. *Zhonghua*

- Xiaohua Zazhi 2020; **40**: E011 [DOI: [10.3760/cma.j.issn.0254-1432.2020.0011](https://doi.org/10.3760/cma.j.issn.0254-1432.2020.0011)]
- 65 **Stratigos JD**, Katsambas A. Pellagra: a still existing disease. *Br J Dermatol* 1977; **96**: 99-106 [PMID: [843444](https://pubmed.ncbi.nlm.nih.gov/843444/) DOI: [10.1111/j.1365-2133.1977.tb05197.x](https://doi.org/10.1111/j.1365-2133.1977.tb05197.x)]
- 66 **Darby WJ**, McNutt KW, Todhunter EN. Niacin. *Nutr Rev* 1975; **33**: 289-297 [PMID: [1105246](https://pubmed.ncbi.nlm.nih.gov/1105246/) DOI: [10.1111/j.1753-4887.1975.tb05075.x](https://doi.org/10.1111/j.1753-4887.1975.tb05075.x)]
- 67 **Segal I**, Ou Tim L, Demetriou A, Paterson A, Hale M, Leros M. Rectal manifestations of pellagra. *Int J Colorectal Dis* 1986; **1**: 238-243 [PMID: [3598318](https://pubmed.ncbi.nlm.nih.gov/3598318/) DOI: [10.1007/BF01648345](https://doi.org/10.1007/BF01648345)]
- 68 **He L**, Ding Y, Zhang Q, Che X, He Y, Shen H, Wang H, Li Z, Zhao L, Geng J, Deng Y, Yang L, Li J, Cai J, Qiu L, Wen K, Xu X, Jiang S. Expression of elevated levels of pro-inflammatory cytokines in SARS-CoV-infected ACE2+ cells in SARS patients: relation to the acute lung injury and pathogenesis of SARS. *J Pathol* 2006; **210**: 288-297 [PMID: [17031779](https://pubmed.ncbi.nlm.nih.gov/17031779/) DOI: [10.1002/path.2067](https://doi.org/10.1002/path.2067)]
- 69 **Cheung CY**, Poon LL, Ng IH, Luk W, Sia SF, Wu MH, Chan KH, Yuen KY, Gordon S, Guan Y, Peiris JS. Cytokine responses in severe acute respiratory syndrome coronavirus-infected macrophages in vitro: possible relevance to pathogenesis. *J Virol* 2005; **79**: 7819-7826 [PMID: [15919935](https://pubmed.ncbi.nlm.nih.gov/15919935/) DOI: [10.1128/JVI.79.12.7819-7826.2005](https://doi.org/10.1128/JVI.79.12.7819-7826.2005)]
- 70 **Lau SKP**, Lau CCY, Chan KH, Li CPY, Chen H, Jin DY, Chan JFW, Woo PCY, Yuen KY. Delayed induction of proinflammatory cytokines and suppression of innate antiviral response by the novel Middle East respiratory syndrome coronavirus: implications for pathogenesis and treatment. *J Gen Virol* 2013; **94**: 2679-2690 [PMID: [24077366](https://pubmed.ncbi.nlm.nih.gov/24077366/) DOI: [10.1099/vir.0.055533-0](https://doi.org/10.1099/vir.0.055533-0)]
- 71 **Law HK**, Cheung CY, Ng HY, Sia SF, Chan YO, Luk W, Nicholls JM, Peiris JS, Lau YL. Chemokine up-regulation in SARS-coronavirus-infected, monocyte-derived human dendritic cells. *Blood* 2005; **106**: 2366-2374 [PMID: [15860669](https://pubmed.ncbi.nlm.nih.gov/15860669/) DOI: [10.1182/blood-2004-10-4166](https://doi.org/10.1182/blood-2004-10-4166)]
- 72 **Gu J**, Korteweg C. Pathology and pathogenesis of severe acute respiratory syndrome. *Am J Pathol* 2007; **170**: 1136-1147 [PMID: [17392154](https://pubmed.ncbi.nlm.nih.gov/17392154/) DOI: [10.2353/ajpath.2007.061088](https://doi.org/10.2353/ajpath.2007.061088)]
- 73 **Cao X**. COVID-19: immunopathology and its implications for therapy. *Nat Rev Immunol* 2020; **20**: 269-270 [PMID: [32273594](https://pubmed.ncbi.nlm.nih.gov/32273594/) DOI: [10.1038/s41577-020-0308-3](https://doi.org/10.1038/s41577-020-0308-3)]
- 74 **Lodigiani C**, Iapichino G, Carenzo L, Cecconi M, Ferrazzi P, Sebastian T, Kucher N, Studt JD, Sacco C, Bertuzzi A, Sandri MT, Barco S; Humanitas COVID-19 Task Force. Venous and arterial thromboembolic complications in COVID-19 patients admitted to an academic hospital in Milan, Italy. *Thromb Res* 2020; **191**: 9-14 [PMID: [32353746](https://pubmed.ncbi.nlm.nih.gov/32353746/) DOI: [10.1016/j.thromres.2020.04.024](https://doi.org/10.1016/j.thromres.2020.04.024)]
- 75 **Bhayana R**, Som A, Li MD, Carey DE, Anderson MA, Blake MA, Catalano O, Gee MS, Hahn PF, Harisinghani M, Kilcoyne A, Lee SI, Mojtaba A, Pandharipande PV, Pierce TT, Rosman DA, Saini S, Samir AE, Simeone JF, Gervais DA, Velmahos G, Misdrabi J, Kambadakone A. Abdominal Imaging Findings in COVID-19: Preliminary Observations. *Radiology* 2020; **297**: E207-E215 [PMID: [32391742](https://pubmed.ncbi.nlm.nih.gov/32391742/) DOI: [10.1148/radiol.2020201908](https://doi.org/10.1148/radiol.2020201908)]
- 76 **Parry AH**, Wani AH, Yaseen M. Acute Mesenteric Ischemia in Severe Coronavirus-19 (COVID-19): Possible Mechanisms and Diagnostic Pathway. *Acad Radiol* 2020; **27**: 1190 [PMID: [32475635](https://pubmed.ncbi.nlm.nih.gov/32475635/) DOI: [10.1016/j.acra.2020.05.016](https://doi.org/10.1016/j.acra.2020.05.016)]
- 77 **Panigada M**, Bottino N, Tagliabue P, Grasselli G, Novembrino C, Chantarangkul V, Pesenti A, Peyvandi F, Tripodi A. Hypercoagulability of COVID-19 patients in intensive care unit: A report of thromboelastography findings and other parameters of hemostasis. *J Thromb Haemost* 2020; **18**: 1738-1742 [PMID: [32302438](https://pubmed.ncbi.nlm.nih.gov/32302438/) DOI: [10.1111/jth.14850](https://doi.org/10.1111/jth.14850)]
- 78 **Pons S**, Fodil S, Azoulay E, Zafrani L. The vascular endothelium: the cornerstone of organ dysfunction in severe SARS-CoV-2 infection. *Crit Care* 2020; **24**: 353 [PMID: [32546188](https://pubmed.ncbi.nlm.nih.gov/32546188/) DOI: [10.1186/s13054-020-03062-7](https://doi.org/10.1186/s13054-020-03062-7)]
- 79 **Miesbach W**, Makris M. COVID-19: Coagulopathy, Risk of Thrombosis, and the Rationale for Anticoagulation. *Clin Appl Thromb Hemost* 2020; **26**: 1076029620938149 [PMID: [32677459](https://pubmed.ncbi.nlm.nih.gov/32677459/) DOI: [10.1177/1076029620938149](https://doi.org/10.1177/1076029620938149)]
- 80 **The Lancet Haematology**. COVID-19 coagulopathy: an evolving story. *Lancet Haematol* 2020; **7**: e425 [PMID: [32470428](https://pubmed.ncbi.nlm.nih.gov/32470428/) DOI: [10.1016/S2352-3026\(20\)30151-4](https://doi.org/10.1016/S2352-3026(20)30151-4)]
- 81 **Galanis N**, Stavrika C, Agathangelidis F, Petsatodis E, Giannoulou C, Givissis P. Coagulopathy in COVID-19 infection: a case of acute upper limb ischemia. *J Surg Case Rep* 2020; **2020**: rjaa204 [PMID: [32661487](https://pubmed.ncbi.nlm.nih.gov/32661487/) DOI: [10.1093/jscr/rjaa204](https://doi.org/10.1093/jscr/rjaa204)]
- 82 **Budden KF**, Gellatly SL, Wood DL, Cooper MA, Morrison M, Hugenholtz P, Hansbro PM. Emerging pathogenic links between microbiota and the gut-lung axis. *Nat Rev Microbiol* 2017; **15**: 55-63 [PMID: [27694885](https://pubmed.ncbi.nlm.nih.gov/27694885/) DOI: [10.1038/nrmicro.2016.142](https://doi.org/10.1038/nrmicro.2016.142)]
- 83 **Domínguez-Díaz C**, García-Orozco A, Riera-Leal A, Padilla-Arellano JR, Fafutis-Morris M. Microbiota and Its Role on Viral Evasion: Is It With Us or Against Us? *Front Cell Infect Microbiol* 2019; **9**: 256 [PMID: [31380299](https://pubmed.ncbi.nlm.nih.gov/31380299/) DOI: [10.3389/fcimb.2019.00256](https://doi.org/10.3389/fcimb.2019.00256)]
- 84 **Wang J**, Li F, Wei H, Lian ZX, Sun R, Tian Z. Respiratory influenza virus infection induces intestinal immune injury via microbiota-mediated Th17 cell-dependent inflammation. *J Exp Med* 2014; **211**: 2397-2410 [PMID: [25366965](https://pubmed.ncbi.nlm.nih.gov/25366965/) DOI: [10.1084/jem.20140625](https://doi.org/10.1084/jem.20140625)]
- 85 **Papadakis KA**, Prehn J, Nelson V, Cheng L, Binder SW, Ponath PD, Andrew DP, Targan SR. The role of thymus-expressed chemokine and its receptor CCR9 on lymphocytes in the regional specialization of the mucosal immune system. *J Immunol* 2000; **165**: 5069-5076 [PMID: [11046037](https://pubmed.ncbi.nlm.nih.gov/11046037/) DOI: [10.4049/jimmunol.165.9.5069](https://doi.org/10.4049/jimmunol.165.9.5069)]
- 86 **Stenstad H**, Ericsson A, Johansson-Lindbom B, Svensson M, Marsal J, Mack M, Picarella D, Soler D, Marquez G, Briskin M, Agace WW. Gut-associated lymphoid tissue-primed CD4+ T cells display CCR9-dependent and -independent homing to the small intestine. *Blood* 2006; **107**: 3447-3454



- [PMID: 16391017 DOI: 10.1182/blood-2005-07-2860]
- 87 **Crowe CR**, Chen K, Pociask DA, Alcorn JF, Krivich C, Enelow RI, Ross TM, Witztum JL, Kolls JK. Critical role of IL-17RA in immunopathology of influenza infection. *J Immunol* 2009; **183**: 5301-5310 [PMID: 19783685 DOI: 10.4049/jimmunol.0900995]
  - 88 **Zhang D**, Li S, Wang N, Tan HY, Zhang Z, Feng Y. The Cross-Talk Between Gut Microbiota and Lungs in Common Lung Diseases. *Front Microbiol* 2020; **11**: 301 [PMID: 32158441 DOI: 10.3389/fmicb.2020.00301]
  - 89 **Tripathi A**, Debelius J, Brenner DA, Karin M, Lomboa R, Schnabl B, Knight R. The gut-liver axis and the intersection with the microbiome. *Nat Rev Gastroenterol Hepatol* 2018; **15**: 397-411 [PMID: 29748586 DOI: 10.1038/s41575-018-0011-z]
  - 90 **Hu Y**, Lu GZ, Xu J. Discussion on symptoms of digestive tract caused by novel coronavirus infection. *Zhonghua Chuanranbing Zazhi* 2020; **38**: E022-E022 [DOI: 10.3760/cma.j.cn311365-20200220-00094]
  - 91 **Zhang FC**, Yin ZB, Tang XP. Clinical analysis of 260 cases of SARS in Guangzhou. *Zhonghua Chuanranbing Zazhi* 2003; **21**: 84-88
  - 92 **Leung WK**, To KF, Chan PK, Chan HL, Wu AK, Lee N, Yuen KY, Sung JJ. Enteric involvement of severe acute respiratory syndrome-associated coronavirus infection. *Gastroenterology* 2003; **125**: 1011-1017 [PMID: 14517783 DOI: 10.1016/s0016-5085(03)01215-0]
  - 93 **Fang D**, Ma JD, Guan JL, Wang MR, Song Y, Tian DA, Li PY. A single-center, descriptive study on the digestive system of COVID-19 inpatients in wuhan. *Zhonghua Xiaohua Zazhi* 2020; **40**: E005-E005
  - 94 **Chinese Society of Gastroenterology**. Expert consensus on diagnosis and treatment of covid-19 digestive system. *Zhongguo Yishi Zazhi* 2020; **100** [DOI: 10.3760/cma.j.cn112137-20200308-00645]
  - 95 **Kocielek LK**, Gerding DN. Breakthroughs in the treatment and prevention of Clostridium difficile infection. *Nat Rev Gastroenterol Hepatol* 2016; **13**: 150-160 [PMID: 26860266 DOI: 10.1038/nrgastro.2015.220]
  - 96 **Perisetti A**, Gajendran M, Goyal H. Putative Mechanisms of Diarrhea in COVID-19. *Clin Gastroenterol Hepatol* 2020; **18**: 3054-3055 [PMID: 32535231 DOI: 10.1016/j.cgh.2020.06.008]
  - 97 **Strand DS**, Kim D, Peura DA. 25 Years of Proton Pump Inhibitors: A Comprehensive Review. *Gut Liver* 2017; **11**: 27-37 [PMID: 27840364 DOI: 10.5009/gnl15502]
  - 98 **Robinson M**. Review article: pH, healing and symptom relief with rabeprazole treatment in acid-related disorders. *Aliment Pharmacol Ther* 2004; **20** Suppl 6: 30-37 [PMID: 15496216 DOI: 10.1111/j.1365-2036.2004.02163.x]
  - 99 **Xiao X**, Chakraborti S, Dimitrov AS, Gramatikoff K, Dimitrov DS. The SARS-CoV S glycoprotein: expression and functional characterization. *Biochem Biophys Res Commun* 2003; **312**: 1159-1164 [PMID: 14651994 DOI: 10.1016/j.bbrc.2003.11.054]
  - 100 **Darnell ME**, Subbarao K, Feinstone SM, Taylor DR. Inactivation of the coronavirus that induces severe acute respiratory syndrome, SARS-CoV. *J Virol Methods* 2004; **121**: 85-91 [PMID: 15350737 DOI: 10.1016/j.jviromet.2004.06.006]
  - 101 **Chan KH**, Sridhar S, Zhang RR, Chu H, Fung AY, Chan G, Chan JF, To KK, Hung IF, Cheng VC, Yuen KY. Factors affecting stability and infectivity of SARS-CoV-2. *J Hosp Infect* 2020; **106**: 226-231 [PMID: 32652214 DOI: 10.1016/j.jhin.2020.07.009]
  - 102 **Zhou L**, Niu Z, Jiang X, Zhang Z, Zheng Y, Wang Z, Zhu Y, Gao L, Wang X, Sun Q. Systemic analysis of tissue cells potentially vulnerable to SARS-CoV-2 infection by the protein-proofed single-cell RNA profiling of ACE2, TMPRSS2 and Furin proteases. 2020 Preprint. Available from: bioRxiv:2020.2004.2006.028522 [DOI: 10.1101/2020.04.06.028522]
  - 103 **Ramachandran P**, Perisetti A, Gajendran M, Jean-Louis F, Bansal P, Dwivedi AK, Goyal H. Pre-hospitalization proton pump inhibitor use and clinical outcomes in COVID-19. *Eur J Gastroenterol Hepatol* 2020 [PMID: 33252418 DOI: 10.1097/MEG.0000000000002013]
  - 104 **Yang J**, Zheng Y, Gou X, Pu K, Chen Z, Guo Q, Ji R, Wang H, Wang Y, Zhou Y. Prevalence of comorbidities and its effects in patients infected with SARS-CoV-2: a systematic review and meta-analysis. *Int J Infect Dis* 2020; **94**: 91-95 [PMID: 32173574 DOI: 10.1016/j.ijid.2020.03.017]
  - 105 **Mao R**, Liang J, Shen J, Ghosh S, Zhu LR, Yang H, Wu KC, Chen MH; Chinese Society of IBD, Chinese Elite IBD Union; Chinese IBD Quality Care Evaluation Center Committee. Implications of COVID-19 for patients with pre-existing digestive diseases. *Lancet Gastroenterol Hepatol* 2020; **5**: 425-427 [PMID: 32171057 DOI: 10.1016/S2468-1253(20)30076-5]
  - 106 **An P**, Ji M, Ren H, Su J, Kang J, Yin A, Zhou Q, Shen L, Zhao L, Jiang X, Xiao Y, Tan W, Lv X, Li J, Liu S, Zhou J, Chen H, Xu Y, Liu J, Ding Y. Protection of 318 Inflammatory Bowel Disease Patients from the Outbreak and Rapid Spread of COVID-19 Infection in Wuhan, China. *SSRN Electronic J* 2020 [DOI: 10.2139/ssrn.3543590]
  - 107 **Danese S**, Cecconi M, Spinelli A. Management of IBD during the COVID-19 outbreak: resetting clinical priorities. *Nat Rev Gastroenterol Hepatol* 2020; **17**: 253-255 [PMID: 32214232 DOI: 10.1038/s41575-020-0294-8]
  - 108 **British Society of Gastroenterology (BSG)**. British Society of Gastroenterology (BSG) advice for management of inflammatory bowel diseases during the COVID-19 pandemic. 2020. [cited 22 March 2020]. Available from: <https://www.bsg.org.uk/covid-19-advice/bsg-advice-for-management-of-inflammatory-bowel-diseases-during-the-covid-19-pandemic/>
  - 109 **Lamb CA**, Kennedy NA, Raine T, Hendy PA, Smith PJ, Limdi JK, Hayee B, Lomer MCE, Parkes GC, Selinger C, Barrett KJ, Davies RJ, Bennett C, Gittens S, Dunlop MG, Faiz O, Fraser A, Garrick

- V, Johnston PD, Parkes M, Sanderson J, Terry H; IBD guidelines eDelphi consensus group, Gaya DR, Iqbal TH, Taylor SA, Smith M, Brookes M, Hansen R, Hawthorne AB. British Society of Gastroenterology consensus guidelines on the management of inflammatory bowel disease in adults. *Gut* 2019; **68**: s1-s106 [PMID: 31562236 DOI: 10.1136/gutjnl-2019-318484]
- 110 **Rubin DT**, Abreu MT, Rai V, Siegel CA; International Organization for the Study of Inflammatory Bowel Disease. Management of Patients With Crohn's Disease and Ulcerative Colitis During the Coronavirus Disease-2019 Pandemic: Results of an International Meeting. *Gastroenterology* 2020; **159**: 6-13.e6 [PMID: 32272113 DOI: 10.1053/j.gastro.2020.04.002]
- 111 **Queiroz NSF**, Barros LL, Azevedo MFC, Oba J, Sobrado CW, Carlos AS, Milani LR, Sipahi AM, Damião AOMC. Management of inflammatory bowel disease patients in the COVID-19 pandemic era: a Brazilian tertiary referral center guidance. *Clinics (Sao Paulo)* 2020; **75**: e1909 [PMID: 32321117 DOI: 10.6061/clinics/2020/e1909]
- 112 **Lei S**, Jiang F, Su W, Chen C, Chen J, Mei W, Zhan LY, Jia Y, Zhang L, Liu D, Xia ZY, Xia Z. Clinical characteristics and outcomes of patients undergoing surgeries during the incubation period of COVID-19 infection. *EClinicalMedicine* 2020; **21**: 100331 [PMID: 32292899 DOI: 10.1016/j.eclim.2020.100331]
- 113 **SAGES**. SAGES and EAES recommendations regarding surgical response to COVID-19 crisis. 2020. [cited 29 March 2020]. Available from: <http://www.sages.org/recommendations-surgical-response-covid-19/>
- 114 **CBCD**. Posicionamento do CBCD quanto ao COVID-19. 2020. [cited 1 April 2020]. Available from: <http://www.cbcd.org.br/cbcdnews/2020/posicionamento-do-cbcd-quantoao-covid-19/>
- 115 **Holshue ML**, DeBolt C, Lindquist S, Lofy KH, Wiesman J, Bruce H, Spitters C, Ericson K, Wilkerson S, Tural A, Diaz G, Cohn A, Fox L, Patel A, Gerber SI, Kim L, Tong S, Lu X, Lindstrom S, Pallansch MA, Weldon WC, Biggs HM, Uyeki TM, Pillai SK; Washington State 2019-nCoV Case Investigation Team. First Case of 2019 Novel Coronavirus in the United States. *N Engl J Med* 2020; **382**: 929-936 [PMID: 32004427 DOI: 10.1056/NEJMoa2001191]
- 116 **Yeo C**, Kaushal S, Yeo D. Enteric involvement of coronaviruses: is faecal-oral transmission of SARS-CoV-2 possible? *Lancet Gastroenterol Hepatol* 2020; **5**: 335-337 [PMID: 32087098 DOI: 10.1016/S2468-1253(20)30048-0]
- 117 **Wang W**, Xu Y, Gao R, Lu R, Han K, Wu G, Tan W. Detection of SARS-CoV-2 in Different Types of Clinical Specimens. *JAMA* 2020; **323**: 1843-1844 [PMID: 32159775 DOI: 10.1001/jama.2020.3786]
- 118 **Chen L**, Lou J, Bai Y, Wang M. COVID-19 Disease With Positive Fecal and Negative Pharyngeal and Sputum Viral Tests. *Am J Gastroenterol* 2020; **115**: 790 [PMID: 32205644 DOI: 10.14309/ajg.0000000000000610]
- 119 **Wu Y**, Guo C, Tang L, Hong Z, Zhou J, Dong X, Yin H, Xiao Q, Tang Y, Qu X, Kuang L, Fang X, Mishra N, Lu J, Shan H, Jiang G, Huang X. Prolonged presence of SARS-CoV-2 viral RNA in faecal samples. *Lancet Gastroenterol Hepatol* 2020; **5**: 434-435 [PMID: 32199469 DOI: 10.1016/S2468-1253(20)30083-2]
- 120 **Li C**, Liu P, Guo SS, Zhao ZG. Study on the mechanism and treatment of COVID-19, SARS and MERS with gastrointestinal symptoms. *Zhonghua Xiaohua Zazhi* 2020; **40** [DOI: 10.3760/cma.j.issn.0254-1432.2020.0009]
- 121 **Wilkins T**, Sequoia J. Probiotics for Gastrointestinal Conditions: A Summary of the Evidence. *Am Fam Physician* 2017; **96**: 170-178 [PMID: 28762696 DOI: 10.1016/j.tgie.2017.03.008]
- 122 Diagnosis and Treatment Protocol for Novel Coronavirus Pneumonia (Trial Version 7). *Chin Med J (Engl)* 2020; **133**: 1087-1095 [PMID: 32358325 DOI: 10.1097/CM9.0000000000000819]
- 123 **Chen Y**, Guo Y, Pan Y, Zhao ZJ. Structure analysis of the receptor binding of 2019-nCoV. *Biochem Biophys Res Commun* 2020 [PMID: 32081428 DOI: 10.1016/j.bbrc.2020.02.071]
- 124 **Damaso CR**, Oliveira MF, Massarani SM, Moussatché N. Azathioprine inhibits vaccinia virus replication in both BSC-40 and RAG cell lines acting on different stages of virus cycle. *Virology* 2002; **300**: 79-91 [PMID: 12202208 DOI: 10.1006/viro.2002.1534]
- 125 **Hersberger L**, Bargetzi L, Bargetzi A, Tribolet P, Fehr R, Baechli V, Geiser M, Deiss M, Gomes F, Kutz A, Kägi-Braun N, Hoess C, Pavlicek V, Schmid S, Bilz S, Sigrist S, Brändle M, Benz C, Henzen C, Nigg M, Thomann R, Brand C, Rutishauser J, Aujesky D, Rodondi N, Donzé J, Stanga Z, Mueller B, Schuetz P. Nutritional risk screening (NRS 2002) is a strong and modifiable predictor risk score for short-term and long-term clinical outcomes: secondary analysis of a prospective randomised trial. *Clin Nutr* 2020; **39**: 2720-2729 [PMID: 31882232 DOI: 10.1016/j.clnu.2019.11.041]
- 126 **Xu L**, Liu J, Lu M, Yang D, Zheng X. Liver injury during highly pathogenic human coronavirus infections. *Liver Int* 2020; **40**: 998-1004 [PMID: 32170806 DOI: 10.1111/liv.14435]
- 127 **Kukla M**, Skonieczna-Żydecka K, Kotfis K, Maciejewska D, Łoniewski I, Lara LF, Pazgan-Simon M, Stachowska E, Kaczmarczyk M, Koulaouzidis A, Marlicz W. COVID-19, MERS and SARS with Concomitant Liver Injury-Systematic Review of the Existing Literature. *J Clin Med* 2020; **9** [PMID: 32403255 DOI: 10.3390/jcm9051420]
- 128 **Richardson S**, Hirsch JS, Narasimhan M, Crawford JM, McGinn T, Davidson KW; the Northwell COVID-19 Research Consortium, Barnaby DP, Becker LB, Chelico JD, Cohen SL, Cookingham J, Coppa K, Diefenbach MA, Dominello AJ, Duer-Hefele J, Falzon L, Gitlin J, Hajizadeh N, Harvin TG, Hirschwerk DA, Kim EJ, Kozel ZM, Marrast LM, Mogavero JN, Osorio GA, Qiu M, Zanos TP. Presenting Characteristics, Comorbidities, and Outcomes Among 5700 Patients Hospitalized With

- COVID-19 in the New York City Area. *JAMA* 2020; **323**: 2052-2059 [PMID: [32320003](#) DOI: [10.1001/jama.2020.6775](#)]
- 129 **Cai Q**, Huang D, Yu H, Zhu Z, Xia Z, Su Y, Li Z, Zhou G, Gou J, Qu J, Sun Y, Liu Y, He Q, Chen J, Liu L, Xu L. COVID-19: Abnormal liver function tests. *J Hepatol* 2020; **73**: 566-574 [PMID: [32298767](#) DOI: [10.1016/j.jhep.2020.04.006](#)]
  - 130 **Parohan M**, Yaghoubi S, Seraji A. Liver injury is associated with severe coronavirus disease 2019 (COVID-19) infection: A systematic review and meta-analysis of retrospective studies. *Hepatol Res* 2020; **50**: 924-935 [PMID: [32386449](#) DOI: [10.1111/hepr.13510](#)]
  - 131 **Bloom PP**, Meyerowitz EA, Reinus Z, Daidone M, Gustafson J, Kim AY, Schaefer E, Chung RT. Liver Biochemistries in Hospitalized Patients With COVID-19. *Hepatology* 2021; **73**: 890-900 [PMID: [32415860](#) DOI: [10.1002/hep.31326](#)]
  - 132 **Lei F**, Liu YM, Zhou F, Qin JJ, Zhang P, Zhu L, Zhang XJ, Cai J, Lin L, Ouyang S, Wang X, Yang C, Cheng X, Liu W, Li H, Xie J, Wu B, Luo H, Xiao F, Chen J, Tao L, Cheng G, She ZG, Zhou J, Wang H, Lin J, Luo P, Fu S, Ye P, Xiao B, Mao W, Liu L, Yan Y, Chen G, Huang X, Zhang BH, Yuan Y. Longitudinal Association Between Markers of Liver Injury and Mortality in COVID-19 in China. *Hepatology* 2020; **72**: 389-398 [PMID: [32359177](#) DOI: [10.1002/hep.31301](#)]
  - 133 **Xie H**, Zhao J, Lian N, Lin S, Xie Q, Zhuo H. Clinical characteristics of non-ICU hospitalized patients with coronavirus disease 2019 and liver injury: A retrospective study. *Liver Int* 2020; **40**: 1321-1326 [PMID: [32239591](#) DOI: [10.1111/liv.14449](#)]
  - 134 **Fan Z**, Chen L, Li J, Cheng X, Yang J, Tian C, Zhang Y, Huang S, Liu Z, Cheng J. Clinical Features of COVID-19-Related Liver Functional Abnormality. *Clin Gastroenterol Hepatol* 2020; **18**: 1561-1566 [PMID: [32283325](#) DOI: [10.1016/j.cgh.2020.04.002](#)]
  - 135 **Zhang B**, Zhou X, Qiu Y, Feng F, Feng J, Jia Y, Zhu H, Hu K, Liu J, Liu Z, Wang S, Gong Y, Zhou C, Zhu T, Cheng Y, Deng H, Tao F, Ren Y, Cheng B, Gao L, Wu X, Yu L, Huang Z, Mao Z, Song Q, Zhu B, Wang J. Clinical characteristics of 82 death cases with COVID-19. 2020 Preprint. Available from: medRxiv:2020.2002.2026.20028191 [DOI: [10.1101/2020.02.26.20028191](#)]
  - 136 **Gordon DE**, Jang GM, Bouhaddou M, Xu J, Obernier K, White KM, O'Meara MJ, Rezelj VV, Guo JZ, Swaney DL, Tummino TA, Hüttenhain R, Kaake RM, Richards AL, Tutuncuoglu B, Foussard H, Batra J, Haas K, Modak M, Kim M, Haas P, Polacco BJ, Braberg H, Fabius JM, Eckhardt M, Soucheray M, Bennett MJ, Cakir M, McGregor MJ, Li Q, Meyer B, Roesch F, Vallet T, Mac Kain A, Miorin L, Moreno E, Naing ZZC, Zhou Y, Peng S, Shi Y, Zhang Z, Shen W, Kirby IT, Melnyk JE, Chorbha JS, Lou K, Dai SA, Barrio-Hernandez I, Memon D, Hernandez-Armenta C, Lyu J, Mathy CJP, Perica T, Pilla KB, Ganesan SJ, Saltzberg DJ, Rakesh R, Liu X, Rosenthal SB, Calviello L, Venkataramanan S, Liboy-Lugo J, Lin Y, Huang XP, Liu Y, Wankowicz SA, Bohn M, Safari M, Ugur FS, Koh C, Savar NS, Tran QD, Shengjuler D, Fletcher SJ, O'Neal MC, Cai Y, Chang JCJ, Broadhurst DJ, Klippsten S, Sharp PP, Wenzell NA, Kuzuoglu-Ozturk D, Wang HY, Trenker R, Young JM, Cavero DA, Hiatt J, Roth TL, Rathore U, Subramanian A, Noack J, Hubert M, Stroud RM, Frankel AD, Rosenberg OS, Verba KA, Agard DA, Ott M, Emerman M, Jura N, von Zastrow M, Verdin E, Ashworth A, Schwartz O, d'Enfert C, Mukherjee S, Jacobson M, Malik HS, Fujimori DG, Ideker T, Craik CS, Floor SN, Fraser JS, Gross JD, Sali A, Roth BL, Ruggero D, Taunton J, Kortemme T, Beltrao P, Vignuzzi M, García-Sastre A, Shokat KM, Shoichet BK, Krogan NJ. A SARS-CoV-2 protein interaction map reveals targets for drug repurposing. *Nature* 2020; **583**: 459-468 [PMID: [32353859](#) DOI: [10.1038/s41586-020-2286-9](#)]
  - 137 **Wang Y**, Liu S, Liu H, Li W, Lin F, Jiang L, Li X, Xu P, Zhang L, Zhao L, Cao Y, Kang J, Yang J, Li L, Liu X, Li Y, Nie R, Mu J, Lu F, Zhao S, Lu J, Zhao J. SARS-CoV-2 infection of the liver directly contributes to hepatic impairment in patients with COVID-19. *J Hepatol* 2020; **73**: 807-816 [PMID: [32437830](#) DOI: [10.1016/j.jhep.2020.05.002](#)]
  - 138 **Sarin SK**, Choudhury A, Lau GK, Zheng MH, Ji D, Abd-Elsalam S, Hwang J, Qi X, Cua IH, Suh JJ, Park JG, Putharoen O, Kaewdech A, Piratvisuth T, Treeprasertsuk S, Park S, Wejnaruemarn S, Payawal DA, Baatarkhuu O, Ahn SH, Yeo CD, Alonzo UR, Chinbayar T, Loho IM, Yokosuka O, Jafri W, Tan S, Soo LI, Tanwandee T, Gani R, Anand L, Esmail ES, Khalaf M, Alam S, Lin CY, Chuang WL, Soin AS, Garg HK, Kalista K, Batsukh B, Purnomo HD, Dara VP, Rath P, Al Mahtab M, Shukla A, Sharma MK, Omata M; APASL COVID Task Force, APASL COVID Liver Injury Spectrum Study (APCOLIS Study-NCT 04345640). Pre-existing liver disease is associated with poor outcome in patients with SARS CoV2 infection; The APCOLIS Study (APASL COVID-19 Liver Injury Spectrum Study). *Hepatol Int* 2020; **14**: 690-700 [PMID: [32623632](#) DOI: [10.1007/s12072-020-10072-8](#)]
  - 139 **Xu Z**, Shi L, Wang Y, Zhang J, Huang L, Zhang C, Liu S, Zhao P, Liu H, Zhu L, Tai Y, Bai C, Gao T, Song J, Xia P, Dong J, Zhao J, Wang FS. Pathological findings of COVID-19 associated with acute respiratory distress syndrome. *Lancet Respir Med* 2020; **8**: 420-422 [PMID: [32085846](#) DOI: [10.1016/S2213-2600\(20\)30076-X](#)]
  - 140 **Liu Q**, Wang RS, Qu GQ, Wang YY, Liu P, Zhu YZ, Fei G, Ren L, Zhou YW, Liu L. Gross examination report of a COVID-19 death autopsy. *Fa Yi Xue Za Zhi* 2020; **36**: 21-23 [PMID: [32198987](#) DOI: [10.12116/j.issn.1004-5619.2020.01.005](#)]
  - 141 **Sonzogni A**, Previtali G, Seghezzi M, Alessio MG, Gianatti A, Licini L, Zerbi P, Carsana L, Rossi R, Lauri E, Pellegrinelli A, Nebuloni M. Liver and COVID 19 Infection: A Very Preliminary Lesson Learnt from Histological Post-mortem Findings in 48 patients. 2020 Preprint. Available from: medRxiv:2020040438 [DOI: [10.20944/preprints202004.0438.v1](#)]
  - 142 **Boettler T**, Newsome PN, Mondelli MU, Maticic M, Cordero E, Cornberg M, Berg T. Care of

- patients with liver disease during the COVID-19 pandemic: EASL-ESCMID position paper. *JHEP Rep* 2020; **2**: 100113 [PMID: 32289115 DOI: 10.1016/j.jhepr.2020.100113]
- 143 Li Y, Xiao SY. Hepatic involvement in COVID-19 patients: Pathology, pathogenesis, and clinical implications. *J Med Virol* 2020; **92**: 1491-1494 [PMID: 32369204 DOI: 10.1002/jmv.25973]
  - 144 Ramachandran P, Perisetti A, Gajendran M, Chakraborti A, Narh JT, Goyal H. Increased Serum Aminotransferase Activity and Clinical Outcomes in Coronavirus Disease 2019. *J Clin Exp Hepatol* 2020; **10**: 533-539 [PMID: 32837096 DOI: 10.1016/j.jceh.2020.06.009]
  - 145 SOHU News. Doctor blackened after successful rescue? Expert: It could be multiple organ damage [in Chinese]. 2020. [cited 14 January 2021]. Available from: [https://www.sohu.com/a/389423079\\_160789](https://www.sohu.com/a/389423079_160789)
  - 146 Zhu Y. Skin darkens in patients with COVID-19: don't ignore the medical reasons. *Health J* 2020; **9**: 1-2
  - 147 Liu X, Xue R, Yang C, Gu J, Chen S, Zhang S. Cholestasis-induced bile acid elevates estrogen level via farnesoid X receptor-mediated suppression of the estrogen sulfotransferase SULT1E1. *J Biol Chem* 2018; **293**: 12759-12769 [PMID: 29929982 DOI: 10.1074/jbc.RA118.001789]
  - 148 Jee SH, Lee SY, Chiu HC, Chang CC, Chen TJ. Effects of estrogen and estrogen receptor in normal human melanocytes. *Biochem Biophys Res Commun* 1994; **199**: 1407-1412 [PMID: 8147884 DOI: 10.1006/bbrc.1994.1387]
  - 149 Burra P. Liver abnormalities and endocrine diseases. *Best Pract Res Clin Gastroenterol* 2013; **27**: 553-563 [PMID: 24090942 DOI: 10.1016/j.bpg.2013.06.014]
  - 150 Wang CY, Babitt JL. Liver iron sensing and body iron homeostasis. *Blood* 2019; **133**: 18-29 [PMID: 30401708 DOI: 10.1182/blood-2018-06-815894]
  - 151 Graham RM, Chua AC, Herbison CE, Olynyk JK, Trinder D. Liver iron transport. *World J Gastroenterol* 2007; **13**: 4725-4736 [PMID: 17729394 DOI: 10.3748/wjg.v13.i35.4725]
  - 152 Xu X, Chen P, Wang J, Feng J, Zhou H, Li X, Zhong W, Hao P. Evolution of the novel coronavirus from the ongoing Wuhan outbreak and modeling of its spike protein for risk of human transmission. *Sci China Life Sci* 2020; **63**: 457-460 [PMID: 32009228 DOI: 10.1007/s11427-020-1637-5]
  - 153 Letko M, Marzi A, Munster V. Functional assessment of cell entry and receptor usage for SARS-CoV-2 and other lineage B betacoronaviruses. *Nat Microbiol* 2020; **5**: 562-569 [PMID: 32094589 DOI: 10.1038/s41564-020-0688-y]
  - 154 Chai X, Hu L, Zhang Y, Han W, Lu Z, Ke A, Zhou J, Shi G, Fang N, Fan J, Cai J, Lan F. Specific ACE2 Expression in Cholangiocytes May Cause Liver Damage After 2019-nCoV Infection. 2020 Preprint. Available from: bioRxiv:2020 [DOI: 10.1101/2020.02.03.931766]
  - 155 Zhang Y, Zheng L, Liu L, Zhao M, Xiao J, Zhao Q. Liver impairment in COVID-19 patients: A retrospective analysis of 115 cases from a single centre in Wuhan city, China. *Liver Int* 2020; **40**: 2095-2103 [PMID: 32239796 DOI: 10.1111/liv.14455]
  - 156 Tirado SM, Yoon KJ. Antibody-dependent enhancement of virus infection and disease. *Viral Immunol* 2003; **16**: 69-86 [PMID: 12725690 DOI: 10.1089/088282403763635465]
  - 157 Wang SF, Tseng SP, Yen CH, Yang JY, Tsao CH, Shen CW, Chen KH, Liu FT, Liu WT, Chen YM, Huang JC. Antibody-dependent SARS coronavirus infection is mediated by antibodies against spike proteins. *Biochem Biophys Res Commun* 2014; **451**: 208-214 [PMID: 25073113 DOI: 10.1016/j.bbrc.2014.07.090]
  - 158 Wong CK, Lam CW, Wu AK, Ip WK, Lee NL, Chan IH, Lit LC, Hui DS, Chan MH, Chung SS, Sung JJ. Plasma inflammatory cytokines and chemokines in severe acute respiratory syndrome. *Clin Exp Immunol* 2004; **136**: 95-103 [PMID: 15030519 DOI: 10.1111/j.1365-2249.2004.02415.x]
  - 159 Channappanavar R, Perlman S. Pathogenic human coronavirus infections: causes and consequences of cytokine storm and immunopathology. *Semin Immunopathol* 2017; **39**: 529-539 [PMID: 28466096 DOI: 10.1007/s00281-017-0629-x]
  - 160 Mahallawi WH, Khabour OF, Zhang Q, Makhdom HM, Suliman BA. MERS-CoV infection in humans is associated with a pro-inflammatory Th1 and Th17 cytokine profile. *Cytokine* 2018; **104**: 8-13 [PMID: 29414327 DOI: 10.1016/j.cyto.2018.01.025]
  - 161 Tian D, Ye Q. Hepatic complications of COVID-19 and its treatment. *J Med Virol* 2020; **92**: 1818-1824 [PMID: 32437004 DOI: 10.1002/jmv.26036]
  - 162 Li X, Li X, Huang N, Liu R, Sun R. A comprehensive review and perspectives on pharmacology and toxicology of saikosaponins. *Phytomedicine* 2018; **50**: 73-87 [PMID: 30466994 DOI: 10.1016/j.phymed.2018.09.174]
  - 163 Li X, Li X, Lu J, Huang Y, Lv L, Luan Y, Liu R, Sun R. Saikosaponins induced hepatotoxicity in mice via lipid metabolism dysregulation and oxidative stress: a proteomic study. *BMC Complement Altern Med* 2017; **17**: 219 [PMID: 28420359 DOI: 10.1186/s12906-017-1733-0]
  - 164 Pan X, Zhou J, Chen Y, Xie X, Rao C, Liang J, Zhang Y, Peng C. Classification, hepatotoxic mechanisms, and targets of the risk ingredients in traditional Chinese medicine-induced liver injury. *Toxicol Lett* 2020; **323**: 48-56 [PMID: 32017980 DOI: 10.1016/j.toxlet.2020.01.026]
  - 165 Iorga A, Dara L. Cell death in drug-induced liver injury. *Adv Pharmacol* 2019; **85**: 31-74 [PMID: 31307591 DOI: 10.1016/bs.apha.2019.01.006]
  - 166 Shehu AI, Lu J, Wang P, Zhu J, Wang Y, Yang D, McMahon D, Xie W, Gonzalez FJ, Ma X. Pregnane X receptor activation potentiates ritonavir hepatotoxicity. *J Clin Invest* 2019; **129**: 2898-2903 [PMID: 31039134 DOI: 10.1172/JCI128274]
  - 167 Zha BS, Wan X, Zhang X, Zha W, Zhou J, Wabitsch M, Wang G, Lyall V, Hylemon PB, Zhou H.



- HIV protease inhibitors disrupt lipid metabolism by activating endoplasmic reticulum stress and inhibiting autophagy activity in adipocytes. *PLoS One* 2013; **8**: e59514 [PMID: [23533630](#) DOI: [10.1371/journal.pone.0059514](#)]
- 168 **Cao R**, Hu Y, Wang Y, Gurley EC, Studer EJ, Wang X, Hylemon PB, Pandak WM, Sanyal AJ, Zhang L, Zhou H. Prevention of HIV protease inhibitor-induced dysregulation of hepatic lipid metabolism by raltegravir via endoplasmic reticulum stress signaling pathways. *J Pharmacol Exp Ther* 2010; **334**: 530-539 [PMID: [20472667](#) DOI: [10.1124/jpet.110.168484](#)]
- 169 **Shen T**, Liu Y, Shang J, Xie Q, Li J, Yan M, Xu J, Niu J, Liu J, Watkins PB, Aithal GP, Andrade RJ, Dou X, Yao L, Lv F, Wang Q, Li Y, Zhou X, Zhang Y, Zong P, Wan B, Zou Z, Yang D, Nie Y, Li D, Wang Y, Han X, Zhuang H, Mao Y, Chen C. Incidence and Etiology of Drug-Induced Liver Injury in Mainland China. *Gastroenterology* 2019; **156**: 2230-2241.e11 [PMID: [30742832](#) DOI: [10.1053/j.gastro.2019.02.002](#)]
- 170 **Zhang C**, Shi L, Wang FS. Liver injury in COVID-19: management and challenges. *Lancet Gastroenterol Hepatol* 2020; **5**: 428-430 [PMID: [32145190](#) DOI: [10.1016/S2468-1253\(20\)30057-1](#)]
- 171 **Huang Y**, Gao Z. Study of the relationship SARS and hepatitis virus B. *Zhongguo Linchuang Ganbingxue Zazhi* 2003; **6**: 342-343
- 172 **Strnad P**, Tacke F, Koch A, Trautwein C. Liver - guardian, modifier and target of sepsis. *Nat Rev Gastroenterol Hepatol* 2017; **14**: 55-66 [PMID: [27924081](#) DOI: [10.1038/nrgastro.2016.168](#)]
- 173 **Xiao Y**, Pan H, She Q, Wang F, Chen M. Prevention of SARS-CoV-2 infection in patients with decompensated cirrhosis. *Lancet Gastroenterol Hepatol* 2020; **5**: 528-529 [PMID: [32197093](#) DOI: [10.1016/S2468-1253\(20\)30080-7](#)]
- 174 **Kumar D**, Tellier R, Draker R, Levy G, Humar A. Severe Acute Respiratory Syndrome (SARS) in a liver transplant recipient and guidelines for donor SARS screening. *Am J Transplant* 2003; **3**: 977-981 [PMID: [12859532](#) DOI: [10.1034/j.1600-6143.2003.00197.x](#)]
- 175 **Michaels MG**, La Hoz RM, Danziger-Isakov L, Blumberg EA, Kumar D, Green M, Pruett TL, Wolfe CR. Coronavirus disease 2019: Implications of emerging infections for transplantation. *Am J Transplant* 2020; **20**: 1768-1772 [PMID: [32090448](#) DOI: [10.1111/ajt.15832](#)]
- 176 **Gori A**, Dondossola D, Antonelli B, Mangioni D, Alagna L, Reggiani P, Bandera A, Rossi G. Coronavirus disease 2019 and transplantation: A view from the inside. *Am J Transplant* 2020; **20**: 1939-1940 [PMID: [32181969](#) DOI: [10.1111/ajt.15853](#)]
- 177 **Qin J**, Wang H, Qin X, Zhang P, Zhu L, Cai J, Yuan Y, Li H. Perioperative Presentation of COVID-19 Disease in a Liver Transplant Recipient. *Hepatology* 2020; **72**: 1491-1493 [PMID: [32220017](#) DOI: [10.1002/hep.31257](#)]
- 178 **Fraser J**, Mousley J, Testro A, Smibert OC, Koshy AN. Clinical Presentation, Treatment, and Mortality Rate in Liver Transplant Recipients With Coronavirus Disease 2019: A Systematic Review and Quantitative Analysis. *Transplant Proc* 2020; **52**: 2676-2683 [PMID: [32891405](#) DOI: [10.1016/j.transproceed.2020.07.012](#)]
- 179 **D'Antiga L**. Coronaviruses and Immunosuppressed Patients: The Facts During the Third Epidemic. *Liver Transpl* 2020; **26**: 832-834 [PMID: [32196933](#) DOI: [10.1002/lt.25756](#)]
- 180 **Webb GJ**, Marjot T, Cook JA, Aloman C, Armstrong MJ, Brenner EJ, Catana MA, Cargill T, Dhanasekaran R, García-Juárez I, Hagström H, Kennedy JM, Marshall A, Masson S, Mercer CJ, Perumalswami PV, Ruiz I, Thaker S, Ufere NN, Barnes E, Barritt AS 4th, Moon AM. Outcomes following SARS-CoV-2 infection in liver transplant recipients: an international registry study. *Lancet Gastroenterol Hepatol* 2020; **5**: 1008-1016 [PMID: [32866433](#) DOI: [10.1016/S2468-1253\(20\)30271-5](#)]
- 181 **Yang RX**, Zheng RD, Fan JG. Etiology and management of liver injury in patients with COVID-19. *World J Gastroenterol* 2020; **26**: 4753-4762 [PMID: [32921955](#) DOI: [10.3748/wjg.v26.i32.4753](#)]
- 182 **Tang JW**, Li Y, Eames I, Chan PK, Ridgway GL. Factors involved in the aerosol transmission of infection and control of ventilation in healthcare premises. *J Hosp Infect* 2006; **64**: 100-114 [PMID: [16916564](#) DOI: [10.1016/j.jhin.2006.05.022](#)]
- 183 **Lau G**, Ward JW. Synthesis of Liver Associations Recommendations for Hepatology and Liver Transplant Care During the COVID-19 Pandemic. *Clin Liver Dis (Hoboken)* 2020; **15**: 204-209 [PMID: [32489655](#) DOI: [10.1002/cld.972](#)]
- 184 **Kushner T**, Cafardi J. Chronic Liver Disease and COVID-19: Alcohol Use Disorder/Alcohol-Associated Liver Disease, Nonalcoholic Fatty Liver Disease/Nonalcoholic Steatohepatitis, Autoimmune Liver Disease, and Compensated Cirrhosis. *Clin Liver Dis (Hoboken)* 2020; **15**: 195-199 [PMID: [32537135](#) DOI: [10.1002/cld.974](#)]
- 185 **The Lancet**. COVID-19: protecting health-care workers. *Lancet* 2020; **395**: 922 [PMID: [32199474](#) DOI: [10.1016/S0140-6736\(20\)30644-9](#)]
- 186 **Wang C**, Horby PW, Hayden FG, Gao GF. A novel coronavirus outbreak of global health concern. *Lancet* 2020; **395**: 470-473 [PMID: [31986257](#) DOI: [10.1016/S0140-6736\(20\)30185-9](#)]
- 187 **Johnston ER**, Habib-Bein N, Dueker JM, Quiroz B, Corsaro E, Ambrogio M, Kingsley M, Papachristou GI, Kreiss C, Khalid A. Risk of bacterial exposure to the endoscopist's face during endoscopy. *Gastrointest Endosc* 2019; **89**: 818-824 [PMID: [30391253](#) DOI: [10.1016/j.gie.2018.10.034](#)]
- 188 **Mohandas KM**, Gopalakrishnan G. Mucocutaneous exposure to body fluids during digestive endoscopy: the need for universal precautions. *Indian J Gastroenterol* 1999; **18**: 109-111 [PMID: [10407563](#)]
- 189 **Agency for Healthcare Research and Quality**. Preventable tragedies: superbugs and how



- ineffective monitoring of medical device safety fails patients. Rockville: Agency for Healthcare Research and Quality, 2016
- 190 **Costerton JW**, Lewandowski Z, Caldwell DE, Korber DR, Lappin-Scott HM. Microbial biofilms. *Annu Rev Microbiol* 1995; **49**: 711-745 [PMID: [8561477](#) DOI: [10.1146/annurev.mi.49.100195.003431](#)]
  - 191 **Pajkos A**, Vickery K, Cossart Y. Is biofilm accumulation on endoscope tubing a contributor to the failure of cleaning and decontamination? *J Hosp Infect* 2004; **58**: 224-229 [PMID: [15501338](#) DOI: [10.1016/j.jhin.2004.06.023](#)]
  - 192 **Leung JW**, Ling TK, Chan RC, Cheung SW, Lai CW, Sung JJ, Chung SC, Cheng AF. Antibiotics, biliary sepsis, and bile duct stones. *Gastrointest Endosc* 1994; **40**: 716-721 [PMID: [7859970](#) DOI: [10.1016/S0016-5107\(94\)70115-6](#)]
  - 193 **Rerknimitr R**, Fogel EL, Kalayci C, Esber E, Lehman GA, Sherman S. Microbiology of bile in patients with cholangitis or cholestasis with and without plastic biliary endoprosthesis. *Gastrointest Endosc* 2002; **56**: 885-889 [PMID: [12447303](#) DOI: [10.1067/mge.2002.129604](#)]
  - 194 **Nelson DB**, Muscarella LF. Current issues in endoscope reprocessing and infection control during gastrointestinal endoscopy. *World J Gastroenterol* 2006; **12**: 3953-3964 [PMID: [16810740](#) DOI: [10.3748/wjg.v12.i25.3953](#)]
  - 195 **Kovaleva J**, Peters FT, van der Mei HC, Degener JE. Transmission of infection by flexible gastrointestinal endoscopy and bronchoscopy. *Clin Microbiol Rev* 2013; **26**: 231-254 [PMID: [23554415](#) DOI: [10.1128/CMR.00085-12](#)]
  - 196 **Rutala WA**, Weber DJ. Outbreaks of carbapenem-resistant Enterobacteriaceae infections associated with duodenoscopes: What can we do to prevent infections? *Am J Infect Control* 2016; **44**: e47-e51 [PMID: [27131135](#) DOI: [10.1016/j.ajic.2015.10.037](#)]
  - 197 **Reprocessing Guideline Task Force**, Petersen BT, Cohen J, Hambrick RD 3rd, Buttar N, Greenwald DA, Buscaglia JM, Collins J, Eisen G. Multisociety guideline on reprocessing flexible GI endoscopes: 2016 update. *Gastrointest Endosc* 2017; **85**: 282-294.e1 [PMID: [28069113](#) DOI: [10.1016/j.gie.2016.10.002](#)]
  - 198 **U.S. Food and Drug Administration (FDA)**. Supplemental Measures to Enhance Duodenoscope Reprocessing: FDA Safety Communication. New Hampshire Avenue: FDA; 2015. [cited 1 January 2021]. Available from: <https://www.fda.gov/>
  - 199 **U.S. Food and Drug Administration (FDA)**. Reprocessing medical devices in health care settings: validation methods and labeling guidance for industry and Food and Drug Administration staff. New Hampshire Avenue: FDA; 2015. [cited 10 January 2021]. Available from: <https://www.fda.gov/>
  - 200 **Rutala WA**, Weber DJ. Guideline for disinfection and sterilization in healthcare facilities. Atlanta, GA: CDC; 2019. [cited 5 January 2021]. Available from: [https://www.baidu.com/link?url=iza\\_ELF480aY0logG5yoAQfQWGHtZhsDXCauPcrUM32TMiqpwSXklwjDdsPbGOAhZAUZPb\\_v3cSiaCU\\_384Edhw4voHdo0-S9CXSocClzhxAFKj1dCvEouuSjo8kyVA&wd=&eqid=9a54e1460017380c0000000260b771a4](https://www.baidu.com/link?url=iza_ELF480aY0logG5yoAQfQWGHtZhsDXCauPcrUM32TMiqpwSXklwjDdsPbGOAhZAUZPb_v3cSiaCU_384Edhw4voHdo0-S9CXSocClzhxAFKj1dCvEouuSjo8kyVA&wd=&eqid=9a54e1460017380c0000000260b771a4)
  - 201 **Food and Drug Administration (FDA)**. Brief Summary of the Gastroenterology and Urology Panel of the Medical Devices Advisory Committee Meeting – February 26, 2016. Rockville, MD: FDA; 2016. [cited 1 January 2021]. Available from: <https://www.fda.gov/>
  - 202 **Muthusamy VR**, Bruno MJ, Kozarek RA, Petersen BT, Pleskow DK, Sejal DV, Slivka A, Peetermans JA, Rousseau MJ, Tirrell GP, Ross AS. Clinical Evaluation of a Single-Use Duodenoscope for Endoscopic Retrograde Cholangiopancreatography. *Clin Gastroenterol Hepatol* 2020; **18**: 2108-2117.e3 [PMID: [31706060](#) DOI: [10.1016/j.cgh.2019.10.052](#)]
  - 203 **Gralnek IM**, Hassan C, Beilenhoff U, Antonelli G, Ebigo A, Pellisé M, Arvanitakis M, Bhandari P, Bisschops R, Van Hooft JE, Kaminski MF, Triantafyllou K, Webster G, Pohl H, Dunkley I, Fehrke B, Gazic M, Gjergjek T, Maasen S, Waagenes W, de Pater M, Ponchon T, Siersema PD, Messmann H, Dinis-Ribeiro M. ESGE and ESGENA Position Statement on gastrointestinal endoscopy and the COVID-19 pandemic. *Endoscopy* 2020; **52**: 483-490 [PMID: [32303090](#) DOI: [10.1055/a-1155-6229](#)]
  - 204 **Franzini TAP**, Kotinda APST, Moura DTH, Badana MLV, Medeiros MS, Lima PGR, Mello BF, Kayano RP, Carmona MJC, Rocha MC, Campos AF, McCarty TR, Guimarães T, Moura MLDN, Thompson CC, Moura EGH. Approach to Endoscopic Procedures: A Routine Protocol from a Quaternary University Referral Center Exclusively for Coronavirus Disease 2019 Patients. *Clinics (Sao Paulo)* 2020; **75**: e1989 [PMID: [32555947](#) DOI: [10.6061/clinics/2020/e1989](#)]
  - 205 **Smith ZL**, Das KK, Kushnir VM. Anesthesia-administered sedation for endoscopic retrograde cholangiopancreatography: monitored anesthesia care or general endotracheal anesthesia? *Curr Opin Anaesthesiol* 2019; **32**: 531-537 [PMID: [30994476](#) DOI: [10.1097/ACO.0000000000000741](#)]
  - 206 **Chen X**, Liu Y, Gong Y, Guo X, Zuo M, Li J, Shi W, Li H, Xu X, Mi W, Huang Y; Chinese Society of Anesthesiology; Chinese Association of Anesthesiologists. Perioperative Management of Patients Infected with the Novel Coronavirus: Recommendation from the Joint Task Force of the Chinese Society of Anesthesiology and the Chinese Association of Anesthesiologists. *Anesthesiology* 2020; **132**: 1307-1316 [PMID: [32195699](#) DOI: [10.1097/ALN.00000000000003301](#)]
  - 207 **Kujawski S**, Wong K, Collins J, Epstein L, Killerby M, Midgley C, Abedi G, Ahmed N, Almendares O, Alvarez F, Anderson K, Balter S, Barry V, Bartlett K, Beer K, Ben-Aderet M, Benowitz I, Biggs H, Binder A. First 12 patients with coronavirus disease 2019 (COVID-19) in the United States. *BMJ* 2020 [DOI: [10.1101/2020.03.09.20032896](#)]

- 208 **Young BE**, Ong SWX, Kalimuddin S, Low JG, Tan SY, Loh J, Ng OT, Marimuthu K, Ang LW, Mak TM, Lau SK, Anderson DE, Chan KS, Tan TY, Ng TY, Cui L, Said Z, Kurupatham L, Chen MI, Chan M, Vasoo S, Wang LF, Tan BH, Lin RTP, Lee VJM, Leo YS, Lye DC; Singapore 2019 Novel Coronavirus Outbreak Research Team. Epidemiologic Features and Clinical Course of Patients Infected With SARS-CoV-2 in Singapore. *JAMA* 2020; **323**: 1488-1494 [PMID: [32125362](#) DOI: [10.1001/jama.2020.3204](#)]
- 209 **Tabata S**, Imai K, Kawano S, Ikeda M, Kodama T, Miyoshi K, Obinata H, Mimura S, Kodera T, Kitagaki M, Sato M, Suzuki S, Ito T, Uwabe Y, Tamura K. Clinical characteristics of COVID-19 in 104 people with SARS-CoV-2 infection on the Diamond Princess cruise ship: a retrospective analysis. *Lancet Infect Dis* 2020; **20**: 1043-1050 [PMID: [32539988](#) DOI: [10.1016/S1473-3099\(20\)30482-5](#)]
- 210 **Wölfel R**, Corman VM, Guggemos W, Seilmaier M, Zange S, Müller MA, Niemeyer D, Jones TC, Vollmar P, Rothe C, Hoelscher M, Bleicker T, Brünink S, Schneider J, Ehmann R, Zwirgmaier K, Drosten C, Wendtner C. Virological assessment of hospitalized patients with COVID-2019. *Nature* 2020; **581**: 465-469 [PMID: [32235945](#) DOI: [10.1038/s41586-020-2196-x](#)]
- 211 **Gritti G**, Raimondi F, Ripamonti D, Riva I, Landi F, Alborghetti L, Frigeni M, Damiani M, Micò C, Fagioli S. IL-6 signalling pathway inactivation with siltuximab in patients with COVID-19 respiratory failure: an observational cohort study. *BMJ* 2020 [DOI: [10.1101/2020.04.01.20048561](#)]
- 212 **COVID-19 National Incident Room Surveillance Team**. COVID-19, Australia: Epidemiology Report 7 (Reporting week ending 19:00 AEDT 14 March 2020). *Commun Dis Intell (2018)* 2020; **44** [PMID: [32192424](#) DOI: [10.33321/cdi.2020.44.23](#)]
- 213 **COVID-19 National Emergency Response Center**, Epidemiology and Case Management Team, Korea Centers for Disease Control and Prevention. Early Epidemiological and Clinical Characteristics of 28 Cases of Coronavirus Disease in South Korea. *Osong Public Health Res Perspect* 2020; **11**: 8-14 [PMID: [32149037](#) DOI: [10.24171/j.phrp.2020.11.1.03](#)]
- 214 **Sierpiński R**, Pinkas J, Jankowski M, Zgliczyński WS, Wierzbna W, Gujski M, Szumowski Ł. Sex differences in the frequency of gastrointestinal symptoms and olfactory or taste disorders in 1942 nonhospitalized patients with coronavirus disease 2019 (COVID-19). *Pol Arch Intern Med* 2020; **130**: 501-505 [PMID: [32491298](#) DOI: [10.20452/pamw.15414](#)]
- 215 **Qi D**, Yan X, Tang X, Peng J, Yu Q, Feng L, Yuan G, Zhang A, Chen Y, Yuan J. Epidemiological and clinical features of 2019-nCoV acute respiratory disease cases in Chongqing municipality, China: a retrospective, descriptive, multiple-center study. *BMJ* 2020 [DOI: [10.1101/2020.03.01.20029397](#)]
- 216 **Wen Y**, Wei L, Li Y, Tang X, Feng S, Leung K, Wu X, Pan X-F, Chen C, Xia J. Epidemiological and clinical characteristics of COVID-19 in Shenzhen, the largest migrant city of China. *BMJ* 2020 [DOI: [10.1101/2020.03.22.20035246](#)]
- 217 **Dan F**, Jingdong MA, Jialun G, Muru W, Yang S, Dean T, Peiyuan LI. Manifestations of digestive system in hospitalized patients with novel coronavirus pneumonia in Wuhan, China: a single-center, descriptive study. *Zhonghua Xiaohua Zazhi* 2020; **12**: E005 [DOI: [10.3760/cma.j.issn.0254-1432.2020.0005](#)]
- 218 **Ma L**, Xie W, Li D, Shi L, Mao Y, Xiong Y, Zhang Y, Zhang M. Effect of SARS-CoV-2 infection upon male gonadal function: A single center-based study. *BMJ* 2020 [DOI: [10.1101/2020.03.21.20037267](#)]
- 219 **Liu L**, Liu W, Zheng Y, Jiang X, Kou G, Ding J, Wang Q, Huang Q, Ding Y, Ni W, Wu W, Tang S, Tan L, Hu Z, Xu W, Zhang Y, Zhang B, Tang Z, Zhang X, Li H, Rao Z, Jiang H, Ren X, Wang S, Zheng S. A preliminary study on serological assay for severe acute respiratory syndrome coronavirus 2 (SARS-CoV-2) in 238 admitted hospital patients. *Microbes Infect* 2020; **22**: 206-211 [PMID: [32425648](#) DOI: [10.1016/j.micinf.2020.05.008](#)]
- 220 **Ai J**, Chen J, Wang Y, Liu X, Fan W, Gaojing Q, Zhang M, Pei S, Tang B, Yuan S, Li Y, Wang L, Huang G, Pei B. The cross-sectional study of hospitalized coronavirus disease 2019 patients in Xiangyang, Hubei province. 2020 Preprint. Available from: medRxiv:2020 [DOI: [10.1101/2020.02.19.20025023](#)]
- 221 **Zhao Z**, Xie J, Yin M, Yang Y, He H, Jin T, Li W, Zhu X, Xu J, Zhao C, Li L, Li Y, Mengist HM, Zahid A, Yao Z, Ding C, Qi Y, Gao Y, Ma X. Clinical and Laboratory Profiles of 75 Hospitalized Patients with Novel Coronavirus Disease 2019 in Hefei, China. 2020 Preprint. Available from: medRxiv:2020 [DOI: [10.1101/2020.03.01.20029785](#)]
- 222 **Li K**, Wu J, Wu F, Guo D, Chen L, Fang Z, Li C. The Clinical and Chest CT Features Associated With Severe and Critical COVID-19 Pneumonia. *Invest Radiol* 2020; **55**: 327-331 [PMID: [32118615](#) DOI: [10.1097/RLI.0000000000000672](#)]
- 223 **Lin L**, Jiang X, Zhang Z, Huang S, Fang Z, Gu Z, Gao L, Shi H, Mai L, Liu Y, Lin X, Lai R, Yan Z, Li X, Shan H. Gastrointestinal symptoms of 95 cases with SARS-CoV-2 infection. *Gut* 2020; **69**: 997-1001 [PMID: [32241899](#) DOI: [10.1136/gutjnl-2020-321013](#)]
- 224 **Cholankeril G**, Podboy A, Aivaliotis VI, Pham EA, Spencer SP, Kim D, Ahmed A. Association of Digestive Symptoms and Hospitalization in Patients With SARS-CoV-2 Infection. *Am J Gastroenterol* 2020; **115**: 1129-1132 [PMID: [32618665](#) DOI: [10.14309/ajg.0000000000000712](#)]
- 225 **Redd WD**, Zhou JC, Hathorn KE, McCarty TR, Bazarbashi AN, Thompson CC, Shen L, Chan WW. Prevalence and Characteristics of Gastrointestinal Symptoms in Patients With Severe Acute Respiratory Syndrome Coronavirus 2 Infection in the United States: A Multicenter Cohort Study. *Gastroenterology* 2020; **159**: 765-767.e2 [PMID: [32333911](#) DOI: [10.1053/j.gastro.2020.04.045](#)]

- 226 **Kluytmans-van den Bergh MFQ**, Buiting AGM, Pas SD, Bentvelsen RG, van den Bijllaardt W, van Oudheusden A, van Rijen MML, Verweij JJ, Koopmans MPG, Kluytmans JAJW. SARS-CoV-2 infection in 86 healthcare workers in two Dutch hospitals in March 2020: a cross-sectional study with short-term follow-up. 2020 Preprint. Available from: medRxiv:2020 [DOI: [10.1101/2020.03.23.20041913](https://doi.org/10.1101/2020.03.23.20041913)]
- 227 **Shu L**, Wang X, Li M, Chen X, Ji N, Shi L, Wu M, Deng K, Wei J, Cao Y, Yan J, Feng G. Clinical characteristics of moderate COVID-19 patients aggravation in Wuhan Stadium Cabin Hospital: A 571 cases of retrospective cohort study. *J Med Virol* 2021; **93**: 1133-1140 [PMID: [32779760](https://pubmed.ncbi.nlm.nih.gov/32779760/) DOI: [10.1002/jmv.26414](https://doi.org/10.1002/jmv.26414)]
- 228 **Huang Y**, Yang R, Xu Y, Gong P. Clinical characteristics of 36 non-survivors with COVID-19 in Wuhan, China. 2020 Preprint. Available from: medRxiv:2020 [DOI: [10.1101/2020.02.27.20029009](https://doi.org/10.1101/2020.02.27.20029009)]
- 229 **Yao N**, Wang SN, Lian JQ, Sun YT, Zhang GF, Kang WZ, Kang W. [Clinical characteristics and influencing factors of patients with novel coronavirus pneumonia combined with liver injury in Shaanxi region]. *Zhonghua Gan Zang Bing Za Zhi* 2020; **28**: 234-239 [PMID: [32153170](https://pubmed.ncbi.nlm.nih.gov/32153170/) DOI: [10.3760/cma.j.cn501113-20200226-00070](https://doi.org/10.3760/cma.j.cn501113-20200226-00070)]
- 230 **Xu S**, Fu L, Fei J, Xiang H-X, Xiang Y, Tan Z-X, Li M-D, Liu F-F, Li Y, Han M-F, Li X-Y, Yu D-X, Zhao H, Xu D-X. Acute kidney injury at early stage as a negative prognostic indicator of patients with COVID-19: a hospital-based retrospective analysis. 2020 Preprint. Available from: medRxiv:2020 [DOI: [10.1101/2020.03.24.20042408](https://doi.org/10.1101/2020.03.24.20042408)]
- 231 **Cai Q**, Huang D, Ou P, Yu H, Zhu Z, Xia Z, Su Y, Ma Z, Zhang Y, Li Z, He Q, Liu L, Fu Y, Chen J. COVID-19 in a designated infectious diseases hospital outside Hubei Province, China. *Allergy* 2020; **75**: 1742-1752 [PMID: [32239761](https://pubmed.ncbi.nlm.nih.gov/32239761/) DOI: [10.1111/all.14309](https://doi.org/10.1111/all.14309)]



Published by **Baishideng Publishing Group Inc**  
7041 Koll Center Parkway, Suite 160, Pleasanton, CA 94566, USA

**Telephone:** +1-925-3991568

**E-mail:** [bpgoffice@wjgnet.com](mailto:bpgoffice@wjgnet.com)

**Help Desk:** <https://www.f6publishing.com/helpdesk>

<https://www.wjgnet.com>

