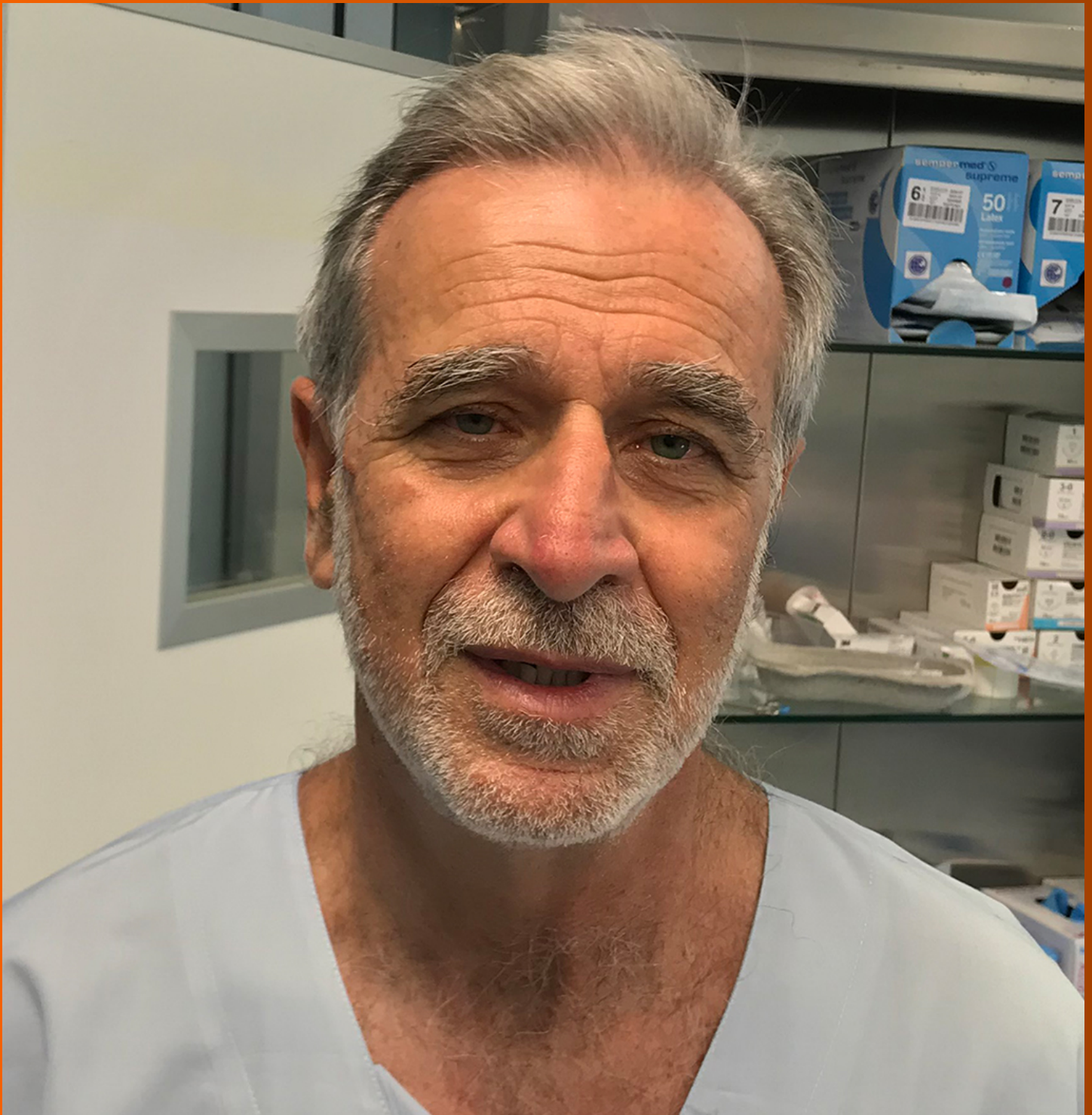


# World Journal of *Gastroenterology*

*World J Gastroenterol* 2021 August 7; 27(29): 4746-4938



### REVIEW

- 4746** Ischemic bowel disease in 2021  
*Ahmed M*
- 4763** Therapeutic implications of SARS-CoV-2 dysregulation of the gut-brain-lung axis  
*Johnson SD, Olwenyi OA, Bhyravhatla N, Thurman M, Pandey K, Klug EA, Johnston M, Dyavar SR, Acharya A, Podany AT, Fletcher CV, Mohan M, Singh K, Byrareddy SN*
- 4784** Hepatitis B virus infection modeling using multi-cellular organoids derived from human induced pluripotent stem cells  
*Cao D, Ge JY, Wang Y, Oda T, Zheng YW*

### MINIREVIEWS

- 4802** Artificial intelligence in colonoscopy  
*Joseph J, LePage EM, Cheney CP, Pawa R*
- 4818** New hope for hepatitis C virus: Summary of global epidemiologic changes and novel innovations over 20 years  
*Dennis BB, Naji L, Jajarmi Y, Ahmed A, Kim D*
- 4831** Impact of modern antiviral therapy of chronic hepatitis B and C on clinical outcomes of liver disease  
*Khoo T, Lam D, Olynyk JK*
- 4846** Neurological and psychiatric effects of hepatitis C virus infection  
*Faccioli J, Nardelli S, Gioia S, Riggio O, Ridola L*
- 4862** Muscular abnormalities in liver cirrhosis  
*Hari A*

### ORIGINAL ARTICLE

#### Basic Study

- 4879** Impact of *Fusobacterium nucleatum* in the gastrointestinal tract on natural killer cells  
*Kim YJ, Kim BK, Park SJ, Kim JH*

#### Retrospective Study

- 4890** Poor performance of anti-mitochondrial antibodies for the diagnosis of primary biliary cholangitis in female Colombian patients: A single-center study  
*Guatibonza-García V, Gaete PV, Pérez-Londoño A, Puerto-Baracaldo DK, Gutiérrez-Romero SA, Mendivil CO, Tapias M*

**Clinical Trials Study**

- 4900** Effects of permissive hypocaloric *vs* standard enteral feeding on gastrointestinal function and outcomes in sepsis

*Sun JK, Nie S, Chen YM, Zhou J, Wang X, Zhou SM, Mu XW*

**Observational Study**

- 4913** Advanced glycation end product: A potential biomarker for risk stratification of non-alcoholic fatty liver disease in ELSA-Brasil study

*Pereira ENGDS, Paula DP, Araujo BP, Fonseca MJMD, Diniz MFHS, Daliry A, Griep RH*

**CASE REPORT**

- 4929** Autoimmune enteropathy and primary biliary cholangitis after proctocolectomy for ulcerative colitis: A case report and review of the literature

*Zhou QY, Zhou WX, Sun XY, Wu B, Zheng WY, Li Y, Qian JM*

**ABOUT COVER**

Editorial Board Member of *World Journal of Gastroenterology*, Aldo Bove, MD, PhD, Assistant Professor of Surgery, Chief of Surgery "Pierangeli Hospital" Pescara, Department of Medicine, Dentistry and Biotechnology, University "G. D'Annunzio", Via dei Vestini, Chieti 66100, Italy. above@unich.it

**AIMS AND SCOPE**

The primary aim of *World Journal of Gastroenterology* (WJG, *World J Gastroenterol*) is to provide scholars and readers from various fields of gastroenterology and hepatology with a platform to publish high-quality basic and clinical research articles and communicate their research findings online. WJG mainly publishes articles reporting research results and findings obtained in the field of gastroenterology and hepatology and covering a wide range of topics including gastroenterology, hepatology, gastrointestinal endoscopy, gastrointestinal surgery, gastrointestinal oncology, and pediatric gastroenterology.

**INDEXING/ABSTRACTING**

The WJG is now indexed in Current Contents®/Clinical Medicine, Science Citation Index Expanded (also known as SciSearch®), Journal Citation Reports®, Index Medicus, MEDLINE, PubMed, PubMed Central, and Scopus. The 2021 edition of Journal Citation Report® cites the 2020 impact factor (IF) for WJG as 5.742; Journal Citation Indicator: 0.79; IF without journal self cites: 5.590; 5-year IF: 5.044; Ranking: 28 among 92 journals in gastroenterology and hepatology; and Quartile category: Q2. The WJG's CiteScore for 2020 is 6.9 and Scopus CiteScore rank 2020: Gastroenterology is 19/136.

**RESPONSIBLE EDITORS FOR THIS ISSUE**

Production Editor: *Ying-Yi Yuan*, Production Department Director: *Xiang Li*, Editorial Office Director: *Ze-Mao Gong*.

**NAME OF JOURNAL**

*World Journal of Gastroenterology*

**ISSN**

ISSN 1007-9327 (print) ISSN 2219-2840 (online)

**LAUNCH DATE**

October 1, 1995

**FREQUENCY**

Weekly

**EDITORS-IN-CHIEF**

Andrzej S Tarnawski, Subrata Ghosh

**EDITORIAL BOARD MEMBERS**

<http://www.wjgnet.com/1007-9327/editorialboard.htm>

**PUBLICATION DATE**

August 7, 2021

**COPYRIGHT**

© 2021 Baishideng Publishing Group Inc

**INSTRUCTIONS TO AUTHORS**

<https://www.wjgnet.com/bpg/gerinfo/204>

**GUIDELINES FOR ETHICS DOCUMENTS**

<https://www.wjgnet.com/bpg/GerInfo/287>

**GUIDELINES FOR NON-NATIVE SPEAKERS OF ENGLISH**

<https://www.wjgnet.com/bpg/gerinfo/240>

**PUBLICATION ETHICS**

<https://www.wjgnet.com/bpg/GerInfo/288>

**PUBLICATION MISCONDUCT**

<https://www.wjgnet.com/bpg/gerinfo/208>

**ARTICLE PROCESSING CHARGE**

<https://www.wjgnet.com/bpg/gerinfo/242>

**STEPS FOR SUBMITTING MANUSCRIPTS**

<https://www.wjgnet.com/bpg/GerInfo/239>

**ONLINE SUBMISSION**

<https://www.f6publishing.com>



## Neurological and psychiatric effects of hepatitis C virus infection

Jessica Faccioli, Silvia Nardelli, Stefania Gioia, Oliviero Riggio, Lorenzo Ridola

**ORCID number:** Jessica Faccioli 0000-0001-6960-9701; Silvia Nardelli 0000-0002-7038-9539; Stefania Gioia 0000-0002-3940-4390; Oliviero Riggio 0000-0000-2241-3223; Lorenzo Ridola 0000-0002-8596-2609.

**Author contributions:** Faccioli J and Ridola L drafted the manuscript; Nardelli S, Gioia S, Riggio O and Ridola L critically reviewed the manuscript for important intellectual content; Riggio O and Ridola L approved the manuscript.

**Conflict-of-interest statement:** None declared.

**Open-Access:** This article is an open-access article that was selected by an in-house editor and fully peer-reviewed by external reviewers. It is distributed in accordance with the Creative Commons Attribution NonCommercial (CC BY-NC 4.0) license, which permits others to distribute, remix, adapt, build upon this work non-commercially, and license their derivative works on different terms, provided the original work is properly cited and the use is non-commercial. See: <http://creativecommons.org/licenses/by-nc/4.0/>

**Manuscript source:** Invited manuscript

**Specialty type:** Gastroenterology and hepatology

**Jessica Faccioli, Silvia Nardelli, Stefania Gioia, Oliviero Riggio, Lorenzo Ridola**, Department of Translational and Precision Medicine, “Sapienza” University of Rome, Rome 00185, Italy

**Corresponding author:** Lorenzo Ridola, MD, PhD, Associate Professor, Department of Translational and Precision Medicine, “Sapienza” University of Rome, viale dell’Università, 37, Rome 00185, Italy. [lorenzo.ridola@uniroma1.it](mailto:lorenzo.ridola@uniroma1.it)

### Abstract

Hepatitis C virus (HCV) infection is widespread and affects 71 million people worldwide. Although hepatic manifestations are the most frequent, ranging from chronic hepatitis to cirrhosis and hepatocellular carcinoma, it is also associated with several extrahepatic manifestations. Infected patients may present non-specific neurological symptoms, regardless of the presence of liver cirrhosis. Several pathogenetic mechanisms underlying neurological symptoms have been hypothesized: neuroinvasion, immune-mediated damage, neurotransmitter alterations and cryoglobulinemia. Alterations of the central nervous system include cerebral vasculopathy, acute or subacute encephalopathy and inflammatory disorders. HCV infection may be responsible for neuropathies, of which the most frequent form is symmetrical axonal sensory or sensory-motor polyneuropathy which causes loss of leg sensitivity and weakness. Up to 50% of patients with HCV infection may experience cognitive decline and psychological disorders, such as depression and fatigue. HCV associated neurocognitive disorder is independent of the presence of liver cirrhosis and affects different domains than in patients with hepatic encephalopathy. It can be studied using specific tests that mainly explore executive functions, verbal learning and verbal recall. These disorders significantly reduce the quality of life. The new antiviral therapies improve the extrahepatic symptoms of HCV infection and their success depends on the achievement of sustained virological response. However, the effect of therapy may differ depending on the type of organ involved; neurological symptoms can be irreversible if there is organic liver damage. The aim of this review is to provide a critical overview of physiopathological mechanisms, diagnostic and therapeutic strategies of the neurological and psychiatric effects of HCV infection.

**Key Words:** Hepatitis C virus; Neurological disorders; Psychiatric disorders; Antiviral therapy; Quality of life; Hepatic encephalopathy

©The Author(s) 2021. Published by Baishideng Publishing Group Inc. All rights reserved.



**Country/Territory of origin:** Italy**Peer-review report's scientific quality classification**

Grade A (Excellent): 0

Grade B (Very good): B

Grade C (Good): 0

Grade D (Fair): 0

Grade E (Poor): 0

**Received:** February 2, 2021**Peer-review started:** February 2, 2021**First decision:** May 1, 2021**Revised:** May 7, 2021**Accepted:** June 4, 2021**Article in press:** June 4, 2021**Published online:** August 7, 2021**P-Reviewer:** Fhkam ML**S-Editor:** Zhang H**L-Editor:** Webster JR**P-Editor:** Yuan YY

**Core Tip:** The aim of this review is to provide a critical overview of neurological and psychiatric disorders in patients with hepatitis C virus infection, the underlying pathogenetic mechanisms and the effect of new direct-acting antivirals on extrahepatic symptoms. The main clinical and pathogenetic differences to hepatic encephalopathy and the different diagnostic strategies used in these two conditions are reported.

**Citation:** Faccioli J, Nardelli S, Gioia S, Riggio O, Ridola L. Neurological and psychiatric effects of hepatitis C virus infection. *World J Gastroenterol* 2021; 27(29): 4846-4861

**URL:** <https://www.wjgnet.com/1007-9327/full/v27/i29/4846.htm>

**DOI:** <https://dx.doi.org/10.3748/wjg.v27.i29.4846>

## INTRODUCTION

Hepatitis C is caused by hepatitis C virus (HCV), an RNA virus belonging to the family Hepadnaviridae. It has been estimated that there are 71 million patients with HCV infection worldwide[1] and it is an important cause of liver-related morbidity and mortality[2].

Despite the prevalent hepatic involvement, HCV infection is now considered a systemic infection due to increasing evidence of the ability of the virus to enter and replicate in major cellular systems[3].

HCV infection has been associated with more than 30 extrahepatic manifestations [4], some of which are a consequence of the proliferation of B lymphocytes with consequent monoclonal and polyclonal production of antibodies showing the activity of the rheumatoid factor or cryoglobulins[5].

Extrahepatic symptoms can prevail over hepatic symptoms or aggravate them[3] and can involve cardiovascular, joint, dermatological, renal and neurological systems.

Hepatic encephalopathy is the most typical manifestation of central nervous system involvement in patients with liver cirrhosis. The hypothesis that chronic HCV infection can itself cause brain dysfunction derives from evidence from patients without cirrhosis or cryoglobulinemia who frequently have a wide range of non-specific neurological symptoms[2].

Up to 50% of non-cirrhotic patients with HCV develop neurological and psychiatric symptoms whose manifestations do not correlate with the severity of liver disease or with viral replication rate[3].

Thus, in the diagnostic work-up of a patient with neurological and psychiatric symptoms, physicians should also consider HCV infection as a possible etiological factor[3].

Finally, it should be considered that the presence of HCV in an extrahepatic and immune-privileged site could be a potential source of late relapse after antiviral therapy[2].

## PATHOGENESIS

The ways in which HCV causes the occurrence of neurological and psychiatric symptoms are different and several mechanisms have been hypothesized: Neuroinvasion and direct damage: Several studies have shown that the nervous system is a permissive site for viral replication, as confirmed by the presence of intermediate replicative forms of HCV-RNA and viral proteins at this level[3].

Furthermore, the presence of HCV in the cerebrospinal fluid of patients with cognitive decline has been demonstrated through gene sequencing techniques[2], but HCV-RNA levels are 1000-10000 times lower than those found in the liver[6].

However, the viral sequences of E1 and 5' untranslated regions found in the central nervous system are different to the hepatic sequences, suggesting an independent life of the virus in the central nervous system[3,6].

In line with this hypothesis, cerebral viral quasispecies share genomic sequences with those found in lymphoid tissues and peripheral blood mononuclear cells, but not with hepatic cells[3].

These data suggest the hypothesis that peripheral blood mononuclear cells can mediate the entry of virus into the central nervous system through a mechanism called “trojan horse”[7].

Therefore, the virus first infects peripheral monocytes and then crosses the blood-brain barrier after infection of brain microvascular endothelial cells[6]. In this way, virus, immune cells, cytokines and chemokines can enter the central nervous system causing immune brain activation[8,9].

It should be noted that microvascular endothelium cells are the only cells in the central nervous system that express HCV receptors; so, they play a critical role in allowing virus entry in this site[10].

CD-81, SR-BI and claudin 1 are expressed on epithelial and endothelial cells of different tissues and it has been shown that antibodies against these antigens inhibit virus entry into cell lines derived from cerebral endothelium *in vitro*. Therefore, they can represent the target for HCV entry in brain endothelial cells[10,11].

Other studies have shown that Apolipoprotein E (ApoE) also plays an important role in this process. In fact, anti-ApoE antibodies can neutralize infection in cell lines derived from cerebral endothelium[6].

Therefore, although normally microglia do not express the molecules necessary for HCV entry, the virus evades this obstacle by directly infecting peripheral precursors and altering the selective filter of the blood-brain barrier. This mechanism is similar to that described for HIV[12,13].

Confirming this hypothesis, immunohistochemical and molecular techniques have shown that astrocytes and microglia are target cells for HCV infection[12,14].

Cells with positivity for HCV NS3, also express CD-68 which is a marker of glial cells. When RNA of these cells is amplified, the result is expression of both microglia markers and pro-inflammatory genes such as IL-12, IL-8 and TNF alpha[14]. Moreover, the activation of infected microglia cells results in an increased production of excitatory amino acids that can induce neuronal death through excitotoxicity[15].

Metabolic and neurotransmission alteration: Magnetic resonance spectroscopy allows measurement of the concentration of certain metabolites in specific brain regions. Choline is a metabolite expressed by glial and proliferating cells and is used as a marker of inflammation and of the synthesis and turnover of cell membranes; N-acetyl aspartate is a neuronal metabolite and a marker of neuronal integrity, so its decrease is indicative of neuronal loss or dysfunction; myoinositol is produced only by glial cells and increases with glial proliferation, called gliosis, or with interruption of myelin[2,16].

Several studies have shown an increased level of choline and myoinositol, both in cerebral white matter and basal ganglia, and a reduction of N-acetyl aspartate level in basal ganglia. These findings are suggestive of glial activation and macrophage infiltration and support the hypothesis of neuroinflammation.

Neurotransmission studies using single photon emission computed tomography (SPECT) demonstrated an alteration of serotonergic and dopaminergic neurotransmitter systems in the midbrain and basal ganglia of up to 60% in HCV patients[17,18]. This can be related to high peripheral cytokine levels, particularly IL-1 and IL-6, which can negatively interfere with neurotransmitter systems and impair memory and executive functions[2,19].

Finally, perfusion studies have shown increased perfusion in the basal ganglia compared to cerebral cortex; this report suggests a vascular response secondary to immune activation due to neuronal invasion, confirming the hypothesis of neuroinflammation[20].

This picture is typical of other inflammatory conditions such as multiple sclerosis [21].

Overall, these studies have shown abnormalities in dopamine and serotonin signaling, neuronal hypometabolism and neuro-inflammation in some patients with chronic HCV infection.

Cryoglobulinemia: cryoglobulins are immunoglobulins able to bind to each other at temperatures below 37°C, causing organ damage through two main mechanisms. The first mechanism, associated with type I cryoglobulinemia, consists of “vascular sludging” which is a hyperviscosity syndrome; the second mechanism, typical of type II and III cryoglobulinemia, is a mechanism of immune-mediated vasculitis[22].

One of the consequences of HCV infection is mixed cryoglobulinemia (type II and III) which is characterized by the precipitation of immune complexes. Type II and III cryoglobulinemia are due to an increase in cryoglobulin production by B lymphocytes clones.

HCV lymph-tropism is the first step in inducing cryoglobulinemia; in fact, the E2 protein of the viral envelope interacts with the surface protein CD-81 of B lympho-

cytes, inducing proliferation and production of IgM monoclonal antibodies[23,24].

The characteristic pathological sign of cryoglobulinemia is leukocytoclastic vasculitis which affects medium and small blood vessels with transmural fibrinoid necrosis, thrombotic lumen occlusion and infiltration of polymorphonuclear cells. The consequence of vasculitis is ischemic tissue damage[4]. This condition is now referred to as HCV-associated cryoglobulinemic vasculitis (HCV-associated CV).

## CENTRAL NERVOUS SYSTEM DISORDERS

### **Cerebrovascular disease**

Acute and chronic cerebral vasculopathy is more frequent in patients with HCV than in the general population and HCV-RNA level correlates positively with the risk of cerebrovascular death[25].

Acute events such as stroke, transient ischemic attack, lacunar syndrome and, rarely, bleeding, have been reported in patients with HCV infection, in some cases representing the initial clinical manifestation of infection itself[26].

Several retrospective and prospective studies have shown an association between HCV infection and risk of stroke, which can occur at a lower age and without the classic cardiovascular risk factors[25].

Several responsible mechanisms have been hypothesized.

Chronic systemic inflammatory state can be responsible for arterial remodeling that precedes the development of carotid plaque[27], while the locally active presence of virus can cause plaque instability with erosion, rupture and thromboembolic event [28].

Furthermore, chronic HCV infection predisposes to metabolic imbalances; in particular, the virus can alter glucose homeostasis and lipid metabolism in a pro-atherogenic sense[29]. The association between infection and development of type II diabetes mellitus is well documented in the literature[6].

Mixed cryoglobulinemia in the brain can affect vasa nervorum and cerebral arterioles causing occlusive cerebral vasculopathy[2] and they constitute an independent risk factor for carotid plaque formation[4].

Finally, in some patients the ischemic event may be secondary to ANCA or anti-phospholipid antibodies which can cause a non-cryoglobulinemic vasculitis[4,30].

### **Acute or subacute encephalopathy**

Chronic HCV infection can be responsible for acute and subacute involvement of white matter when associated with cryoglobulinemia or systemic vasculitis[4].

This encephalopathy is clinically characterized by cognitive decline, confusion, altered state of consciousness, dysarthria, dysphagia and incontinence as a result of widespread involvement of cerebral white matter in patients with cryoglobulins or circulating anticardiolipin antibodies[4].

This condition could be due to ischemic damage and this hypothesis is confirmed by the presence of small subcortical and peri-ventricular white matter lesions found on magnetic resonance imaging[4]. In addition, diffuse and severe changes in supratentorial and infratentorial white matter highly suggestive of cerebral vasculitis, have been observed in patients with systemic vasculitis[31].

### **Inflammatory disorders**

HCV infection has been associated with the onset of central nervous system inflammatory diseases which can occur in different clinical scenarios.

In the literature, cases of rapidly developing leucoencephalitis clinically characterized by cognitive decline, tetraparesis and aphasia, and histologically by perivascular infiltrates of T lymphocytes and microglia nodules have been reported.

Fatally progressive encephalomyelitis presenting with epilepsy, motor, sensory and autonomic deficits and characterized by loss of neurons and perivascular infiltration of lymphocytes in the brainstem and cervical spinal cord may occur[32,33].

The hypothesized pathogenetic mechanism is that of immune-mediated damage rather than direct damage induced by virus[4]. Confirming this hypothesis is the response to steroid therapy in cases of acute disseminated encephalomyelitis, a post-infectious autoimmune disease characterized by immune-mediated damage of cerebral and cerebellar white matter and clinically characterized by alterations of consciousness, psychomotor agitation, focal neurological symptoms and urinary retention[3,34].



Chronic HCV infection can also induce myelitis due to antibody-mediated autoimmune demyelination. Transverse myelitis is a common manifestation of this group of disorders in which the immune-mediated mechanism of damage is confirmed by anti-HCV antibodies but not the presence of viral genome in cerebrospinal fluid. The prevalent symptoms are autonomic, sensory and motor dysfunction, sensory ataxia and spastic paraplegia[4].

## PERIPHERAL NERVOUS SYSTEM DISORDERS

During HCV infection, a high prevalence of peripheral neuropathy has been reported, which involves 40% to 75% of patients[6].

This finding is more evident in patients with mixed cryoglobulinemia, in whom fascicular ischemia and axonal degeneration are observed as a result of vasculitis of the vasa nervorum or necrotizing arteritis of medium-sized vessels[35]. In fact, up to 60% of patients with cryoglobulinemia present peripheral neuropathy, while a smaller percentage presents involvement of the central nervous system (6%) due to direct involvement of cerebral arterioles[4].

However, peripheral neuropathy has been demonstrated in subjects who do not have mixed cryoglobulinemia. In these cases, immune complexes or autoimmune mechanisms induced by virus and dependent on T lymphocytes, may play a role in inducing vascular and perivascular inflammation[2,36].

In any case, the pathogenesis is indirect and predominantly inflammatory as the virus does not invade peripheral nerves or muscle tissue[6].

Sensory or motor axon degeneration disrupts communication between the central and peripheral nervous systems. Motor damage can be responsible for weakness, while sensory damage can cause paresthesia, hyperalgesia, allodynia, pain and numbness. Autonomic damage can result in organ damage[6].

The most frequent form of peripheral neuropathy is symmetrical axonal sensory or sensorimotor polyneuropathy which is typically characterized by loss of sensation and weakness in the lower leg region[37].

Asymmetrical forms include small fiber sensory polyneuropathy which is the most common clinical manifestation and is characterized by tingling, burning feet and restless legs syndrome. In more advanced cases, neuropathy can affect larger caliber fibers (sensory polyneuropathy of the large fibers) which presents with loss of sensation, paresthesia, cramps and numbness[38,39].

Other clinical presentations are mononeuropathy and multiple mononeuropathy, which involves non-contiguous nerves. Cranial nerves are usually spared from this phenomenon, although there have been reports of abductor, facial and trigeminal nerve involvement[4].

Rare forms of neuropathy are pure motor polyneuropathy and autonomic neuropathy[40,41].

## NEUROPSYCHOLOGICAL DISORDERS

Up to 50% of patients with chronic HCV infection has neuropsychiatric symptoms, "brain fog", fatigue and impaired quality of life, regardless of the severity of liver disease[6,13]. These alterations can interfere with daily activities and with the ability to maintain independence[15].

While it is possible that psychiatric symptoms can contribute to cognitive decline in these patients, it appears unlikely that psychiatric symptoms alone can fully explain the cognitive deficits.

A more likely scenario is that both psychiatric symptoms and cognitive impairments are part of the neuropsychiatric syndrome found in patients with chronic HCV infection[15].

### Fatigue

Chronic fatigue is the most common symptom of chronic HCV infection, with a prevalence ranging from 20% to 80% in different cohorts[2].

It is perceived as a feeling of physical and mental exhaustion that is often accompanied by muscle and joint pain, sleep disturbances and restless legs syndrome[4]. This "central" fatigue differs from the "peripheral" fatigue linked to muscle weakness.

Fatigue is influenced by psychological, social and physical factors, so a direct virus effect on this symptom remains unclear[2]. In fact, it is the hallmark of depression and consequent apathy, demotivation, unrefreshing sleep, disinterest and loss of energy [42].

Moreover, a positive association between fatigue and hepatic fibrosis has been demonstrated by Teuber *et al*[43]. In fact, the degree of fatigue assessed with the Fatigue impact scale was higher in patients with severe fibrosis or cirrhosis than in patients with mild fibrosis, mostly in the physical domain.

However, central fatigue and depression may share possible biological changes in the brain.

It has been hypothesized that alterations in cerebral metabolism and neurotransmission in the limbic system, ascending reticular system, globus pallidus and putamen are associated with chronic fatigue[4].

Dopamine reduction in the limbic system and ascending reticular system could be secondary to cytokine-induced reduction of tetrahydrobiopterin, an enzyme involved in dopamine synthesis[44,45]. In fact, a study showed an association between fatigue and peripheral inflammation, suggesting that activity of the peripheral immune system may contribute to this symptom[46].

Impairment of serotonin transmission, implicated in depression, has also been correlated with fatigue. This finding is confirmed by the fact that treatment with ondansetron, a competitive antagonist of the serotonin receptor, is effective in improving fatigue. Therefore, this evidence supports the role of serotonin pattern dysfunction in causing fatigue and is in line with data showing a decrease in serum tryptophan levels and a reduction in serotonin synthesis in patients with chronic HCV infection[17,47].

### Depression

A high frequency of anxiety and depression has been reported in patients with HCV infection and these psychiatric pathologies negatively impact the quality of life[2].

The prevalence of HCV infection in patients with psychiatric disorders is significantly higher than in the general population and can affect 20% to 50% of infected patients compared to 10% of healthy subjects[2,6]. This association would be greater in genotype 3a[48,49].

An important aspect is that depression can affect patient prognosis as it is associated with poor adherence to antiviral therapy[50]. Therefore, multidisciplinary involvement is essential both to ensure adherence to treatment and for management of depressive symptoms[45].

Depression can be reactive to physical and psychosocial sequelae of HCV infection. Being aware of infection itself constitutes a risk factor for depression due to the impairment of family and intimate relationships, stigmatization and social marginalization[2,45]. Frequent coexistence of intravenous substance abuse[51] or symptoms such as fatigue and cognitive decline may also explain the onset of depression[52]. Depression can also be secondary to comorbidities associated with HCV infection such as diabetes mellitus and insulin resistance, metabolic syndrome, cardiovascular disease and inflammatory conditions such as cryoglobulinemia and arthritis which cause skin manifestations, motor and sensory neuropathies, joint pain and reduced joint mobility[45].

A higher burden of physical symptoms from HCV is associated with increased depression, and this burden increases with complications of cirrhosis such as ascites, sarcopenia and encephalopathy, causing limitations in physical and social function [44].

However, depression is not entirely attributable to these factors.

Endotoxins and peripheral cytokines, in particular IL-2, IL-6 and IL-10, act on the blood-brain barrier stimulating prostaglandin E2 release in the central nervous system. This in turn stimulates the release of additional cytokines by microglia cells, such as IL-1, IL-4, IL-6, IL-12, IL-18 and TNF- $\alpha$ . These mediators can inhibit neurotransmission in areas involved in affective responses and emotional processes[53], and induce the activity of enzymes that metabolize tryptophan into neurotoxic metabolites rather than serotonin[54]. In turn, serotonin deficiency can cause an excessive release of inhibitory neurotransmitters leading to depressive symptoms. In fact, serotonergic projections from midbrain nuclei modulate the activities of cortical and subcortical structures involved in behavior, mood and attention regulation[16].

The cytokines can excessively stimulate the hypothalamus-pituitary-adrenal system leading to excessive endogenous cortisol production which can alter hippocampus neurotransmission. In addition, corticotropin-releasing hormone can directly cause neurotoxicity[45].

Confirming the direct role of virus in causing depression, in a cross-sectional study of patients with liver disease of different etiology [hepatitis B virus (HBV), HCV, alcohol abuse and metabolic syndrome], only the presence of HCV was found to be independently associated with depression. This suggests an additional and causal mechanism due to virus presence that contributes to depression.

### Quality of life

The World Health Organization defines the quality of life as the individual's perception of their state of physical, mental and social well-being[2].

Several studies have highlighted the impact of chronic HCV infection on quality of life, even without significant liver disease and regardless of modality of virus acquisition, for example previous substance abuse[2].

Even in the absence of debilitating symptoms, HCV compromises quality of life by negatively impacting the physical and mental well-being of patients. Nonspecific symptoms such as asthenia, irritability, general malaise and musculoskeletal pain can occur in patients with chronic HCV infection and in many cases reduce the sense of physical well-being causing emotional problems[1]. Indeed, in quality of life studies in which the SF-36 questionnaire was used, depression and fatigue were found to be independent predictors of reduced quality of life[45].

Other factors involved in the deterioration of quality of life are the psychological impact of prognosis, comorbidities associated with infection and social stigmatization, the shame of being infected and the fear of infecting other people, unemployment and financial problems.

Furthermore, until a few years ago, patients were concerned about the limited eradication capacity of interferon-based regimens and about the disabling adverse effects associated with this therapy[1].

Quality of life is more compromised in patients with HCV than HBV infection and this may suggest a direct role of HCV virus on this aspect[55]. In fact, several prospective studies have shown that infected patients compared to non-infected, have lower scores related to quality of life even before knowing their serological status[56] and that antiviral therapy and viral suppression induce an important clinical improvement[1].

Therefore, HCV infection has a direct effect on quality of life that can be aggravated by psychological factors related to diagnosis and clinical complications of infection itself[2].

Several studies have identified which factors are independently associated with reduced quality of life as they can potentially aggravate the burden of infection.

A study by Jang *et al*[57] showed that the SF-36 physical and mental component summary scores of HCV patients, were below the normal limits. However, those with decompensated cirrhosis had the lowest health-related quality of life (HRQoL), while HCC and chronic hepatitis patients had similar HRQoL results.

Confirming this hypothesis, Golabi and colleagues demonstrated that severity of liver disease may effects patients' HRQoL; in fact worsening hepatic dysfunction in patients with cirrhosis (higher MELD score) and development of complications, such as ascites and hepatic encephalopathy, can cause severe impairment of HRQoL[58].

Thus, there may be a stage-dependent relationship between the degree of fibrosis and the impairment of QoL in patients with severe fibrosis or cirrhosis, compared to those with moderate fibrosis.

## HCV-ASSOCIATED NEUROCOGNITIVE DISORDER AND MINIMAL HEPATIC ENCEPHALOPATHY

There is increasing evidence to support that cognitive impairments in patients with chronic HCV infection occur before the development of cirrhosis and are independent of liver function, viral load and genotype[15].

Many factors that may coexist in infected patients can aggravate cognitive decline such as the presence of liver cirrhosis and minimal hepatic encephalopathy (MHE), drug abuse and psychiatric disorders such as anxiety and depression[2]. On the other hand, pre-infectious intellectual functions and educational level can be protective against cognitive decline[59,60].

Genetic factors have also been seen to play a role in the development of cognitive disorders; in particular, some allelic variants of *ApoE* gene result in a lower impairment of attention and executive functions[61].

The term HCV-associated neurocognitive disorder (HCV-AND) is used to refer to this spectrum of alterations unrelated to advanced liver disease and therefore distinct from potentially reversible complications seen in patients with MHE[16].

Patients with chronic HCV infection may present symptoms related to cognitive decline. In particular, the areas mainly involved are: Executive functions: involved in problem solving, monitoring one's own behavior, self-control, cognitive flexibility, working memory, volition, sustained attention and logical reasoning; verbal learning and verbal recall. Therefore, in HCV patients there is a prevalent involvement of the frontal lobe, which is responsible for alterations of executive functions.

Cognitive domains related to posterior brain regions, primarily involved in visuospatial and visual perceptual abilities and constructive practice, are rarely involved; conversely these regions are mainly altered in patients with MHE[16]. Thus, there are some differences from both a pathogenic and a clinical-diagnostic point of view between HCV infected patients and those with hepatic encephalopathy.

Type C hepatic encephalopathy is one of the complications seen in patients with liver cirrhosis of different etiology and is a consequence of severe hepatocellular damage or porto-systemic shunts. This condition can manifest itself with a wide spectrum of neurological and psychiatric symptoms whose spectrum varies from subclinical forms to more severe forms characterized by a complete alteration of the state of consciousness.

To date, hepatic encephalopathy is divided into two types: covert which includes minimal hepatic encephalopathy and grade I hepatic encephalopathy, and overt (OHE), which includes grade II, III and IV hepatic encephalopathy[62-64].

OHE is characterized by personality alterations such as apathy, disinhibition and irritability, alterations in the sleep-wake cycle with excessive daytime rest, disorientation in time and space, altered state of consciousness, asterixis, acute confusion, stupor and finally coma.

The pathogenesis shown by hematoxylin and eosin staining is complex and sees a central role of ammonia which determines the activation of oxidative stress in astrocytes and swelling due to intracellular accumulation of osmotically active substances such as lactates and glutamine; a contribution is also linked to metal accumulation and neurosteroids that are able to activate inhibitory GABA-A receptors [65]. However, HE pathogenesis could be considered multifactorial. In fact, systemic inflammation and metabolites other than ammonia are involved.

MHE is the mildest form of hepatic encephalopathy, characterized by poor performance on psychometric tests that assess attention, working memory, psychomotor speed and visuospatial skills. Despite being subclinical, minimal HE has a heavy burden both on patients and caregivers. In fact, the relationship between MHE and QoL, driving capacity and sleeping is well known. Therefore, it is important to detect MHE, which can be recognized in asymptomatic patients using appropriate psychometric tests and neurophysiological methods.

MHE is a frequent complication of liver cirrhosis, affecting up to 80% of patients and, despite its minimal clinical expression, constitutes a significant problem as it is associated with burden on the caregiver, inability to drive, sleep disturbances, falls, worsening quality of life and risk of developing OHE[60].

Cognitive decline in patients with MHE mainly affects the following domains: Selective attention and vigilance; Psychomotor speed, with lengthening of reaction times; Inhibitory responses, with loss of inhibitory control; Visuospatial skills; Verbal skills are relatively preserved[66].

## DIAGNOSTIC STRATEGIES IN HCV-AND

To distinguish between HCV-AND and MHE in terms of cognitive decline, a multimodal approach is required that includes assessment of liver function, brain imaging and extensive neuropsychological tests that assess broad aspects of cognition and not just those related to frontal executive functions[16].

In patients with suspected HCV-AND, tests that can be used to analyze the various cognitive domains are: Verbal learning and episodic memory: Rey auditory verbal learning test, Hopkins verbal learning test total recall, brief visual memory test revised total recall, digit forward span, verbal learning and memory test; Working memory: digit backward span, letter number sequencing, paced auditory serial addition task; Visuospatial skills and planning: Rey-Osterrieth complex figure test (ROCF) in the immediate trial; Lexical skills and executive functions: phonemic and the semantic verbal fluency tests, color-word-interference test (Stroop), trail making test part B,

Wisconsin card sorting test, ROCF in the 10-min delayed recall trial; Logical thinking: verbal judgment test; Non-verbal intelligence: Horn's performance test system[67-69].

**Table 1** summarizes the main tests and their relative characteristics that can be used to investigate the altered cognitive domains in patients with HCV-AND.

Neuropsychological tests, such as potential P300 related to the event, have shown an increase in latency and a reduction in peak amplitude in patients with cognitive decline, regardless of confounding factors such as fatigue and depression[4].

### **Diagnostic strategies in MHE**

The optimal measure for diagnosing MHE is still debated. In fact, none of the methods proposed cover the complexity and the heterogeneity characteristic of this syndrome. Diagnosis of MHE can be made with psychometric tests and electrophysiological tests. Tests used to investigate domains known to be affected in patients with MHE are: Selective attention and vigilance: critical flicker frequency, continuous reaction time test, SCAN test; Psychomotor speed and visuospatial skills: psychometric hepatic encephalopathy score, Stroop test, repeatable battery for the assessment of neuropsychological status; inhibitory responses: inhibitory control test; animal naming test.

Similar to non-cirrhotic patients with chronic hepatitis C, patients with MHE present emotional alterations such as depression, anxiety and alexithymia[70], especially in the final stages of their pathology which is characterized by medical complications, hospitalizations, functional limitations and changes in body image[1].

They also have a reduced quality of life which can be linked to various mechanisms such as physical problems and complications related to liver cirrhosis and psychiatric symptoms. In fact, depression, anxiety and alexithymia are among the major determinants of the quality of life of cirrhotic patients, regardless of the severity of the liver disease.

The presence of these disorders can be explored using tests such as: Depression: Zung-self depression rating scale; Anxiety: Spielberger state-trait anxiety inventory Y1 and Y2; Alexithymia: Toronto alexithymia scale[70].

### **Imaging in HCV-AND**

Over time, several imaging studies have been conducted with the aim of finding a biological relationship between HCV infection and cognitive decline[2].

On magnetic resonance imaging, patients with cognitive decline show an increase in signal intensity in T2-weighted sequences in peri-ventricular white matter[71]. Furthermore, atrophy and cytoarchitectural alterations are observed in the lobe of insula which is involved in attention[16].

SPECT studies have demonstrated an alteration in mesencephalic/hypothalamic and striatal dopaminergic transporters in up to 60% of patients and this finding is associated with executive-attentional function decline[18].

On the other hand, a positron emission tomography (PET) with 18-fludeoxyglucose (18-FDG) study, demonstrated hypometabolism in the anterior cingulate gyrus and in the upper and middle frontal gyrus, responsible for fatigue and impaired attention, and in the parahippocampal gyrus and caudate nucleus bilaterally, causing anxiety, depression and lengthening of reaction times[16]. These data confirm the role of impaired dopaminergic transmission in the cognitive decline of patients with chronic HCV infection[2,72].

Spectroscopy studies have instead highlighted an increase in the choline/creatine ratio in the basal ganglia and frontal white matter[73], which is associated with executive functions decline[6]; another study showed a reduction in the N-acetyl aspartate/creatine ratio in frontal grey matter, which proves a reduction in the neuronal population in this area. These findings suggest an increase in cell membrane turnover and a decrease in neuronal functions, respectively[74].

The increase in myo-inositol levels agrees with chronic cellular inflammation induced by virus[75] and has been associated with fatigue and cognitive decline[76].

Overall, neurophysiological and imaging tests are important tools for characterizing cognitive impairments as they can anticipate dysfunction before it manifests clinically. They are also not subject to bias due to test batteries, self-reported measurements, different socio-cultural levels and different degrees of school education[15].

### **Imaging in HE**

Imaging findings in patients with liver cirrhosis are different to those previously described for patients with HCV-AND.

In fact, spectroscopy studies confirm that the pathogenetic mechanism for these symptoms is different to that observed in patients with chronic hepatitis C. In



**Table 1 Tests exploring cognitive domains[67-69]**

Test	Tested domains	Description
Rey auditory verbal learning test (RAVLT)	Immediate memory and learning	After hearing a list of 15 unrelated words, the patient has to recite as many words as he can recall for a total of five trials.
Hopkins verbal learning test total recall (HVLTL)	Verbal memory	This test consists of three parts: total recall, delayed recall and recognition. The test consists firstly of three free recall learning trials with 12 words from three different categories such as professions, food and sports (HVLTL total recall). 20-min later, the patient has to name the words from the free recall learning list (HVLTL delayed recall). Finally, the yes/no recognition trial is completed (HVLTL recognition).
Brief visual memory test revised total recall (BVRT)	Visuospatial memory	In three learning trials, the patient views the stimulus page for 10 s and then has to draw as many figures as possible in their correct location. A delayed recall trial is administered after a 25-min delay. Lastly, a recognition trial, in which the patient has to identify which of the 12 figures were included among the original geometric figures, is administered.
Digit forward span and digit backward	Verbal learning and episodic memory	The Digit Span consists of two different tests: digits forward (repeating digits forward) and digits backward (repeating digits in reverse). This test consists of pairs of sequences of numbers read by the examiner. When the patient repeats correctly the first sequence, the examiner reads the next one, which is longer by one number than the previous one, and continues until the patient fails a pair of sequences or correctly repeats the last sequence consisting of nine numbers.
Letter number sequencing (LNS)	Working memory	During administration, the patient listens to a series of numbers and letters read by the examiner. Then he has to repeat the numbers in ascending order and letters in alphabetic order.
Paced auditory serial addition task (PASAT)	Auditory-verbal divided attention; selective and sustained attention	Numbers are presented orally at a rate of about 1-2 s. The patient has to add pairs of numbers, adding each number to the previous one. In this way, the first number will be added with the second, the second with the third, the third with the fourth and so on.
Rey-Osterrieth complex figure test in the immediate trial (ROCF)	Visuoconstructive ability, problem solving, perceptual organization and visual memory	There are 18 elements overall. In the first part, the patient has to copy a figure (ROCF copy). Three minutes later, he has to perform the figure again without the stimulus (ROCF immediate recall). Two points are given when the elements are correctly reproduced; one point when the production is distorted, incomplete but placed properly, or completed but placed poorly; half point when the elements are distorted or incomplete and placed poorly; zero point when the elements are absent or not recognizable.
Phonemic and semantic verbal fluency test	Lexical skills and executive functions; verbal functioning	For the phonemic part, the patient has to list as many words as possible starting with an F, A or S during 60-s intervals. For the semantic part, he has to list as many animals as he can during a 60-s interval.
Color word interference test (Stroop)	Lexical skills, cognitive flexibility, selective attention and response inhibition (or disinhibition)	Patient has to read three different tables as fast as possible. Two of them represent the “congruous condition” in which he has to read names of colors printed in black. Conversely, in the third table, color-words are printed in an inconsistent colour ink. In this incongruent condition, the patient has to name the ink colour instead of reading the word.
Trial making test part B (TMT-B)	Lexical skills, executive functions, cognitive flexibility	In the TMT-B, the patient has to draw lines sequentially connecting numbers and words alternately. The score represents the amount of time required to complete the task.
Wisconsin card sorting test (WCST)	Lexical skills and executive functions; cognitive reasoning	Patient has to classify cards according to different criteria. There are different ways to classify each card and the only feedback is whether the classification is correct or not. Classification possibilities are the color of symbols, the shape of symbols and the number of shapes on each card. The classification rule changes every 10 cards; so, once the patient has figured out the rule, he will start making mistakes when the rule changes. This test measures how well the patient is able to adapt to changing rules.
Verbal judgment test (VJT)	Logical thinking	This test consists of an oral interview. The examiner asks the patient how he would solve a hypothetical situation.
Horn's performance test system (LPS)	Non-verbal intelligence	This test comprises 40 rows, each with 9 numbers and/or letters. Every row has a logical order with one letter or number that does not fit and the goal is to identify the mismatched character. The outcome parameter is the sum of correct rows.

RAVLT: Rey auditory verbal learning test; HVLTL: Hopkins verbal learning test total recall; BVRT: Brief visual memory test revised total recall; LNS: Letter number sequencing; PASAT: Paced auditory serial addition task; ROCF: Rey-Osterrieth complex figure test in the immediate trial; TMT-B: Trial making test part B; WCST: Wisconsin card sorting test; VJT: Verbal judgment test; LPS: Horn's performance test system.

particular, the prevailing pattern is characterized by a reduction of the choline/creatine and myo-inositol/creatine ratio and an increase in the glutamine/creatine ratio.

The exact mechanism underlying the reduction in choline levels has not been fully defined.

This is partly explained by a decrease in choline transport, malnutrition and cerebral metabolism alteration secondary to liver dysfunction.

Glutamine increase could be a consequence of hyperammonemia. In this condition, astrocytes detoxify ammonium converting it into glutamine which causes low-grade cerebral edema and symptoms of HE due to its osmotic effect[77].

In addition, brain MRI reveals basal ganglia hyperintensity in T1-weighted sequences, most likely related to manganese deposits[77].

## EFFECTS OF ANTIVIRAL THERAPY

Until recently, INF and pegylated INF have been the only effective treatments for HCV infection as modulators of the immune response, showing a sustained virological response (SVR) of up to 50%-80% when combined with ribavirin.

This therapy is associated with a high prevalence of neuropsychiatric disorders, which affect up to 70% of subjects. Predominant symptoms are mood disorders such as anxiety and depression, psychosis and manic agitation, suicidal ideation and cognitive decline. These disorders disappear at the end of therapy[16] and can be attributed to numerous pathophysiological complications associated with treatment such as alteration of monoamine metabolism, increase in apoptosis, reduction in cerebral neurotrophic factor, alteration of hypothalamic-pituitary-adrenal axis[78] and alteration of frontal-subcortical circuits[15]. Co-factors for the development of this disorder during antiviral therapy are low education, a known history of psychiatric disease and high serum concentrations of IL-6[79]. In subjects infected with HCV and treated with INF, PET studies with 18-FDG have shown a reduction of metabolic activity in the prefrontal cortex which agrees with a depressive state[80].

HCV infection treatment has been radically changed since the introduction of direct-acting antivirals (DAAs). INF-free regimens are better tolerated and are highly effective, reaching an SVR greater than 95%; furthermore, the simplicity of dosage and their safety profile guarantee good compliance.

These antiviral agents considerably improve extrahepatic symptoms underlining the direct and indirect pathogenetic role of virus in precipitating these disorders. Obviously, the success of this strategy depends on achievement of the SVR[6]. This has been confirmed in several clinical studies.

A recent study by Nardelli *et al*[1] showed an improvement in all domains investigated using the SF-36 questionnaire after therapy with DAAs, but also in psychiatric symptoms such as anxiety, depression and alexithymia, which were found to be among the major determinants of altered quality of life.

Some trials have shown that the improvement in quality of life is evident during the first 4 wk of therapy, coinciding with the suppression of viral replication, then continuing until the end of the therapy and beyond during the follow-up[81].

Patients who achieve SVR 12 wk after sofosbuvir therapy, including those with cirrhosis, have reported significant improvements in quality of life, general well-being, fatigue, sleep disturbances, emotional state and physical functioning[16,81].

When INF-based regimens are used, quality of life worsens during treatment due to poor tolerability of these regimens and then improves in those that reach SVR at the end of treatment. Similarly, ribavirin-based regimens are associated with greater impairment of quality of life during treatment than ribavirin-free regimens[81].

However, therapy with new antivirals improves not only psychiatric symptoms, but also cognitive changes.

The study by Kleefeld *et al*[68] demonstrated that after DAA therapy, fatigue and mental health, as well as executive functions, processing speed, learning, verbal fluency and motor skills improved in both monoinfected and those with HIV infection. However, no differences were found in working memory and verbal memory before and after therapy. The hypothesis that has been advanced to explain this phenomenon is that the compartmentalization of virus in the central nervous system may represent a potential source of reactivation of virus, thus explaining the persistence of some cognitive symptoms at the end of therapy with DAAs[45,66]. Therefore, it is unclear to what extent the new antiviral regimens can guarantee a return to normal[81].

To confirm this fact, neurocognitive tests and spectroscopy images were compared in several studies before and after antiviral therapy; patients who reached SVR had a significant reduction in the choline/creatine and myo-inositol/creatine ratio as well as an increase in cognitive functions compared to untreated patients or patients who did not achieve SVR[82].

Mixed cryoglobulinemia is strongly associated with HCV infection and its clinical expression varies from completely asymptomatic to severe vasculitis that manifests with dermatological, renal, neurological and musculoskeletal complications. Many authors report that up to 30% of HCV-infected patients have mixed cryoglobulinemia, but of these less than 10% develop symptoms. Symptomatic patients usually have higher immunoglobulin values.

Mortality and morbidity associated with mixed cryoglobulinemia are significant and treatments are focused on either eradicating the viral trigger with antiviral therapy or inhibiting B cell proliferation with immunosuppressive therapy, usually with steroids and rituximab in severe forms.

INF and ribavirin therapy has been associated with clinical and immunological improvement in patients with mixed cryoglobulinemia, in terms of cryoglobulin, IgM, rheumatoid factor and complement levels. Therefore, in patients who reach SVR, INF-based therapies exert a beneficial effect in those with HCV-CV (62%-78%). However, patients with HCV-CV have a lower rate of achievement of SVR than patients who do not (48.6% *vs* 61.4%). In fact, these patients tend to have comorbidities that can affect the achievement of SVR.

Almost all studies have also shown a complete or partial clinical response in patients with mixed cryoglobulinemia who reach SVR after DAAs therapy (61%-100%). The highest clinical response was seen in the study by Saadoun *et al*[83] in which all patients achieved a clinical response (90% complete and 10% partial) after 12 wk or 24 wk of sofosbuvir/daclatasvir therapy. A similar result was obtained by Gragnani *et al*[84] with complete or partial clinical response achieved in 93% of patients.

However, therapeutic effect may differ depending on the type of organ involved. The study by Gragnani *et al*[84] showed that the effect on dermatological symptoms is greater than that on nephrological and neurological symptoms. Furthermore, palpable purpura, renal pathology and skin ulcers resolve more rapidly than sicca syndrome, fatigue and peripheral neuropathy. In fact, neurological symptoms and sicca syndrome can be irreversible if there is permanent organ damage.

Among patients who have been cured of the infection and who continue to present symptoms of cryoglobulinemic vasculitis, an alternative explanation should be considered such as B-cell non-Hodgkin lymphoma. In fact, B lymphocyte proliferation can reach an autonomous and virus-independent replication phase demonstrated by the persistence of B lymphocyte clones t (14; 18) and small quantities of HCV-RNA in the lymphatic system after eradication therapy[85].

## CONCLUSION

HCV can strongly impair the neuropsychological panorama of cirrhotic patients. In this review, we summarized the most innovative aspects of central nervous system impairment in HCV positive patients. Particular attention was paid to patients with advanced liver disease and minimal HE. DAAs therapy completely revolutionized the standard of care for HCV infected patients. In fact, these drugs, characterized by great efficacy and tolerability, have made it possible to reach levels of SVR unthinkable in the twentieth century. Further studies are needed to evaluate in depth the effects of HCV eradication, even in the long-term, on the neuropsychological alterations of these patients, and to determine if there is a residual deficit, which cannot be resolved with viral eradication.

## REFERENCES

- 1 Nardelli S, Riggio O, Rosati D, Gioia S, Farcomeni A, Ridola L. Hepatitis C virus eradication with directly acting antivirals improves health-related quality of life and psychological symptoms. *World J Gastroenterol* 2019; **25**: 6928-6938 [PMID: 31908396 DOI: 10.3748/wjg.v25.i48.6928]
- 2 Yarlott L, Heald E, Forton D. Hepatitis C virus infection, and neurological and psychiatric disorders - A review. *J Adv Res* 2017; **8**: 139-148 [PMID: 28149649 DOI: 10.1016/j.jare.2016.09.005]
- 3 Adinolfi LE, Nevola R, Lus G, Restivo L, Guerrera B, Romano C, Zampino R, Rinaldi L, Sellitto A, Giordano M, Marrone A. Chronic hepatitis C virus infection and neurological and psychiatric disorders: an overview. *World J Gastroenterol* 2015; **21**: 2269-2280 [PMID: 25741133 DOI: 10.3748/wjg.v21.i8.2269]
- 4 Monaco S, Ferrari S, Gajofatto A, Zanusso G, Mariotto S. HCV-related nervous system disorders. *Clin Dev Immunol* 2012; **2012**: 236148 [PMID: 22899946 DOI: 10.1155/2012/236148]
- 5 Dammacco F, Sansonno D, Piccoli C, Racanelli V, D'Amore FP, Lauletta G. The lymphoid system in hepatitis C virus infection: autoimmunity, mixed cryoglobulinemia, and Overt B-cell malignancy. *Semin Liver Dis* 2000; **20**: 143-157 [PMID: 10946420 DOI: 10.1055/s-2000-9613]
- 6 Mathew S, Faheem M, Ibrahim SM, Iqbal W, Rauff B, Fatima K, Qadri I. Hepatitis C virus and neurological damage. *World J Hepatol* 2016; **8**: 545-556 [PMID: 27134702 DOI: 10.4254/wjh.v8.i12.545]
- 7 Forton DM, Thomas HC, Murphy CA, Allsop JM, Foster GR, Main J, Wesnes KA, Taylor-Robinson

- SD. Hepatitis C and cognitive impairment in a cohort of patients with mild liver disease. *Hepatology* 2002; **35**: 433-439 [PMID: [11826420](#) DOI: [10.1053/jhep.2002.30688](#)]
- 8 **Fletcher NF**, Wilson GK, Murray J, Hu K, Lewis A, Reynolds GM, Stamatakis Z, Meredith LW, Rowe IA, Luo G, Lopez-Ramirez MA, Baumert TF, Weksler B, Couraud PO, Kim KS, Romero IA, Jopling C, Morgello S, Balfe P, McKeating JA. Hepatitis C virus infects the endothelial cells of the blood-brain barrier. *Gastroenterology* 2012; **142**: 634-643.e6 [PMID: [22138189](#) DOI: [10.1053/j.gastro.2011.11.028](#)]
  - 9 **Paulino AD**, Ubhi K, Rockenstein E, Adame A, Crews L, Letendre S, Ellis R, Everall IP, Grant I, Masliah E. Neurotoxic effects of the HCV core protein are mediated by sustained activation of ERK via TLR2 signaling. *J Neurovirol* 2011; **17**: 327-340 [PMID: [21660601](#) DOI: [10.1007/s13365-011-0039-0](#)]
  - 10 **Fletcher NF**, Yang JP, Farquhar MJ, Hu K, Davis C, He Q, Dowd K, Ray SC, Krieger SE, Neyts J, Baumert TF, Balfe P, McKeating JA, Wong-Staal F. Hepatitis C virus infection of neuroepithelioma cell lines. *Gastroenterology* 2010; **139**: 1365-1374 [PMID: [20538002](#) DOI: [10.1053/j.gastro.2010.06.008](#)]
  - 11 **Ploss A**, Evans MJ, Gaysinskaya VA, Panis M, You H, de Jong YP, Rice CM. Human occludin is a hepatitis C virus entry factor required for infection of mouse cells. *Nature* 2009; **457**: 882-886 [PMID: [19182773](#) DOI: [10.1038/nature07684](#)]
  - 12 **Wilkinson J**, Radkowski M, Laskus T. Hepatitis C virus neuroinvasion: identification of infected cells. *J Virol* 2009; **83**: 1312-1319 [PMID: [19019968](#) DOI: [10.1128/JVI.01890-08](#)]
  - 13 **Senzolo M**, Schiff S, D'Aloiso CM, Crivellin C, Cholongitas E, Burra P, Montagnese S. Neuropsychological alterations in hepatitis C infection: the role of inflammation. *World J Gastroenterol* 2011; **17**: 3369-3374 [PMID: [21876628](#) DOI: [10.3748/wjg.v17.i29.3369](#)]
  - 14 **Wilkinson J**, Radkowski M, Eschbacher JM, Laskus T. Activation of brain macrophages/microglia cells in hepatitis C infection. *Gut* 2010; **59**: 1394-1400 [PMID: [20675697](#) DOI: [10.1136/gut.2009.199356](#)]
  - 15 **Perry W**, Hilsabeck RC, Hassanein TI. Cognitive dysfunction in chronic hepatitis C: a review. *Dig Dis Sci* 2008; **53**: 307-321 [PMID: [17703362](#) DOI: [10.1007/s10620-007-9896-z](#)]
  - 16 **Tagliapietra M**, Monaco S. Neuroimaging Findings in Chronic Hepatitis C Virus Infection: Correlation with Neurocognitive and Neuropsychiatric Manifestations. *Int J Mol Sci* 2020; **21** [PMID: [32252497](#) DOI: [10.3390/ijms21072478](#)]
  - 17 **Cozzi A**, Zignego AL, Carpendo R, Biagiotti T, Aldinucci A, Monti M, Giannini C, Rosselli M, Laffi G, Moroni F. Low serum tryptophan levels, reduced macrophage IDO activity and high frequency of psychopathology in HCV patients. *J Viral Hepat* 2006; **13**: 402-408 [PMID: [16842443](#) DOI: [10.1111/j.1365-2893.2005.00706.x](#)]
  - 18 **Weissenborn K**, Ennen JC, Bokemeyer M, Ahl B, Wurster U, Tillmann H, Trebst C, Hecker H, Berding G. Monoaminergic neurotransmission is altered in hepatitis C virus infected patients with chronic fatigue and cognitive impairment. *Gut* 2006; **55**: 1624-1630 [PMID: [16682431](#) DOI: [10.1136/gut.2005.080267](#)]
  - 19 **Marsland AL**, Petersen KL, Sathanoori R, Muldoon MF, Neumann SA, Ryan C, Flory JD, Manuck SB. Interleukin-6 covaries inversely with cognitive performance among middle-aged community volunteers. *Psychosom Med* 2006; **68**: 895-903 [PMID: [17132839](#) DOI: [10.1097/01.psy.0000238451.22174.92](#)]
  - 20 **Bladowska J**, Zimny A, Knysz B, Małyszczak K, Kołtowska A, Szewczyk P, Gąsiorowski J, Furdal M, Sasiadek MJ. Evaluation of early cerebral metabolic, perfusion and microstructural changes in HCV-positive patients: a pilot study. *J Hepatol* 2013; **59**: 651-657 [PMID: [23680314](#) DOI: [10.1016/j.jhep.2013.05.008](#)]
  - 21 **Bester M**, Forkert ND, Stellmann JP, Stürner K, Aly L, Drabik A, Young KL, Heesen C, Fiehler J, Siemonsen S. Increased perfusion in normal appearing white matter in high inflammatory multiple sclerosis patients. *PLoS One* 2015; **10**: e0119356 [PMID: [25774497](#) DOI: [10.1371/journal.pone.0119356](#)]
  - 22 **Ramos-Casals M**, Stone JH, Cid MC, Bosch X. The cryoglobulinaemias. *Lancet* 2012; **379**: 348-360 [PMID: [21868085](#) DOI: [10.1016/S0140-6736\(11\)60242-0](#)]
  - 23 **Pileri P**, Uematsu Y, Campagnoli S, Galli G, Falugi F, Petracca R, Weiner AJ, Houghton M, Rosa D, Grandi G, Abrignani S. Binding of hepatitis C virus to CD81. *Science* 1998; **282**: 938-941 [PMID: [9794763](#) DOI: [10.1126/science.282.5390.938](#)]
  - 24 **Schott P**, Polzien F, Müller-Issberner A, Ramadori G, Hartmann H. In vitro reactivity of cryoglobulin IgM and IgG in hepatitis C virus-associated mixed cryoglobulinemia. *J Hepatol* 1998; **28**: 17-26 [PMID: [9537859](#) DOI: [10.1016/S0168-8278\(98\)80197-9](#)]
  - 25 **Lee MH**, Yang HI, Wang CH, Jen CL, Yeh SH, Liu CJ, You SL, Chen WJ, Chen CJ. Hepatitis C virus infection and increased risk of cerebrovascular disease. *Stroke* 2010; **41**: 2894-2900 [PMID: [20966408](#) DOI: [10.1161/STROKEAHA.110.598136](#)]
  - 26 **Cacoub P**, Sbai A, Hausfater P, Papo T, Gatel A, Piette JC. [Central nervous system involvement in hepatitis C virus infection]. *Gastroenterol Clin Biol* 1998; **22**: 631-633 [PMID: [9762334](#)]
  - 27 **Ishizaka N**, Ishizaka Y, Takahashi E, Tooda Ei, Hashimoto H, Nagai R, Yamakado M. Association between hepatitis C virus seropositivity, carotid-artery plaque, and intima-media thickening. *Lancet* 2002; **359**: 133-135 [PMID: [11809259](#) DOI: [10.1016/S0140-6736\(02\)07339-7](#)]
  - 28 **Boddi M**, Abbate R, Chellini B, Giusti B, Giannini C, Pratesi G, Rossi L, Pratesi C, Gensini GF, Paperetti L, Zignego AL. Hepatitis C virus RNA localization in human carotid plaques. *J Clin Virol*



- 2010; **47**: 72-75 [PMID: [19896417](#) DOI: [10.1016/j.jev.2009.10.005](#)]
- 29 **Adinolfi LE**, Restivo L, Zampino R, Lonardo A, Loria P. Metabolic alterations and chronic hepatitis C: treatment strategies. *Expert Opin Pharmacother* 2011; **12**: 2215-2234 [PMID: [21883025](#) DOI: [10.1517/14656566.2011.597742](#)]
- 30 **Malnick SD**, Abend Y, Evron E, Sthoeger ZM. HCV hepatitis associated with anticardiolipin antibody and a cerebrovascular accident. Response to interferon therapy. *J Clin Gastroenterol* 1997; **24**: 40-42 [PMID: [9013350](#) DOI: [10.1097/00004836-199701000-00009](#)]
- 31 **Serena M**, Biscaro R, Moretto G, Recchia E. Peripheral and central nervous system involvement in essential mixed cryoglobulinemia: a case report. *Clin Neuropathol* 1991; **10**: 177-180 [PMID: [1884525](#)]
- 32 **Seifert F**, Struffert T, Hildebrandt M, Blümcke I, Brück W, Staykov D, Huttner HB, Hilz MJ, Schwab S, Bardutzky J. In vivo detection of hepatitis C virus (HCV) RNA in the brain in a case of encephalitis: evidence for HCV neuroinvasion. *Eur J Neurol* 2008; **15**: 214-218 [PMID: [18215154](#) DOI: [10.1111/j.1468-1331.2007.02044.x](#)]
- 33 **Bolay H**, Söylemezoğlu F, Nurlu G, Tuncer S, Varli K. PCR detected hepatitis C virus genome in the brain of a case with progressive encephalomyelitis with rigidity. *Clin Neurol Neurosurg* 1996; **98**: 305-308 [PMID: [9081776](#) DOI: [10.1016/0303-8467\(96\)00040-6](#)]
- 34 **Sacconi S**, Salvati L, Merelli E. Acute disseminated encephalomyelitis associated with hepatitis C virus infection. *Arch Neurol* 2001; **58**: 1679-1681 [PMID: [11594929](#) DOI: [10.1001/archneur.58.10.1679](#)]
- 35 **Vital C**, Vital A, Canron MH, Jaffré A, Viallard JF, Ragnaud JM, Brechenmacher C, Lagueny A. Combined nerve and muscle biopsy in the diagnosis of vasculitic neuropathy. A 16-year retrospective study of 202 cases. *J Peripher Nerv Syst* 2006; **11**: 20-29 [PMID: [16519779](#) DOI: [10.1111/j.1085-9489.2006.00060.x](#)]
- 36 **De Martino L**, Sampaolo S, Tucci C, Ambrosone L, Budillon A, Migliaresi S, Di Iorio G. Viral RNA in nerve tissues of patients with hepatitis C infection and peripheral neuropathy. *Muscle Nerve* 2003; **27**: 102-104 [PMID: [12508302](#) DOI: [10.1002/mus.10260](#)]
- 37 **Authier FJ**, Bassez G, Payan C, Guillevin L, Pawlotsky JM, Degos JD, Gherardi RK, Belec L. Detection of genomic viral RNA in nerve and muscle of patients with HCV neuropathy. *Neurology* 2003; **60**: 808-812 [PMID: [12629238](#) DOI: [10.1212/01.wnl.0000044399.71601.ca](#)]
- 38 **Tembl JJ**, Ferrer JM, Sevilla MT, Lago A, Mayordomo F, Vilchez JJ. Neurologic complications associated with hepatitis C virus infection. *Neurology* 1999; **53**: 861-864 [PMID: [10489056](#) DOI: [10.1212/wnl.53.4.861](#)]
- 39 **Bant A**, Hurowitz B, Hassan N, Du VT, Nadir A. Complex regional pain syndrome (reflex sympathetic dystrophy) in a patient with essential mixed cryoglobulinemia and chronic hepatitis C. *J Pak Med Assoc* 2007; **57**: 96-98 [PMID: [17370795](#)]
- 40 **Costa J**, Resende C, de Carvalho M. Motor-axonal polyneuropathy associated with hepatitis C virus. *Eur J Neurol* 2003; **10**: 183-185 [PMID: [12603295](#) DOI: [10.1046/j.1468-1331.2003.00560.x](#)]
- 41 **Ammendola A**, Sampaolo S, Migliaresi S, Ambrosone L, Ammendola E, Ciccone G, Di Iorio G. Autonomic neuropathy in mixed cryoglobulinemia. *J Neurol* 2007; **254**: 215-219 [PMID: [17334955](#) DOI: [10.1007/s00415-006-0333-6](#)]
- 42 **Bonetti B**, Scardoni M, Monaco S, Rizzuto N, Scarpa A. Hepatitis C virus infection of peripheral nerves in type II cryoglobulinaemia. *Virchows Arch* 1999; **434**: 533-535 [PMID: [10394889](#) DOI: [10.1007/s004280050380](#)]
- 43 **Teuber G**, Schäfer A, Rimpel J, Paul K, Keicher C, Scheurlen M, Zeuzem S, Kraus MR. Deterioration of health-related quality of life and fatigue in patients with chronic hepatitis C: Association with demographic factors, inflammatory activity, and degree of fibrosis. *J Hepatol* 2008; **49**: 923-929 [PMID: [18929420](#) DOI: [10.1016/j.jhep.2008.07.025](#)]
- 44 **Biasiotto A**, Casato M, La Cesa S, Colantuono S, Di Stefano G, Leone C, Carlesimo M, Piroso S, Cruccu G, Truini A. Clinical, neurophysiological, and skin biopsy findings in peripheral neuropathy associated with hepatitis C virus-related cryoglobulinemia. *J Neurol* 2014; **261**: 725-731 [PMID: [24500496](#) DOI: [10.1007/s00415-014-7261-7](#)]
- 45 **Yeoh SW**, Holmes ACN, Saling MM, Everall IP, Nicoll AJ. Depression, fatigue and neurocognitive deficits in chronic hepatitis C. *Hepatol Int* 2018; **12**: 294-304 [PMID: [29931590](#) DOI: [10.1007/s12072-018-9879-5](#)]
- 46 **Huckans M**, Fuller BE, Olavarria H, Sasaki AW, Chang M, Flora KD, Kolessar M, Kriz D, Anderson JR, Vandenbark AA, Loftis JM. Multi-analyte profile analysis of plasma immune proteins: altered expression of peripheral immune factors is associated with neuropsychiatric symptom severity in adults with and without chronic hepatitis C virus infection. *Brain Behav* 2014; **4**: 123-142 [PMID: [24683507](#) DOI: [10.1002/brb3.200](#)]
- 47 **Jones EA**. Relief from profound fatigue associated with chronic liver disease by long-term ondansetron therapy. *Lancet* 1999; **354**: 397 [PMID: [10437877](#) DOI: [10.1016/S0140-6736\(99\)02936-0](#)]
- 48 **Ashrafi M**, Modabbernia A, Dalir M, Taslimi S, Karami M, Ostovaneh MR, Malekzadeh R, Poustchi H. Predictors of mental and physical health in non-cirrhotic patients with viral hepatitis: a case control study. *J Psychosom Res* 2012; **73**: 218-224 [PMID: [22850263](#) DOI: [10.1016/j.jpsychores.2012.06.006](#)]
- 49 **Raison CL**, Demetrashvili M, Capuron L, Miller AH. Neuropsychiatric adverse effects of interferon-alpha: recognition and management. *CNS Drugs* 2005; **19**: 105-123 [PMID: [15697325](#) DOI: [10.1016/j.jev.2009.10.005](#)]



- 10.2165/00023210-200519020-00002]
- 50 **Helbling B**, Overbeck K, Gonvers JJ, Malinverni R, Dufour JF, Borovicka J, Heim M, Cerny A, Negro F, Bucher S, Rickenbach M, Renner EL, Mullhaupt B; Swiss Hepatitis C Cohort Study. Host-rather than virus-related factors reduce health-related quality of life in hepatitis C virus infection. *Gut* 2008; **57**: 1597-1603 [PMID: 18625696 DOI: 10.1136/gut.2007.142844]
  - 51 **Brienza RS**, Stein MD, Chen M, Gogineni A, Sobota M, Maksad J, Hu P, Clarke J. Depression among needle exchange program and methadone maintenance clients. *J Subst Abuse Treat* 2000; **18**: 331-337 [PMID: 10812305 DOI: 10.1016/s0740-5472(99)00084-7]
  - 52 **McDonald J**, Jayasuriya J, Bindley P, Gonsalvez C, Gluskeska S. Fatigue and psychological disorders in chronic hepatitis C. *J Gastroenterol Hepatol* 2002; **17**: 171-176 [PMID: 11966947 DOI: 10.1046/j.1440-1746.2002.02669.x]
  - 53 **Su AI**, Wiltshire T, Batalov S, Lapp H, Ching KA, Block D, Zhang J, Soden R, Hayakawa M, Kreiman G, Cooke MP, Walker JR, Hogenesch JB. A gene atlas of the mouse and human protein-encoding transcriptomes. *Proc Natl Acad Sci USA* 2004; **101**: 6062-6067 [PMID: 15075390 DOI: 10.1073/pnas.0400782101]
  - 54 **Hülsermann U**, Hoffmann MM, Massing U, Fricker G. Uptake of apolipoprotein E fragment coupled liposomes by cultured brain microvessel endothelial cells and intact brain capillaries. *J Drug Target* 2009; **17**: 610-618 [PMID: 19694613 DOI: 10.1080/10611860903105986]
  - 55 **Foster GR**. Hepatitis C virus infection: quality of life and side effects of treatment. *J Hepatol* 1999; **31** Suppl 1: 250-254 [PMID: 10622597 DOI: 10.1016/s0168-8278(99)80411-5]
  - 56 **Strauss E**, Porto-Ferreira FA, de Almeida-Neto C, Teixeira MC. Altered quality of life in the early stages of chronic hepatitis C is due to the virus itself. *Clin Res Hepatol Gastroenterol* 2014; **38**: 40-45 [PMID: 24239318 DOI: 10.1016/j.clinre.2013.08.008]
  - 57 **Jang ES**, Kim YS, Kim KA, Lee YJ, Chung WJ, Kim IH, Lee BS, Jeong SH. Factors Associated with Health-Related Quality of Life in Korean Patients with Chronic Hepatitis C Infection Using the SF-36 and EQ-5D. *Gut Liver* 2018; **12**: 440-448 [PMID: 29588435 DOI: 10.5009/gnl17322]
  - 58 **Golabi P**, Sayiner M, Bush H, Gerber LH, Younossi ZM. Patient-Reported Outcomes and Fatigue in Patients with Chronic Hepatitis C Infection. *Clin Liver Dis* 2017; **21**: 565-578 [PMID: 28689594 DOI: 10.1016/j.cld.2017.03.011]
  - 59 **Sakamoto M**, Woods SP, Kolessar M, Kriz D, Anderson JR, Olavarria H, Sasaki AW, Chang M, Flora KD, Loftis JM, Huckans M. Protective effects of higher cognitive reserve for neuropsychological and daily functioning among individuals infected with hepatitis C. *J Neurovirol* 2013; **19**: 442-451 [PMID: 24018902 DOI: 10.1007/s13365-013-0196-4]
  - 60 **Bieliauskas LA**, Back-Madruga C, Lindsay KL, Wright EC, Kronfol Z, Lok AS, Fontana RJ; Halt-C Trial Group. Cognitive reserve and neuropsychological functioning in patients infected with hepatitis C. *J Int Neuropsychol Soc* 2007; **13**: 687-692 [PMID: 17521478 DOI: 10.1017/S1355617707070877]
  - 61 **Wozniak MA**, Lugo Iparraguirre LM, Dirks M, Deb-Chatterji M, Pflugrad H, Goldbecker A, Tryc AB, Worthmann H, Gess M, Crossey MM, Forton DM, Taylor-Robinson SD, Itzhaki RF, Weissenborn K. Apolipoprotein E-ε4 deficiency and cognitive function in hepatitis C virus-infected patients. *J Viral Hepat* 2016; **23**: 39-46 [PMID: 26306786 DOI: 10.1111/jvh.12443]
  - 62 **Rose CF**, Amodio P, Bajaj JS, Dhiman RK, Montagnese S, Taylor-Robinson SD, Vilstrup H, Jalan R. Hepatic encephalopathy: Novel insights into classification, pathophysiology and therapy. *J Hepatol* 2020; **73**: 1526-1547 [PMID: 33097308 DOI: 10.1016/j.jhep.2020.07.013]
  - 63 **Vilstrup H**, Amodio P, Bajaj J, Cordoba J, Ferenci P, Mullen KD, Weissenborn K, Wong P. Hepatic encephalopathy in chronic liver disease: 2014 Practice Guideline by the American Association for the Study of Liver Diseases and the European Association for the Study of the Liver. *Hepatology* 2014; **60**: 715-735 [PMID: 25042402 DOI: 10.1002/hep.27210]
  - 64 **Montagnese S**, Russo FP, Amodio P, Burra P, Gasbarrini A, Loguercio C, Marchesini G, Merli M, Ponziani FR, Riggio O, Scarpignato C. Hepatic encephalopathy 2018: A clinical practice guideline by the Italian Association for the Study of the Liver (AISF). *Dig Liver Dis* 2019; **51**: 190-205 [PMID: 30606696 DOI: 10.1016/j.dld.2018.11.035]
  - 65 **Nardone R**, Taylor AC, Höller Y, Brigo F, Lochner P, Trinkla E. Minimal hepatic encephalopathy: A review. *Neurosci Res* 2016; **111**: 1-12 [PMID: 27153746 DOI: 10.1016/j.neures.2016.04.009]
  - 66 **Ridola L**, Riggio O, Gioia S, Faccioli J, Nardelli S. Clinical management of type C hepatic encephalopathy. *United European Gastroenterol J* 2020; **8**: 536-543 [PMID: 32213035 DOI: 10.1177/2050640620909675]
  - 67 **Vaghi G**, Gori B, Strigaro G, Burlone M, Minisini R, Barbaglia MN, Brigatti E, Varrasi C, Pirisi M, Cantello R. Direct antivirals and cognitive impairment in hepatitis C: a clinical-neurophysiologic study. *J Neurovirol* 2020; **26**: 870-879 [PMID: 32910431 DOI: 10.1007/s13365-020-00904-6]
  - 68 **Kleefeld F**, Heller S, Ingiliz P, Jessen H, Petersen A, Kopp U, Kraft A, Hahn K. Interferon-free therapy in hepatitis C virus (HCV) monoinfected and HCV/HIV coinfecting patients: effect on cognitive function, fatigue, and mental health. *J Neurovirol* 2018; **24**: 557-569 [PMID: 29785584 DOI: 10.1007/s13365-018-0647-z]
  - 69 **Morgello S**, Estanislao L, Ryan E, Gerits P, Simpson D, Verma S, DiRocco A, Sharp V; Manhattan HIV Brain Bank. Effects of hepatic function and hepatitis C virus on the nervous system assessment of advanced-stage HIV-infected individuals. *AIDS* 2005; **19** Suppl 3: S116-S122 [PMID: 16251806 DOI: 10.1097/01.aids.0000192079.49185.f9]
  - 70 **Nardelli S**, Pentassuglio I, Pasquale C, Ridola L, Moscucci F, Merli M, Mina C, Marianetti M, Fratino M, Izzo C, Merkel C, Riggio O. Depression, anxiety and alexithymia symptoms are major

- determinants of health related quality of life (HRQoL) in cirrhotic patients. *Metab Brain Dis* 2013; **28**: 239-243 [PMID: [23296469](#) DOI: [10.1007/s11011-012-9364-0](#)]
- 71 **Buccoliero R**, Gambelli S, Sicurelli F, Malandrini A, Palmeri S, De Santis M, Stromillo ML, De Stefano N, Sperduto A, Musumeci SA, Federico A. Leukoencephalopathy as a rare complication of hepatitis C infection. *Neurol Sci* 2006; **27**: 360-363 [PMID: [17122948](#) DOI: [10.1007/s10072-006-0711-y](#)]
  - 72 **Heeren M**, Weissenborn K, Arvanitis D, Bokemeyer M, Goldbecker A, Tountopoulou A, Peschel T, Grosskreutz J, Hecker H, Buchert R, Berding G. Cerebral glucose utilisation in hepatitis C virus infection-associated encephalopathy. *J Cereb Blood Flow Metab* 2011; **31**: 2199-2208 [PMID: [21629258](#) DOI: [10.1038/jcbfm.2011.82](#)]
  - 73 **Forton DM**, Allsop JM, Main J, Foster GR, Thomas HC, Taylor-Robinson SD. Evidence for a cerebral effect of the hepatitis C virus. *Lancet* 2001; **358**: 38-39 [PMID: [11454379](#) DOI: [10.1016/S0140-6736\(00\)05270-3](#)]
  - 74 **McAndrews MP**, Farcnik K, Carlen P, Damyanovich A, Mrkonjic M, Jones S, Heathcote EJ. Prevalence and significance of neurocognitive dysfunction in hepatitis C in the absence of correlated risk factors. *Hepatology* 2005; **41**: 801-808 [PMID: [15793853](#) DOI: [10.1002/hep.20635](#)]
  - 75 **Bokemeyer M**, Ding XQ, Goldbecker A, Raab P, Heeren M, Arvanitis D, Tillmann HL, Lanfermann H, Weissenborn K. Evidence for neuroinflammation and neuroprotection in HCV infection-associated encephalopathy. *Gut* 2011; **60**: 370-377 [PMID: [20926642](#) DOI: [10.1136/gut.2010.217976](#)]
  - 76 **Thames AD**, Castellon SA, Singer EJ, Nagarajan R, Sarma MK, Smith J, Thaler NS, Truong JH, Schonfeld D, Thomas MA, Hinkin CH. Neuroimaging abnormalities, neurocognitive function, and fatigue in patients with hepatitis C. *Neurol Neuroimmunol Neuroinflamm* 2015; **2**: e59 [PMID: [25610883](#) DOI: [10.1212/NXI.0000000000000059](#)]
  - 77 **Yadav SK**, Goel A, Saraswat VA, Thomas MA, Wang E, Marincola FM, Haris M, Gupta RK. Evaluation of cognitivity, proinflammatory cytokines, and brain magnetic resonance imaging in minimal hepatic encephalopathy induced by cirrhosis and extrahepatic portal vein obstruction. *J Gastroenterol Hepatol* 2016; **31**: 1986-1994 [PMID: [27119420](#) DOI: [10.1111/jgh.13427](#)]
  - 78 **Rifai MA**, Gleason OC, Sabouni D. Psychiatric care of the patient with hepatitis C: a review of the literature. *Prim Care Companion J Clin Psychiatry* 2010; **12** [PMID: [21494349](#) DOI: [10.4088/PCC.09r00877whi](#)]
  - 79 **McMahon JM**, Tortu S. A potential hidden source of hepatitis C infection among noninjecting drug users. *J Psychoactive Drugs* 2003; **35**: 455-460 [PMID: [14986874](#) DOI: [10.1080/02791072.2003.10400492](#)]
  - 80 **Juengling FD**, Ebert D, Gut O, Engelbrecht MA, Rasenack J, Nitzsche EU, Bauer J, Lieb K. Prefrontal cortical hypometabolism during low-dose interferon alpha treatment. *Psychopharmacology (Berl)* 2000; **152**: 383-389 [PMID: [11140330](#) DOI: [10.1007/s002130000549](#)]
  - 81 **Forton D**, Weissenborn K, Bondin M, Cacoub P. Expert opinion on managing chronic HCV in patients with neuropsychiatric manifestations. *Antivir Ther* 2018; **23**: 47-55 [PMID: [30451150](#) DOI: [10.3851/IMP3245](#)]
  - 82 **Jadali Z**. Autoimmune thyroid disorders in hepatitis C virus infection: Effect of interferon therapy. *Indian J Endocrinol Metab* 2013; **17**: 69-75 [PMID: [23776855](#) DOI: [10.4103/2230-8210.107856](#)]
  - 83 **Saadoun D**, Pol S, Ferfar Y, Alric L, Hezode C, Si Ahmed SN, de Saint Martin L, Comarmond C, Bouyer AS, Musset L, Poynard T, Resche Rigon M, Cacoub P. Efficacy and Safety of Sofosbuvir Plus Daclatasvir for Treatment of HCV-Associated Cryoglobulinemia Vasculitis. *Gastroenterology* 2017; **153**: 49-52.e5 [PMID: [28288791](#) DOI: [10.1053/j.gastro.2017.03.006](#)]
  - 84 **Gragnani L**, Visentini M, Fognani E, Urraro T, De Santis A, Petracchia L, Perez M, Ceccotti G, Colantuono S, Mitrevski M, Stasi C, Del Padre M, Monti M, Gianni E, Pulsoni A, Fiorilli M, Casato M, Zignego AL. Prospective study of guideline-tailored therapy with direct-acting antivirals for hepatitis C virus-associated mixed cryoglobulinemia. *Hepatology* 2016; **64**: 1473-1482 [PMID: [27483451](#) DOI: [10.1002/hep.28753](#)]
  - 85 **Bunchorntavakul C**, Mitrani R, Reddy KR. Advances in HCV and Cryoglobulinemic Vasculitis in the Era of DAAs: Are We at the End of the Road? *J Clin Exp Hepatol* 2018; **8**: 81-94 [PMID: [29743799](#) DOI: [10.1016/j.jceh.2017.11.012](#)]



Published by **Baishideng Publishing Group Inc**  
7041 Koll Center Parkway, Suite 160, Pleasanton, CA 94566, USA

**Telephone:** +1-925-3991568

**E-mail:** [bpgoffice@wjgnet.com](mailto:bpgoffice@wjgnet.com)

**Help Desk:** <https://www.f6publishing.com/helpdesk>

<https://www.wjgnet.com>

