

World Journal of *Gastroenterology*

World J Gastroenterol 2021 August 28; 27(32): 5297-5459



OPINION REVIEW

- 5297** Management of Flood syndrome: What can we do better?
Strainiene S, Peculyte M, Strainys T, Stundiene I, Savlan I, Liakina V, Valantinas J

REVIEW

- 5306** Radiomics and machine learning applications in rectal cancer: Current update and future perspectives
Stanzione A, Verde F, Romeo V, Boccadifuoco F, Mainenti PP, Maurea S
- 5322** Could the burden of pancreatic cancer originate in childhood?
Diaconescu S, Gilcă-Blanariu GE, Poamaneagra S, Marginean O, Paduraru G, Stefanescu G

MINIREVIEWS

- 5341** Application of artificial intelligence in preoperative imaging of hepatocellular carcinoma: Current status and future perspectives
Feng B, Ma XH, Wang S, Cai W, Liu XB, Zhao XM
- 5351** Artificial intelligence application in diagnostic gastrointestinal endoscopy - Deus ex machina?
Correia FP, Lourenço LC
- 5362** Faecal microbiota transplantation enhances efficacy of immune checkpoint inhibitors therapy against cancer
Kang YB, Cai Y
- 5376** Immune checkpoint inhibitor-related hepatotoxicity: A review
Remash D, Prince DS, McKenzie C, Strasser SI, Kao S, Liu K

ORIGINAL ARTICLE

Basic Study

- 5392** Therapeutic effect of *Cistanche deserticola* on defecation in senile constipation rat model through stem cell factor/C-kit signaling pathway
Zhang X, Zheng FJ, Zhang Z
- 5404** Recombinant angiopoietin-like protein 4 attenuates intestinal barrier structure and function injury after ischemia/reperfusion
Wang ZY, Lin JY, Feng YR, Liu DS, Zhao XZ, Li T, Li SY, Sun JC, Li SF, Jia WY, Jing HR

Retrospective Study

- 5424** Prolonged survival in patients with hand-foot skin reaction secondary to cooperative sorafenib treatment
Ochi M, Kamoshida T, Araki M, Ikegami T

- 5438** Contrast-enhanced ultrasound imaging for intestinal lymphoma

Cui NY, Gong XT, Tian YT, Wang Y, Zhang R, Liu MJ, Han J, Wang B, Yang D

Observational Study

- 5448** Intestinal ischemic manifestations of SARS-CoV-2: Results from the ABDOCOVID multicentre study

Norsa L, Bonaffini PA, Caldato M, Bonifacio C, Sonzogni A, Indriolo A, Valle C, Furfaro F, Bonanomi A, Franco PN, Gori M, Smania V, Scaramella L, Forzenigo L, Vecchi M, Solbiati M, Costantino G, Danese S, D'Antiga L, Sironi S, Elli L

ABOUT COVER

Editorial Board Member of *World Journal of Gastroenterology*, Luca Mastracci, MD, Associate Professor, Anatomic Pathology, Department of Surgical Sciences and Integrated Diagnostics (DISC), University of Genova, Ospedale Policlinico San Martino, Largo Rosanna Benzi 10, Genova 16132, Italy. luca.mastracci@unige.it

AIMS AND SCOPE

The primary aim of *World Journal of Gastroenterology* (WJG, *World J Gastroenterol*) is to provide scholars and readers from various fields of gastroenterology and hepatology with a platform to publish high-quality basic and clinical research articles and communicate their research findings online. WJG mainly publishes articles reporting research results and findings obtained in the field of gastroenterology and hepatology and covering a wide range of topics including gastroenterology, hepatology, gastrointestinal endoscopy, gastrointestinal surgery, gastrointestinal oncology, and pediatric gastroenterology.

INDEXING/ABSTRACTING

The WJG is now indexed in Current Contents®/Clinical Medicine, Science Citation Index Expanded (also known as SciSearch®), Journal Citation Reports®, Index Medicus, MEDLINE, PubMed, PubMed Central, and Scopus. The 2021 edition of Journal Citation Report® cites the 2020 impact factor (IF) for WJG as 5.742; Journal Citation Indicator: 0.79; IF without journal self cites: 5.590; 5-year IF: 5.044; Ranking: 28 among 92 journals in gastroenterology and hepatology; and Quartile category: Q2. The WJG's CiteScore for 2020 is 6.9 and Scopus CiteScore rank 2020: Gastroenterology is 19/136.

RESPONSIBLE EDITORS FOR THIS ISSUE

Production Editor: Jia-Hui Li; Production Department Director: Yu-Jie Ma; Editorial Office Director: Ze-Mao Gong.

NAME OF JOURNAL

World Journal of Gastroenterology

ISSN

ISSN 1007-9327 (print) ISSN 2219-2840 (online)

LAUNCH DATE

October 1, 1995

FREQUENCY

Weekly

EDITORS-IN-CHIEF

Andrzej S Tarnawski, Subrata Ghosh

EDITORIAL BOARD MEMBERS

<http://www.wjgnet.com/1007-9327/editorialboard.htm>

PUBLICATION DATE

August 28, 2021

COPYRIGHT

© 2021 Baishideng Publishing Group Inc

INSTRUCTIONS TO AUTHORS

<https://www.wjgnet.com/bpg/gerinfo/204>

GUIDELINES FOR ETHICS DOCUMENTS

<https://www.wjgnet.com/bpg/GerInfo/287>

GUIDELINES FOR NON-NATIVE SPEAKERS OF ENGLISH

<https://www.wjgnet.com/bpg/gerinfo/240>

PUBLICATION ETHICS

<https://www.wjgnet.com/bpg/GerInfo/288>

PUBLICATION MISCONDUCT

<https://www.wjgnet.com/bpg/gerinfo/208>

ARTICLE PROCESSING CHARGE

<https://www.wjgnet.com/bpg/gerinfo/242>

STEPS FOR SUBMITTING MANUSCRIPTS

<https://www.wjgnet.com/bpg/GerInfo/239>

ONLINE SUBMISSION

<https://www.f6publishing.com>



Application of artificial intelligence in preoperative imaging of hepatocellular carcinoma: Current status and future perspectives

Bing Feng, Xiao-Hong Ma, Shuang Wang, Wei Cai, Xia-Bi Liu, Xin-Ming Zhao

ORCID number: Bing Feng 0000-0003-1080-9551; Xiao-Hong Ma 0000-0002-9048-8374; Shuang Wang 0000-0001-9241-2018; Wei Cai 0000-0002-6273-3678; Xia-Bi Liu 0000-0003-1633-0648; Xin-Ming Zhao 0000-0001-7286-771X.

Author contributions: Feng B performed literature review and drafted the manuscript; Cai W contributed to data collection of the study; Wang S, Liu XB, and Zhao XM reviewed the manuscript; Ma XH contributed to conception and design of the study, and critically revised this manuscript; all authors have read and approved the final manuscript.

Supported by CAMS Innovation Fund for Medical Sciences (CIFMS), No. 2016-I2M-1-001; PUMC Youth Fund, No. 2017320010; Chinese Academy of Medical Sciences (CAMS) Research Fund, No. ZZ2016B01; Beijing HopeRun Special Fund of Cancer Foundation of China, No. LC2016B15; and PUMC Postgraduate Education and Teaching Reform Fund, No. 10023201900303.

Conflict-of-interest statement: The authors declare no conflict of interests for this article.

Open-Access: This article is an open-access article that was

Bing Feng, Xiao-Hong Ma, Shuang Wang, Wei Cai, Xin-Ming Zhao, Department of Diagnostic Radiology, National Cancer Center/National Clinical Research Center for Cancer/Cancer Hospital, Chinese Academy of Medical Sciences and Peking Union Medical College, Beijing 100021, China

Xia-Bi Liu, Beijing Laboratory of Intelligent Information Technology, School of Computer Science and Technology, Beijing Institute of Technology, Beijing 100081, China

Corresponding author: Xiao-Hong Ma, MD, Associate Professor, Doctor, Department of Diagnostic Radiology, National Cancer Center/National Clinical Research Center for Cancer/Cancer Hospital, Chinese Academy of Medical Sciences and Peking Union Medical College, No. 17 Panjiayuan Nanli, Chaoyang District, Beijing 100021, China.

maxiaohong@cicams.ac.cn

Abstract

Hepatocellular carcinoma (HCC) is the most common primary malignant liver tumor in China. Preoperative diagnosis of HCC is challenging because of atypical imaging manifestations and the diversity of focal liver lesions. Artificial intelligence (AI), such as machine learning (ML) and deep learning, has recently gained attention for its capability to reveal quantitative information on images. Currently, AI is used throughout the entire radiomics process and plays a critical role in multiple fields of medicine. This review summarizes the applications of AI in various aspects of preoperative imaging of HCC, including segmentation, differential diagnosis, prediction of histo-pathology, early detection of recurrence after curative treatment, and evaluation of treatment response. We also review the limitations of previous studies and discuss future directions for diagnostic imaging of HCC.

Key Words: Hepatocellular carcinoma; Radiomics; Artificial intelligence; Diagnosis; Treatment; Recurrence

©The Author(s) 2021. Published by Baishideng Publishing Group Inc. All rights reserved.

Core Tip: Hepatocellular carcinoma (HCC) threatens human health because of its high morbidity and recurrence rates. Patients with HCC may benefit from early diagnosis,

selected by an in-house editor and fully peer-reviewed by external reviewers. It is distributed in accordance with the Creative Commons Attribution NonCommercial (CC BY-NC 4.0) license, which permits others to distribute, remix, adapt, build upon this work non-commercially, and license their derivative works on different terms, provided the original work is properly cited and the use is non-commercial. See: <http://creativecommons.org/licenses/by-nc/4.0/>

Manuscript source: Invited manuscript

Specialty type: Gastroenterology and hepatology

Country/Territory of origin: China

Peer-review report's scientific quality classification

Grade A (Excellent): 0
Grade B (Very good): B
Grade C (Good): 0
Grade D (Fair): 0
Grade E (Poor): 0

Received: January 28, 2021

Peer-review started: January 28, 2021

First decision: March 29, 2021

Revised: April 15, 2021

Accepted: July 27, 2021

Article in press: July 27, 2021

Published online: August 28, 2021

P-Reviewer: Yang SS

S-Editor: Yan JP

L-Editor: Wang TQ

P-Editor: Liu JH



timely treatment, and appropriate follow-up strategies. In the era of big data, artificial intelligence (AI) provides critical information regarding the diagnosis, treatment, and prognosis of HCC. We herein discuss the role of AI in the following aspects of preoperative imaging: Segmentation, differential diagnosis, prediction of histopathology, early detection of recurrence after curative treatment, and evaluation of treatment response.

Citation: Feng B, Ma XH, Wang S, Cai W, Liu XB, Zhao XM. Application of artificial intelligence in preoperative imaging of hepatocellular carcinoma: Current status and future perspectives. *World J Gastroenterol* 2021; 27(32): 5341-5350

URL: <https://www.wjgnet.com/1007-9327/full/v27/i32/5341.htm>

DOI: <https://dx.doi.org/10.3748/wjg.v27.i32.5341>

INTRODUCTION

Hepatocellular carcinoma (HCC), which most often arises from chronic hepatitis B virus infection, is one of the main causes of cancer-related deaths worldwide, particularly in China[1]. HCC presents with characteristic radiological features and can be diagnosed without biopsy. Imaging is therefore crucial for diagnosis and management. Computed tomography (CT) is the most widely used method for HCC diagnosis, although magnetic resonance imaging (MRI) is the optimal diagnostic modality, owing to its multi-parameter imaging techniques. However, even with the application of dynamic contrast-enhanced MRI (DCE-MRI), the imaging diagnosis of HCC is challenging because of atypical imaging manifestations and liver tumor diversity.

A single clinical image contains a large amount of quantitative information that can provide crucial data for diagnostic and treatment purposes. This information can be processed using innovative methods. Radiomics has recently gained attention for its potential to further analyze images. It allows for the extraction of a large amount of quantitative objective data included in radiological images that could be explored for determining underlying biological processes[2]. The workflow of a radiomics study generally includes five stages: Image acquisition, segmentation, feature extraction, exploratory analysis, and modeling[3] (Figure 1). Every stage is closely related to artificial intelligence (AI). The concept of AI was first advocated in 1955 by McCarthy *et al*[4], who described AI as a computer program that attempts to simulate human cognitive functions. AI can learn and solve problems to improve itself.

Machine learning (ML) is at the core of AI and involves various techniques, such as artificial neural networks, support vector machines (SVM), and random forest (RF). Deep learning (DL) is an important branch of ML, and convolutional neural networks (CNNs) are a type of DL algorithm. The relationships among AI, ML, and DL are described in Figure 2. With technological advances and the use of AI, radiomics has rapidly developed in recent years, and all radiomics techniques have now been utilized in studies within the medical field. This review focuses on the application of AI for HCC imaging, including segmentation, differential diagnosis, prediction of histopathology, early detection of recurrence after curative treatment, and evaluation of treatment response.

SEGMENTATION OF HCC LESIONS

Although HCC segmentation is challenging, it is crucial for various medical imaging analyses. Manual and semi-manual segmentation are time-consuming and susceptible to interobserver variability, which might in turn lead to the biased results. In contrast, automatic segmentation based on an AI algorithm is more repeatable and efficient. CNNs have been successfully applied for the automatic segmentation of hepatic lesions in both CT and MRI. Chlebus *et al*[5] figured out a CNN model for the automatic segmentation of liver tumors on CT; however, with respect to tumor detection, the model performed poorly compared with human performance. Bousabarah *et al*[6] established a DL algorithm to automatically delineate the liver and HCC lesions on MRI. The model was a combination of a deep CNN, RF, and thresholding. The mean dice similarity coefficient between the DL model and manual

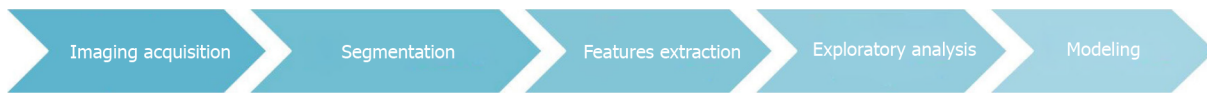


Figure 1 The five stages of a radiomics study where artificial intelligence can play a role.

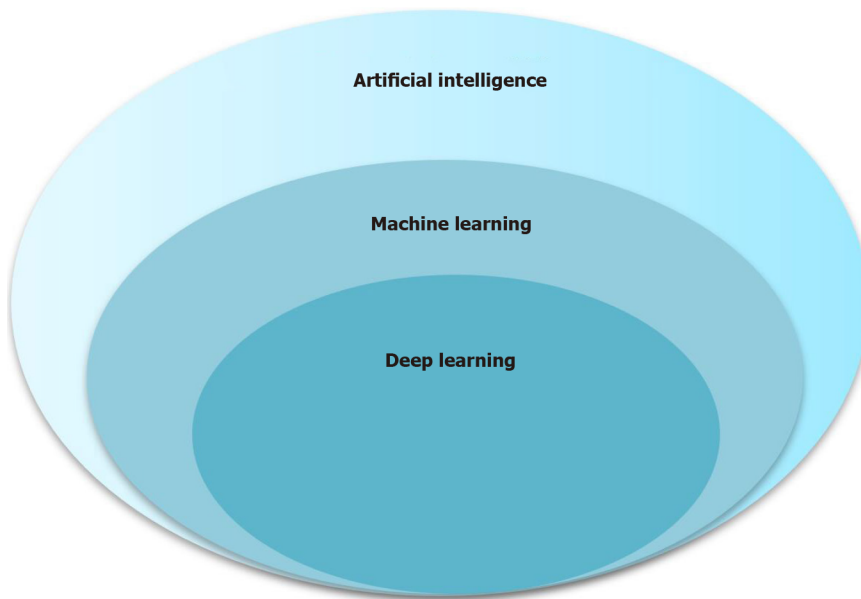


Figure 2 Relationship of artificial intelligence, machine learning, and deep learning.

segmentation was 0.64/0.68 (validation/test) for tumor segmentation and 0.91/0.91 for liver segmentations. Current methods do not achieve a comparably high level of performance in liver imaging for automatic tumor segmentation. This may be due to the heterogeneity of the liver parenchyma and the tumor itself. Larger datasets will be required to improve the accuracy of DL algorithms and will ensure optimal sensitivity and specificity.

DIFFERENTIAL DIAGNOSIS

Imaging-based differential diagnosis improves the accuracy of diagnosis. For HCC, the primary diagnostic modalities are CT and MRI. Radiomics with AI has been gradually applied in clinical research, as it can provide quantitative information, including additional differential characteristics not yet recognized in current radiological diagnosis. This could, in turn, help less-experienced radiologists diagnose focal liver lesions more accurately. Table 1 summarizes the studies on the differential diagnosis of HCC with AI.

CT

Some studies have applied conventional ML algorithms for the differentiation of liver masses. In the non-cirrhotic liver, Nie *et al*[7,8] reported CT-based radiomics nomograms for the preoperative differentiation of HCC from hepatocellular adenoma (HCA) and focal nodular hyperplasia (FNH). It showed good discrimination capability, with an area under the curve (AUC) of 0.96/0.94 and 0.979/0.917 (training/validation) for differentiating HCC from HCA and FNH, respectively. In patients with cirrhosis, ML techniques could classify indeterminate liver nodules as HCC or non-HCC based on triphasic CT scans, with an AUC of 0.70/0.66 (training/validation)[9]. Ponnopratt *et al*[10] developed an ML method to differentiate between HCC and intrahepatic cholangiocarcinoma (ICC), the two most common malignant liver tumors, based on multi-phase CT. They reported an 88% accuracy in HCC-ICC classification. DL with CNN for the differential diagnosis of liver lesions also showed relatively high diagnostic capability, reaching an AUC of 0.86-0.99[11-13].

Table 1 Summary of studies on differential diagnosis of hepatocellular carcinoma

Ref.	Aim of the study	Modality	Patients	Method	AUC of the final model
Nie <i>et al</i> [7]	Differentiation between HCC and HCA	CT	131	ML	T: 0.96, V: 0.94
Nie <i>et al</i> [8]	Differentiation between HCC and FNH	CT	156	ML	T: 0.979, V: 0.917
Mokrane <i>et al</i> [9]	Differentiation between HCC and non-HCC nodules	CT	178	ML	T: 0.70, V: 0.66
Ponnoprat <i>et al</i> [10]	Differentiation between HCC and ICC	CT	257	ML	NA
Shi <i>et al</i> [11]	Differentiation of HCC from other FLLs	CT	342	DL	0.925
Yasaka <i>et al</i> [12]	Liver mass classification	CT	560	DL	0.92
Cao <i>et al</i> [13]	FLL classification	CT	375	DL	V: 0.88-0.99
Jiang <i>et al</i> [14]	Comparing the diagnostic accuracies of EASL (v2018), LI-RADS criteria, and radiomics models for HCC	MRI	211	ML	T: 0.861, V: 0.810
Zhen <i>et al</i> [15]	Classification of liver tumors	MRI	1411	DL	0.963-0.998
Liu <i>et al</i> [16]	Differentiation of cHCC-CC from CC and HCC	MRI	85	ML	0.77
Huang <i>et al</i> [17]	Diagnosis of DPHCC	MRI	100	ML	0.784
Jian <i>et al</i> [18]	Characterization of HCC	MRI	112	DL	NA
Wu <i>et al</i> [19]	Classification of HCC and hepatic hemangioma	MRI	369	ML	T: 0.86, V: 0.89

T: Training cohort; V: Validation cohort; NA: Not available; AUC: The area under the receiver operating characteristic curve; ML: Machine learning; DL: Deep learning; HCC: Hepatocellular carcinoma; HCA: Hepatocellular adenoma; FNH: Focal nodular hyperplasia; ICC: Intrahepatic cholangiocarcinoma; cHCC-CC: Combined hepatocellular cholangiocarcinoma; CC: Cholangiocarcinoma; DPHCC: Dual-phenotype hepatocellular carcinoma; FLL: Focal liver lesion.

MRI

MRI can provide more comprehensive information for differential diagnosis than CT because of its multi-parameter techniques and various tissue contrast mechanisms. Accurate diagnosis of HCC remains a challenge because of liver tumor diversity and relies on the experience of radiologists. Jiang *et al*[14] established a radiomics signature from multi-sequence MRI using the least absolute shrinkage and selection operator (LASSO) model and multivariate logistic regression analysis. The AUC of the radiomics signature was 0.810. It showed a comparable accuracy with the LI-RADS (0.841) and EASL criteria (0.811) for HCC diagnosis. Zhen *et al*[15] used CNNs to develop a DL model to classify liver tumors based on MR images. The CNN model combined with clinical data performed well in identifying HCC (AUC, 0.985; 95%CI: 0.960-1.000), metastatic tumors (AUC, 0.998; 95%CI: 0.989-1.000), and other primary malignancies (AUC, 0.963; 95%CI: 0.896-1.000). Some researchers have also applied ML algorithms to the differential diagnosis of primary liver cancer subtypes. Liu *et al*[16] reported an ML analysis of MRI radiomics features for the differentiation of combined hepatocellular cholangiocarcinoma (cHCC-CC) from HCC and cholangiocarcinoma. The model showed acceptable performance, with an AUC of 0.77. Huang *et al*[17] created a radiomics signature from Gd-EOB-DTPA-enhanced MRI for the diagnosis of dual-phenotype HCC (DPHCC). They used LASSO and four classifiers: Multi-layer perceptron, SVM, logistic regression, and K-nearest neighbor. The combination of different phases and classifiers achieved the best performance in the preoperative diagnosis of DPHCC. ML and DL algorithms can also be used in non-contrast MRI to increase the diagnostic accuracy of HCC[18,19]. This is beneficial for patients who cannot receive contrast injections.

CT- or MRI-based ML and DL models have demonstrated promising predictive performance and have reached a high level of accuracy similar to that of experienced radiologists. Accurate preoperative diagnosis of focal liver lesions can help clinicians make proper decisions, optimize patient management, and improve patient prognosis.

PREOPERATIVE PREDICTION OF HISTOPATHOLOGY

Grade

Histological grade represents the biological behavior and aggressiveness of tumors. The high recurrence rate of HCC is associated with its pathological grade. The pathological grade of HCC determined using imaging may provide valuable prognostic information. Mao *et al*[20] developed an ML model based on contrast-enhanced CT for preoperative prediction of the pathological grade of HCC. The model achieved an AUC of 0.8014 when combined with clinical factors. The radiomics signature based on T1WI, T2WI, and DCE-MRI was also found to be significantly related to the histopathological grade of HCC[21,22]. Yang *et al*[22] proposed a DL model with a multichannel fusion three-dimensional CNN (3D-CNN) based on DCE-MR to differentiate among pathological grades. The model reached an average accuracy of 0.7396 ± 0.0104 . Thus, further improvements are needed to achieve better diagnostic performance of radiomics models for histological grade.

Microvascular invasion

In addition to predicting the HCC grade, the prediction of microvascular invasion (MVI) has also become a common topic of study. MVI status is a crucial factor influencing treatment selection and follow-up planning; thus, it must be determined preoperatively[23,24]. Some studies have tried to predict MVI before surgery using radiological images and clinical factors. They found that MVI was closely related to several factors. Some studies used LASSO to construct radiomics signatures from CT and MRI and developed models with various conventional ML algorithms for the preoperative prediction of MVI[25-27]. The results showed favorable predictive accuracy for MVI status in HCC patients, especially when combined with clinical factors[28,29]. Jiang *et al*[30] figured out a CT-based model using eXtreme Gradient Boosting and DL algorithm with 3D-CNN to predict MVI preoperatively. The 3D-CNN model demonstrated high diagnostic capability, with an AUC of 0.980/0.906 (training/validation). However, different dimensionality reduction and modeling methods affect the diagnostic performance of the final models. Ni *et al*[31] retrospectively analyzed 206 HCC cases to explore the best radiomic-based diagnostic model. The LASSO + GBDT method showed better performance than the other methods, when the threshold probability was more than 0.22.

MVI usually occurs in the peritumoral region, but it is unclear whether including the features of the peritumoral region could improve predictive capability. Nebbia *et al*[32] developed an ML model for preoperative prediction of MVI status using multiparametric MRI. They found that radiomics features extracted from the tumor region had good diagnostic performance, with an AUC of 0.867. Radiomics features from the peritumoral region also showed an association with MVI; however, the AUC was slightly lower than that of intratumoral radiomics features. Although peritumoral enhancement pattern is reported to be a good predictor of MVI status[33], the usefulness of the features extracted from peritumoral regions for predicting MVI status needs further evaluation in larger populations.

Molecular profiling

HCC originates from hepatocytes and/or hepatic progenitor cells and can express various molecular phenotypes[34]. As such, prognosis varies even among patients with the same pathological grade. Molecular profiling is an important modality that may reflect the biological behavior and invasiveness of tumors. Several studies have used ML methods to identify the molecular phenotypes of HCC preoperatively. CK19 is a biliary-specific marker, and CK19 positivity is associated with a poor postoperative prognosis in HCC[35,36]. In a recent study, the radiomics signature derived from gadoxetic acid-enhanced MRI was used to predict CK19 status in HCC. The final model combined the radiomics signature and clinical factors and achieved a sensitivity of 0.818/0.769 (training/validation) and specificity of 0.974/0.818 (training/validation)[37].

Glypican 3 (GPC3), a type of heparan sulfate proteoglycan, is located on the cell surface. Previous studies have found that GPC3 is closely associated with postoperative metastasis and recurrence in patients with HCC[38]. Furthermore, GPC3 is considered a potential immunotherapeutic target for HCC therapy, especially in patients with unresectable HCC. Gu *et al*[39] constructed a radiomics signature from MRI and achieved good predictive efficacy, with an AUC of 0.879/0.871 (training/validation). Combining the radiomics signature with α -fetoprotein levels further improved the predictive performance, with an AUC of 0.926/0.914 (train-

ing/validation). Another molecular biomarker of HCC is the Ki-67 index. A high Ki-67 index is related to early recurrence and poor prognosis, thus making it a potential indicator of tumor aggressiveness. Recent studies have reported that the Ki-67 status can be predicted preoperatively using CT and MRI[40,41]. Prediction of molecular phenotypes *via* preoperative imaging can aid in the selection of individualized therapeutic strategies.

PREDICTION OF TREATMENT RESPONSE AND EARLY RECURRENCE AFTER CURATIVE TREATMENT

Individualized medical care depends on accurate risk stratification systems. These systems help select the proper treatment and evaluate treatment response. Pretreatment imaging acts as an important role in predicting the effects of treatment, helping clinicians choose the best individualized treatment strategy for patients.

Early recurrence, that is, recurrence within 1-2 years after resection or ablation, is a strong influencing factor of poor prognosis in patients with HCC. A radiomics nomogram derived from preoperative CT and MRI was established to predict early recurrence after surgery or curative ablation in HCC patients[42,43]. The radiomics nomogram comprising both the radiomics score and clinicoradiological risk factors demonstrated good performance, with an AUC of 0.785-0.844[44,45]. Prediction of early recurrence is critical for planning follow-up surveillance strategies and determining the necessity of further interventions after curative treatment. Wang *et al* [46] proposed a DL-based radiomics approach from multi-phase CT images to predict the early recurrence of HCC; it achieved an AUC of 0.825. Unfortunately, image-based radiomics models for early recurrent HCC have poor reproducibility among medical centers[47], limiting their application in clinical practice.

GUIDANCE OF TREATMENT SELECTION

Trans-arterial chemoembolization

Patients with unresectable HCC can undergo trans-arterial chemoembolization (TACE), local radiofrequency ablation, and systemic treatment with sorafenib. ML or DL models based on pretreatment CT or MRI have been recently considered as potential tools for predicting treatment response to TACE for HCC[48,49]. Morshid *et al*[50] used pretreatment quantitative CT image features and clinical factors to develop an ML model to predict treatment response to TACE; the model had an accuracy of 74.2%. Abajian *et al*[51] used MR imaging and clinical data to create an AI model for the prediction of TACE treatment response; the model had an overall accuracy of 78%. Similar results were obtained in other studies, confirming the usefulness of radiomics features extracted from pretreatment CT or MRI for the prediction of tumor response to TACE[52-54]. Peng *et al*[55] described a DL model of a residual CNN to predict the treatment response to TACE for HCC. The final model had a high accuracy in predicting four different therapy response types (complete response, partial response, stable disease, and progressive disease). Thus, it could help clinicians identify patients who will optimally benefit from TACE.

Immunotherapy

Immunotherapy has been shown to be a promising treatment for HCC; however, treatment response to immunotherapy remains low[56-58]. Therefore, it is necessary for clinicians to identify which patients will respond to immunotherapy. Treatment response to immunotherapy is highly dependent on the immune status of the tumor [59]. Tumor immunoprofiling is thus important in predicting its effect. A contrast-enhanced CT-based Rad score developed using the ML algorithm showed high predictive power for CD8⁺ T-cell infiltration, which is associated with the immunotherapy response[60]. Hectors *et al*[61] reported that MRI radiomics features were correlated with various immunohistochemical cell markers and the expression of certain immunotherapy targets. Chen *et al*[62] used clinical data and intratumoral and peritumoral radiomics features to build an ML model from Gd-EOB-DTPA-enhanced MRI. The model showed excellent performance in predicting the immunoscore, with an AUC of 0.926 (95%CI: 0.884-0.967). Collectively, these findings indicated that radiomics features extracted by ML methods might serve as noninvasive predictors of the immune characteristics of HCC and assist physicians in identifying patients who

will benefit from immunotherapy.

LIMITATIONS

The application of AI in different fields of medical research has demonstrated promising results; however, there are some limitations. First, nearly all the research was retrospective and included a relatively small sample size. Therefore, the performance of these predictive models should be validated in larger, multicenter, and prospective studies. Second, the predictive models had limited reproducibility for application in clinical practice, and image heterogeneity might be a significant influencing factor. Third, the AI calculation algorithm requires specialized software packages, leading to increased medical costs. The workflow includes imaging acquisition, segmentation, feature extraction, exploratory analysis, and modeling, making it complex and diverse, further limiting its clinical application.

While AI and radiomics have proven useful in various aspects of HCC, the underlying mechanisms have not been clearly stated, such as pathological correlation and relationship between radiomics and genomics. More research is needed to explore the relationships among imaging, pathophysiology, and prognosis.

CONCLUSION

AI has been applied in many studies on preoperative imaging of HCC. It can extract a large amount of quantitative information from images and reflect pathophysiological processes. Diagnostic and predictive models using AI algorithms have demonstrated promising results in the fields of segmentation, differential diagnosis, prediction of histology, and guidance for treatment selection. However, considering the limitations and complexity of AI, additional research is needed before it can be widely used in clinical practice. Some specific issues, such as reproducibility, heterogeneity of imaging acquisition, and lack of external multicenter validation, need to be considered. Further research will be crucial in improving the accuracy and reproducibility of diagnostic and predictive models, enabling their application for individualized treatment in patients with HCC.

REFERENCES

- 1 Villanueva A. Hepatocellular Carcinoma. *N Engl J Med* 2019; **380**: 1450-1462 [PMID: 30970190 DOI: 10.1056/NEJMra1713263]
- 2 Gillies RJ, Kinahan PE, Hricak H. Radiomics: Images Are More than Pictures, They Are Data. *Radiology* 2016; **278**: 563-577 [PMID: 26579733 DOI: 10.1148/radiol.2015151169]
- 3 Lewis S, Hectors S, Taouli B. Radiomics of hepatocellular carcinoma. *Abdom Radiol (NY)* 2021; **46**: 111-123 [PMID: 31925492 DOI: 10.1007/s00261-019-02378-5]
- 4 McCarthy J, Minsky ML, Rochester N, Shannon CE. A Proposal for the Dartmouth Summer Research Project on Artificial Intelligence. *AI Mag* 1955; **27**: 12-14
- 5 Chlebus G, Schenk A, Moltz JH, van Ginneken B, Hahn HK, Meine H. Automatic liver tumor segmentation in CT with fully convolutional neural networks and object-based postprocessing. *Sci Rep* 2018; **8**: 15497 [PMID: 30341319 DOI: 10.1038/s41598-018-33860-7]
- 6 Bousabarah K, Letzen B, Tefera J, Savic L, Schobert I, Schlachter T, Staib LH, Kocher M, Chapiro J, Lin M. Automated detection and delineation of hepatocellular carcinoma on multiphasic contrast-enhanced MRI using deep learning. *Abdom Radiol (NY)* 2021; **46**: 216-225 [PMID: 32500237 DOI: 10.1007/s00261-020-02604-5]
- 7 Nie P, Wang N, Pang J, Yang G, Duan S, Chen J, Xu W. CT-Based Radiomics Nomogram: A Potential Tool for Differentiating Hepatocellular Adenoma From Hepatocellular Carcinoma in the Noncirrhotic Liver. *Acad Radiol* 2021; **28**: 799-807 [PMID: 32386828 DOI: 10.1016/j.acra.2020.04.027]
- 8 Nie P, Yang G, Guo J, Chen J, Li X, Ji Q, Wu J, Cui J, Xu W. A CT-based radiomics nomogram for differentiation of focal nodular hyperplasia from hepatocellular carcinoma in the non-cirrhotic liver. *Cancer Imaging* 2020; **20**: 20 [PMID: 32093786 DOI: 10.1186/s40644-020-00297-z]
- 9 Mokrane FZ, Lu L, Vavasseur A, Otal P, Peron JM, Luk L, Yang H, Ammari S, Saenger Y, Rousseau H, Zhao B, Schwartz LH, Derle L. Radiomics machine-learning signature for diagnosis of hepatocellular carcinoma in cirrhotic patients with indeterminate liver nodules. *Eur Radiol* 2020; **30**: 558-570 [PMID: 31444598 DOI: 10.1007/s00330-019-06347-w]
- 10 Ponnoprat D, Inkeaw P, Chaijaruwanich J, Traisathit P, Sripan P, Inmutto N, Na Chiangmai W,

- Pongnikorn D, Chitapanarux I. Classification of hepatocellular carcinoma and intrahepatic cholangiocarcinoma based on multi-phase CT scans. *Med Biol Eng Comput* 2020; **58**: 2497-2515 [PMID: 32794015 DOI: 10.1007/s11517-020-02229-2]
- 11 Shi W, Kuang S, Cao S, Hu B, Xie S, Chen S, Chen Y, Gao D, Zhu Y, Zhang H, Liu H, Ye M, Sirlin CB, Wang J. Deep learning assisted differentiation of hepatocellular carcinoma from focal liver lesions: choice of four-phase and three-phase CT imaging protocol. *Abdom Radiol (NY)* 2020; **45**: 2688-2697 [PMID: 32232524 DOI: 10.1007/s00261-020-02485-8]
 - 12 Yasaka K, Akai H, Abe O, Kiryu S. Deep Learning with Convolutional Neural Network for Differentiation of Liver Masses at Dynamic Contrast-enhanced CT: A Preliminary Study. *Radiology* 2018; **286**: 887-896 [PMID: 29059036 DOI: 10.1148/radiol.2017170706]
 - 13 Cao SE, Zhang LQ, Kuang SC, Shi WQ, Hu B, Xie SD, Chen YN, Liu H, Chen SM, Jiang T, Ye M, Zhang HX, Wang J. Multiphase convolutional dense network for the classification of focal liver lesions on dynamic contrast-enhanced computed tomography. *World J Gastroenterol* 2020; **26**: 3660-3672 [PMID: 32742134 DOI: 10.3748/wjg.v26.i25.3660]
 - 14 Jiang H, Liu X, Chen J, Wei Y, Lee JM, Cao L, Wu Y, Duan T, Li X, Ma L, Song B. Man or machine? *Cancer Imaging* 2019; **19**: 84 [PMID: 31806050 DOI: 10.1186/s40644-019-0266-9]
 - 15 Zhen SH, Cheng M, Tao YB, Wang YF, Juengpanich S, Jiang ZY, Jiang YK, Yan YY, Lu W, Lue JM, Qian JH, Wu ZY, Sun JH, Lin H, Cai XJ. Deep Learning for Accurate Diagnosis of Liver Tumor Based on Magnetic Resonance Imaging and Clinical Data. *Front Oncol* 2020; **10**: 680 [PMID: 32547939 DOI: 10.3389/fonc.2020.00680]
 - 16 Liu X, Khalvati F, Namdar K, Fischer S, Lewis S, Taouli B, Haider MA, Jhaveri KS. Can machine learning radiomics provide pre-operative differentiation of combined hepatocellular cholangiocarcinoma from hepatocellular carcinoma and cholangiocarcinoma to inform optimal treatment planning? *Eur Radiol* 2021; **31**: 244-255 [PMID: 32749585 DOI: 10.1007/s00330-020-07119-7]
 - 17 Huang X, Long L, Wei J, Li Y, Xia Y, Zuo P, Chai X. Radiomics for diagnosis of dual-phenotype hepatocellular carcinoma using Gd-EOB-DTPA-enhanced MRI and patient prognosis. *J Cancer Res Clin Oncol* 2019; **145**: 2995-3003 [PMID: 31664520 DOI: 10.1007/s00432-019-03062-3]
 - 18 Jian W, Ju H, Cen X, Cui M, Zhang H, Zhang L, Wang G, Gu L, Zhou W. Improving the malignancy characterization of hepatocellular carcinoma using deeply supervised cross modal transfer learning for non-enhanced MR. *Annu Int Conf IEEE Eng Med Biol Soc* 2019; **2019**: 853-856 [PMID: 31946029 DOI: 10.1109/EMBC.2019.8857467]
 - 19 Wu J, Liu A, Cui J, Chen A, Song Q, Xie L. Radiomics-based classification of hepatocellular carcinoma and hepatic haemangioma on precontrast magnetic resonance images. *BMC Med Imaging* 2019; **19**: 23 [PMID: 30866850 DOI: 10.1186/s12880-019-0321-9]
 - 20 Mao B, Zhang L, Ning P, Ding F, Wu F, Lu G, Geng Y, Ma J. Preoperative prediction for pathological grade of hepatocellular carcinoma via machine learning-based radiomics. *Eur Radiol* 2020; **30**: 6924-6932 [PMID: 32696256 DOI: 10.1007/s00330-020-07056-5]
 - 21 Wu M, Tan H, Gao F, Hai J, Ning P, Chen J, Zhu S, Wang M, Dou S, Shi D. Predicting the grade of hepatocellular carcinoma based on non-contrast-enhanced MRI radiomics signature. *Eur Radiol* 2019; **29**: 2802-2811 [PMID: 30406313 DOI: 10.1007/s00330-018-5787-2]
 - 22 Yang DW, Jia XB, Xiao YJ, Wang XP, Wang ZC, Yang ZH. Noninvasive Evaluation of the Pathologic Grade of Hepatocellular Carcinoma Using MCF-3DCNN: A Pilot Study. *Biomed Res Int* 2019; **2019**: 9783106 [PMID: 31183380 DOI: 10.1155/2019/9783106]
 - 23 Peng Z, Chen S, Xiao H, Wang Y, Li J, Mei J, Chen Z, Zhou Q, Feng S, Chen M, Qian G, Peng S, Kuang M. Microvascular Invasion as a Predictor of Response to Treatment with Sorafenib and Transarterial Chemoembolization for Recurrent Intermediate-Stage Hepatocellular Carcinoma. *Radiology* 2019; **292**: 237-247 [PMID: 31135299 DOI: 10.1148/radiol.2019181818]
 - 24 Tang A. Using MRI to Assess Microvascular Invasion in Hepatocellular Carcinoma. *Radiology* 2020; **297**: 582-583 [PMID: 32996872 DOI: 10.1148/radiol.2020203376]
 - 25 Zhang X, Ruan S, Xiao W, Shao J, Tian W, Liu W, Zhang Z, Wan D, Huang J, Huang Q, Yang Y, Yang H, Ding Y, Liang W, Bai X, Liang T. Contrast-enhanced CT radiomics for preoperative evaluation of microvascular invasion in hepatocellular carcinoma: A two-center study. *Clin Transl Med* 2020; **10**: e111 [PMID: 32567245 DOI: 10.1002/ctm2.111]
 - 26 Peng J, Zhang J, Zhang Q, Xu Y, Zhou J, Liu L. A radiomics nomogram for preoperative prediction of microvascular invasion risk in hepatitis B virus-related hepatocellular carcinoma. *Diagn Interv Radiol* 2018; **24**: 121-127 [PMID: 29770763 DOI: 10.5152/dir.2018.17467]
 - 27 Ma X, Wei J, Gu D, Zhu Y, Feng B, Liang M, Wang S, Zhao X, Tian J. Preoperative radiomics nomogram for microvascular invasion prediction in hepatocellular carcinoma using contrast-enhanced CT. *Eur Radiol* 2019; **29**: 3595-3605 [PMID: 30770969 DOI: 10.1007/s00330-018-5985-y]
 - 28 Yang L, Gu D, Wei J, Yang C, Rao S, Wang W, Chen C, Ding Y, Tian J, Zeng M. A Radiomics Nomogram for Preoperative Prediction of Microvascular Invasion in Hepatocellular Carcinoma. *Liver Cancer* 2019; **8**: 373-386 [PMID: 31768346 DOI: 10.1159/000494099]
 - 29 Zhang R, Xu L, Wen X, Zhang J, Yang P, Zhang L, Xue X, Wang X, Huang Q, Guo C, Shi Y, Niu T, Chen F. A nomogram based on bi-regional radiomics features from multimodal magnetic resonance imaging for preoperative prediction of microvascular invasion in hepatocellular carcinoma. *Quant Imaging Med Surg* 2019; **9**: 1503-1515 [PMID: 31667137 DOI: 10.21037/qims.2019.09.07]
 - 30 Jiang YQ, Cao SE, Cao S, Chen JN, Wang GY, Shi WQ, Deng YN, Cheng N, Ma K, Zeng KN, Yan XJ, Yang HZ, Huan WJ, Tang WM, Zheng Y, Shao CK, Wang J, Yang Y, Chen GH. Preoperative

- identification of microvascular invasion in hepatocellular carcinoma by XGBoost and deep learning. *J Cancer Res Clin Oncol* 2021; **147**: 821-833 [PMID: 32852634 DOI: 10.1007/s00432-020-03366-9]
- 31 Ni M, Zhou X, Lv Q, Li Z, Gao Y, Tan Y, Liu J, Liu F, Yu H, Jiao L, Wang G. Radiomics models for diagnosing microvascular invasion in hepatocellular carcinoma: which model is the best model? *Cancer Imaging* 2019; **19**: 60 [PMID: 31455432 DOI: 10.1186/s40644-019-0249-x]
 - 32 Nebbia G, Zhang Q, Arefan D, Zhao X, Wu S. Pre-operative Microvascular Invasion Prediction Using Multi-parametric Liver MRI Radiomics. *J Digit Imaging* 2020; **33**: 1376-1386 [PMID: 32495126 DOI: 10.1007/s10278-020-00353-x]
 - 33 Ahn SJ, Kim JH, Park SJ, Kim ST, Han JK. Hepatocellular carcinoma: preoperative gadoteric acid-enhanced MR imaging can predict early recurrence after curative resection using image features and texture analysis. *Abdom Radiol (NY)* 2019; **44**: 539-548 [PMID: 30229421 DOI: 10.1007/s00261-018-1768-9]
 - 34 Mishra L, Banker T, Murray J, Byers S, Thenappan A, He AR, Shetty K, Johnson L, Reddy EP. Liver stem cells and hepatocellular carcinoma. *Hepatology* 2009; **49**: 318-329 [PMID: 19111019 DOI: 10.1002/hep.22704]
 - 35 Lee SH, Lee JS, Na GH, You YK, Kim DG. Immunohistochemical markers for hepatocellular carcinoma prognosis after liver resection and liver transplantation. *Clin Transplant* 2017; **31** [PMID: 27653235 DOI: 10.1111/ctr.12852]
 - 36 Roncalli M, Park YN, Di Tommaso L. Histopathological classification of hepatocellular carcinoma. *Dig Liver Dis* 2010; **42** Suppl 3: S228-S234 [PMID: 20547308 DOI: 10.1016/S1590-8658(10)60510-5]
 - 37 Wang W, Gu D, Wei J, Ding Y, Yang L, Zhu K, Luo R, Rao SX, Tian J, Zeng M. A radiomics-based biomarker for cytokeratin 19 status of hepatocellular carcinoma with gadoteric acid-enhanced MRI. *Eur Radiol* 2020; **30**: 3004-3014 [PMID: 32002645 DOI: 10.1007/s00330-019-06585-y]
 - 38 Ning S, Bin C, Na H, Peng S, Yi D, Xiang-hua Y, Fang-yin Z, Da-yong Z, Rong-cheng L. Glypican-3, a novel prognostic marker of hepatocellular cancer, is related with postoperative metastasis and recurrence in hepatocellular cancer patients. *Mol Biol Rep* 2012; **39**: 351-357 [PMID: 21655958 DOI: 10.1007/s11033-011-0745-y]
 - 39 Gu D, Xie Y, Wei J, Li W, Ye Z, Zhu Z, Tian J, Li X. MRI-Based Radiomics Signature: A Potential Biomarker for Identifying Glypican 3-Positive Hepatocellular Carcinoma. *J Magn Reson Imaging* 2020; **52**: 1679-1687 [PMID: 32491239 DOI: 10.1002/jmri.27199]
 - 40 Ye Z, Jiang H, Chen J, Liu X, Wei Y, Xia C, Duan T, Cao L, Zhang Z, Song B. Texture analysis on gadoteric acid enhanced-MRI for predicting Ki-67 status in hepatocellular carcinoma: A prospective study. *Chin J Cancer Res* 2019; **31**: 806-817 [PMID: 31814684 DOI: 10.21147/j.issn.1000-9604.2019.05.10]
 - 41 Wu H, Han X, Wang Z, Mo L, Liu W, Guo Y, Wei X, Jiang X. Prediction of the Ki-67 marker index in hepatocellular carcinoma based on CT radiomics features. *Phys Med Biol* 2020; **65**: 235048 [PMID: 32756021 DOI: 10.1088/1361-6560/abac9c]
 - 42 Zhou Y, He L, Huang Y, Chen S, Wu P, Ye W, Liu Z, Liang C. CT-based radiomics signature: a potential biomarker for preoperative prediction of early recurrence in hepatocellular carcinoma. *Abdom Radiol (NY)* 2017; **42**: 1695-1704 [PMID: 28180924 DOI: 10.1007/s00261-017-1072-0]
 - 43 Yuan C, Wang Z, Gu D, Tian J, Zhao P, Wei J, Yang X, Hao X, Dong D, He N, Sun Y, Gao W, Feng J. Prediction early recurrence of hepatocellular carcinoma eligible for curative ablation using a Radiomics nomogram. *Cancer Imaging* 2019; **19**: 21 [PMID: 31027510 DOI: 10.1186/s40644-019-0207-7]
 - 44 Zhu HB, Zheng ZY, Zhao H, Zhang J, Zhu H, Li YH, Dong ZY, Xiao LS, Kuang JJ, Zhang XL, Liu L. Radiomics-based nomogram using CT imaging for noninvasive preoperative prediction of early recurrence in patients with hepatocellular carcinoma. *Diagn Interv Radiol* 2020; **26**: 411-419 [PMID: 32490826 DOI: 10.5152/dir.2020.19623]
 - 45 Zhang Z, Jiang H, Chen J, Wei Y, Cao L, Ye Z, Li X, Ma L, Song B. Hepatocellular carcinoma: radiomics nomogram on gadoteric acid-enhanced MR imaging for early postoperative recurrence prediction. *Cancer Imaging* 2019; **19**: 22 [PMID: 31088553 DOI: 10.1186/s40644-019-0209-5]
 - 46 Wang W, Chen Q, Iwamoto Y, Han X, Zhang Q, Hu H, Lin L, Chen YW. Deep Learning-Based Radiomics Models for Early Recurrence Prediction of Hepatocellular Carcinoma with Multi-phase CT Images and Clinical Data. *Annu Int Conf IEEE Eng Med Biol Soc* 2019; **2019**: 4881-4884 [PMID: 31946954 DOI: 10.1109/EMBC.2019.8856356]
 - 47 Hu HT, Shan QY, Chen SL, Li B, Feng ST, Xu EJ, Li X, Long JY, Xie XY, Lu MD, Kuang M, Shen JX, Wang W. CT-based radiomics for preoperative prediction of early recurrent hepatocellular carcinoma: technical reproducibility of acquisition and scanners. *Radiol Med* 2020; **125**: 697-705 [PMID: 32200455 DOI: 10.1007/s11547-020-01174-2]
 - 48 Kim J, Choi SJ, Lee SH, Lee HY, Park H. Predicting Survival Using Pretreatment CT for Patients With Hepatocellular Carcinoma Treated With Transarterial Chemoembolization: Comparison of Models Using Radiomics. *AJR Am J Roentgenol* 2018; **211**: 1026-1034 [PMID: 30240304 DOI: 10.2214/AJR.18.19507]
 - 49 Liu QP, Xu X, Zhu FP, Zhang YD, Liu XS. Prediction of prognostic risk factors in hepatocellular carcinoma with transarterial chemoembolization using multi-modal multi-task deep learning. *EClinicalMedicine* 2020; **23**: 100379 [PMID: 32548574 DOI: 10.1016/j.eclinm.2020.100379]
 - 50 Morshid A, Elsayes KM, Khalaf AM, Elmohr MM, Yu J, Kaseb AO, Hassan M, Mahvash A, Wang Z, Hazle JD, Fuentes D. A machine learning model to predict hepatocellular carcinoma response to

- transcatheter arterial chemoembolization. *Radiol Artif Intell* 2019; **1** [PMID: 31858078 DOI: 10.1148/ryai.2019180021]
- 51 **Abajian A**, Murali N, Savic LJ, Laage-Gaupp FM, Nezami N, Duncan JS, Schlachter T, Lin M, Geschwind JF, Chapiro J. Predicting Treatment Response to Intra-arterial Therapies for Hepatocellular Carcinoma with the Use of Supervised Machine Learning-An Artificial Intelligence Concept. *J Vasc Interv Radiol* 2018; **29**: 850-857.e1 [PMID: 29548875 DOI: 10.1016/j.jvir.2018.01.769]
 - 52 **Song W**, Yu X, Guo D, Liu H, Tang Z, Liu X, Zhou J, Zhang H, Liu Y. MRI-Based Radiomics: Associations With the Recurrence-Free Survival of Patients With Hepatocellular Carcinoma Treated With Conventional Transcatheter Arterial Chemoembolization. *J Magn Reson Imaging* 2020; **52**: 461-473 [PMID: 31675174 DOI: 10.1002/jmri.26977]
 - 53 **Abajian A**, Murali N, Savic LJ, Laage-Gaupp FM, Nezami N, Duncan JS, Schlachter T, Lin M, Geschwind JF, Chapiro J. Predicting Treatment Response to Image-Guided Therapies Using Machine Learning: An Example for Trans-Arterial Treatment of Hepatocellular Carcinoma. *J Vis Exp* 2018 [PMID: 30371657 DOI: 10.3791/58382]
 - 54 **Meng XP**, Wang YC, Ju S, Lu CQ, Zhong BY, Ni CF, Zhang Q, Yu Q, Xu J, Ji J, Zhang XM, Tang TY, Yang G, Zhao Z. Radiomics Analysis on Multiphase Contrast-Enhanced CT: A Survival Prediction Tool in Patients With Hepatocellular Carcinoma Undergoing Transarterial Chemoembolization. *Front Oncol* 2020; **10**: 1196 [PMID: 32850345 DOI: 10.3389/fonc.2020.01196]
 - 55 **Peng J**, Kang S, Ning Z, Deng H, Shen J, Xu Y, Zhang J, Zhao W, Li X, Gong W, Huang J, Liu L. Residual convolutional neural network for predicting response of transarterial chemoembolization in hepatocellular carcinoma from CT imaging. *Eur Radiol* 2020; **30**: 413-424 [PMID: 31332558 DOI: 10.1007/s00330-019-06318-1]
 - 56 **Yau T**, Kang YK, Kim TY, El-Khoueiry AB, Santoro A, Sangro B, Melero I, Kudo M, Hou MM, Matilla A, Tovoli F, Knox JJ, Ruth He A, El-Rayes BF, Acosta-Rivera M, Lim HY, Neely J, Shen Y, Wisniewski T, Anderson J, Hsu C. Efficacy and Safety of Nivolumab Plus Ipilimumab in Patients With Advanced Hepatocellular Carcinoma Previously Treated With Sorafenib: The CheckMate 040 Randomized Clinical Trial. *JAMA Oncol* 2020; **6**: e204564 [PMID: 33001135 DOI: 10.1001/jamaoncol.2020.4564]
 - 57 **Lee MS**, Ryoo BY, Hsu CH, Numata K, Stein S, Verret W, Hack SP, Spahn J, Liu B, Abdullah H, Wang Y, He AR, Lee KH; GO30140 investigators. Atezolizumab with or without bevacizumab in unresectable hepatocellular carcinoma (GO30140): an open-label, multicentre, phase 1b study. *Lancet Oncol* 2020; **21**: 808-820 [PMID: 32502443 DOI: 10.1016/S1470-2045(20)30156-X]
 - 58 **Finn RS**, Qin S, Ikeda M, Galle PR, Ducreux M, Kim TY, Kudo M, Breder V, Merle P, Kaseb AO, Li D, Verret W, Xu DZ, Hernandez S, Liu J, Huang C, Mulla S, Wang Y, Lim HY, Zhu AX, Cheng AL; IMbrave150 Investigators. Atezolizumab plus Bevacizumab in Unresectable Hepatocellular Carcinoma. *N Engl J Med* 2020; **382**: 1894-1905 [PMID: 32402160 DOI: 10.1056/NEJMoa1915745]
 - 59 **Chen DS**, Mellman I. Elements of cancer immunity and the cancer-immune set point. *Nature* 2017; **541**: 321-330 [PMID: 28102259 DOI: 10.1038/nature21349]
 - 60 **Liao H**, Zhang Z, Chen J, Liao M, Xu L, Wu Z, Yuan K, Song B, Zeng Y. Preoperative Radiomic Approach to Evaluate Tumor-Infiltrating CD8⁺ T Cells in Hepatocellular Carcinoma Patients Using Contrast-Enhanced Computed Tomography. *Ann Surg Oncol* 2019; **26**: 4537-4547 [PMID: 31520208 DOI: 10.1245/s10434-019-07815-9]
 - 61 **Hectors SJ**, Lewis S, Besa C, King MJ, Said D, Putra J, Ward S, Higashi T, Thung S, Yao S, Laface I, Schwartz M, Gnajatic S, Merad M, Hoshida Y, Taouli B. MRI radiomics features predict immunological characteristics of hepatocellular carcinoma. *Eur Radiol* 2020; **30**: 3759-3769 [PMID: 32086577 DOI: 10.1007/s00330-020-06675-2]
 - 62 **Chen S**, Feng S, Wei J, Liu F, Li B, Li X, Hou Y, Gu D, Tang M, Xiao H, Jia Y, Peng S, Tian J, Kuang M. Pretreatment prediction of immunoscore in hepatocellular cancer: a radiomics-based clinical model based on Gd-EOB-DTPA-enhanced MRI imaging. *Eur Radiol* 2019; **29**: 4177-4187 [PMID: 30666445 DOI: 10.1007/s00330-018-5986-x]



Published by **Baishideng Publishing Group Inc**
7041 Koll Center Parkway, Suite 160, Pleasanton, CA 94566, USA

Telephone: +1-925-3991568

E-mail: bpgoffice@wjgnet.com

Help Desk: <https://www.f6publishing.com/helpdesk>

<https://www.wjgnet.com>

