

World Journal of *Gastroenterology*

World J Gastroenterol 2022 April 28; 28(16): 1608-1724



THERAPEUTIC AND DIAGNOSTIC GUIDELINES

- 1608** Guidelines to diagnose and treat peri-levator high-5 anal fistulas: Supralelevator, suprasphincteric, extrasphincteric, high outersphincteric, and high intrarectal fistulas
Garg P, Yagnik VD, Dawka S, Kaur B, Menon GR

REVIEW

- 1625** Noninvasive imaging of hepatic dysfunction: A state-of-the-art review
Duan T, Jiang HY, Ling WW, Song B
- 1641** Small nucleolar RNA host gene 3 functions as a novel biomarker in liver cancer and other tumour progression
Shan DD, Zheng QX, Wang J, Chen Z

ORIGINAL ARTICLE**Basic Study**

- 1656** LncRNA cancer susceptibility 20 regulates the metastasis of human gastric cancer cells *via* the miR-143-5p/MEMO1 molecular axis
Shan KS, Li WW, Ren W, Kong S, Peng LP, Zhuo HQ, Tian SB

Retrospective Cohort Study

- 1671** Aspartate transferase-to-platelet ratio index-plus: A new simplified model for predicting the risk of mortality among patients with COVID-19
Madian A, Eliwa A, Abdalla H, Azeem Aly H

Retrospective Study

- 1681** Association of maternal obesity and gestational diabetes mellitus with overweight/obesity and fatty liver risk in offspring
Zeng J, Shen F, Zou ZY, Yang RX, Jin Q, Yang J, Chen GY, Fan JG
- 1692** Evaluating the accuracy of American Society for Gastrointestinal Endoscopy guidelines in patients with acute gallstone pancreatitis with choledocholithiasis
Tintara S, Shah I, Yakah W, Ahmed A, Sorrento CS, Kandasamy C, Freedman SD, Kothari DJ, Sheth SG

SYSTEMATIC REVIEWS

- 1705** Risk of venous thromboembolism in children and adolescents with inflammatory bowel disease: A systematic review and meta-analysis
Zhang XY, Dong HC, Wang WF, Zhang Y

LETTER TO THE EDITOR

- 1718** Viral hepatitis: A global burden needs future directions for the management
Verma HK, Prasad K, Kumar P, Lyks B
- 1722** Comment on “Artificial intelligence in gastroenterology: A state-of-the-art review”
Bjørsum-Meyer T, Koulaouzidis A, Baatrup G

ABOUT COVER

Editorial Board Member of *World Journal of Gastroenterology*, Mauro Bortolotti, MD, Gastroenterologist, Internist, Former Director of 1st level and contract Professor at the Department of Internal Medicine and Gastroenterology of the S.Orsola-Malpighi Polyclinic, University of Bologna, via Massarenti 9, Bologna 40138, Italy. bormau@tin.it

AIMS AND SCOPE

The primary aim of *World Journal of Gastroenterology* (WJG, *World J Gastroenterol*) is to provide scholars and readers from various fields of gastroenterology and hepatology with a platform to publish high-quality basic and clinical research articles and communicate their research findings online. WJG mainly publishes articles reporting research results and findings obtained in the field of gastroenterology and hepatology and covering a wide range of topics including gastroenterology, hepatology, gastrointestinal endoscopy, gastrointestinal surgery, gastrointestinal oncology, and pediatric gastroenterology.

INDEXING/ABSTRACTING

The WJG is now indexed in Current Contents®/Clinical Medicine, Science Citation Index Expanded (also known as SciSearch®), Journal Citation Reports®, Index Medicus, MEDLINE, PubMed, PubMed Central, and Scopus. The 2021 edition of Journal Citation Report® cites the 2020 impact factor (IF) for WJG as 5.742; Journal Citation Indicator: 0.79; IF without journal self cites: 5.590; 5-year IF: 5.044; Ranking: 28 among 92 journals in gastroenterology and hepatology; and Quartile category: Q2. The WJG's CiteScore for 2020 is 6.9 and Scopus CiteScore rank 2020: Gastroenterology is 19/136.

RESPONSIBLE EDITORS FOR THIS ISSUE

Production Editor: Hua-Ge Yin, Production Department Director: Xu Guo, Editorial Office Director: Ze-Mao Gong.

NAME OF JOURNAL

World Journal of Gastroenterology

ISSN

ISSN 1007-9327 (print) ISSN 2219-2840 (online)

LAUNCH DATE

October 1, 1995

FREQUENCY

Weekly

EDITORS-IN-CHIEF

Andrzej S Tarnawski

EDITORIAL BOARD MEMBERS

<http://www.wjgnet.com/1007-9327/editorialboard.htm>

PUBLICATION DATE

April 28, 2022

COPYRIGHT

© 2022 Baishideng Publishing Group Inc

INSTRUCTIONS TO AUTHORS

<https://www.wjgnet.com/bpg/gerinfo/204>

GUIDELINES FOR ETHICS DOCUMENTS

<https://www.wjgnet.com/bpg/GerInfo/287>

GUIDELINES FOR NON-NATIVE SPEAKERS OF ENGLISH

<https://www.wjgnet.com/bpg/gerinfo/240>

PUBLICATION ETHICS

<https://www.wjgnet.com/bpg/GerInfo/288>

PUBLICATION MISCONDUCT

<https://www.wjgnet.com/bpg/gerinfo/208>

ARTICLE PROCESSING CHARGE

<https://www.wjgnet.com/bpg/gerinfo/242>

STEPS FOR SUBMITTING MANUSCRIPTS

<https://www.wjgnet.com/bpg/GerInfo/239>

ONLINE SUBMISSION

<https://www.f6publishing.com>



Guidelines to diagnose and treat peri-levator high-5 anal fistulas: Supralelevator, suprasphincteric, extrasphincteric, high outersphincteric, and high intrarectal fistulas

Pankaj Garg, Vipul D Yagnik, Sushil Dawka, Baljit Kaur, Geetha R Menon

Specialty type: Gastroenterology and hepatology

Provenance and peer review: Invited article; Externally peer reviewed.

Peer-review model: Single blind

Peer-review report's scientific quality classification

Grade A (Excellent): 0
Grade B (Very good): B
Grade C (Good): C, C, C, C, C
Grade D (Fair): 0
Grade E (Poor): 0

P-Reviewer: Elfeki H, Egypt; Zheng LH, China; Ozkan OF, Turkey; Tamburini AM, Italy

Received: August 25, 2021

Peer-review started: August 25, 2021

First decision: September 29, 2021

Revised: October 6, 2021

Accepted: March 16, 2022

Article in press: March 16, 2022

Published online: April 28, 2022



Pankaj Garg, Department of Colorectal Surgery, Garg Fistula Research Institute, Panchkula 134113, Haryana, India

Pankaj Garg, Department of Colorectal Surgery, Indus International Hospital, Mohali 140201, Punjab, India

Vipul D Yagnik, Department of Surgical Gastroenterology, Nishtha Surgical Hospital and Research Center, Patan 384265, Gujarat, India

Sushil Dawka, Department of Surgery, SSR Medical College, Belle Rive 744101, Mauritius

Baljit Kaur, Department of Radiology, SSRD Magnetic Resonance Imaging Institute, Chandigarh 160011, India

Geetha R Menon, Department of Statistics, Indian Council of Medical Research, New Delhi 110029, India

Corresponding author: Pankaj Garg, MD, MS, Chief Surgeon, Department of Colorectal Surgery, Garg Fistula Research Institute, 1042/15, Panchkula 134113, Haryana, India. drarggpankaj@yahoo.com

Abstract

Supralelevator, suprasphincteric, extrasphincteric, and high intrarectal fistulas (high fistulas in muscle layers of the rectal wall) are well-known high anal fistulas which are considered the most complex and extremely challenging fistulas to manage. Magnetic resonance imaging has brought more clarity to the pathophysiology of these fistulas. Along with these fistulas, a new type of complex fistula in high outersphincteric space, a fistula at the roof of ischiorectal fossa inside the levator ani muscle (RIFIL), has been described. The diagnosis, management, and prognosis of RIFIL fistulas is reported to be even worse than supralelevator and suprasphincteric fistulas. There is a lot of confusion regarding the anatomy, diagnosis, and management of these five types of fistulas. The main reason for this is the paucity of literature about these fistulas. The common feature of all these fistulas is their complete involvement of the external anal sphincter. Therefore, fistulotomy, the simplest and most commonly performed procedure, is practically ruled out in these fistulas and a sphincter-saving procedure needs to be performed. Recent advances have provided new insights into the anatomy,

radiological modalities, diagnosis, and management of these five types of high fistulas. These have been discussed and guidelines formulated for the diagnosis and treatment of these fistulas for the first time in this paper.

Key Words: Anal fistula; Supralelevator; Suprasphincteric; Extrasphincteric; Magnetic resonance imaging

©The Author(s) 2022. Published by Baishideng Publishing Group Inc. All rights reserved.

Core Tip: These are the first published guidelines to manage the five types of peri-levator anal fistulas that involve almost the complete external anal sphincter and have, therefore, been grouped together as high-5 fistulas. These are supralelevator, suprasphincteric, extrasphincteric, and high intrarectal and fistulas at the roof of ischioanal fossa inside the levator ani muscle. The diagnosis and management of these five fistulas is quite challenging. Magnetic resonance imaging is the best modality to accurately delineate these fistulas. Once diagnosed, care should be exercised to avoid sphincter-cutting procedures (fistulotomy) in these fistulas, as the risk of incontinence would be very high. Sphincter-sparing procedures should be done. However, there is little literature available on satisfactory management of these fistulas.

Citation: Garg P, Yagnik VD, Dawka S, Kaur B, Menon GR. Guidelines to diagnose and treat peri-levator high-5 anal fistulas: Supralelevator, suprasphincteric, extrasphincteric, high outersphincteric, and high intrarectal fistulas. *World J Gastroenterol* 2022; 28(16): 1608-1624

URL: <https://www.wjgnet.com/1007-9327/full/v28/i16/1608.htm>

DOI: <https://dx.doi.org/10.3748/wjg.v28.i16.1608>

INTRODUCTION

Anal fistulas are feared by patients and surgeons alike[1]. The prime reasons for this are difficulty in understanding the pathophysiology, risk of debilitating incontinence, and high recurrence rates, especially in complex fistulas[2-5]. Amongst the category of complex fistulas, the three well-known notorious fistulas are supralelevator, suprasphincteric and extrasphincteric fistulas[6,7]. Another less known fistula is the high intra-rectal fistula which occurs by cephalad extension of the fistula between the internal anal sphincter (IAS) and conjoint longitudinal muscle (CLM). This fistula was first described by Parks *et al*[8] in 1976. Recently, another fistula, fistula at the roof of ischioanal fossa inside the levator ani muscle (RIFIL) has also joined the category of these high fistulas[9]. RIFIL fistulas are also highly complex and involve the complete external anal sphincter (EAS). The common feature of these five fistulas is that they are quite high as these reach up to the levator muscle and involve almost the complete EAS (Figure 1). Hence, these five fistulas have been grouped together as high-5 fistulas and are discussed in detail below.

The high-five anal fistulas include: (1) Supralelevator (Figures 2 and 3); (2) Suprasphincteric (Figures 4-6); (3) Extrasphincteric (Figure 7); (4) High intra-rectal (Figures 3,8 and 9)[8]; and (5) RIFIL (Figures 10-12)[9]. These fistulas are considered most dreaded because understanding their anatomy and pathophysiology, proper diagnosis, and successful safe treatment are quite challenging. All these five fistulas involve almost the complete EAS[10,11] (Figures 2-12). As the EAS plays a major role in continence, muscle-dividing procedures like fistulotomy or cutting setons are strictly contraindicated in these fistulas. In fact, fistulotomy with primary sphincter reconstruction or fistulectomy with primary sphincter reconstruction are also best avoided in these patients[1,12-14]. Therefore, the choice of procedures becomes limited. Of these, the extrasphincteric is the only type which is trans-levator, whereas the other four fistulas (supralelevator, sphincteric, high intrarectal, and RIFIL) are peri-levator fistulas which do not traverse through the levator muscle.

This article will address the major concerns of these fistulas, including the challenges in managing and diagnosing the high-5 fistulas, as well as methods to formulate management guidelines..

CHALLENGES IN MANAGING THESE FISTULAS

Confusion about pathophysiology of High-5 fistulas

There is a lot of confusion amongst surgeons about the exact anatomy, pathways of spread, and extent of these fistulas[2]. Not uncommonly, a high transsphincteric fistula is labelled as an extrasphincteric fistula and a suprasphincteric fistula is reported as a high transsphincteric fistula[2].

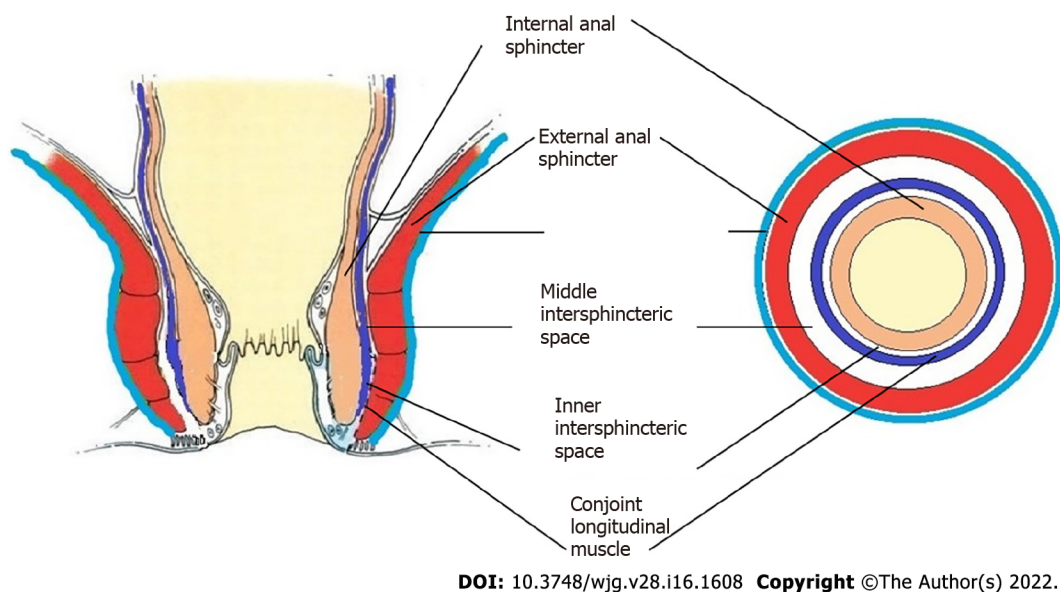


Figure 1 Normal anatomy.

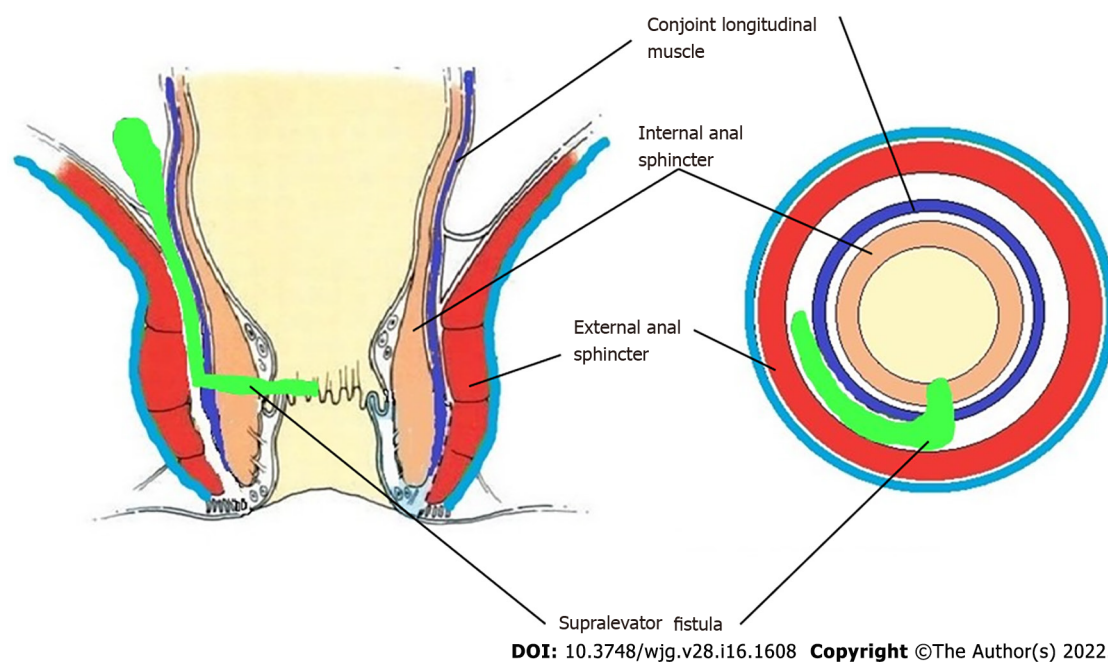
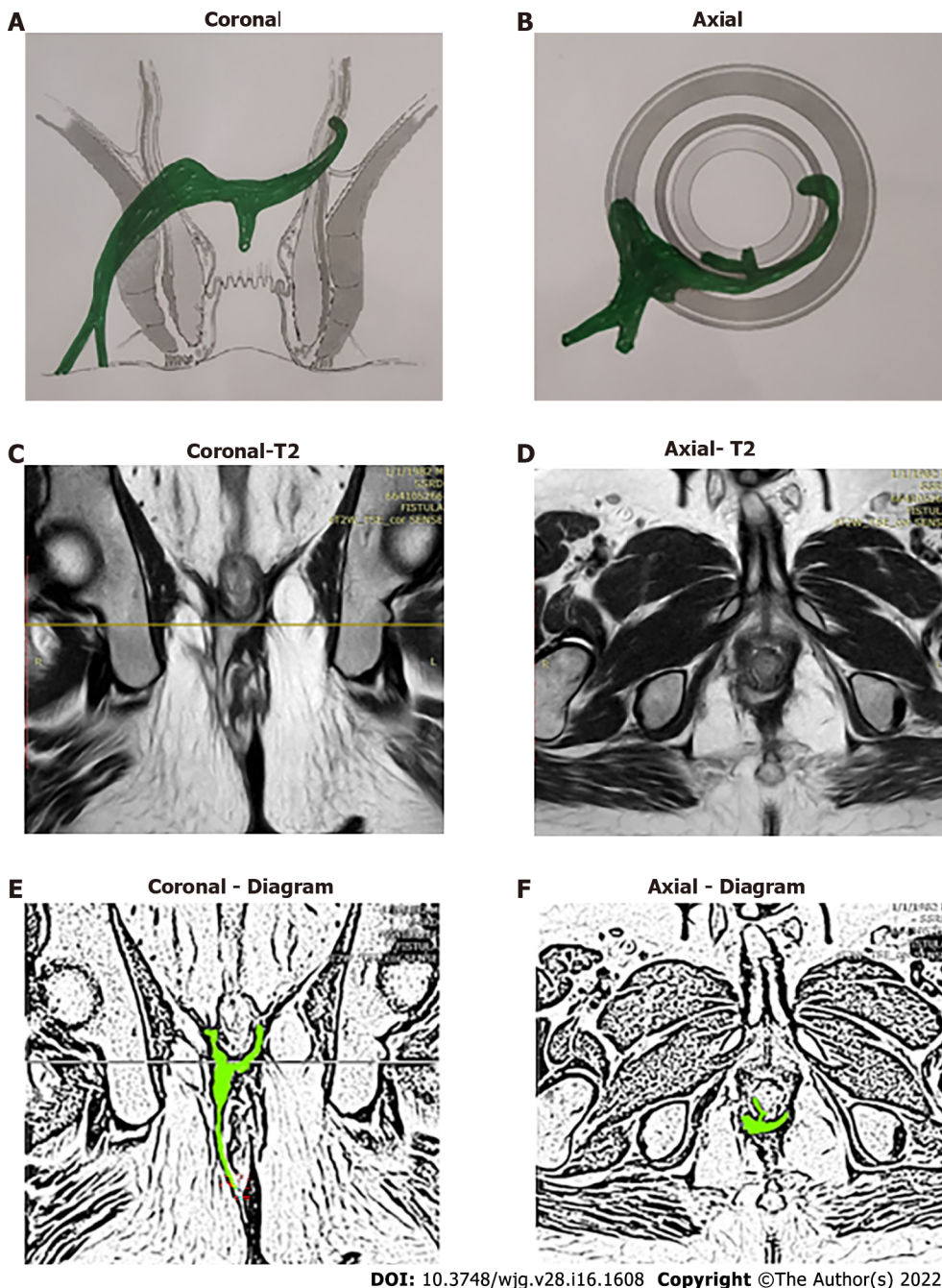


Figure 2 Supralelevator fistula.

In order to understand the pathways of extension of these fistulas, it is important to understand the anatomy of the anal canal. There are three muscle layers in the sphincter-complex in the anorectum which are downward extensions of the muscle layers of the gut. There are potential spaces between these muscle layers in which the fistula and pus can spread[9] (Figures 1, 2, 4, 7, 8 and 10).

The three muscle layers in the sphincter-complex[9] are (1) Inner circular muscle layer of gut continues downwards in the anal sphincter complex as IAS; (2) Outer longitudinal muscle layer of gut continues downwards in the anal sphincter complex as CLM; and (3) Puborectalis component of levator ani muscle continues downwards in the anal sphincter complex as EAS (Figure 1). Conventionally, it was assumed that inside the sphincter-complex, there is only one space where the fistula extends and this space between the IAS and EAS was labelled as the 'intersphincteric space'. However, with the availability of higher resolution magnetic resonance imaging (MRI) and increasing experience, it has been demonstrated that there are three potential spaces associated with in these muscle layers through which the fistula can extend[9].

The three potential spaces in the anal sphincter-complex are (1) Inner intersphincteric space (inner space): Between IAS and CLM; (2) Middle intersphincteric space (middle space): Between CLM and EAS



DOI: 10.3748/wjg.v28.i16.1608 Copyright ©The Author(s) 2022.

Figure 3 A 39-year-old male patient with a high transsphincteric fistula with supralelevator extension at 3 o'clock. There is a high intrarectal tract from 6 to 7 o'clock. The internal opening is at 6 o'clock position. A: Coronal section (schematic diagram); B: Axial section (schematic diagram); C: T2-weighted magnetic resonance imaging (MRI) Coronal section showing supralelevator tract; D: T2-weighted MRI Axial section; E: Sketch of MRI Coronal section highlighting fistula tract (light green color); F: Sketch of MRI Axial section highlighting fistula tract (light green color).

(conventional intersphincteric space); and (3) Outer-sphincteric space (outer space): Between the lateral muscle fibers of EAS and its covering fascia[9] (Figure 1).

The anal fistula, usually initiating at crypt glands at the level of the dentate line, can extend superiorly (cephalad) in any of these three spaces.

The fistulas traversing superiorly in (1) Inner intersphincteric space (inner space) between IAS and CLM inside the rectal wall to become a high intrarectal fistula as these fistulas are present between the muscle layers of the rectal wall[8]. At times, these are erroneously labelled as submucous fistula[8] (Figures 8 and 9); (2) Middle intersphincteric space (middle space) between CLM and EAS become a supralelevator fistula (if it continues into the supralelevator space) (Figures 2 and 3) or a suprasphincteric fistula (if pus extending superiorly in the middle space reaches up to the top of the EAS and then traverses through the junction between the EAS and puborectalis to enter the ischiorectal fossa[15]) (Figures 4-6); and (3) Outer-sphincteric space (outer space) between the EAS and its lateral fascia becomes a RIFIL fistula[9] (Figures 10-12).

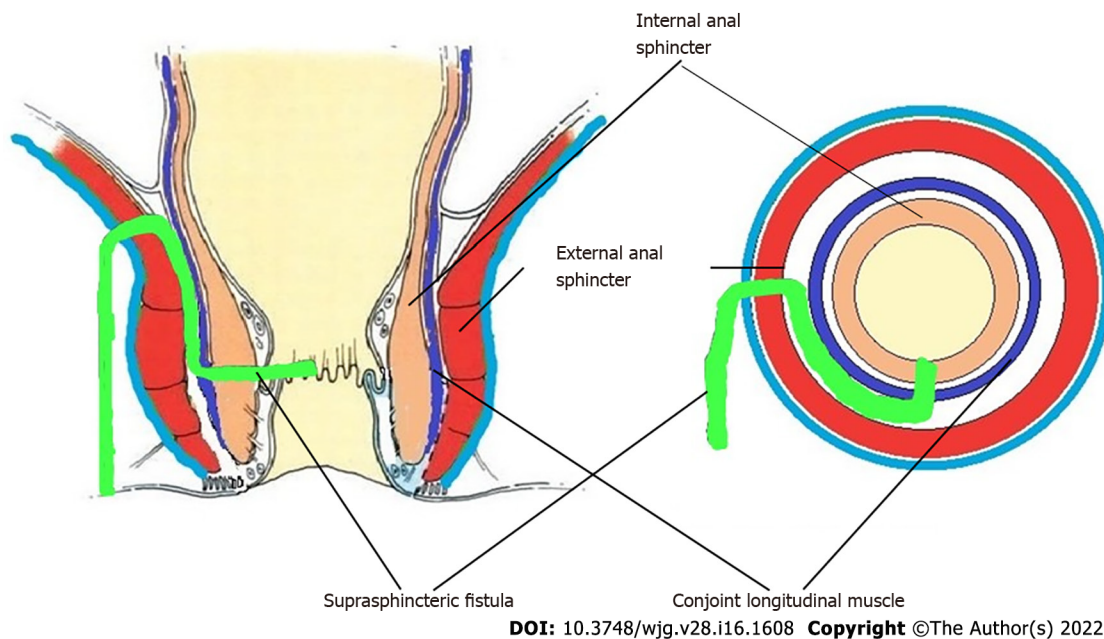


Figure 4 Suprasphincteric fistula.

Thus, the definition of these five fistulas is: (1) Supralelevator (Figures 2 and 3): These fistulas traverse in the middle intersphincteric space to enter the supralelevator space. The fistula may open into the rectum through an additional high rectal opening in the supralelevator space (Figures 3 and 6); (2) Suprasphincteric (Figures 4-6): These fistulas extend superiorly in the middle intersphincteric space to reach up to the top of the EAS and then traverses through the junction between the EAS and puborectalis to enter the ischioanal fossa; (3) Extrasphincteric (Figure 7): These fistulas traverse through the ischioanal fossa and enter the supralelevator space penetrating the levator muscle. They generally do not traverse through the sphincter-complex (EAS and IAS), which is why they are labelled as 'extra-sphincteric' fistulas; (4) High intra-rectal (Figures 8 and 9): These fistulas traverse cephalad between IAS and CLM in the rectal wall and is thus present between the muscle layers of the rectal wall; and (5) RIFIL (Figures 10-12): These fistulas traverse the EAS but do not enter the ischioanal fossa. They extend cephalad between the EAS and its lateral fascia to continue on the undersurface of puborectalis and levator ani muscle[9].

Incidence: In recently published large cohorts, the prevalence of these high-5 fistulas has been highlighted[9,16]. The incidence of these fistulas in a cohort of 419 consecutively operated patients over a 2-year period were RIFIL-10% (42/419), supralelevator-9.5% (40/419), suprasphincteric-5.5% (23/419) and extrasphincteric-0%[9,16].

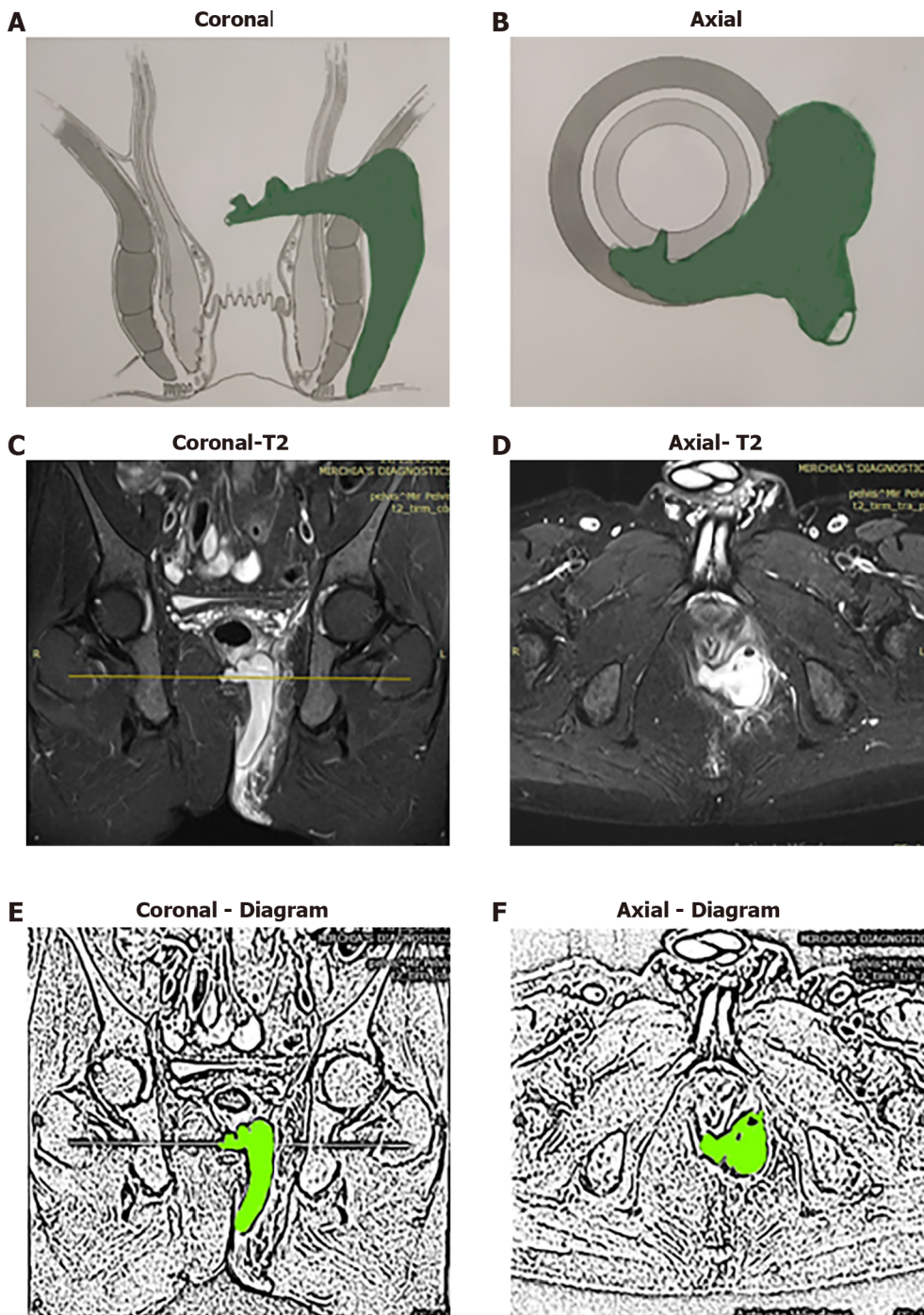
Difficulty in diagnosis

As these fistulas are deep and high, they are extremely difficult to diagnose on clinical examination. It usually requires advanced imaging modalities, MRI, or transrectal ultrasound (TRUS), to diagnose these fistulas[17-21]. Both MRI and 3D-TRUS are very effective in delineating various parameters of these fistulas, including the internal opening, primary tracts, and secondary extensions[17-20,22], though MRI has a slight edge over TRUS. It is really impressive that in the pre-MRI era, doyens in the field like Parks *et al*[8] could describe these deep fistulas with a reasonably high level of accuracy.

MRI helps to clearly differentiate between supralelevator, suprasphincteric, high intrarectal, and RIFIL fistulas[23]. Rather it would not be wrong to say that MRI is mandatory to properly diagnose these fistulas. Therefore, whenever a fistula has recurred several times, or a tract or side branch of the main fistula is seen extending superiorly during surgery, an MRI should be done to rule out these fistulas[23].

Status of extrasphincteric fistulas

Increasing experience with MRI in fistulas has highlighted that extrasphincteric fistulas do not occur or are extremely rare[24]. It stands to reason that it is almost impossible for a fistula in the ischioanal fossa to penetrate through the strong levator plate when it can extend with ease in the surrounding fat of the ischioanal fossa[24]. The only likely possibility for an extrasphincteric fistula to occur is iatrogenic when an artery forceps in a high transsphincteric fistula is pushed through the levator muscle. Even this seems improbable as it would require a lot of force by the operating surgeon. Moreover, due to increased awareness amongst surgeons of iatrogenic injuries, better understanding of regional anatomy, and easy availability of advanced radiological modalities, these iatrogenic blunders seem exceedingly



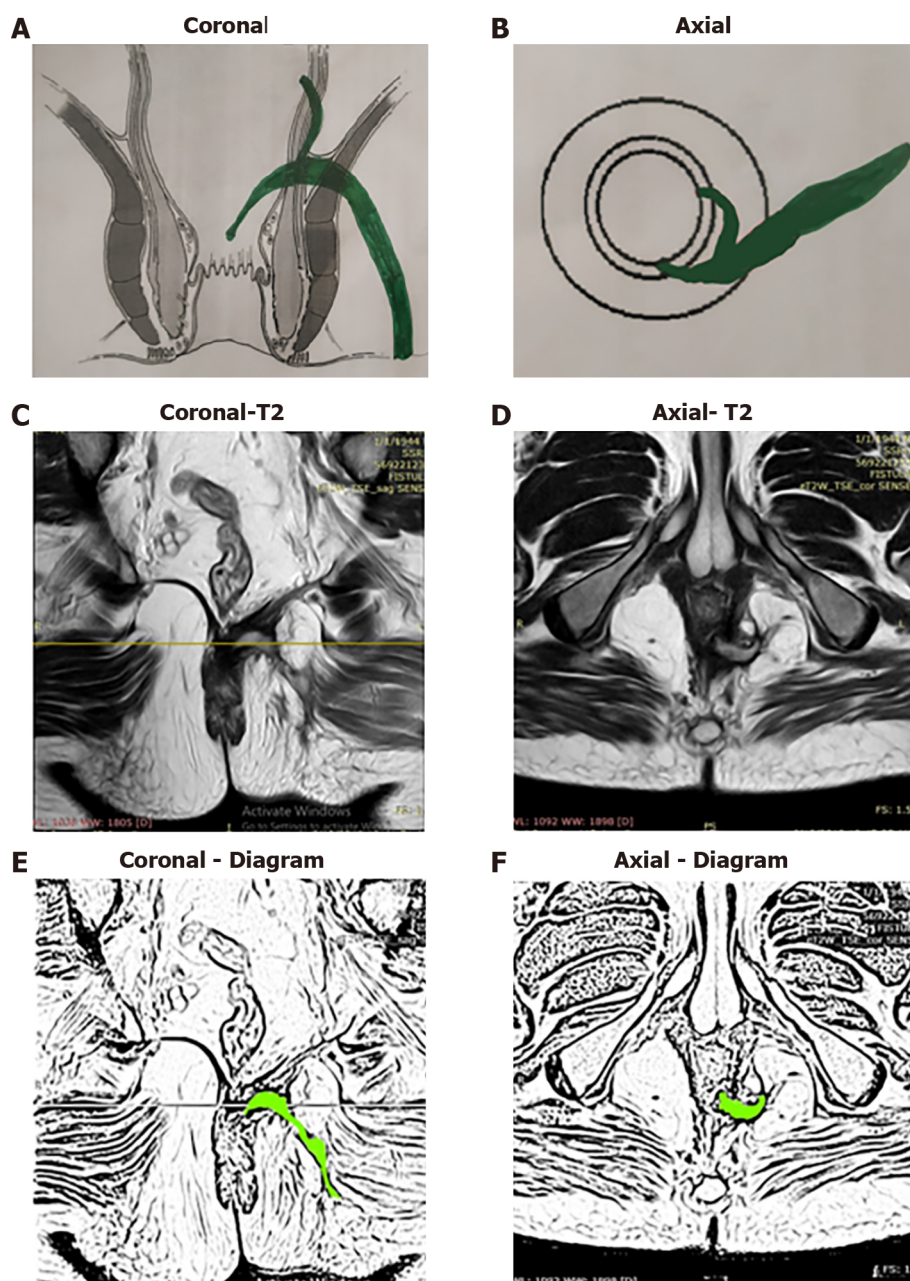
DOI: 10.3748/wjg.v28.i16.1608 Copyright ©The Author(s) 2022.

Figure 5 A 40-year-old male patient with a suprasphincteric fistula and abscess on left side. The internal opening is at 6:30 o'clock position. A: Coronal section (schematic diagram); B: Axial section (schematic diagram); C: Short Tau Inversion Recovery (STIR) magnetic resonance imaging (MRI) Coronal section showing suprasphincteric tract and abscess; D: STIR MRI Axial section; E: Sketch of MRI Coronal section highlighting suprasphincteric fistula tract and abscess (light green color); F: Sketch of MRI Axial section highlighting fistula tract and abscess (light green color).

unlikely. Due to this, extrasphincteric fistulas are not seen (or are extremely rare) these days[24]. It is quite possible that the fistulas diagnosed as extrasphincteric fistulas in the pre-MRI era were perhaps supralevator or RIFIL fistulas. Understandably, in the absence of MRI, it is extremely difficult to differentiate between an extrasphincteric fistula and other deep fistulas. So, a diagnosis of extrasphincteric fistula should be made only after due deliberation and detailed analysis of MRI[24].

Complete involvement of EAS

The main challenge in these five fistulas is that they involve almost the complete EAS (Figures 2, 4, 7, 8 and 10). The EAS plays a major role in maintaining continence and risk of damage to the EAS is very high in these fistulas. Because this risk of incontinence is so high, these fistulas are extra concerning[4,5,



DOI: 10.3748/wjg.v28.i16.1608 Copyright ©The Author(s) 2022.

Figure 6 A 47-year-old male patient with a suprasphincteric fistula on left side and supralelevator tract and high rectal opening at 3 o'clock. The internal opening is at 6 o'clock position. A: Coronal section (schematic diagram); B: Axial section (schematic diagram); C: T2-weighted magnetic resonance imaging (MRI) Coronal section showing suprasphincteric tract; D: T2-weighted MRI Axial section; E: Sketch of MRI Coronal section highlighting supralelevator fistula tract (light green color); F: Sketch of MRI Axial section highlighting fistula tract (light green color).

25]. The most commonly performed procedure, fistulotomy, is contraindicated in these fistulas[25]. There is little published data and there are no standard guidelines to manage these fistulas. Therefore, the fear of managing these fistulas amongst surgeons is easy to understand.

Presence of ASRO (additional supralelevator rectal opening)

One of the features that make these fistulas more challenging is the presence of an ASRO along with a primary internal opening at the dentate line[6]. In a large cohort, ASRO was present in 2.8% (23/836) anal fistulas, but in supralelevator fistulas, the incidence was 16.6% (23/138)[6]. At times, the presence of ASRO is detected accidentally during surgery (intraoperatively) when a colored solution injected into the external opening comes out through the primary internal opening at the dentate line as well as through the ASRO[6]. In many cases, a granulation polyp or a papilla can be seen at the site of the ASRO. However, ASRO can be diagnosed preoperatively with the help of MRI in almost every case[6]. MRI is an excellent tool to diagnose ASRO with a high level of accuracy[6].

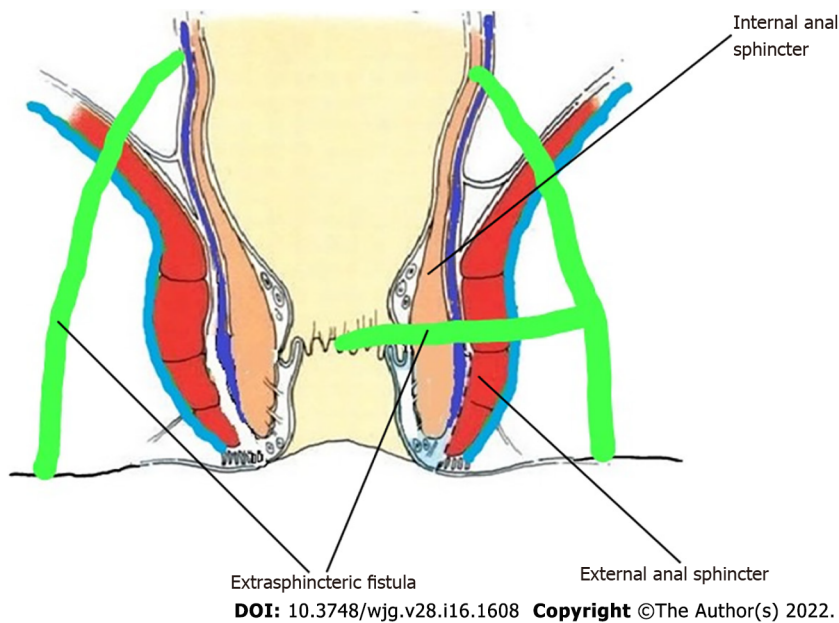


Figure 7 Extrasphincteric fistula.

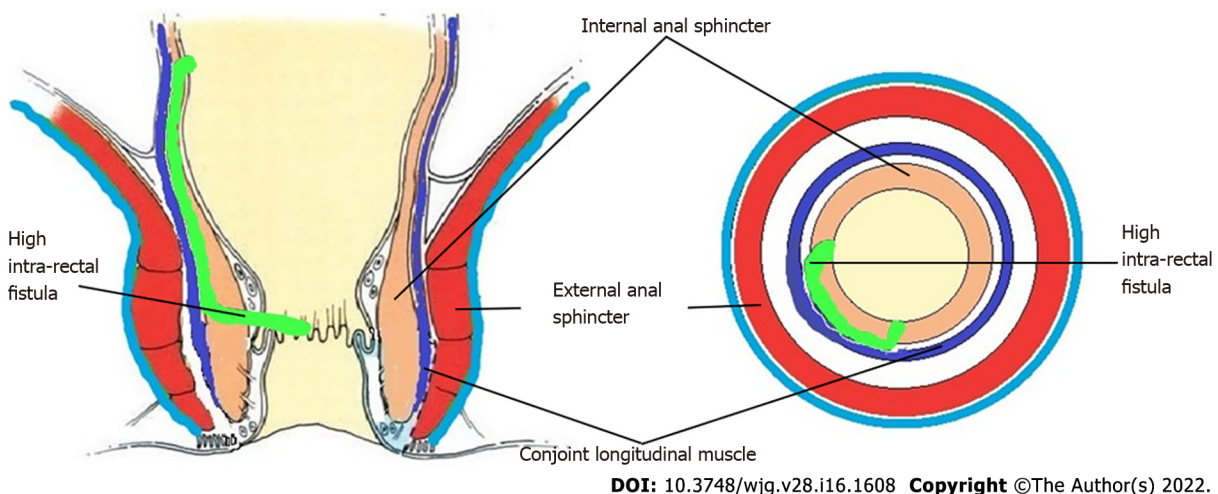


Figure 8 High Intrarectal fistula.

The management of ASRO seems challenging. Closure of an opening high up in the rectum which, at times, is even difficult to reach through the transanal route is not easy. However, there is a sliver of relief in these otherwise complex fistulas. A recent study has demonstrated that even if nothing is done to ASRO, there is no impact on ultimate fistula healing[6].

There is an explanation for this surprising finding. Anal fistulas usually initiate in crypt glands located at the dentate line. The fistula then can extend in different directions from here. Some fistulas or abscesses extend superiorly and enter the supralelevator space[6]. In a small subset (16%) of these supralelevator abscesses, the pressure generated by the supralelevator abscess is so high that the abscess ruptures into the rectum, thus creating an ASRO. In such situations, the flow of infection (and bacteria) in ASRO is from the supralelevator space into the rectum[6]. This continues in the same manner because, unlike in the anal canal where intraluminal pressure rises during defecation, pressure in the mid-rectum is quite low (as the rectum is primarily a storage organ). Therefore, the bacteria usually enter the fistula tract from the primary internal opening at the dentate line, bacterial multiplication leads to suppuration, and then the pus egresses through the external opening and the ASRO (if present)[6]. Hence, ultimate healing of the fistula depends primarily on successful closure of the primary internal opening at the dentate line. Once the primary internal opening at the dentate line heals, the fistula heals irrespective of whether the ASRO is closed or open[6]. Therefore, it is a reassuring fact that ASRO left untreated does not affect the ultimate fistula outcome[6].

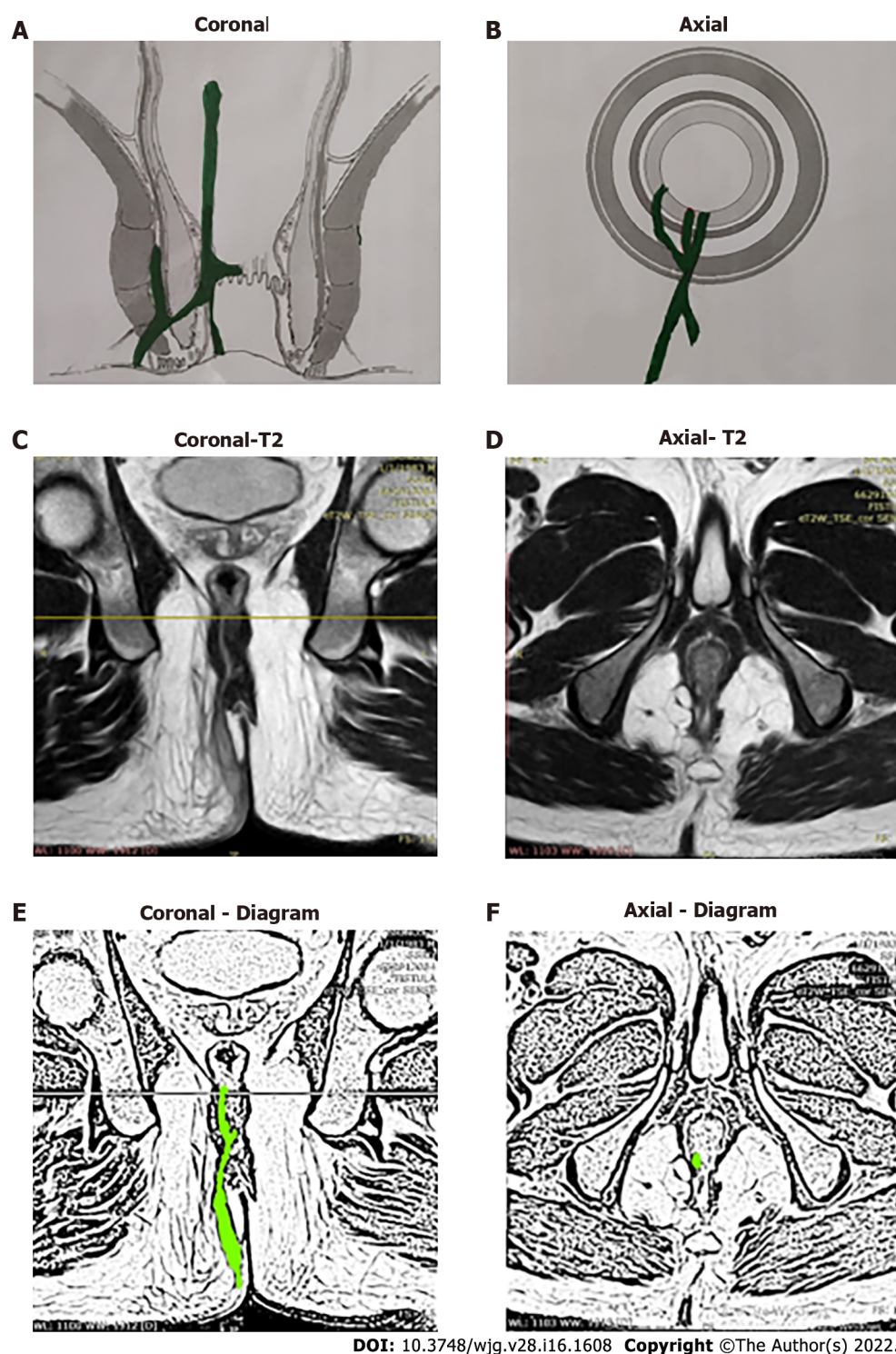


Figure 9 A 36-year-old male patient with a high intrarectal fistula at 7 o'clock. A: Coronal section (schematic diagram); B: Axial section (schematic diagram); C: T2-weighted magnetic resonance imaging (MRI) Coronal section showing high intrarectal fistula tract; D: T2-weighted MRI Axial section; E: Sketch of MRI Coronal section highlighting high intrarectal fistula tract (light green color); F: Sketch of MRI Axial section highlighting fistula tract (light green color).

Detection of underlying secondary pathology

The high-5 fistulas are more complex and refractory to treatment as compared to other fistulas. The incidence of associated complicating pathology like Crohn's disease and tuberculosis is higher in these fistulas[24,26,27]. Therefore, it is important that these diseases should be ruled out whenever any of these high fistulas are diagnosed or suspected.

In regions where Crohn's disease is common, a colonoscopy should be done in all cases of high fistulas[28]. On the other hand, in regions where tuberculosis is common, polymerase chain-reaction (PCR) should be done in samples from the fistula (pus or fistula tract wall or tract lining)[24,29]. In a large series published from a TB-endemic region (India), tuberculosis was detected in 10% (133/1336) of

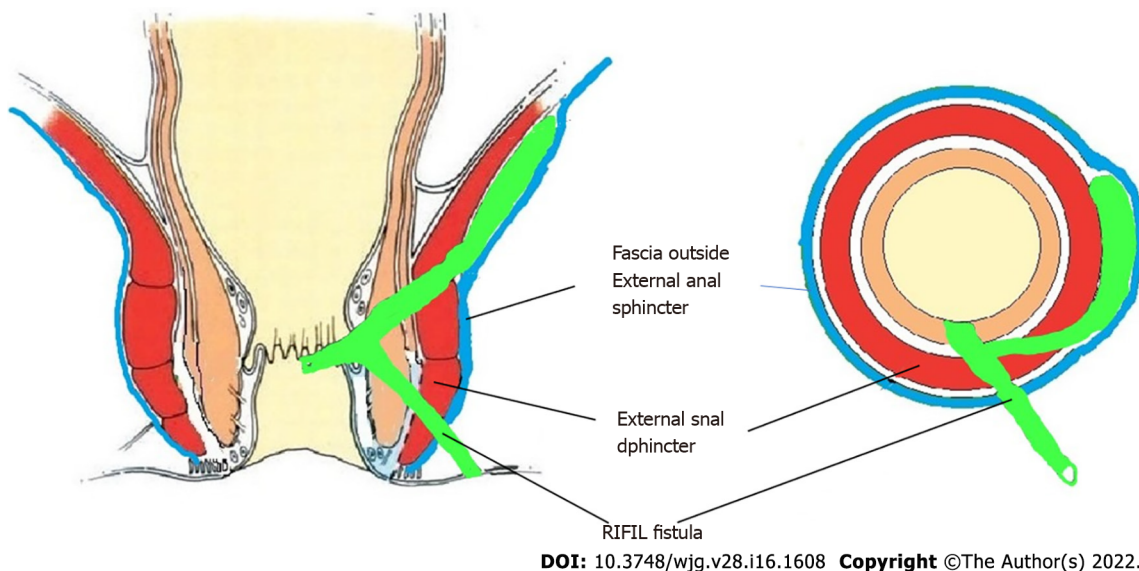


Figure 10 Roof of ischiorectal fossa inside the levator ani muscle fistula. RIFIL: Roof of ischiorectal fossa inside the levator ani muscle.

tested samples (fistula tract lining or pus)[29]. The detection rate of tuberculosis was 12.5% (129/1034) by PCR, 1.5% (3/197) by histopathology, and 0.9% (1/105) by GeneXpert tests[29]. Therefore, PCR is significantly more sensitive than histopathology or GeneXpert to detect tuberculosis[29]. However, in spite of high sensitivity, it is not uncommon that tuberculosis is missed and goes undetected in the first sample. Therefore, in regions where tuberculosis is endemic, it is recommended that repeated samples should be sent for testing, especially in more complex refractory fistulas[29].

METHODS USED TO FORMULATE MANAGEMENT GUIDELINES

A search was performed on MEDLINE, PubMed, EMBASE, and the Cochrane Database of Collected Reviews from January 1975 to September 2021. Keyword combinations using MeSH terms included supralelevator, suprasphincteric, extrasphincteric, intrarectal, abscess, fistula, fistula-in-ano, anal, rectal, perianal, perineal, seton, fistula plug, fibrin glue, advancement flap, tuberculosis, Crohn's disease, ligation of intersphincteric tract, ligation of intersphincteric fistula tract (LIFT), fistulectomy with primary sphincter reconstruction (FPR), fistulectomy with primary sphincter repair, transanal opening of the intersphincteric space (TROPIS) and stem cells.

Various guidelines, such as GRADE[30,31], RIGHT[32] AGREE[33] were evaluated, but considering the rarity of the disease condition (Hi-5 fistulas) in the study, the Levels of Evidence for Therapeutic Studies developed by Centre for Evidence-Based Medicine, <http://www.cebm.net>. (Oxford, United Kingdom) (Table 1) and Grade Practice Recommendations recommended by American Society of Plastic Surgeons (Table 2) were utilized[34]. Each diagnostic and therapeutic intervention was assigned a 'level of evidence' from 1A to 5 (1A being the strongest evidence and 5 being the weakest) (Table 1) and then a 'grade of recommendation' was awarded ranging from 'A' to 'D' ('A' being a strong recommendation and 'D' being a weak option) (Table 2).

Authors (PG, VDY) reviewed all English language articles and tabulated all the evidence available and allotted the level of evidence. After that, the grade of recommendation was decided with consensus of all the authors.

MANAGEMENT GUIDELINES

Diagnostic evaluation of Hi-5 fistulas

MRI or TRUS are preferred modalities to evaluate Hi-5 fistulas. MRI is better than TRUS to evaluate high secondary extensions. Level of Evidence-2B. Grade of recommendation-B.

MRI and TRUS are the diagnostic modalities of choice to evaluate complex anal fistulas[17,19-21]. MRI and 3D-TRUS have comparable efficacy in outlining the internal opening and primary tracts; however, MRI is significantly more effective than 3D-TRUS in detecting deep secondary extensions[35]. The sensitivity of 3D-TRUS to detect deep secondary extensions was 73.9% while MRI had sensitivity of 97% ($P = 0.041$)[35]. Therefore, MRI is the preferred modality to diagnose high fistulas especially the high-5 fistulas[10,36].

Table 1 Levels of evidence for therapeutic studies[49]

Level	Type of evidence
1	A B C
2	A B C
3	A B
4	
5	

Citation: CEBM. OCEBM levels of evidence. [cited 11 January 2022]. Available from: <https://www.cebm.ox.ac.uk/resources/levels-of-evidence/ocebm-levels-of-evidence>. Copyright© 2022 University of Oxford.

RCTs: Randomized controlled trials.

Table 2 Grade practice recommendations¹

Grade	Level of Recommendation	Qualifying evidence	Implications for clinicians
A	Strong recommendation	Level I evidence or consistent findings from several studies of levels II, III, or IV	These recommendations should be followed unless an alternative approach with clear and compelling rationale is present
B	Recommendation	Consistent evidence of levels II, III, or IV	These recommendations should be followed but clinicians should understand that there is scope of improvement and these may be slightly modified as <i>per</i> patient preferences
C	Option	Levels II, III, or IV evidence, but findings are inconsistent	These guidelines are broad guidelines and clinicians should be flexible in their decision-making regarding appropriate practice keeping patient preferences in mind
D	Option	Level V evidence: Little or no substantial evidence	These recommendations may be referred but clinicians should consider all other available options while making decisions

¹Based on the American Society of Plastic Surgeons[34].

Surgical procedure

Due to the challenging factors discussed above, the management of high-5 fistulas is quite difficult and far from satisfactory. Apart from the associated complex parameters, the additional problem is minimal experience or published data on the management of these fistulas. Due to this, the quality of data is of a low evidence level.

As discussed earlier, due to complete involvement of EAS, the most commonly performed procedure, fistulotomy, is contraindicated in these fistulas[25] unless it is coupled with primary sphincter repair. The newer sphincter-sparing procedures, like video-assisted anal fistula treatment[24], fistula laser closure[24], over-the scope clip (OTSC)[37-39], anal fistula plug (AFP)[40], stem cells[28] *etc*, have dismal success rates in complex fistulas. In fact, there are hardly any studies that have analyzed the success rates of these newer procedures in high-5 fistulas. Therefore, the sphincter-preserving procedures, such as LIFT, FPR, advancement flaps, and TROPIS, seem more suitable procedures for high-5 fistulas.

TROPIS provides a ray of hope, as it has been shown to have satisfactory results in these fistulas[2,3,16,24,41]. In the TROPIS procedure, the intersphincteric space is laid open in the anal canal and the resultant wound is allowed to heal by secondary intention[16,24]. The transsphincteric tracts (tracts lateral to the EAS in the ischioanal fossa) are thoroughly curetted and cleaned[3,41]. Thus, the tracts on both sides of the EAS are managed separately (tracts inner to the EAS are laid open into the anal canal and tracts outside the EAS in the ischioanal fossa are curetted and cleaned) and the EAS is not cut or damaged at all[16,24]. Due to this, it has been shown that there is no deterioration in continence after the TROPIS procedure[16,24].

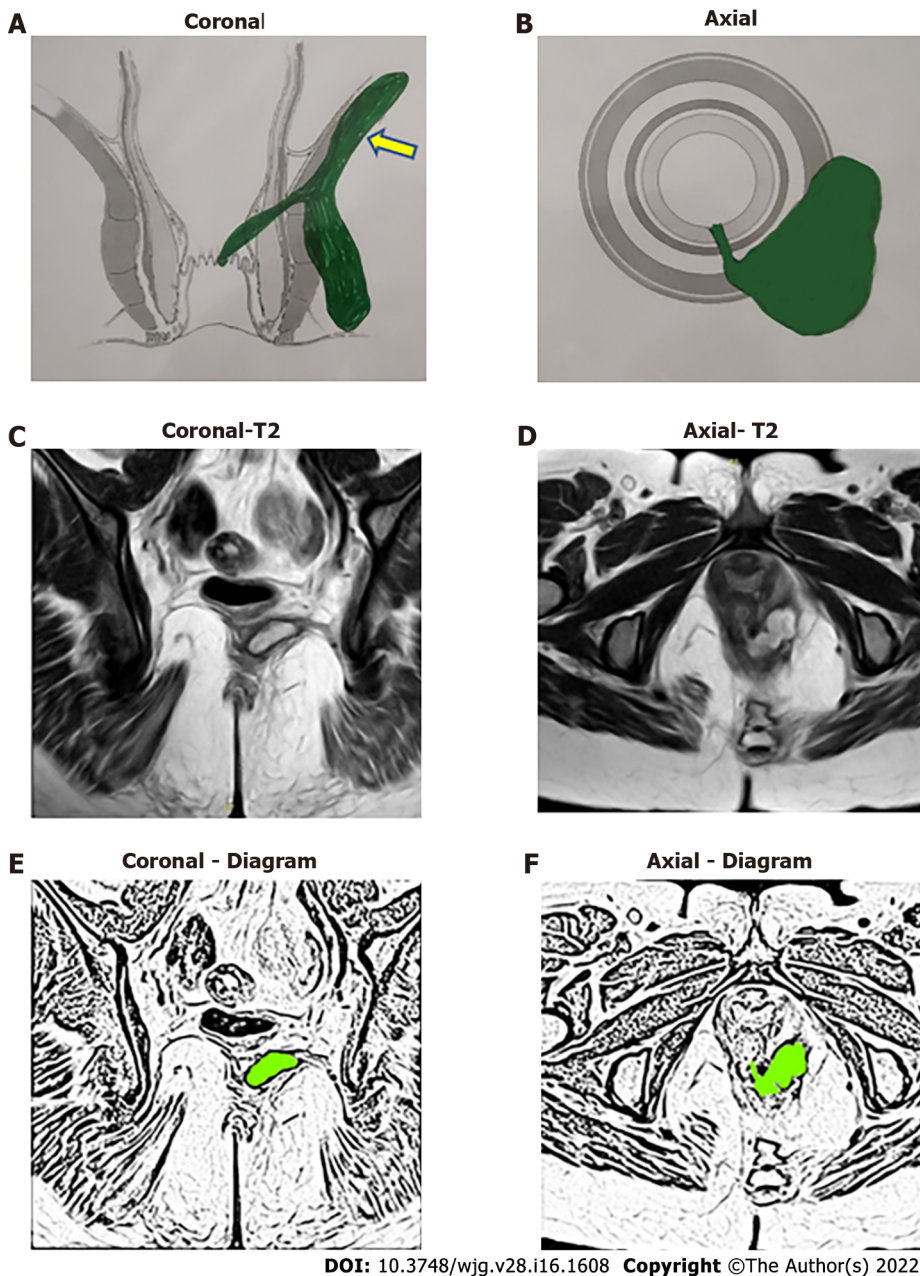


Figure 11 A 33-year-old female patient with a roof of ischiorectal fossa inside the levator ani muscle fistula on left side at 5 o'clock and internal opening at 6 o'clock position. A: Coronal section showing roof of ischiorectal fossa inside the levator ani muscle (RIFIL) fistula (yellow arrow) (schematic diagram); B: Axial section (schematic diagram); C: T2-weighted magnetic resonance imaging (MRI) Coronal section showing RIFIL fistula tract; D: T2-weighted MRI Axial section; E: Sketch of MRI Coronal section highlighting RIFIL fistula tract (light green color); F: Sketch of MRI Axial section highlighting fistula tract (light green color).

The reason for the higher success rate of the TROPIS procedure could be that, unlike other procedures, TROPIS adequately tackles the sepsis in the intersphincteric space[3,41]. It is now understood that the pus/sepsis in the intersphincteric part of the fistula tract is like an abscess in a closed space[24]. Therefore, this sepsis is best managed in the manner an abscess anywhere else in the body is managed-deroofting the abscess cavity and allowing it to heal by secondary intention[24].

Supralelevator fistulas

A supralelevator abscesses can be drained into the rectum with a moderate success rate[7,42-44]. The level of evidence for this is 2B with a grade of recommendation of B. For example, Garcia-Granero *et al*[7] drained the supralelevator abscess into the rectum in four patients and all of them healed.

This not only leads to resolution of the acute symptoms, but also leads to fistula healing in many cases[7,44].

Fistulectomy with or without advancement flap may be done in selected cases with a moderate success rate[44]. The level of evidence is a -4, with the grade of recommendation a-D. Van Onkelen *et al*

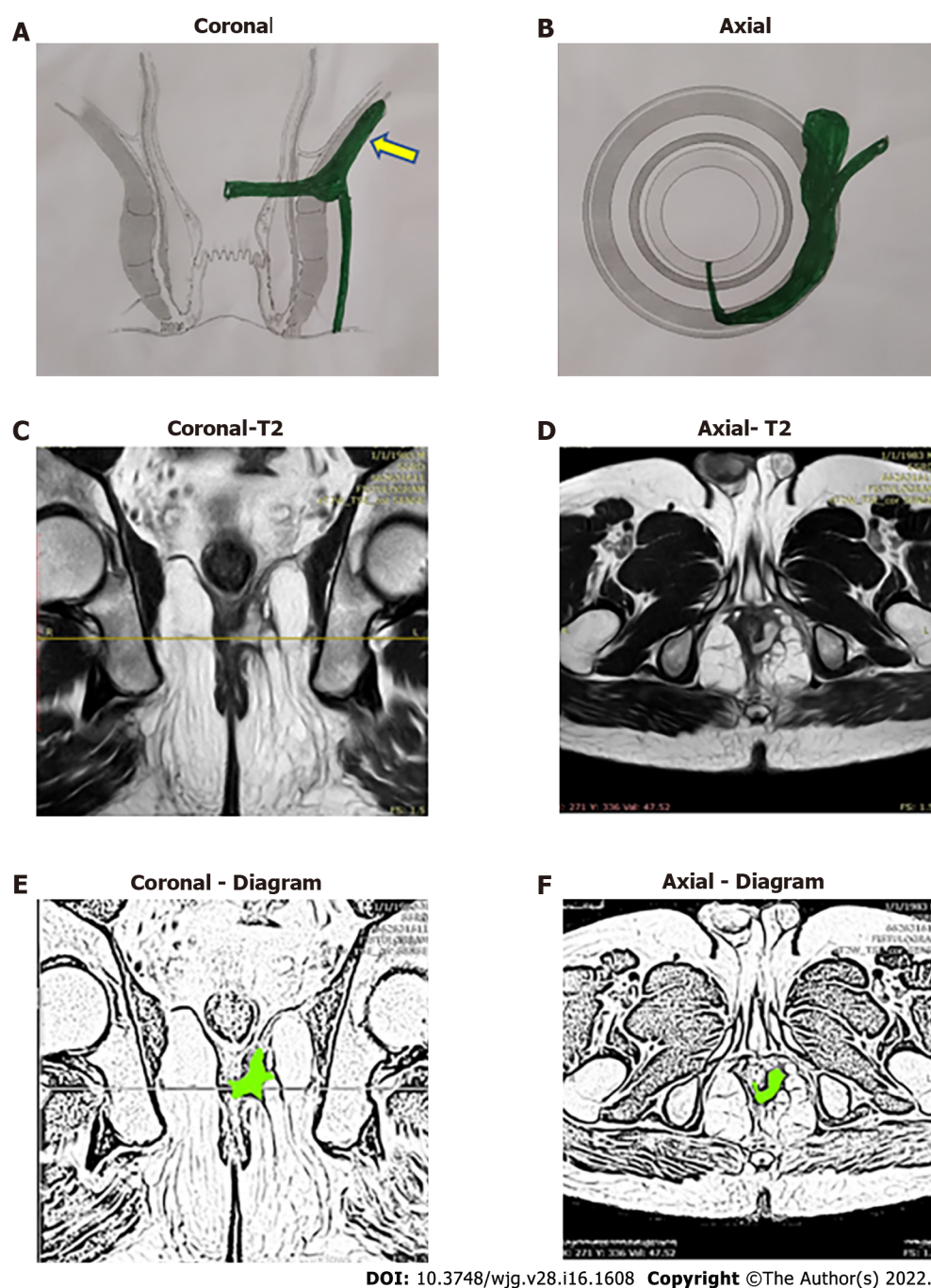


Figure 12 A 38-year-old male patient with a roof of ischiorectal fossa inside the levator ani muscle fistula on left side at 3 o'clock and internal opening at 6 o'clock position. A: Coronal section showing roof of ischiorectal fossa inside the levator ani muscle (RIFIL) fistula (yellow arrow) (schematic diagram); B: Axial section (schematic diagram); C: T2-weighted magnetic resonance imaging (MRI) Coronal section showing RIFIL fistula tract; D: T2-weighted MRI Axial section; E: Sketch of MRI Coronal section highlighting RIFIL fistula tract (light green color); F: Sketch of MRI Axial section highlighting fistula tract (light green color).

[44] performed advancement flap in three patients after draining the supralelevator abscess. All patients healed but multiple surgeries were required in order to achieve fistula healing[44].

Supralelevator fistula can be managed with laying open of the supralelevator extension into the rectum through the transanal route (TROPIS) procedure with a satisfactory healing rate[6,16]. The level of evidence for this is 2B with a grade of recommendation of B. The success rate was 84.6% (11/13) in the initial series and 82.1% (92/112) on long-term follow-up (median 30 mo) in the same series[16].

LIFT and FPR can also be done in selected cases with good success rates (80%-91%) in high complex fistulas (the studies included supralelevator fistulas)[45,46]. The level of evidence for this is 5 with a grade of recommendation of D. However, data for these two procedures specific to supralelevator fistulas is not available.

Suprasphincteric fistulas

Advancement flap, fistulotomy/fistulectomy with primary sphincter repair and stem cells have moderate success rates, with a success rate range from 70%-85%, though the sample size was quite small [47]. The level of evidence for this is 2B with a grade of recommendation of D. Perez *et al* [47] compared advancement flap *vs* fistulotomy with sphincter reconstruction in suprasphincteric fistulas and the healing rate was 80% (4/5) and 83.3% (5/6) respectively [47]. However, the risk of cutting the entire EAS and then repairing the same seems a difficult option to most surgeons. Also, in the rare eventuality of suture dehiscence, the risk of incontinence would be very high.

Fibrin glue has a poor success rate in suprasphincteric fistulas. The level of evidence for this is 2B with a grade of recommendation of C. Garcia-Olmo *et al* [48] compared the healing rate of fibrin glue *vs* adipose stem cells in suprasphincteric fistulas. The healing rate in the fibrin glue group was 8% (2/16) while it was 71% (10/14) in the stem cells group [48].

The TROPIS procedure has had promising results with a good success rate with minimal impact on continence. The level of evidence for this is 4 with a grade of recommendation of C. Out of 14 suprasphincteric fistulas, 78.6% (11/14) patients were cured with no deterioration in continence levels after surgery on long-term follow-up (median 30 mo) [16].

LIFT can be done in selected cases but is technically difficult. The level of evidence for this is 2B with a grade of recommendation of C.

There are studies in which LFT has shown a good success rate (80%-91%) in high complex fistulas [45, 46], but data for LIFT exclusive to supralelevator fistulas is not available. It is also expected that performing the LIFT procedure in suprasphincteric fistulas (ligating the intersphincteric tract high up in the intersphincteric plane) would be a technically demanding procedure.

Extrasphincteric fistulas

Temporary colostomy with management of the primary pathology can be used for extrasphincteric fistulas. The level of evidence for this is 5 with a grade of recommendation of D.

Extrasphincteric fistulas are extremely rare these days, which means there is little data available on the management of these fistulas. As most of these fistulas are caused by secondary pelvic pathology or iatrogenic factors, a diverting stoma along with management of the underlying cause would be the mainstay of treatment [8].

High intra-rectal fistulas

Intra-anal fistulotomy (TROPIS procedure) has a high success rate with minimal impact on continence. The level of evidence for this is 4 with a grade of recommendation of B. These fistulas are perhaps the easiest to treat. Simple intra-rectal fistulotomy (laying open the fistula tract into the anorectum) would cure these fistulas with a high success rate (> 90%) [8, 16].

RIFIL fistulas (fistula at the roof of ischioanal fossa inside the levator ani muscle)

TROPIS has a moderate success rate with minimal impact on continence in RIFIL fistulas. The level of evidence for this is 2B with a grade of recommendation of B. RIFIL fistulas are challenging to manage because access to the RIFIL component might become difficult. TROPIS has shown a moderate success rate in RIFIL fistulas [9]. The healing rate in RIFIL fistulas by the TROPIS procedure was 69.4% (25/36) with a follow-up (median) of 12 mo [9]. There was no negative impact on continence following surgery.

LIFT and FPR are expected to have a moderate success rate; however, since RIFIL fistulas have been recently described [9] and till now, there are no studies of LIFT or FPR procedure in RIFIL fistulas. Conceptually it is expected that these procedures would also prove at least moderately effective for these fistulas. The level of evidence for this is 5 with a grade of recommendation of D.

CONCLUSION

Anal fistulas that reach up to the levator muscle and involve almost the complete EAS have been grouped together as high-5 fistulas. These comprise supralelevator, suprasphincteric, extrasphincteric, high intrarectal, and RIFIL fistulas. The diagnosis as well as the management of these five fistulas is quite challenging. Advanced radiological modalities, preferably MRI, are needed to accurately delineate these fistulas. Once diagnosed, care should be exercised to avoid sphincter-cutting procedures like fistulotomy or cutting seton in these fistulas as the risk of incontinence would be very high. Sphincter-sparing procedures like TROPIS or LIFT should be carried out in these fistulas. These guidelines may help improve understanding and outcomes in the management of these complex fistulas.

FOOTNOTES

Author contributions: Garg P conceived and designed the study, collected and analyzed the data, revised the data,

approved and submitted the final manuscript (guarantor of the review); Dawka S critically analyzed the data, reviewed and edited the manuscript, and approved and submitted the final manuscript; Kaur B and Yagnik VD collected and analyzed the data, revised the data, and approved and submitted the final manuscript; Menon GR analyzed the data, revised the data, and approved and submitted the final manuscript.

Conflict-of-interest statement: None of the authors, Pankaj Garg, Vipul D Yagnik, Baljit Kaur, Sushil Dawka, or Geetha R Menon, have any conflict of interest.

Open-Access: This article is an open-access article that was selected by an in-house editor and fully peer-reviewed by external reviewers. It is distributed in accordance with the Creative Commons Attribution NonCommercial (CC BY-NC 4.0) license, which permits others to distribute, remix, adapt, build upon this work non-commercially, and license their derivative works on different terms, provided the original work is properly cited and the use is non-commercial. See: <https://creativecommons.org/licenses/by-nc/4.0/>

Country/Territory of origin: India

ORCID number: Pankaj Garg 0000-0002-0800-3578; Vipul D Yagnik 0000-0003-4008-6040; Sushil Dawka 0000-0002-9372-3683; Baljit Kaur 0000-0002-3882-7578; Geetha R Menon 0000-0003-2491-0650.

Corresponding Author's Membership in Professional Societies: American Society of Colon Rectum Surgeons; American Society of Gastrointestinal Endoscopic Surgeons; Association of Surgeons of India.

S-Editor: Fan JR

L-Editor: Filipodia

P-Editor: Yu HG

REFERENCES

- 1 **Ratto C**, Grossi U, Litta F, Di Tanna GL, Parello A, De Simone V, Tozer P, DE Zimmerman D, Maeda Y. Contemporary surgical practice in the management of anal fistula: results from an international survey. *Tech Coloproctol* 2019; **23**: 729-741 [PMID: 31368010 DOI: 10.1007/s10151-019-02051-5]
- 2 **Włodarczyk M**, Włodarczyk J, Sobolewska-Włodarczyk A, Trzeciński R, Dzikowski Ł, Fichna J. Current concepts in the pathogenesis of cryptoglandular perianal fistula. *J Int Med Res* 2021; **49**: 300060520986669 [PMID: 33595349 DOI: 10.1177/0300060520986669]
- 3 **Li YB**, Chen JH, Wang MD, Fu J, Zhou BC, Li DG, Zeng HQ, Pang LM. Transanal Opening of Intersphincteric Space for Fistula-in-Ano. *Am Surg* 2021; 3134821989048 [PMID: 33517706 DOI: 10.1177/0003134821989048]
- 4 **Jeong HY**, Song SG, Nam WJ, Lee JK. Puborectalis Muscle Involvement on Magnetic Resonance Imaging in Complex Fistula: A New Perspective on Diagnosis and Treatment. *Ann Coloproctol* 2021; **37**: 51-57 [PMID: 32972097 DOI: 10.3393/ac.2020.08.26.1]
- 5 **Jayne DG**, Scholefield J, Tolan D, Gray R, Senapati A, Hulme CT, Sutton AJ, Handley K, Hewitt CA, Kaur M, Magill L; FIAT Trial Collaborative Group. A Multicenter Randomized Controlled Trial Comparing Safety, Efficacy, and Cost-effectiveness of the Surgisis Anal Fistula Plug Versus Surgeon's Preference for Transsphincteric Fistula-in-Ano: The FIAT Trial. *Ann Surg* 2021; **273**: 433-441 [PMID: 32516229 DOI: 10.1097/SLA.0000000000003981]
- 6 **Garg P**, R Menon G, Kaur B. Comparison of different methods to manage supralelevator rectal opening in anal fistulas: A retrospective cohort study. *Cir Esp (Engl Ed)* 2021 [PMID: 33875192 DOI: 10.1016/j.ciresp.2021.03.011]
- 7 **Garcia-Granero A**, Granero-Castro P, Frasson M, Flor-Lorente B, Carreño O, Espí A, Puchades I, Garcia-Granero E. Management of cryptoglandular supralelevator abscesses in the magnetic resonance imaging era: a case series. *Int J Colorectal Dis* 2014; **29**: 1557-1564 [PMID: 25339133 DOI: 10.1007/s00384-014-2028-2]
- 8 **Parks AG**, Gordon PH, Hardcastle JD. A classification of fistula-in-ano. *Br J Surg* 1976; **63**: 1-12 [PMID: 1267867 DOI: 10.1002/bjs.1800630102]
- 9 **Garg P**, Dawka S, Yagnik VD, Kaur B, Menon GR. Anal fistula at roof of ischiorectal fossa inside levator-ani muscle (RIFIL): a new highly complex anal fistula diagnosed on MRI. *Abdom Radiol (NY)* 2021; **46**: 5550-5563 [PMID: 34455464 DOI: 10.1007/s00261-021-03261-y]
- 10 **Liu X**, Wang Z, Ren H, Ren A, Wang W, Yang X, Shi S. Evaluating postoperative anal fistula prognosis by diffusion-weighted MRI. *Eur J Radiol* 2020; **132**: 109294 [PMID: 33038577 DOI: 10.1016/j.ejrad.2020.109294]
- 11 **Halligan S**, Tolan D, Amitai MM, Hoeffel C, Kim SH, Maccioni F, Morrin MM, Mortele KJ, Rafaelsen SR, Rimola J, Schmidt S, Stoker J, Yang J. ESGAR consensus statement on the imaging of fistula-in-ano and other causes of anal sepsis. *Eur Radiol* 2020; **30**: 4734-4740 [PMID: 32307564 DOI: 10.1007/s00330-020-06826-5]
- 12 **De Hous N**, Van den Broeck T, de Gheldere C. Fistulectomy and primary sphincteroplasty (FIPS) to prevent keyhole deformity in simple anal fistula: a single-center retrospective cohort study. *Acta Chir Belg* 2021; **121**: 308-313 [PMID: 32253992 DOI: 10.1080/00015458.2020.1753151]
- 13 **Ratto C**, Litta F, Marra AA, Campenni P, De Simone V, Parello A. Fistulotomy plus end-to-end primary sphincteroplasty - a video vignette. *Colorectal Dis* 2021; **23**: 2213-2214 [PMID: 34022114 DOI: 10.1111/codi.15745]
- 14 **Litta F**, Parello A, Ferri L, Torrecilla NO, Marra AA, Orefice R, De Simone V, Campenni P, Goglia M, Ratto C. Simple fistula-in-ano: is it all simple? *Tech Coloproctol* 2021; **25**: 385-399 [PMID: 33387100 DOI: 10.1007/s10151-020-02385-5]
- 15 **Fröhlich B**, Höttinger H, Fritsch H. Tomographical anatomy of the pelvis, pelvic floor, and related structures. *Clin Anat* 1997; **10**: 223-230 [PMID: 9213037 DOI: 10.1002/(SICI)1098-2353(1997)10:4<223::AID-CA1>3.0.CO;2-T]

- 16 **Garg P**, Kaur B, Goyal A, Yagnik VD, Dawka S, Menon GR. Lessons learned from an audit of 1250 anal fistula patients operated at a single center: A retrospective review. *World J Gastrointest Surg* 2021; **13**: 340-354 [PMID: [33968301](#) DOI: [10.4240/wjgs.v13.i4.340](#)]
- 17 **van Rijn KL**, Lansdorp CA, Tielbeek JAW, Nio CY, Buskens CJ, D'Haens GRAM, Löwenberg M, Stoker J. Evaluation of the modified Van Assche index for assessing response to anti-TNF therapy with MRI in perianal fistulizing Crohn's disease. *Clin Imaging* 2020; **59**: 179-187 [PMID: [31821976](#) DOI: [10.1016/j.clinimag.2019.10.007](#)]
- 18 **Balci S**, Onur MR, Karaosmanoğlu AD, Karçaaltıncaba M, Akata D, Konan A, Özmen MN. MRI evaluation of anal and perianal diseases. *Diagn Interv Radiol* 2019; **25**: 21-27 [PMID: [30582572](#) DOI: [10.5152/dir.2018.17499](#)]
- 19 **Konan A**, Onur MR, Özmen MN. The contribution of preoperative MRI to the surgical management of anal fistulas. *Diagn Interv Radiol* 2018; **24**: 321-327 [PMID: [30272562](#) DOI: [10.5152/dir.2018.18340](#)]
- 20 **Almeida IS**, Jayarajah U, Wickramasinghe DP, Samarasekera DN. Value of three-dimensional endoanal ultrasound scan (3D-EAUS) in preoperative assessment of fistula-in-ano. *BMC Res Notes* 2019; **12**: 66 [PMID: [30696490](#) DOI: [10.1186/s13104-019-4098-2](#)]
- 21 **Youssef A**. The Ultrasound of Perianal External Opening. *Gastroenterol Hepatol Int J* 2017; **2**: 000128
- 22 **Lefrançois P**, Zummo-Soucy M, Olivié D, Billiard JS, Gilbert G, Garel J, Visée E, Manchec P, Tang A. Diagnostic performance of intravoxel incoherent motion diffusion-weighted imaging and dynamic contrast-enhanced MRI for assessment of anal fistula activity. *PLoS One* 2018; **13**: e0191822 [PMID: [29370278](#) DOI: [10.1371/journal.pone.0191822](#)]
- 23 **Erden A**. MRI of anal canal: normal anatomy, imaging protocol, and perianal fistulas: Part 1. *Abdom Radiol (NY)* 2018; **43**: 1334-1352 [PMID: [28840368](#) DOI: [10.1007/s00261-017-1305-2](#)]
- 24 **Garg P**, Sodhi SS, Garg N. Management of Complex Cryptoglandular Anal Fistula: Challenges and Solutions. *Clin Exp Gastroenterol* 2020; **13**: 555-567 [PMID: [33204136](#) DOI: [10.2147/CEG.S198796](#)]
- 25 **Nottingham JM**, Rentea RM. Anal Fistulotomy. StatPearls. Treasure Island (FL), 2021
- 26 **Buhlaigah H**, Truong A, Zaghiyan K, Fleshner P. Clinical Factors Associated With Response to Fecal Diversion in Crohn's Disease. *Am Surg* 2020; **86**: 1277-1280 [PMID: [33150794](#) DOI: [10.1177/0003134820964223](#)]
- 27 **Truong A**, Zaghiyan K, Fleshner P. Anorectal Crohn's Disease. *Surg Clin North Am* 2019; **99**: 1151-1162 [PMID: [31676054](#) DOI: [10.1016/j.suc.2019.08.012](#)]
- 28 **Cao Y**, Su Q, Zhang B, Shen F, Li S. Efficacy of stem cells therapy for Crohn's fistula: a meta-analysis and systematic review. *Stem Cell Res Ther* 2021; **12**: 32 [PMID: [33413661](#) DOI: [10.1186/s13287-020-02095-7](#)]
- 29 **Garg P**, Goyal A, Yagnik VD, Dawka S, Menon GR. Diagnosis of anorectal tuberculosis by polymerase chain reaction, GeneXpert and histopathology in 1336 samples in 776 anal fistula patients. *World J Gastrointest Surg* 2021; **13**: 355-365 [PMID: [33968302](#) DOI: [10.4240/wjgs.v13.i4.355](#)]
- 30 **Guyatt G**, Gutterman D, Baumann MH, Addrizzo-Harris D, Hylek EM, Phillips B, Raskob G, Lewis SZ, Schünemann H. Grading strength of recommendations and quality of evidence in clinical guidelines: report from an american college of chest physicians task force. *Chest* 2006; **129**: 174-181 [PMID: [16424429](#) DOI: [10.1378/chest.129.1.174](#)]
- 31 **Aguayo-Albasini JL**, Flores-Pastor B, Soria-Aledo V. [GRADE system: classification of quality of evidence and strength of recommendation]. *Cir Esp* 2014; **92**: 82-88 [PMID: [24361098](#) DOI: [10.1016/j.ciresp.2013.08.002](#)]
- 32 **Chen Y**, Yang K, Marušić A, Qaseem A, Meerpohl JJ, Flottorp S, Akl EA, Schünemann HJ, Chan ES, Falck-Ytter Y, Ahmed F, Barber S, Chen C, Zhang M, Xu B, Tian J, Song F, Shang H, Tang K, Wang Q, Norris SL; RIGHT (Reporting Items for Practice Guidelines in Healthcare) Working Group. A Reporting Tool for Practice Guidelines in Health Care: The RIGHT Statement. *Ann Intern Med* 2017; **166**: 128-132 [PMID: [27893062](#) DOI: [10.7326/M16-1565](#)]
- 33 **Appraisal of Guidelines for Research and Evaluation**. Global Rating Scale. [cited 16 September 2021]. Available from: <https://www.agreetrust.org/wp-content/uploads/2017/11/AGREE-GRS.pdf>
- 34 **Burns PB**, Rohrich RJ, Chung KC. The levels of evidence and their role in evidence-based medicine. *Plast Reconstr Surg* 2011; **128**: 305-310 [PMID: [21701348](#) DOI: [10.1097/PRS.0b013e318219c171](#)]
- 35 **Brillantino A**, Iacobellis F, Reginelli A, Monaco L, Sodano B, Tufano G, Tufano A, Maglio M, De Palma M, Di Martino N, Renzi A, Grassi R. Preoperative assessment of simple and complex anorectal fistulas: Tridimensional endoanal ultrasound? *Radiol Med* 2019; **124**: 339-349 [PMID: [30607867](#) DOI: [10.1007/s11547-018-0975-3](#)]
- 36 **Mathew RP**, Patel V, Low G. Caution in using 3D-EAUS as the first-line diagnostic tool in the preoperative work up for perianal fistulas. *Radiol Med* 2020; **125**: 155-156 [PMID: [31679127](#) DOI: [10.1007/s11547-019-01101-0](#)]
- 37 **Grossberg SJ**, Harran N, Bebington B, Lutrin DL. Use of the OVESCO OTSC® Proctology Clip for closure of fistula-in-ano at Wits Donald Gordon Medical Centre - a single centre experience. *S Afr J Surg* 2020; **58**: 74-77 [PMID: [32644310](#)]
- 38 **Mascagni D**, Pironi D, Grimaldi G, Romani AM, La Torre G, Eberspacher C, Palma R, Sorrenti S, Pontone S. OTSC® Proctology vs. fistulectomy and primary sphincter reconstruction as a treatment for low trans-sphincteric anal fistula in a randomized controlled pilot trial. *Minerva Chir* 2019; **74**: 1-6 [PMID: [29397638](#) DOI: [10.23736/S0026-4733.18.07617-4](#)]
- 39 **Marinello F**, Kraft M, Ridaura N, Vallribera F, Espín E. Treatment of Fistula-in-ano With OTSC® Proctology Clip Device: Short-term Results. *Cir Esp (Engl Ed)* 2018; **96**: 369-374 [PMID: [29525123](#) DOI: [10.1016/j.ciresp.2018.02.003](#)]
- 40 **Tao Y**, Zheng Y, Han JG, Wang ZJ, Cui JJ, Zhao BC, Yang XQ. Effects of an anal fistula plug on anal function after surgery for treatment of a trans-sphincteric anal fistula. *Langenbecks Arch Surg* 2021; **406**: 855-861 [PMID: [33174168](#) DOI: [10.1007/s00423-020-02024-5](#)]
- 41 **Huang B**, Wang X, Zhou D, Chen S, Li B, Wang Y, Tai J. Treating highly complex anal fistula with a new method of combined intraoperative endoanal ultrasonography (IOEAUS) and transanal opening of intersphincteric space (TROPIS). *Wideochir Inne Tech Maloinwazyjne* 2021; **16**: 697-703 [PMID: [34950264](#) DOI: [10.5114/wiitm.2021.104368](#)]
- 42 **Bevans DW Jr**, Westbrook KC, Thompson BW, Caldwell JT. Perirectal abscess: a potentially fatal illness. *Am J Surg* 1973; **126**: 765-768 [PMID: [4586132](#) DOI: [10.1016/s0002-9610\(73\)80067-4](#)]
- 43 **Ferguson EF Jr**, Houston CH. Iatrogenic supralelevator fistula. *South Med J* 1978; **71**: 490-495 [PMID: [644353](#) DOI: [10.1097/00007611-197805000-00004](#)]
- 44 **van Onkelen RS**, Gosselink MP, Schouten WR. Treatment of anal fistulas with high intersphincteric extension. *Dis Colon Rectum* 2013; **56**: 987-991 [PMID: [23838868](#) DOI: [10.1097/DCR.0b013e3182908be6](#)]

- 45 **Malakorn S**, Sammour T, Khomvilai S, Chowchankit I, Gunarasa S, Kanjanasilp P, Thiptanakij C, Rojanasakul A. Ligation of Intersphincteric Fistula Tract for Fistula in Ano: Lessons Learned From a Decade of Experience. *Dis Colon Rectum* 2017; **60**: 1065-1070 [PMID: [28891850](#) DOI: [10.1097/DCR.0000000000000880](#)]
- 46 **Litta F**, Parello A, De Simone V, Grossi U, Orefice R, Ratto C. Fistulotomy and primary sphincteroplasty for anal fistula: long-term data on continence and patient satisfaction. *Tech Coloproctol* 2019; **23**: 993-1001 [PMID: [31538298](#) DOI: [10.1007/s10151-019-02093-9](#)]
- 47 **Perez F**, Arroyo A, Serrano P, Sánchez A, Candela F, Perez MT, Calpena R. Randomized clinical and manometric study of advancement flap vs fistulotomy with sphincter reconstruction in the management of complex fistula-in-ano. *Am J Surg* 2006; **192**: 34-40 [PMID: [16769272](#) DOI: [10.1016/j.amjsurg.2006.01.028](#)]
- 48 **Garcia-Olmo D**, Herreros D, Pascual I, Pascual JA, Del-Valle E, Zorrilla J, De-La-Quintana P, Garcia-Arranz M, Pascual M. Expanded adipose-derived stem cells for the treatment of complex perianal fistula: a phase II clinical trial. *Dis Colon Rectum* 2009; **52**: 79-86 [PMID: [19273960](#) DOI: [10.1007/DCR.0b013e3181973487](#)]
- 49 **CEBM**. OCEBM levels of evidence. [cited 11 January 2022]. Available from: <https://www.cebm.ox.ac.uk/resources/levels-of-evidence/ocebml-levels-of-evidence>



Published by **Baishideng Publishing Group Inc**
7041 Koll Center Parkway, Suite 160, Pleasanton, CA 94566, USA

Telephone: +1-925-3991568

E-mail: bpgoffice@wjgnet.com

Help Desk: <https://www.f6publishing.com/helpdesk>

<https://www.wjgnet.com>

